

## Forenzična rekonstrukcija lica muškarca s lokaliteta Rižinice i aproksimacija morfologije nedostajuće mandibule

*Forenzična rekonstrukcija lica je multidisciplinarna forenzična disciplina koja se analizom morfologije kostiju lica i glave koristi u svrhu identifikacije nepoznate osobe u kriminalističkim slučajevima. Primarna implementacija rekonstrukcije lica koristi se u forenzici, kriminalističkim istragama, ali i u antropologiji i arheologiji. Forenzična rekonstrukcija lica uglavnom se primjenjuje u identifikaciji koštanih ostataka nepoznate osobe kada su ostale metode identifikacije neuspješne. DNK analiza i usporedba zuba pomoću stomatološkog kartona nerijetko je neuspješna kad ne postoji referentni uzorak za usporedbu, te se identifikacija osobe u tim slučajevima oslanja na rekonstrukciju lica. Rekonstrukcija lica samo je sredstvo za prepoznavanje, odnosno stvaranje popisa mogućih žrtava kojima se potom identitet potvrđuje pomoću DNK profila, analizom zubnog kartona ili nekom drugom pravno prihvatljivom metodom za identifikaciju. Glavna svrha ovog rada je izrada rekonstrukcije lica muške osobe u svrhu provjere metode rekonstrukcije morfologije mandibule kada mandibula nije dostupna. Lubanja muške osobe fotografirana je frontalno i u profilu, te se preko tih fotografija gradilo lice u Adobe Photoshop CC programu. Pri izradi lica muške osobe koristila se dvodimenzionalna metoda rekonstrukcije koja uključuje postupno građenje karakteristika lica uz pomoć fotografija iz baze podataka pridržavajući se antropometrijskih podataka specifičnih za dob, spol i podrijetlo pojedinca. Ovim radom predstavljaju se rezultati i metodologija izrade rekonstrukcije lica osobe s lokaliteta Rižinice i metoda aproksimacije morfologije nedostajuće mandibule.*

**Ključne riječi:** forenzika; rekonstrukcija lica, Rižinice, Adobe Photoshop.

# Forensic facial reconstruction of a male from the site of Rižinice and approximation of the morphology of the missing mandible

*Forensic facial reconstruction is a multidisciplinary forensic discipline that uses the analysis of facial and cranial bone morphology for the purpose of identifying unknown persons in criminal cases. Facial reconstruction is primarily implemented in forensics and criminal investigations, as well as in anthropology and archaeology. Forensic facial reconstruction is mainly applied in the identification of bone remains of unknown individuals when other methods of identification have failed. DNA analysis and comparison of teeth using dental records are often unsuccessful when there is no reference sample for comparison, and the identification in these cases relies on facial reconstruction. Facial reconstruction is but a means of recognising, i.e. creating a list of possible victims whose identity is then confirmed by DNA profile, dental record analysis or some other legally acceptable method of identification. The main goal of this paper is to present the procedure of reconstructing the face of a male person in order to test the method of reconstruction of the morphology of the mandible when the mandible is not available. The skull of a male person was photographed from the front and sides, and a face was built in Adobe Photoshop CC. A two-dimensional reconstruction method was used to make the man's face, involving gradual development of facial features with the help of photographs from the database, while adhering to anthropometric data specific to the age, sex and ancestry of an individual. This paper presents the results and methodology of reconstruction of the face of a person from the site of Rižinice, and the method of approximation of the morphology of the missing mandible.*

*Keywords: forensics, facial reconstruction, Rižinice, Adobe Photoshop.*

## 1. Uvod

Forenzična rekonstrukcija lica temelji se na odnosu koštanog tkiva lubanje s potkožnim mekim tkivom i crtama lica nastalim kombinacijom morfologije lubanje i debljine i/ili oblika mekog tkiva<sup>1</sup>. Facijalne rekonstrukcije primjenu nalaze u forenzici i kriminalističkim istragama, ali i antropologiji i arheologiji<sup>2</sup>. Proizvedena rekonstrukcija lica može biti dvodimenzionalna (2D), koja se postiže crtanjem lica preko fotografije lubanje, i trodimenzionalna (3D), koja uključuje modeliranje lica, manualno ili virtualno, preko modela lubanje nepoznate osobe u mjerilu 1:1. U dvodimenzionalnoj rekonstrukciji lubanja se fotografira sa svim bitnim markerima za debljine mekog tkiva<sup>3</sup> na odgovarajućim anatomskim mjestima, te se koristi papir za precrtavanje ili bilo koji drugi prozirni papir koji se postavlja preko slike lubanje. Forenzični umjetnik crta lice na prozirnem papiru pažljivo prateći markere debljine tkiva te konture lubanje. Prije početka izrade 2D rekonstrukcije lica potrebno je postaviti markere za debljine tkiva na odgovarajuće anatomске točke. Nakon što su markeri zalijepljeni, lubanja se fotografira iz najmanje tri pozicije: frontalno, profil i poluprofil, a fotografije se razvijaju u prirodnoj veličini lubanje. Na ovaj način moguće je koristiti informacije svih markera, jer kamera odmah oduzima visinu s markera koja nestaje perspektivnim skraćivanjem, isto kao što se događa s licem na fotografiji. Dodatno, povećavanjem fotografije na prirodnu veličinu moguće je koristiti se svim formulama za predviđanje pojedinih značajki lica koje se inače koriste kod 3D rekonstrukcija. 2D rekonstrukcija pogodna je za rad s lubanjama koje su previše lomljive za izradu kalupa za replike lubanje koja bi se koristila kao baza za rekonstrukciju lica<sup>4</sup>.

Prilikom rekonstrukcije važno je pratiti konture kostiju u odnosu na markere za debljine mekanog tkiva, te posvetiti posebnu pozornost na značajke kao što su zubi, oblik orbita, most nosa, nazalni otvori te izraženost mišićnih polazišta i hvatišta. Obrisi lica koje diktiraju koštane formacije lubanje i indikatori dubine tkiva jednostavno će „spo-

## 1. Introduction

Forensic facial reconstruction is based on the relationship of skull bone tissue to subcutaneous soft tissue and facial features resulting from a combination of skull morphology and thickness and/or shape of soft tissue<sup>1</sup>. Facial reconstructions are used in forensics and criminal investigations, as well as in anthropology and archaeology<sup>2</sup>. Completed facial reconstructions can be two-dimensional (2D), achieved by drawing the face over a photograph of the skull, and three-dimensional (3D), which involves face modelling, either manual or virtual, over the skull model of an unknown person at a scale of 1:1. In two-dimensional reconstructions, the skull is photographed with all the essential soft tissue thickness markers<sup>3</sup> at the appropriate anatomical points, with tracing paper or any other transparent paper placed over the image of the skull. The forensic artist then draws the face on the transparent paper, carefully following the tissue depth markers and contours of the skull. Before making a 2D facial reconstruction, it is necessary to place tissue depth markers at the relevant anatomical points. Once the markers are glued, the skull is photographed from at least three positions: frontal, profile, and semi-profile, and the photographs are made in the life-size of the skull. In this way, it is possible to utilise the information of all markers, because the camera instantly subtracts the height vanishing due to perspective shortening, just as it happens with the face in the photograph. In addition, by enlarging the photograph to life size, it is possible to use all the formulae for prediction of respective facial features which are normally used in 3D reconstructions. 2D reconstruction is suitable for working with skulls that are too fragile to make a mould for skull replicas to be used as a base for facial reconstruction<sup>4</sup>.

During reconstruction, it is important to follow the contours of the bones in relation to the soft tissue depth markers, and pay special attention to features such as the teeth, orbital shape, nasal bridge, nasal apertures, and the points of muscle attachment. The facial outline as dictated by the bone formations of

<sup>1</sup> Ramesh et al. 2016, str. 1.

<sup>2</sup> Polić, Petaros, Cuculić, Bosnar 2012, str. 30.

<sup>3</sup> Markerima za debljine mekog tkiva ili osteometrijski markeri su biljezi pričvršćeni na lubanju preko lica, a označavaju standardnu debljinu mekog tkiva na više anatomskih točaka. Hines et al. 2010, str. 9.

<sup>4</sup> Morier 1993, str. 2.

<sup>1</sup> Ramesh et al. 2016, p. 1.

<sup>2</sup> Polić, Petaros, Cuculić, Bosnar 2012, p. 30.

<sup>3</sup> Soft tissue thickness markers or osteometric markers are implements for marking which are attached to the skull to indicate the standard soft tissue depth at multiple anatomical points across the face. Hines et al. 2010, p. 9.

<sup>4</sup> Morier 1993, p. 2.

jiti točkice“ koje stvaraju konture obraza, čeljusti i brade<sup>5</sup>. U današnje doba programi kao što su CARES (*Computer Assisted Recovery Enhancement System*), FACES (*Forensic Anthropology Computer Enhancement System*) i drugi brzo stvaraju 2D rekonstrukcije kojima se može manipulirati te ih se može obraditi. Ovi programi ubrzavaju proces rekonstrukcije te stvaraju više općenitijih slika koje je zatim potrebno u razumnoj dozi personalizirati<sup>6</sup>. Uspješnost personalizacije rekonstrukcije lica ovisi isključivo o iskustvu i vještini osobe koja izvodi rekonstrukciju. Metodologija izrade forenzične rekonstrukcije lica znatno je napredovala u zadnjem desetljeću, no izrada rekonstrukcije bez mandibule česta je zbog degradacije mekanog tkiva koje spaja mandibulu s ostatkom kranijalnog kostura. Izrada bez mandibule znatno otežava postizanje precizne rekonstrukcije.<sup>7</sup> Tradicionalne metode rekonstrukcije pristupaju aproksimaciji mandibule prema utvrđenim standardima u jednoj populaciji te ne uzimaju u obzir morfološke varijacije mandibule kod koštanih ostataka koje mogu znatno utjecati na izgled lica osobe<sup>8</sup>. Iz navedenog razloga uvijek je poželjno raditi s informacijama specifičnima za određenu populaciju.

## 2. Metoda aproksimacije morfologije mandibule

Glavni cilj bilo koje tehnike facijalne rekonstrukcije jest stvoriti izgled lica osobe iz koštanih ostataka tako da ima dovoljnu sličnost s izgledom osobe prije smrti<sup>9</sup>. Odabir metode rekonstrukcije prvobitno ovisi o stanju koštanih ostataka, zatim o potrebama osobe koja traži rekonstrukciju, te vremenskom razdoblju u kojem rekonstrukcija mora biti izvedena. Za potrebe ovog rada odlučeno je izvesti 2D rekonstrukciju.

2D rekonstrukcija lica u slučajevima kada nema mandibule, započinje s pripremom koja uključuje fotografiranje lubanje, frontalno i u profilu, na frankfurtskoj horizontali,<sup>10</sup> na tu se sliku dodaje mandi-

the skull and the tissue depth indicators will simply “connect the dots” that create the contours of the cheeks, jaw and chin<sup>5</sup>. Nowadays, various computer software programs like CARES (*Computer Assisted Recovery Enhancement System*), FACES (*Forensic Anthropology Computer Enhancement System*) and others can quickly produce 2D reconstructions which can be manipulated and edited. These programs speed the reconstruction process and produce a number of generic images that need to be reasonably personalised<sup>6</sup>. The success in personalising facial reconstructions depends solely on the experience and skill of the person performing the reconstruction. The methodology of forensic facial reconstruction has advanced significantly in the last decade. However, reconstructions without the mandible are common due to the degradation of the soft tissue that connects the mandible to the rest of the cranial skeleton. Reconstruction without the mandible makes it much more difficult to achieve precision<sup>7</sup>. Traditional methods of reconstruction approach the approximation of the mandible according to established standards in a population and do not take into account the morphological variations of the mandible in skeletal remains that can significantly affect the appearance of a person’s face<sup>8</sup>. For this reason, it is always advisable to use population-specific information.

## 2. Mandibular morphology approximation method

The main objective of any facial reconstruction technique is to create the appearance of a person’s face from skeletal remains so that it sufficiently resembles the person before death<sup>9</sup>. The choice of reconstruction method initially depends on the condition of the skeletal remains, then on the requirements of the person asking for reconstruction, and the time period in which the reconstruction is to be performed. For the purposes of this paper, it was decided to perform a 2D reconstruction.

Where there is no mandible, 2D facial reconstruction begins with preparation, including skull photography, which includes frontal and lateral

<sup>5</sup> Taylor 2000, str. 378-395.

<sup>6</sup> Yadav, Panat, Aggarwal, 2010, str. 40.

<sup>7</sup> Sanggarnjanavanich *et al.* 2014, str. 82-91. / Viloriaa, Mendinuetab, Borreroc, Pinedad 2020, str. 370-375.

<sup>8</sup> Hou, Wang, Li 2007, str. 2408-2415.

<sup>9</sup> Ubelaker, O’Donnell 1992, str. 155.

<sup>10</sup> Ravnina koja spaja gornji rub vanjskoga slušnog hodnika s donjim rubom očne šupljine. Lubanja se postavlja na način da navedena ravnina bude paralelna s podlogom na kojoj lubanja stoji. Frankfurtska ho-

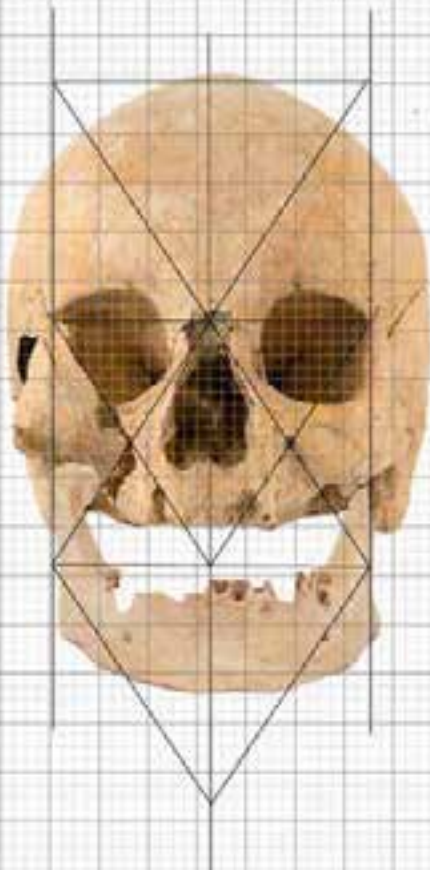
<sup>5</sup> Taylor 2000, pp. 378-395.

<sup>6</sup> Yadav, Panat, Aggarwal, 2010, p. 40.

<sup>7</sup> Sanggarnjanavanich *et al.* 2014, pp. 82-91. / Viloriaa, Mendinuetab, Borreroc, Pinedad 2020, pp. 370-375.

<sup>8</sup> Hou, Wang, Li 2007, pp. 2408-2415.

<sup>9</sup> Ubelaker, O’Donnell 1992, p. 155.



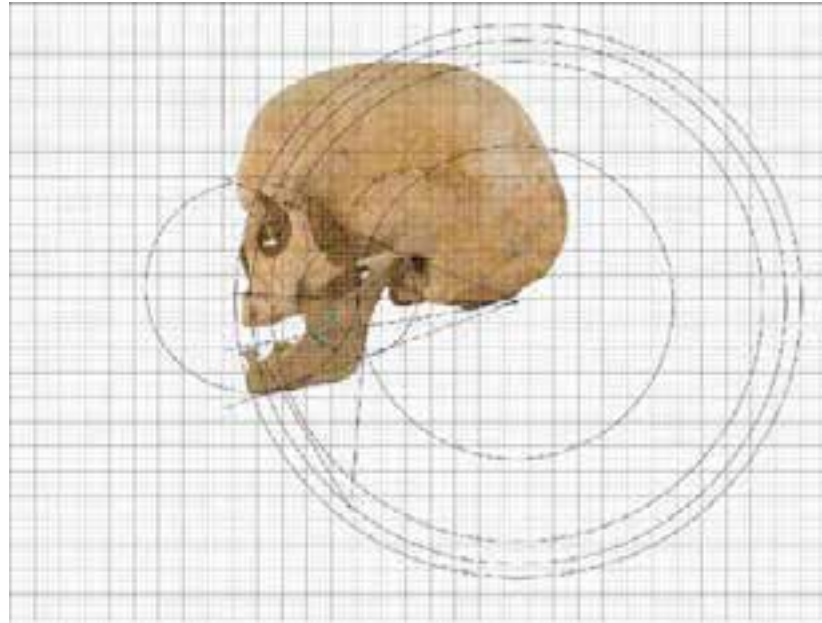
Sl. 1. Postavljanje mandibule (foto: J. Marić)  
Fig. 1 Mandibular placement (photo: J. Marić)

bula druge osobe i prilagođava morfologiji ostatka lubanje. Rekonstrukcija mandibule izvedena je u programu *Adobe Photoshop CC* jer on dopušta dodavanje fotografije mandibule druge osobe u odgovarajući anatomske položaj i deformaciju slike da odgovara morfologiji lubanje osobe čije se lice rekonstruira. Promjena oblika mandibule provedena je prema pravilima Vikena Sassounija (1957)<sup>11</sup> za proporcije mandibule u odnosu na ostatak lubanje. Prije početka prilagođavanja mandibule ostatku lubanje nova je mandibula precizno postavljena na lubanju tako da kondil upada u zglobnu plohu *glenoid fosse*. Zatim se određuju točke na anatomskim mjestima na lubanji i horizontalne ravnine (anteriorna baza kranijuma, bispinale, *occlusal* i mandibular) potrebne za analizu<sup>12</sup> (sl. 1). Navedene ravnine sijeku se u točki *O* kada je lice proporcionalno (sl. 2).

rizontala <http://struna.ihjj.hr/naziv/frankfurtska-horizontala/15298/>.

<sup>11</sup> V. Sassouni 1957, str. 428-442.

<sup>12</sup> Krogman, Iscan 1986, str. 458-479.



Sl. 2. Ravnine i lukovi prema Sassounijevoj cefalometrijskoj analizi, lateralni pogled (foto: J. Marić)

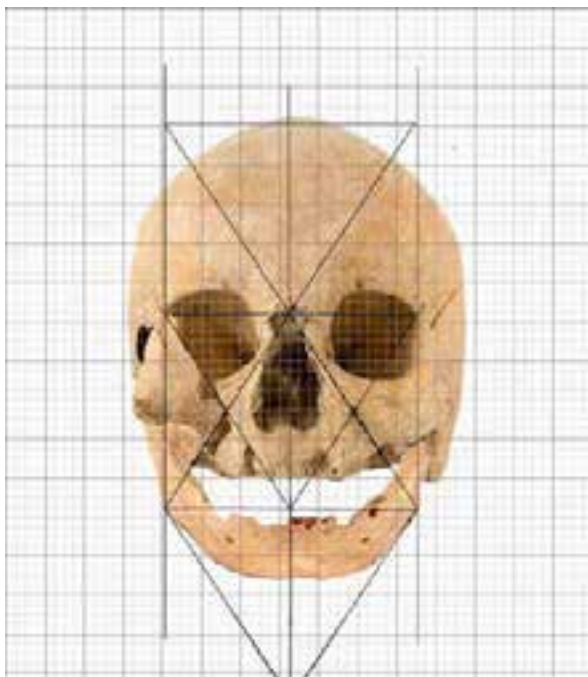
Fig. 2 Planes and arcs according to the Sassouni cephalometric analysis, lateral view (photo: J. Marić)

views, on the Frankfort Horizontal<sup>10</sup>. The mandible of some other person is added to this image and adapted to the morphology of the rest of the skull. Mandibular reconstruction was performed in *Adobe Photoshop CC* because it allows adding a photograph of another person's mandible to the appropriate anatomical position and image deformation to match the morphology of the skull of the person whose face is being reconstructed. The change in the shape of the mandible was performed according to the rules of Viken Sassouni (1957)<sup>11</sup> for the proportions of the mandible in relation to the rest of the skull. Before adjusting the mandible to the rest of the skull, the new mandible is precisely placed on the skull so that the condyle is positioned inside the *glenoid fossa*. The anatomical points on the skull and the horizontal planes (the anterior cranial base, bispinal, *occlusal* and mandibular) required for analysis<sup>12</sup> are then determined (Fig. 1). These

<sup>10</sup> The plane connecting the upper edge of the external auditory meatus to the lower edge of the orbit. The skull is placed in such a way that the plane is parallel to the base on which the skull stands. Frankfurt-ska horizontala <http://struna.ihjj.hr/naziv/frankfurtska-horizontala/15298/>.

<sup>11</sup> V. Sassouni 1957, pp. 428-442.

<sup>12</sup> Krogman, Iscan 1986, pp. 458-479.



Sl. 3. Mandibula nakon deformacije prema Sassounijevim pravilima, frontalni pogled  
(foto: J. Marić)

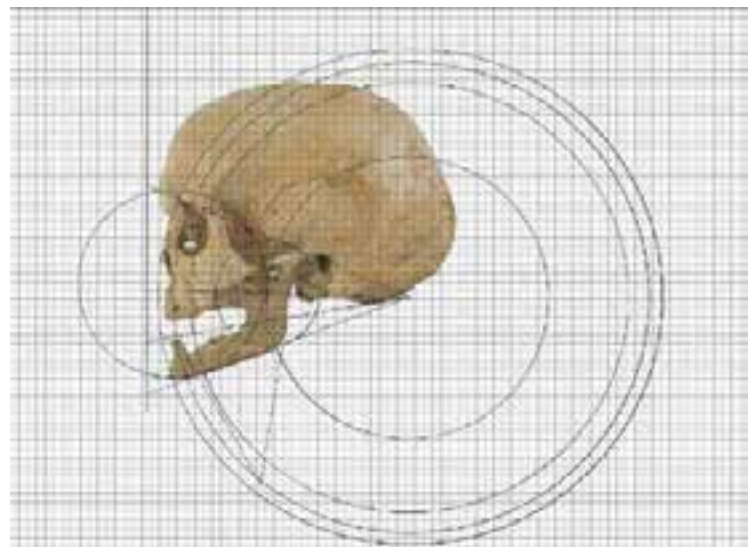
*Fig. 3 Mandible after deformation according to the rules described by Sassouni, frontal view  
(photo: J. Marić)*

Korekcije kosti na navedenim ravninama rezultirat će odgovarajućim vertikalnim proporcijama lica i ispravkom malokluzije. Kada su ravnine na sagitalnoj osi postavljene, crtaju se kružnice, sa središtem na točki *O*, koje prolaze kroz relevantne anatomske točke korištene za određivanje proporcija lubanje. Promjene na mandibuli trebale bi slijediti navedene ravnine tako da nosni greben, zubi gornje čeljusti i brada leže na luku iste kružnice<sup>13</sup> (sl. 3, sl. 4).

### 3. Rekonstrukcija lica muške osobe

Rekonstrukcija lica osobe napravljena je za potrebe multimedijalne izložbe te je iz tog razloga odlučeno raditi dvodimenzionalnu rekonstrukciju muške osobe koja će se na izložbi projicirati preko projektor na fotografiju lubanje. Rekonstrukcija lica muške osobe napravljena je u *Adobe Photoshop CC* programu, te je uključivala rezanje i lijepljenje odgovarajućih karakteristika lica, iz postojećih fotografija iz baze podataka, na fotografiju lubanje. Svaki od zalijepljenih dijelova fotografija prilagođavao se morfologiji kostiju lica, kako bi se postigao što vjerodostojniji prikaz osobe.

<sup>13</sup> Mahoney, Milani, Billinger, Lywood, Gruppioni 2011, str. 368-370.



Sl. 4. Mandibula nakon deformacije prema Sassounijevim pravilima, lateralni pogled  
(foto: J. Marić)

*Fig. 4 Mandible after deformation according to the rules described by Sassouni, lateral view  
(photo: J. Marić)*

planes intersect at point *O* when the face is proportional (Fig. 2). Bone adjustments on these planes will result in appropriate vertical facial proportions and corrected malocclusion. When the planes are positioned on the sagittal axis, circles are drawn, centred at the point *O*, which pass through the relevant anatomical points used to determine the proportions of the skull. The changes on the mandible should follow the planes so that the nasal ridge, the teeth of the upper jaw and the chin lie on the arc of the same circle<sup>13</sup> (Fig. 3, Fig. 4).

### 3. Facial reconstruction of a male

The facial reconstruction was made for a multimedia exhibition. For that reason, two-dimensional reconstruction of the male was chosen, to be projected on the photograph of the skull at the exhibition. The face of the male was reconstructed using *Adobe Photoshop CC*, and included cutting and pasting the relevant facial features from the existing database photographs to the skull photograph. Each of the pasted photo parts was adapted to the morphology of the facial bones, in order to achieve as authentic representation of the person as possible.

During the reconstruction, the only available data concerned the person's gender, age and race.

<sup>13</sup> Mahoney, Milani, Billinger, Lywood, Gruppioni 2011, pp. 368-370.

Prilikom rekonstrukcije bili su dostupni samo podaci o spolu, dobi i rasi. Radila se rekonstrukcija frontalne strane lica zbog čega su na lubanju pričvršćeni samo markeri za debljine mekanog tkiva relevantni za izradu frontalne strane lica. Anatomske točke korištene za nanošenje mjera debelog tkiva muške osobe su: *vertex*, *tragion*, *zygion*, *alare*, *gonion*, *menton*. Srednja vrijednost visina markera za debljine mekog tkiva određena je prema podacima iz Helmerova istraživanja za odraslog muškog Europeida, starog između 40 i 59 godina, normalnog indeksa tjelesne mase.

Facijalna rekonstrukcija muške osobe postignuta je korištenjem istih pravila antropološke procjene morfoloških značajki kostiju lica i glave kao i kod ostalih metoda rekonstrukcije lica. Za potrebe ove rekonstrukcije bilo je potrebno odrediti opći oblik lica; oblik obrva; morfologiju očiju - položaj i oblik očnog otvora, protruziju očnih jabučica, izgled kapaka); oblik i visinu nosa, širinu i položaj nosnica, pravac pružanja nosa; oblik, veličini i debljinu usana; izgled brade (sl. 5). Nije se izvodila facijalna rekonstrukcija profila ove osobe te nije bilo potrebno odrediti veličinu nosa, protruziju usana i brade. Nije se radila ni procjena morfologije *canine fossa* i frontalnog dijela zigomatičnih kostiju u svrhu određivanja naglašenosti nazolabijalnog nabora, jer je ta karakteristika povezana i sa starenjem.

Promjene povezane sa starenjem su predvidljive, no vrijeme nastajanja posve je individualno. Ove promjene ne pojavljuju se kod svakog pojedinca u istoj dobi, zbog čega postoje velike varijacije u izgledu pojedinaca iste dobi.<sup>14</sup> Koža na području obraza počinje se opuštati, što uzrokuje stvaranje nazolabijalnih nabora koji postaju dublji i izraženiji s godinama.<sup>15</sup> Osobe starije od 40 godina obično imaju naglašeni nazolabijalni nabor. Procijenjena biološka dob muške osobe s Rižinice je između 45 i 57 godina, te je bilo potrebno rekonstrukciju prilagoditi izgledu osobe odgovarajuće dobi. Površinske promjene na koži lica povezane sa starenjem jako su važne za realističan prikaz, ali su potpuno prepuštene umjetničkoj interpretaciji. Promjene na koži lica dobro su poznate i dokumentirane, te prate predvidljiv obrazac: koža gubi elastičnost zbog biokemijskih promjena u potkožnom vezivnom tkivu, te se slabije drži za kosti ili mišiće koji se nalaze ispod; bore nastaju zbog promjena u distribuciji i formaciji

Frontal facial reconstruction was made, which is why only soft tissue thickness markers relevant to the frontal side of the face were attached to the skull. The anatomical points used to mark the deep tissue of the male person are: *vertex*, *tragion*, *zygion*, *alare*, *gonion*, *menton*. The mean value of marker heights for soft tissue thickness was determined according to data from Helmer's research of an adult male Caucasian, aged between 40 and 59, of normal body mass index.

The facial reconstruction of the male was achieved by using the same rules of anthropological assessment of morphological traits of facial and head bones as in other methods of facial reconstruction. For the purposes of this reconstruction it was necessary to determine the overall shape of the face; the shape of the eyebrows; the morphology of the eyes – the position and shape of the eye opening, protrusion of the eyeball, the appearance of the eyelids); the shape and height of the nose, the width and position of the nostrils, the line of the nose; the shape, size and thickness of the lips; the appearance of the chin (Fig. 5). The face was not reconstructed in profile, and so it was not necessary to determine the size of the nose or the protrusion of the lips and chin. Also, the morphology of the *canine fossa* and the frontal part of the zygomatic bones was not assessed in order to gauge the depth on the nasolabial furrow, because this feature is also associated with ageing. The changes associated with age progression are predictable, but the time of their onset is entirely individual. These transformations do not occur in all individuals of the same age, which is why there are large variations in the appearance of individuals of the same age<sup>14</sup>. The skin of the cheeks begins to loosen, which causes the formation of nasolabial furrows that become deeper and more prominent with age<sup>15</sup>. People over the age of 40 usually have a pronounced nasolabial fold. The estimated biological age of the male from Rižinice is between 45 and 57 years, and it was necessary to adjust the reconstruction to the appearance corresponding to this age group. Changes on the facial skin surface associated with ageing are very important for realistic depiction. However, they are completely subject to artistic interpretation. Changes in facial skin have been well documented. They

<sup>14</sup> Neave 1998, p. 225.

<sup>15</sup> Takema, Yorimoto, Kawai, Imokawa 1994, pp. 641–648.

<sup>14</sup> Neave 1998, str. 225.

<sup>15</sup> Takema, Yorimoto, Kawai, Imokawa 1994, str. 641-8.



Sl. 5. Fotografija lubanje muškarca s lokaliteta Rižinice (foto: Z. Alajbeg)

*Fig. 5 Photograph of the skull of a man from the site of Rižinice (photo: Z. Alajbeg)*

kolagenog materijala u koži, smanjuje se otpornost vlakana na razvlačenje i opada broj fibroblasta, što vodi do dehidracije, gubitka adipoznog tkiva, zamagljivanje detalja irisa, gubitka kose i slično.<sup>16</sup> Starije osobe mogu izgledati kao da imaju „tužne“ oči zbog resorpcije adipoznog tkiva, a koža na području ispod očiju počinje se također opuštati, što uzrokuje stvaranje „vrećica“; nazolabijalni i mentalni nabori postaju dublji i izraženiji s godinama, nos i brada će s godinama postati prominentniji, razmak između usta i nosa se smanjuje, usne postaju tanje, a hrskavični dijelovi nosa i ušiju postaju veći.<sup>17</sup> Navedene promjene čine rekonstrukciju lica uistinu teškom uz proporcionalni rast mogućnosti pogreške s povećanjem dobi individue.

Oblik lica koje se rekonstruiralo određen je prema obliku lubanje, a oblik obrva prema uputama Fedosyutkin i Nainys (1993), odnosno prema izgledu supraorbitalnog luka i poziciji korijena nosne kosti.<sup>18</sup>

<sup>16</sup> Neave, 1998, str. 227; Khalil, Kubota, Inomata 1996, str. 721-725.

<sup>17</sup> Gonzalez-Ulloa, Flores. 1965, str. 239-246.; Takema, Yorimoto, Kawai, Imokawa 1994, str. 641-648.

<sup>18</sup> Fedosyutkin, Nainys 1993, str. 199-213.

follow a predictable pattern: the skin loses elasticity due to biochemical changes in the subcutaneous connective tissue that cause it to become less firmly attached to the underlying bones or muscles; wrinkles form due to changes in the distribution and formation of collagenous material in the skin, a decrease in the resilience of the fibres, and a decline in the number of fibroblasts, leading to dehydration, loss of adipose tissue, blurring of iris detail, hair loss, and the like<sup>16</sup>. Older persons may appear to have sunken eyes due to resorption of adipose tissue, while the suborbital region may also begin to sag, producing “bags”. Nasolabial and mental creases become more marked and deeper with increased age. The nose and chin appear more prominent and the distance between the mouth and the nose decreases, the lips become thinner, and there is some growth of the cartilaginous portions of the nose and the ears throughout adulthood<sup>17</sup>. Such changes make facial reconstructions really difficult, and the probability of error increases proportionally with the age progression of a person.

The shape of the reconstructed face was determined according to the shape of the skull, while the appearance of the eyebrows was made up as per the instructions of Fedosyutkin and Nainys (1993), i.e. according to the appearance of the supra-orbital ridge and the position of the root of the nasal bone<sup>18</sup>.

The position of the plane connecting the malar tubercle with the deepest point of the lacrimal bone<sup>19</sup> determines the slope of the eye opening, while the position of the eyeball in the orbit affects the protrusion of the eyes<sup>20</sup>. Protrusion of the eyeball is calculated using the following equation:  $18.3 - (0.4 \times \text{orbital depth})$ <sup>21</sup>. The size of the eyeball was determined according to data from Wolff's research (1997), according to which the eyeball diameter in adults averages 24 mm<sup>22</sup>, and it is positioned 4 mm away from the orbital roof and 5 mm away from

<sup>16</sup> Neave R., 1998, p. 227; Khalil, Kubota, Inomata 1996, pp. 721-725.

<sup>17</sup> Gonzalez-Ulloa, Flores. 1965, pp. 239-246.; Takema, Yorimoto, Kawai, Imokawa 1994, pp. 641-648.

<sup>18</sup> Fedosyutkin, Nainys 1993, pp. 199-213.

<sup>19</sup> Wilder 1912, pp. 415-436.

<sup>20</sup> Wilkinson 2010, pp. 235-250.

The malar tubercle is a small protrusion at the edge of the orbit a few millimetres below the frontozygomatic suture. Gray 1859, p. 45.

<sup>21</sup> Wilkinson, Mautner 2003, pp. 1-5.

<sup>22</sup> Bron, Tripathi, Tripathi 1998, pp. 571-572.



Položajem ravnine koja spaja malarni tuberkul s najdubljom točkom lakrimalne kosti<sup>19</sup> određen je nagib očnog otvora, a položaj očne jabučice u orbiti određuje protruziju očiju<sup>20</sup>. Protruzija očne jabučice računa se pomoću sljedeće jednadžbe:  $18,3 - (0,4 \times \text{dubina orbitale})$ <sup>21</sup>. Veličina očne jabučice određena je prema podatcima iz Wolffova istraživanja (1997), kojim je utvrđeno da je promjer očne jabučice kod odraslih osoba u prosjeku 24 mm<sup>22</sup>, te je pozicionirana tako da je 4 mm odmaknuta od krova orbite i 5 mm odmaknuta od zida orbite<sup>23</sup>. Zakrivljenost kapka prati zakrivljenost središnjeg dijela supraorbitalnog ruba.

Visina nosa (udaljenost između nazalne i podnazalne točke) određena je prema dužini između naziona i podnazalne točke<sup>24</sup>. Širina nosnica je 2/5 širine otvora nosnih kostiju<sup>25</sup>. Oblik nosa određen je prema izgledu kostiju na nosnom otvoru u profilu, izgledu nosne kosti i nosnog grebena<sup>26</sup>. Oblik i veličina usana određuje se prema morfologiji alveolarne kosti i dimenzijama visine zuba<sup>27</sup>, no kako koštani ostaci pokazuju resorpciju alveolarne kosti na mjestima većine zuba, nije bilo moguće odrediti širinu usta, oblik i debljinu usana prema utvrđenim standardima<sup>28</sup>. Širina usnog otvora određena je prema zlatnom rezu kojim se diktira da se mjesto spoja superiorne i inferiorne usne nalazi na okomitoj ravnini medijalnih krajeva limbusa rožnice te na 40 % donjeg lica<sup>29</sup>. Debljina usana se uobičajeno računa pomoću jednadžbe koju su razvili i istražili Wilkinson, Motwani i Chiang (2003), no kako ne postoje potrebne informacije za izvedbu navedene jednadžbe debljina usana u ovom se slučaju nije računala.<sup>30</sup> Oblik usana nije bilo moguće procijeniti niti je bilo potrebno jer je ova osoba izgubila gotovo

the wall of the orbit<sup>23</sup>. The curvature of the eyelid follows the curvature of the central part of the supra-orbital ridge.

The height of the nose (the distance between the nasal and subnasal points) was determined by the length between the nasion and the subnasal point<sup>24</sup>. The width of the nostrils is two-fifths of the width of the nasal bone aperture<sup>25</sup>. The shape of the nose was determined by the appearance of the bones on the nasal opening in profile, the nasal bone, and the nasal ridge<sup>26</sup>. The shape and size of the lips are determined by the alveolar bone morphology and teeth height<sup>27</sup>, but since bone remains exhibit the resorption of alveolar bone in most teeth, it was not possible to work out the mouth width, and the shape and thickness of the lips according to the established standards<sup>28</sup>. The width of the oral fissure was determined by the golden ratio, according to which the junction of the superior and inferior lips is on the vertical plane of the medial ends of the corneal limbus and at 40% of the lower face<sup>29</sup>. The thickness of the lips is commonly calculated using the equation developed and researched by Wilkinson, Motwani, and Chiang (2003), but due to the lack of necessary information, the lip thickness was not calculated in this case<sup>30</sup>. The shape of the lips could not be assessed nor was it necessary, because the person had lost almost all his teeth during his lifetime, and his lips were therefore thin, with a weakly accentuated cupid's arc and a thin inferior lip crossing over the superior.

#### 4. Results of the reconstruction of the male's face

In this research, the skull of a man from the site of Rižinice was used. It was photographed and utilised as a template for the reconstruction. No data on the person's identity was available, but only the basic biological profile of the person, which was known to have been an adult male, with a biological

<sup>19</sup> Wilder 1912, str. 415-436.

<sup>20</sup> Wilkinson 2010, str. 235-250.

Malarni tuberkul je mala izbočina na rubu orbite nekoliko milimetara ispod frontozigomatičnog šava. Gray 1859, str. 45.

<sup>21</sup> Wilkinson, Mautner 2003, str. 1-5.

<sup>22</sup> Bron, Tripathi, Tripathi 1998, str. 571-572.

<sup>23</sup> Stephan, Davidson 2008, str. 612-619.

<sup>24</sup> Valentine, Davis 2015, str. 107.

<sup>25</sup> Rynn, Wilkinson, Peters 2010, str. 20-34.

<sup>26</sup> Robison, Rinchuse, Zullo 1986, str. 499-506.

<sup>27</sup> Gatliff 1984, str. 327-332.

<sup>28</sup> Stephan 2003, str. 48-57.; Wilkinson, Motwani, Chiang 2003, str. 728-32.; Ferrario, Sforza, Poggio, Serrao 1996, str. 86-93., Ferrario, Sforza, Serrao 2000, str. 48-54.

<sup>29</sup> Kaya, Turk, Cankaya, Seyhun, Coşkun 2019, str. 500.

<sup>30</sup> Wilkinson, Motwani, Chiang 2003, str. 728-732.

<sup>23</sup> Stephan, Davidson 2008, pp. 612-619.

<sup>24</sup> Valentine, Davis 2015, p. 107.

<sup>25</sup> Rynn, Wilkinson, Peters 2010, pp. 20-34.

<sup>26</sup> Robison, Rinchuse, Zullo 1986, pp. 499-506.

<sup>27</sup> Gatliff 1984, str. 327-332.

<sup>28</sup> Stephan 2003, pp. 48-57.; Wilkinson, Motwani, Chiang 2003, pp. 728-32.; Ferrario, Sforza, Poggio, Serrao 1996, pp. 86-93.; Ferrario, Sforza, Serrao 2000, pp. 48-54.

<sup>29</sup> Kaya, Turk, Cankaya, Seyhun, Coşkun 2019, p. 500.

<sup>30</sup> Wilkinson, Motwani, Chiang 2003, pp. 728-732.

sve zube za vrijeme života, te su mu usne zbog toga bile tanke, sa slabo naglašenim kupidovim lukom i tankom inferiornom usnom koja prelazi preko superiorne.

#### 4. Rezultat rekonstrukcije lica muškarca

U ovom istraživanju korištena je lubanja muškarca s lokaliteta Rižinice koja je fotografirana i koristila se kao predložak za izradu rekonstrukcije. Nisu bili dostupni podaci o identitetu osobe, nego samo osnovni biološki profil osobe; bilo je poznato da je riječ o odrasloj muškoj osobi, biološke dobi između 45 i 57 godina, bijele rase, europskog podrijetla. Rekonstrukcija lica napravljena je pomoću računalne 2D tehnike facijalne rekonstrukcije.

Morfološkom procjenom kostiju lubanje muške osobe s lokaliteta Rižinice utvrđen je ovalni opći oblik glave s bradom U-oblika. Utvrđeno je da je osoba imala jako naglašeni supraorbitalni luk i srednje visok korijen nosa, što upućuje na ravne obrve koje se lateralno blago spuštaju. Malarni tuberkul ove osobe bio je u ravnini s najdubljom točkom lakrimalne kosti, što znači da je osoba imala potpuno horizontalan očni otvor. Pomoću jednadžbe za procjenu protruzije očnih jabučica utvrdilo se da je očna jabučica postavljena 4 mm ispred ruba orbitale, čime je zaključeno da je muškarac imao protruziju očiju jednaku standardu. Visina nosa čini 1/3 visine lica. Prema morfologiji nosnih kostiju određilo se da je muškarac imao ravan nos s okruglim vrhom i malom vidljivošću nosnica. Nosni greben pomaknut je od središta 2 mm, što znači da je vrh nosa frontalno gledajući pomaknut udesno. Maksilarna kost pokazuje resorpciju alveolarne kosti cijelom dužinom osim na mjestima lijevoga lateralnog sjekutića i oba očnjaka, što upućuje na antemortalni gubitak svih zuba osim prethodno navedenih. Jačina mišićnih hvatišta na mandibularnoj kosti nije se mogla pretpostaviti pa je na rekonstrukciju lica dodana brada. Zbog velikog broja izgubljenih zuba na maksilarnoj kosti može se zaključiti i veliki gubitak zuba na mandibularnoj kosti, zbog čega su napravljene tanke usne koje blago ulaze u usnu šupljinu. Dodane su površinske promjene na licu povezane sa starenjem: epikantički nabor, odnosno nabor superiornog kapka koji prekriva lateralni kut oka, blago prelazeći preko trepavica; bore na čelu i oko očiju, „vrećice“ ispod očiju, blago spuštjeni vrh nosa te naglašeni nazolabijalni nabor. Budući da se u procesu starenja širina usana povećava u slučaju ove osobe

age between 45 and 57 years, white, of European descent. The facial reconstruction was performed using a computer 2D facial reconstruction technique.

The morphological assessment of the bones of the Rižinice male's skull determined an oval general head shape with a U-shaped chin. The person was found to have a quite accentuated supra-orbital ridge and a nasal root of medium height, suggesting straight eyebrows gently arching downward laterally. This person's malar tubercle was flush with the deepest point of the lacrimal bone, meaning that the eye aperture was completely horizontal. Using the equation for estimating eyeball protrusion, it was determined that the eyeball was placed 4 mm in front of the orbital margin, and finally concluded that the male's eye protrusion was in line with the standard. The height of the nose makes up one-third of the height of the face. According to the morphology of the nasal bones, it was determined that the man had had a straight nose with a rounded tip and low visibility of the nostrils. The nasal ridge is off-centre by 2 mm, which means that the tip of the nose is displaced to the right, as viewed from the front. The maxillary bone exhibits the alveolar bone resorption along its entire length except in the regions of the left lateral incisor and both canines, suggesting antemortal loss of all teeth except those mentioned above. The strength of muscle attachments on the mandibular bone could not be estimated, and therefore a chin was added to the facial reconstruction. Due to the large number of lost teeth on the maxillary bone, a heavy loss of teeth on the mandibular bone can also be inferred, because of which thin lips were made, gently entering the oral cavity. Surface facial changes were added, associated with ageing: an epicanthic fold, i.e. the fold of the superior eyelid that covers the lateral corner of the eye, slightly passing over the lashes; wrinkles on the forehead and around the eyes, "bags" under the eyes, a slightly lowered tip of the nose and a pronounced nasolabial fold. As a person ages, the lips widen, and therefore the width of the oral fissure of this person was increased to the vertical plane in the middle of the eye<sup>31</sup>. The skeleton of the male was in generally good condition, without significant pathology, and no visible traces of heavy manual labour. Therefore, it can be concluded that the person had been a member of the upper class, and ac-

<sup>31</sup> Prokopakis *et al.* 2013, p. 19.



Sl. 6. Rekonstruirano lice muškarca s lokaliteta Rižinice (foto: J. Marić)  
*Fig. 6 Reconstructed face of the man from the Rižinice site (photo: J. Marić)*

širina usnog otvora povećana je do okomite ravnine na sredini oka.<sup>31</sup> Kostur muške osobe bio je općeg dobrog stanja, bez značajne patologije, te nisu vidljivi tragovi težeg fizičkog rada. Iz navedenog može se zaključiti da je osoba bila pripadnik višeg staleža pa je u skladu s tim prigodom rekonstrukcije lica dodana minimalna količina promjena povezanih sa starenjem (sl. 6).

ordingly it was decided to minimise the amount of changes in the face associated with ageing (Fig. 6).

## 5. Conclusion

Working in a two-dimensional application makes the task more difficult and increases the probability of error because it is not possible to track changes from multiple views, and therefore a three-dimensional software such as *Freeform Mod-*

<sup>31</sup> Prokopakis *et al.* 2013, str. 19.

## 5. Zaključak

Rad u dvodimenzionalnom programu otežava izvedbu zadatka i povećava vjerojatnost pogreške jer nije moguće iz više kutova sagledati promjene, te bi stoga rad u trodimenzionalnom softverskom programu kao što je *Freeform Modeling Plus* znatno olakšao izvedbu zadatka. Koristeći se Sassounijevom metodom cefalometrične predikcije, bilo je moguće dodati mandibulu druge osobe na lubanju rekonstruirane osobe uz minimalna odstupanja od originala. Važno je napomenuti da se navedena metoda koristi za korekciju čeljusti kako bi se postigle standardne proporcije lica, te ne uvjetuje da je osoba čije se lice rekonstruira imala standardne proporcije. Neke od vrsta malokluzije moguće je uočiti na kostima lubanje čak i kada je mandibula nedostupna, dok druge nije. No za slučajeve kada to nije moguće, promjene u izgledu lica minimalne su i zanemarive. Usprkos nedostacima ove metode rekonstrukcije lica rezultati u forenzičnim istragama drugih istraživača pokazali su se zadovoljavajućima, te dokazuju preciznost metodologije izrade. Dodatno, potrebno je više istraživanja na posteroanteriornim radiografima u svrhu predviđanja kraniofacijalne strukture. Navedeno područje nedovoljno je istraženo te je potrebno objavljivanje više publikacija o istoj temi. Rezultati rekonstrukcija lica zanimljivi su široj javnosti, te je na taj način im moguće prezentirati rezultate arheoloških istraživanja.

*eling Plus* would greatly facilitate the task. Utilising the Sassouni method of cephalometric prediction, it was possible to add another person's mandible to the male's skull with minimal deviations from the original. It is important to note that the above method is used for jaw adjustment to achieve standard facial proportions, and does not require standard proportions of the person whose face is reconstructed. Some types of malocclusion can be seen on the bones of the skull even when the mandible is missing, while others cannot. However, in cases where this is not possible, changes in facial appearance are minimal and negligible. Despite the shortcomings of this method of facial reconstruction, the results in forensic investigations of other researchers have proved to be satisfactory, and substantiate the accuracy of the methodology. Additionally, more research on posteroanterior radiographs is required in order to predict the craniofacial structure. This domain has been insufficiently researched, and it is necessary to publish more works on the topic. The results of facial reconstructions are interesting to the general public. They present a possibility to exhibit the results of archaeological investigations.

(D. G.)

## Literatura/Bibliography

- Bron, Tripathi, Tripathi 1998  
J. Bron, R. C. Tripathi, B. Tripathi B, Wolff's anatomy of the eye and orbit, *American Journal of Ophthalmology* 125, 1998, 571-572
- Fedosyutkin, Nainys 1993  
A. Fedosyutkin, J. V. Nainys, *The relationship of skull morphology to facial features*, New York 1993.
- Ferrario, Sforza, Poggio, Serrao 1996  
V. F. Ferrario, C. Sforza, C. E. Poggio, G. Serrao, Facial three-dimensional morphometry, *Am J Orthod Dentofacial Orthop* 109, 1996, 86-93
- Ferrario, Sforza, Serrao 2000  
Ferrario VF, Sforza C, Serrao G, A three-dimensional quantitative analysis of lips in normal young adults, *Cleft Palate Craniofac J* 37, 2000, 48-54
- Frakfurtska horizontala/ *Frankfort horizontal*  
Frakfurtska horizontala, Struna, Available from: <http://struna.ihjj.hr/naziv/frakfurtska-horizontala/15298/>. [konzultirano/accessed 08/04/2020]
- Gatliff 1984  
Gatliff BP, Facial sculpture on the skull for identification, *Am J Forensic Med Pathol* 5, 1984, 327-32
- Gonzalez-Ulloa, Flores 1965  
M. Gonzalez-Ulloa, E. S. Flores, Senility of the face-basic study to understand its causes and effects, *Plastic and Reconstructive Surgery* 36, 1965, 239-46.
- Gray 1859  
Gray H, *Anatomy, descriptive and surgical*, Blanchard and Lea, 1859.
- Hines et al. 2010  
J. W. Hines, C. Ramsey, L. Meadows Jantz, R. L. Jantz, J. Hughes, B. Wood, *Improving Facial Reproduction Using Empirical Modeling*, Final Technical Report, The University of Tennessee: Knoxville 2010. Str. 9 <https://www.ncjrs.gov/pdffiles1/nij/grants/231669.pdf> [konzultirano/ accessed 05. 04. 2020]
- Hou, Wang, Li 2007  
T. Hou, J. Wang, Y. Li, ADME Evaluation in Drug Discovery. 8. The Prediction of Human Intestinal Absorption by a Support Vector Machine, *Journal of Chemical Information and Modeling* 47, 2007, 2408-2415
- Kaya, Turk, Cankaya, Seyhun, Coşkun 2019  
K. S. Kaya, B. Turk, M. Cankaya, N. Seyhun, B. U. Coşkun, Assessment of facial analysis measurements by golden proportion, *Brazilian Journal of Otorhinolaryngology* 85, 2019, 494-501
- Khalil, Kubota 1996  
A. K. Khalil, M. Kubota, H. Inomata, *Ultrastructural Age-Related Changes*, *Arch Ophthalmol.* 114, 1996, 721-725
- Krogman, Iscan 1986  
W. M. Krogman, M. Y. Iscan, *Radiographic analysis: The human skeleton in forensic medicine*, Springfield 1986.
- Mahoney, Milani, Billinger, Lywood, Gruppioni 2011  
G. Mahoney, C. Milani, M. Billinger, V. Lywood, G. Gruppioni, Using a Haptic device and virtual sculpting software for predicting a missing mandible: The case of Angelo Poliziano, *Journal of Biological Research* 84, 2011, 368-370
- Morier 1993  
Morier R, Forensic Facial Reconstruction, *Royal Canadian Mounted Police Gazette* 55, 1993, 1-4
- Neave 1998  
Neave R. *Craniofacial Identification in Forensic Medicine: Age changes to the face in adulthood*. New York 1998.
- Polić, Petaros, Cuculić, Bosnar 2012  
L. Polić, A. Petaros, D. Cuculić, A. Bosnar. Forenzička facijalna rekonstrukcija – između umjetnosti i znanosti, *Medicina Fluminensis: Medicina Fluminensis* 48, 2012, 30-40
- Prokopakis et al. 2013  
E. P. Prokopakis, I. M. Vlastos, V. A. Picavet, G. Nolst Trenite, R. Thomas, C. Cingi, P. W. Hellings, The golden ratio in facial symmetry, *Rhinology* 51, 2013, 18-21
- Ramesh, Nagarajappa, Sreedhar, Sumalatha 2016  
G. Ramesh, R. Nagarajappa, G. Sreedhar, M. N. Sumalatha, Facial Soft Tissue Thickness in Forensic Facial Reconstruction: Is it enough if Norms Set?, *Journal of Forensic Research* 6, 2016, 1-4
- Robison, Rinchuse, Zullo 1986  
J. M. Robison, D. J. Rinchuse, T. G. Zullo, Relationship of skeletal pattern and nasal form, *American Journal of Orthodontics* 89, 1986, 499-506

Rynn, Wilkinson, Peters 2010

A. Rynn, C. M. Wilkinson, H. L. Peters, Prediction of nasal morphology from the skull, *Forensic Science, Medicine, and Pathology* 6, 2010, 20-34.

Sanggarnjanavanich *et. al.* 2014

S. Sanggarnjanavanich, T. Sekiya, Y. Nomura, T. Nakayama, N. Hanada, Y. Nakamura, Cranial-base morphology in adults with skeletal Class III malocclusion, *Am J Orthod Dentofacial Orthoped* 146, 2014, 82-91.

Sassouni 1957

V. Sassouni, Palatoprint, physioprint, and roentgenographic cephalometry, as new methods in human identification, *Journal of forensic science* 2, 1957, 428-442

Stephan 2003

B. N. Stephan, Facial approximation: An evaluation of mouth width determination, *Am J Phys Anthropol* 121, 2003, 48-57.

Stephan 2003

C. N. Stephan, P. L. Davidson, The placement of the human eyeball and canthi in craniofacial identification, *Journal of forensic sciences* 53, 2008, 612-9.

Takema, Yorimoto, Kawai, Imokawa 1994

Y. Takema, Y. Yorimoto, M. Kawai, G. Imokawa. Age-related changes in the elastic properties and thickness of human facial skin, *British Journal of Dermatology* 131, 1994, 641-8.

Taylor 2000

K. T. Taylor, *Forensic art and illustration*, CRC Press, 2000.

Ubelaker, O' Donnell 1992

H. Ubelaker, G. O' Donnell, Computer-assisted facial reproduction, *Journal of Forensic Science* 37, 1992, 155-62.

Valentine, Davis 2015

T. Valentine, J. P. Davis, *Forensic Facial Identification: Theory and Practice of Identification from Eyewitnesses, Composites and CCTV*, Chichester 2015.

Viloriaa, Mendinuetab, Borreroc, Pinedad 2020

A. Viloriaa, M. Mendinuetab, L. A. Borreroc, O. B. Pinedad, Prediction of Mandibular Morphology through Artificial Neural Networks, *Procedia Computer Science* 170, 2020, 370-375

Wilder 1912

H. H. Wilder, The Physiognomy of the Indians of Southern New, *American Anthropologist* 14, 1912, 415-36.

Wilkinson 2010

C. Wilkinson, Facial reconstruction—art or artistic anatomy?, *Journal of Anatomy* 216, 2010, 235-50.

Wilkinson, Mautner 2003

C. M. Wilkinson, S. A. Mautner, Measurement of eyeball protrusion and its application in facial reconstruction, *Journal of Forensic Science* 48, 2003, 1-5.

Wilkinson, Motwani, Chiang 2003

C. M. Wilkinson, M. Motwani, E. Chiang, The relationship between the soft tissues and the skeletal detail of the mouth, *Journal of forensic sciences* 48, 2003, 728-32.

Yadav, Panat, Aggarwal 2010

N. Yadav, R. Panat, A. Aggarwal, CT scans—a compelling tool in forensic facial reconstruction, *J Dent Sci Oral Rehabil* 1, 2010, 39-42