

# Meralgia Paresthetica - Lateral Femoral Cutaneous Nerve Entrapment

Dora Madiraca Glasović<sup>1</sup>, Nika Šlaus<sup>2</sup>, Mirna Šitum<sup>1</sup>, Marko Pećina<sup>2</sup>

<sup>1</sup> Department of Dermatology and Venereology, Sestre milosrdnice University Hospital Center, Zagreb, Croatia

<sup>2</sup> School of Medicine University of Zagreb, Zagreb, Croatia

OPEN ACCESS

## Correspondence:

Dora Madiraca Glasović  
dora.madiraca85@gmail.com

This article was submitted to RAD  
CASA - Medical Sciences  
as the original article

## Conflict of Interest Statement:

The authors declare that the research was conducted in the absence of any commercial or financial relationships that could be construed as a potential conflict of interest.

**Received:** 15 May 2021

**Accepted:** 24 May 2021

**Published:** 15 June 2021

## Citation:

Madiraca Glasović D, Šlaus N, Šitum M, Pećina M. Meralgia paresthetica - lateral femoral cutaneous nerve entrapment  
RAD CASA - Medical Sciences.  
547=54-55 (2021): 56-63  
DOI: <https://dx.doi.org/10.21857/mzvktq6v9>

Copyright (C) 2021 Madiraca Glasović D, Šlaus N, Šitum M, Pećina M. This is an open-access article distributed under the terms of the Creative Commons Attribution License (CC BY). The use, distribution or reproduction in other forums is permitted, provided the original author(s) and the copyright owner(s) are credited and that the original publication in this journal is cited, in accordance with accepted academic practice. No use, distribution or reproduction is permitted which does not comply with these terms.

## ABSTRACT:

Meralgia paresthetica (MP) is a neuropathy that involves pain and sensory symptoms in the distribution of the lateral femoral cutaneous nerve and is mostly caused by entrapment of the lateral femoral cutaneous nerve. The etiology of MP includes pregnancy, trauma, tumors, surgical complications and other conditions with increased intraabdominal pressure. The diagnosis of MP is usually based primarily upon clinical signs and symptoms, but other diagnostic tools can be used in patients with atypical clinical presentations. Treatment focuses on relieving symptoms caused by nerve compression and usually involves conservative approach. Surgical treatment may be considered if conservative methods fail.

**KEYWORDS:** Meralgia paresthetica; lateral femoral cutaneous nerve entrapment; etiology; diagnosis; treatment; hip pain

## SAŽETAK:

MERALGIA PARESTHETICA – KANALIKULARNI SINDROM NERVUS CUTANEUS FEMORIS LATERALIS

Meralgia paresthetica je neuropatija koja nastaje kompresijom ili traumom lateralnog femoralnog kožnog živca. Simptomi karakteristični za ovo stanje su isključivo osjetni i u većini slučajeva unilaterálni. MP uzrokuje žareću bol u vanjskom dijelu bedra, uz paresteziju i disesteziju. Etiološki čimbenici povezani sa nastankom MP jesu stanja koja uzrokuju povećanje intraabdominalnog tlaka poput trudnoće i pretilosti, tumora, trauma i komplikacije kirurških zahvata. Dijagnoza se u većini slučajeva postavlja na temelju detaljne anamneze i karakteristične kliničke slike, no u nejasnim slučajevima potrebne su i druge dijagnostičke metode. Liječenje se temelji na uklanjanju predisponirajućih čimbenika i konzervativnim mjerama. U rezistentnim slučajevima koji ne odgovaraju na konzervativnu terapiju potrebno je kirurško liječenje.

**KLJUČNE RIJEČI:** Meralgia paresthetica; lateralni femoralni kožni živac; pritisak ili istezanje živca; etiologija; dijagnoza; liječenje;

**INTRODUCTION**

Meralgia paraesthetica (MP) is a neuropathy due to compression or entrapment or stretching of the lateral femoral cutaneous nerve (LFCN). The characteristic symptoms consist of paresthesia, burning pain, and dysesthesia in the anterolateral side of the thigh. in the LFCN distribution area. Also in patients with MP there is a reduction or loss of sensation to touch, pain and heat, and very rarely hyperesthesia. The symptoms are more common in males than in females, are similar on the right and left thigh, and are rarely bilateral.

The incidence rate of MP is 4.3 per 10,000 person a year and it usually affects people ages 30 to 40 years. MP is more often present in patients suffering from carpal tunnel syndrome and is related to pregnancy <sup>1</sup>. Even though meralgia paraesthetica (MP) is benign, it is a highly unpleasant sense in the lateral side of the thigh. It is also differentially important when considering pathological conditions in the inguinal region, the region of the greater trochanter, the hip and the lower part of the abdomen and spine. Meralgia paresthetica was first described by Bernhardt in 1895. <sup>2</sup> and in the same year Roth <sup>3,4</sup> applied the name of this entity known also as Bernhardt's syndrome and Roth's meralgy, but Heger 1885. first reported its symptoms <sup>5</sup>. Another interesting fact is that in the year 1895. Sigmund Freud described patients with the symptoms of meralgia paresthetica some of whom exhibited bilateral symptomatology <sup>6</sup>. Freud, himself had symptoms of Meralgia paraesthetica (MP). Freud did not associate these symptoms of MP in described patients with sexual pathology.

The term meralgia paresthetica is derived from the Greek words "meros" and „algos“ meaning meros -thigh, and "algos"-pain. Mumenthaler and Schliack <sup>7</sup> described the same entity as „syndrome of the inguinal ligament“.




Figure 1. The lateral cutaneous femoral nerve originates from the L2 and L3 nerve posterior roots

**ETIOLOGY**

The etiology of the meralgia paresthetica can be discussed under two headings: predisposing lesions and precipitating causes. Predisposing lesions refer to the fact that the nerve is vulnerable to compression or stretching because of its anatomic-topographical position from its origin under the psoas muscle until it exits from the pelvis under or through the inguinal ligament and the fascia lata. The lateral femoral cutaneous nerve (LFCN), a solely sensory nerve, originates from the L2 and L3 nerve posterior roots (Figure 1.), passes under the psoas muscle, and emerges laterally to cross the ilium buried in a fibrous tunnel formed by a doubling in the fascia of the iliacus muscle. In this fibrous tunnel the nerve can be compressed like the others peripheral nerves in the osteofibrous or myofibrous or only fibrous tunnel of the human body described by Pećina M. et al. <sup>8</sup> as „Peripheral nerve compression syndromes or tunnels syndromes“. The lateral femoral cutaneous nerve courses toward the medial aspect of the anterior superior iliac spine and bends below or through the inguinal ligament at an angle of 70 to 90 degrees. This sharp turn of the nerve can also cause symptoms of meralgia paresthetica. Just before reaching the anterior superior iliac spine the nerve emerges to lie superficial to the iliac fascia. The nerve passes into the thigh just medial to

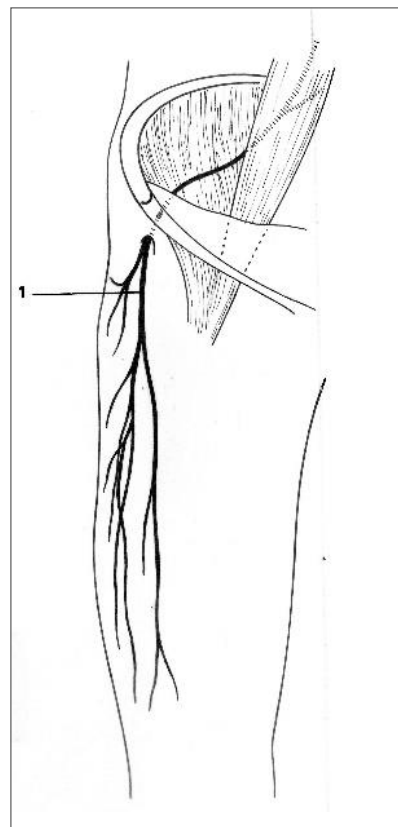


Figure 2. The lateral femoral cutaneous nerve (1) passes into the thigh just medial to the anterior superior iliac spine (ref.8).

Table 1. Proposed precipitating causes in etiologies of Meralgia Paresthetica

ETIOLOGY	AUTHOR(S)
Direct injury, stretching, or scar formation	Peterson; 1952 <sup>13</sup> ; Kopell and Thompson 1963 <sup>12</sup> ; Komar 1977 <sup>14</sup> ; Mandić, 1982 <sup>15</sup> ; Pećina et al., 2001 <sup>8</sup>
Pregnancy	Peterson, 1952 <sup>13</sup> ; Rhodes, 1957 <sup>16</sup> ; Pearson, 1957 <sup>17</sup> ; Gooding, 2020 <sup>18</sup>
Anatomic variation and anomalies	Ghent, 1961 <sup>11</sup> ; Kokubo et al., 2018 <sup>19</sup>
Retroperitoneal hematoma or tumor or metastasis	Flowers, 1968 <sup>20</sup> ; Tharion and Bhattacharji, 1997 <sup>21</sup>
Abdominal aortic aneurysm	Carayon and Gruet, 1969 <sup>22</sup>
Seat belt trauma	Beresford, 1971 <sup>23</sup> ; Mandic, 1982 <sup>15</sup>
Sports – gymnasts, baseball pitcher	MacGrego and Moncur 1977 <sup>24</sup> ; Otoshi et al. 2008 <sup>25</sup> .
Iliopsoas muscle abscess	Komar, 1977 <sup>14</sup>
Abdominal/inguinal surgery	Moscona and Hirshowitz, 1980 <sup>26</sup> ; Yamout et al., 1994 <sup>27</sup> ; Polidori et al., 2003 <sup>28</sup>
Iliac graft harvest	Massey, 1980 <sup>29</sup> ; Mandić 1982 <sup>15</sup> ; Nahabedian and Dellon 1995 <sup>30</sup>
Tight girdle/clothinging	Bora and Ostermann, 1982 <sup>31</sup>
Obesity	Mandic, 1982 <sup>15</sup> ; Parisi et al., 2011 <sup>33</sup>
Weight loss	Baldini et al., 1982 <sup>34</sup>
Laparoscopic inguinal hernia repair	Broin et al., 1995 <sup>35</sup>
Limb length discrepancy	Goel, 1999 <sup>36</sup>
Hemangiomas in the pelvic region	Yamamoto et al., 2001 <sup>37</sup>
Gynecologic and obstetric surgery	Peters et al., 2006 <sup>38</sup>
Hip-huggers	Park et al., 2007 <sup>39</sup>
Body armor wear	Fargo and Konitzer; 2007 <sup>40</sup>
Lipoma	Rau et al., 2010 <sup>41</sup>
Shoulder surgery in the beach chair position	Satin et al., 2014 <sup>42</sup>
Entrapment at the fascia lata	Omichi et al., 2015 <sup>43</sup>
Compression by “smart” devices	Karwa et al., 2016 <sup>44</sup>
Femoral cannulation (catetherization)	Oh SI et al., 2017 <sup>45</sup>
Laparoscopic ventral rectopexy	Jones et al., 2017 <sup>46</sup>
Anterior total hip arthroplasty	Patton et al., 2018 <sup>47</sup>
Hematoma after sartorius muscle tear	Lee and Stubbs, 2018 <sup>48</sup>
Pelvic osteochondroma	Magalhães et al., 2019 <sup>49</sup>
Inguinal lymphadenopathy and lymphadenomegaly	Gencer Atalay et al., 2020 <sup>50</sup> ; Palmar et al., 2020 <sup>51</sup>
Lipomatosis	Ganhao et al., 2020 <sup>52</sup>
Prone position in spinal surgery	Ercan et al., 2020 <sup>53</sup>
Schwannoma of the LFCN	Markis and Markis, 2020 <sup>54</sup>
Prone positioning to treat covid-19	Bellinghausen et al., 2020 <sup>55</sup> ; Marinelli et al., 2020 <sup>56</sup>

the anterior superior iliac spine but posterior to the lateral end of the inguinal ligament and anterior to the iliacus muscle. According to Stevens<sup>9</sup> and Genth<sup>10,11</sup> it is possible that the nerve passes through the splint inguinal ligament and this is also one of the possible etiological factor in the origin of meralgia paresthetica. Normally the nerve can be found approximately 1.5 to 2 cm distal to the inguinal ligament in a groove between the sartorius and iliacus muscles and sometimes exists the anatomical variation that the nerve passes through the sartorius muscle<sup>11</sup> what is also one of the possible causes of the origin of meralgia paresthetica. There is anatomical variation when the nerve courses laterally and behind the anterior superior iliac spine (Gent) and is exposed to damage more than in normal anatomical position<sup>11</sup>. Approximately 10 cm distal to the inguinal ligament, the nerve pierces the fascia lata and divides into its thick anterior and thin posterior branches (Figure 2). This point, where the nerve pierces the fascia lata, is also the location of possible compression or stretching of the nerve with consecutive origin of clinical symptoms characteristic for meralgia paresthetica. The anterior branch of LFCN pierces the fascia lata to innervate the skin of the lateral thigh to a point just proximal to the knee. The distribution of the innervation of this anterior branch of the lateral femoral cutaneous nerve is the region of clinical signs of paresthesia such as burning, etc. The posterior branch of LFCN runs deep under the tensor fascia lata muscle to innervate the skin in the region of the trochanter maior and gluteal region.

According to Kopel and Thompson<sup>12</sup> the symptoms of meralgia paresthetica can exist without the known precipitating causes, this can occur solely because of acute or chronic stretching of the nerve. The lateral femoral cutaneous nerve is attached at both its origin and at the fascial tunnels. The nerve can be stretched because of leg length changes, scoliosis, trunk or leg hyperextension. Increased tension of the abdominal musculature and fascia lata due to long period of standing can cause also stretching of the nerve and provoke the symptoms of meralgia paresthetica. Precipitating causes in the etiology of meralgia paresthetica refer to the fact that the nerve can be damaged by the multiple etiologies including trauma, tumors, surgical complications, etc., as described by many authors and shown in Table 1.

### CLINICAL PRESENTATION

Patients with MP typically present with pain in the distribution of the lateral femoral cutaneous nerve<sup>57</sup>. (Figure 3). This pain may be characterized as burning, stinging, coldness, or lightning pains, which may progress to hypo- or anesthesia and skin area can be hair loss (Figure 4). Pain is often subacute<sup>58</sup>. Dysesthesia can be aggravated by even the touch of clothing, or leg extension during rest and sleeping<sup>57</sup>.

Patients often avoid placing objects over the affected thigh. Classically, these symptoms are produced in the erect or the supine position and are relieved by flexing the thigh<sup>59</sup>. Clinical examination shows a positive inverted Lasegue's sign that is performed

by flexing the knee and extending the hip with the patient in lateral position (similar to Menell's procedure). Local pressure over the inguinal ligament especially close to the anterior superior iliac spine may produce pain or local irritation in the nerve distribution<sup>60</sup>. Sensory changes are usually unilateral and there are no symptoms of motor neuropathy<sup>61</sup>. Many patients present with severe and bizarre types of pain over the lateral aspect of the thigh which may be so severe that the victims are incapacitated. The patient may walk with a limp that closely mimics that of actual hip joint disease<sup>62</sup>.

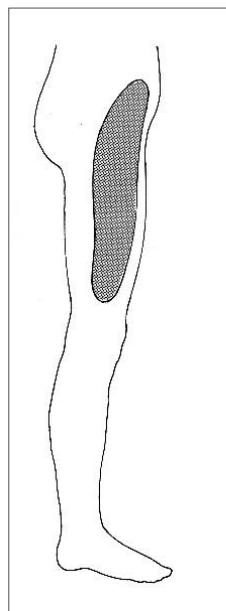


Figure 3. The lateral skin of the thigh typically develops paresthesia, burning pain, and disturbances in sensation (ref. 8)

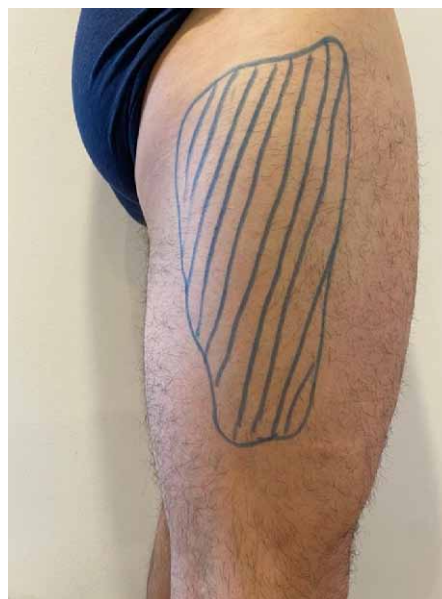

Figure 4. Area of hair loss on the thigh of 35-year-old patient with Meralgia Paresthetica

## DIAGNOSIS

The diagnosis of MP is usually based primarily upon reported clinical signs and symptoms and specific area affected<sup>63</sup>. Electrodiagnostic testing can be used in patients with atypical clinical presentations. Electromyographic studies show nerve compression on affected side using patients' unaffected leg as control<sup>64</sup>. Lo and Pavanni demonstrated on 12 cases the usefulness of antidromic sensory nerve conduction in the diagnosis and prognostic aspects of meralgia paresthetica.<sup>65</sup> Seror compared sensory nerve conduction with somatosensory evoked potential and demonstrated that the sensory nerve conduction is the more reliable method for electrodiagnosis of MP. In daily clinical practice, electrodiagnostic studies are not commonly performed due to their variable results<sup>66</sup>. In the recent literature, ultrasound imaging has been proposed as useful modality as it confirms nerve entrapment with sonographic findings of swollen and hypoechoic lateral femoral cutaneous nerve<sup>67</sup>. Magnetic resonance imaging (MRI) or computed tomography (CT) are useful in the diagnosis of eventual causes of the syndrome because of the compression of the nerve in the abdomen and pelvis<sup>68,69</sup>.

The differential diagnosis includes femoral neuropathy, lumbosacral plexus pathology, extra-spinal radiculopathies L2 and L3 nerve roots, pelvic tumors or metastasis that compress the nerve, chronic appendicitis<sup>70</sup>.

## TREATMENT

The type of treatment in the patient with meralgia paresthetica can be decided almost on the patient's history alone and it can be conservative or operative. More than 85% percent of patients respond to conservative treatment, but recurrence is common<sup>71</sup>. Conservative treatment is known as the local infiltration of the nerve with an anesthetic agent on one or two occasions<sup>72</sup>. Although the injection of the LFCN has been classically described using anatomic landmarks, owing to the anatomic variability of the nerve, failure rates have been reported as high as 60%<sup>73</sup>. On the other hand, similar to any other US guided injections, real-time imaging with US definitely avoids such an untoward eventuality<sup>74,75</sup>. According to Elavarasi A. et al. triamcinolone acetonide injected locally seems to be an effective and safe treatment for refractory MP<sup>76</sup>. Local application of anesthetics and corticosteroid may bring immediate relief of the symptoms.<sup>77</sup> At the same time this injections serves in the differential diagnosis.

Conservative therapy includes iontophoresis and use of the anesthetic ointments on the area of the affected skin. Capsaicin causes *selective excitation* of C-fibre polymodal *nociceptor* afferents and has also been successfully used to treat skin hypersensitivity and itch in MP<sup>78</sup>.

Many authors recommended weight loss in obese patients, optimal diabetic control, removal of compressive garments, and physical and electric therapy like transcutaneous electrical nerve stimulations (TENS), nonsteroidal anti-inflammatory drugs, tricyclic antidepressants, and anticonvulsants. Palmithoylethanolamide (PEA) is commonly used in the treatment of chronic pelvic pain and compressive neuropathies. Calabro RS et al. describe an otherwise healthy 28-year-old patient affected by MP who was successfully treated with PEA (1200mg/day)<sup>79</sup>. Peripheral nerve stimulation (PNS) has been considered a new treatment option for meralgia paresthetica. Newer PNS technology targets peripheral nerves directly yet in a minimally invasive manner<sup>80</sup>. Some authors report the use of lateral femoral cutaneous nerve radiofrequency ablation or extended duration (8 minutes) pulsed radiofrequency of the LFCN for long term control of refractory meralgia paresthetica<sup>81,82,83</sup>.

If conservative therapy fails neurolysis or nerve resection is indicated because the patients prefer hypoesthesia to burning pain. The most common operative treatment is nerve decompression with or without neurolysis<sup>84,85,86,87</sup>. Ahmed A et al. recommended alcohol neurolysis<sup>88</sup>. Son et al. on the experience of 11 patients who had decompression and neurolysis concluded: "that neurolysis of the LFCN can provide adequate pain relief with minimal complications for medically refractory MP. To achieve a good outcome in neurolysis for MP, an accurate diagnosis with careful examination and repeated blocks of the LFCN, along with electrodiagnosis seems to be essential. Possible variation in the course of the LFCN and thorough decompression along the course of the LFCN should be kept in mind in planning decompression surgery for MP<sup>89</sup>. Transposition of the nerve is described by AJ Hanna in two publications<sup>90,91</sup>. Surgical treatment involves transection or decompression of the lateral cutaneous femoral nerve<sup>92,93</sup>.

There is no clear consensus on the superiority of one technique over the other. Payne R et al. performed a systematic review of the literature to answer this question. In conclusion after reviewing the data, there was insufficient evidence to recommend one method of treatment over the other<sup>94</sup>. Many treatments for MP are available, but they are supported only by moderate to low-quality evidence. Treatments range from conservative to interventions using nerve blocks and surgery. The benefit of one treatment regime over another is therefore not possible to quantify. Without a clear superiority of any treatment, Sanjaya A. concludes that treatment should be done in a stepwise fashion, from the noninvasive to the more invasive treatment if symptoms persist<sup>95</sup>.

There is no clear consensus on the superiority of one technique over the other. Payne R et al. performed a systematic review of the literature to answer this question. In conclusion after reviewing the data, there was insufficient evidence to recommend one method of treatment over the other<sup>94</sup>.

Many treatments for MP are available, but they are supported only by moderate to low-quality evidence. Treatments range from conservative to interventions using nerve blocks and surgery. The benefit of one treatment regime over another is therefore not possible to quantify. Without a clear superiority of any treatment, Sanjaya A. concludes that treatment should be done in a stepwise fashion, from the noninvasive to the more invasive treatment if symptoms persist<sup>95</sup>.

## CONCLUSION

Meralgia paresthetica in most cases is self-limited, benign disease but it can decrease the quality of life if not diagnosed and treated appropriately. The diagnosis is based primarily upon clinical history and detailed physical exam, but other diagnostic procedures can assist in the differential diagnosis. The condition in most cases can be treated with conservative therapies and measures, neurosurgical management is performed only in patients with severe symptoms.

## REFERENCES:

1. van Slobbe AM, Bohnen AM, Bernsen RM, Koes BW, Bierma-Zeinstra SM. Incidence rates and determinants in meralgia paresthetica in general practice. *J Neurol* 2004; 251:294-297.
2. Bernhardt M. [Ueber isolirt im Gebiete des N. cutaneus femoris externus vorkommende Parästhesien] *Neurol Centralbl.* 1895;14:242-244.
3. Roth VK. Meralgia paresthetica. *Med Obozr.* 1895;43:678.
4. Roth VK. Meralgia paresthetica, Karger, Berlin, 1895.
5. Heger W. Neuralgia femoris: Resection des Nervus cutaneus femoris anterior externus. *Heilung Deutsche med Wochenschr* 1885;11 : 218.
6. Freud S. Über die Bernhardt'sche Sensibilitätsstörung am Oberschenkel. *Neurologisches Centralblatt (Leipzig)* 1895; 14:491-492.
7. Mumenthaler M, Schiack H. *Laesiones Peripherer Nerven*, G.Thieme, Stuttgart, 1965.
8. Pećina MM, Krmpotić-Nemanić J, Markiewitz AD. *Tunnel Syndromes. Peripheral Nerve Compression Syndromes.* 3rd ed., CRC Press, Boca Raton-London-New York-Washington, D.C. 2001.
9. Stevens H. Meralgia paresthetica. *AMA Arch Neurol Psychiatry* 1957; 77(6):557-74.
10. Ghent WR. Meralgia paraesthetica. *Can Med Assoc J* 1959; 81(8):631-3.
11. Ghent WR. Further studies on meralgia paresthetica. *Can Med Assoc J* 1961; 85(16):871-5.
12. Kopell HP, Thompson WAL. *Peripheral Entrapment Neuropathies*, Williams & Wilkins, Baltimore, 1963.
13. Peterson PH. Meralgia paresthetica related to pregnancy. *Am J Obstet Gynecol* 1952; 64(3):690-1.
14. Komar J. *Alagut-Szindromak.* Medicina Konyvkiado, Budapest, 1977.
15. Mandić V. Meralgia paresthetica as differential diagnostic problem. *Med Jad* 14 (2-4) : 316 – 320, 1982. (in Croatian)
16. Rhodes P. Meralgia paraesthetica in pregnancy. *Lancet* 1957;273(7000):831.
17. Pearson MGJ. Meralgia paraesthetica, with reference to its occurrence in pregnancy. *Obstet Gynaecol Br Emp.* 1957; 64(3):427-30.
18. Gooding MS, Evangelista V, Pereira L. Carpal Tunnel Syndrome and Meralgia Paresthetica in Pregnancy. *Obstet Gynecol Surv.* 2020; 75(2):121-126.
19. Kokubo R, Kim K, Morimoto D, Isu T, Iwamoto N, Kitamura T, Morita A. Anatomic Variation in Patient with Lateral Femoral Cutaneous Nerve Entrapment Neuropathy. *World Neurosurg.* 2018; 115:274-276.
20. Flowers RS. Meralgia paresthetica. A clue to retroperitoneal malignant tumor. *Am J Surg* 1968; 116(1):89-92.
21. Tharion G, Bhattacharij S. Malignant secondary deposit in the iliac crest masquerading as meralgia paresthetica *Arch Phys Med Rehabil* 1997; 78(9):1010-1.
22. Carayon A, Gruet M. Paresthetic meralgia *Bull Soc Med Afr Noire* 1969;14(1):37-41. [Article in French]
23. Beresford HR. Meralgia paresthetica after seat-belt trauma. *J Trauma* 1971; 11(7):629-30.
24. MacGregor J, Moncur JA. Meralgia paraesthetica--a sports lesion in girl gymnasts *Br J Sports Med* 1977; 11(1):16-9.
25. Otoshi K, Itoh Y, Tsujino A, Kikuchi S. Case report: meralgia paresthetica in a baseball pitcher *Clin Orthop Relat Res* 2008; 466(9):2268-70.
26. Moscona AR, Hirshowitz B. Meralgia paresthetica as a complication of the groin flap. *Ann Plast Surg* 1980; 4(2):161-3.
27. Yamout B, Tayyim A, Farhat W. Meralgia paresthetica as a complication of laparoscopic cholecystectomy *Clin Neurol Neurosurg* 1994;96(2):143-4.
28. Polidori L, Magarelli M, Tramutoli R. Meralgia paresthetica as a complication of laparoscopic appendectomy. *Surg Endosc.* 2003; 17(5):832.
29. Massey EW. Meralgia paresthetica secondary to trauma of bone graft. *J Trauma* 1980; 20(4):342-3.
30. Nahabedian MY, Dellon AL. Meralgia paresthetica: etiology, diagnosis, and outcome of surgical decompression. *Ann Plast Surg* 1995; 35(6):590-4.
31. Bora Jr FW, Osterman AL. Compression neuropathy *Clin Orthop Relat Res* 1982; (163):20-32.
32. Pećina M, Pećina HI, Borić I. *Peripheral nerve compression syndromes in sportsmen.* Medicinska naklada, Zagreb, 2019. (in Croatian)
33. Parisi TJ, Jay Mandrekar J, James P, Dyck B, Klein ChJ. Meralgia paresthetica: relation to obesity, advanced age, and diabetes mellitus. *Neurology.* 2011; 77(16):1538-42.
34. Baldini M, Raimondi PL, Princi L. Meralgia paraesthetica following weight loss. Case report. *Neurosurg Rev.* 1982;5(2):45-7.
35. Broin EO, Horner C, Mealy K, Kerin MJ, Gillen P, O'Brien M, Tanner WA. Meralgia paraesthetica following laparoscopic inguinal hernia repair. An anatomical analysis. *Surg Endosc.* 1995; 9(1):76-8.
36. Goel A. Meralgia paresthetica secondary to limb length discrepancy: case report *Arch Phys Med Rehabil* 1999; 80(3):348-9.
37. Yamamoto T, Kurosaka M, Marui T, Mizuno K. Hemangiomas presenting as meralgia paresthetica. *J Pediatr Surg* 2001;36(3):518-20.
38. Peters G, Larner AJ. Meralgia paresthetica following gynecologic and obstetric surgery. *Int J Gynaecol Obstet.* 2006; 95(1):42-3.
39. Park JW, Kim DH, Hwang M, Bun HR. Meralgia paresthetica caused by hip-huggers in a patient with aberrant course

- of the lateral femoral cutaneous nerve. *Muscle Nerve*. 2007; 35(5):678-80.
40. Fargo MV, Konitzer LN. Meralgia paresthetica due to body armor wear in U.S. soldiers serving in Iraq: a case report and review of the literature *Mil Med* 2007;172(6):663-5.
  41. Rau CS, Hsieh CH, Liu YW, Wang LY, Cheng MH. Meralgia paresthetica secondary to lipoma. *J Neurosurg Spine*. 2010; 12(1):103-5.
  42. Satin AM, DePalma AA, Cuellar J, Gruson KI. Lateral femoral cutaneous nerve palsy following shoulder surgery in the beach chair position: a report of 4 cases. *Am J Orthop (Belle Mead NJ)* 2014 Sep;43(9):E206-9.
  43. Omichi Y, Tonogai I, Kaji S, Sangawa T, Sairyo K. Meralgia paresthetica caused by entrapment of the lateral femoral subcutaneous nerve at the fascia lata of the thigh: a case report and literature review *J Med Invest* 2015;62(3-4):248-50.
  44. Karwa KA, Patel D, Tavee JO. Smart device neuropathy. *J Neurol Sci*. 2016; 370:132-133.
  45. Oh SI, Kim EG, Kim SJ. An Unusual Case of Bilateral Meralgia Paresthetica Following Femoral Cannulation. *Neurointervention*. 2017; 12(2):122-124.
  46. Jones CD, Guiot L, Portelli M, Bullen T, Skaife P. Two Interesting Cases of Meralgia Paraesthetica. *Pain Physician*. 2017; 20(6):E987-E989.
  47. Patton RS, Runner RP, Lyons RJ, Bradbury TL. Clinical Outcomes of Patients With Lateral Femoral Cutaneous Nerve Injury After Direct Anterior Total Hip Arthroplasty. *J Arthroplasty*. 2018; 33(9):2919-2926.e1.
  48. Lee B, Stubbs E. Sartorius muscle tear presenting as acute meralgia paresthetica. *Clin Imaging*. 2018; 51:209-212.
  49. Magalhães LVB, Massardi FR, Pereira SAC. Pelvic osteochondroma causing meralgia paresthetica. *Neurol India*. 2019; 67(3):928-929.
  50. Gencer Atalay K, Giray E, Yolcu G, Yağcı İ. Turk J Meralgia paresthetica caused by inguinal lymphadenopathy related to tinea pedis infection: A case report. *Phys Med Rehabil*. 2020; 66(4):473-475.
  51. Palamar D, Misirlioglu TO, Arslan H, Akgung K. Adding an Ultrasound Scan Before the Injection Reveals a Rare Cause of Meralgia Paresthetica: Inguinal Lymphadenomegaly. *Am J Phys Med Rehabil*. 2020; 99(8):e93.
  52. Ganhão S, Uson J.J Meralgia Paresthetica Secondary to Underlying Lipomatosis: An Unusual Case. *Clin Rheumatol*. 2020.
  53. Ercan S, Ataizi ZS, Ertilav K. The Correlation of Meralgia Paresthetica and Spinal Surgery in Prone Position. *Turk Neurosurg*. 2020; 30(1):89-93.
  54. Makris AP, Makris D. Schwannoma of the Lateral Femoral Cutaneous Nerve, an Unusual Cause of Meralgia Paresthetica: A Case Report. *J Orthop Case Rep*. 2020 Nov;10(8):80-83.
  55. Bellinghausen AL, LaBuzetta JN, Chu F, Novelli F, Rodelo AR, Owens RL. Lessons from an ICU recovery clinic: two cases of meralgia paresthetica after prone positioning to treat COVID-19-associated ARDS and modification of unit practices. *Crit Care*. 2020; 24(1):580.
  56. Marinelli L, Mori L, Avanti C, Cotellessa F, Fabbri S, Schenone C, Trompetto C. Meralgia paresthetica after Prone Position Ventilation in a Patient with COVID-19. *Eur J Case Rep Intern Med*. 2020; 7(12) : 002039.
  57. Ivins GK. Meralgia paresthetica, the elusive diagnosis: clinical experience with 14 adult patients. *Ann Surg*. 2000 Aug; 232(2):281-6.
  58. Grossman MG, Ducey SA, Nadler SS, Levy AS. Meralgia paresthetica: diagnosis and treatment. *J Am Acad Orthop Surg*. 2001 Sep-Oct; 9(5):336-44.
  59. Harney D, Patijn J. Meralgia paresthetica: diagnosis and management strategies. *Pain Med*. 2007 Nov-Dec;8(8):669-77.
  60. Nouraei SA, Anand B, Spink G, O'Neill KS. A novel approach to the diagnosis and management of meralgia paresthetica. *Neurosurgery*. 2007 Apr;60(4):696-700; discussion 700.
  61. Cheatham SW, Kolber MJ, Salamh PA. Meralgia paresthetica: a review of the literature. *Int J Sports Phys Ther*. 2013 Dec;8(6):883-93.
  62. Kesserwani H. Meralgia Paresthetica: A Case Report With an Update on Anatomy, Pathology, and Therapy. *Cureus*. 2021 Mar 17;13(3):e13937.
  63. Patijn J, Mekhail N, Hayek S, Lataster A, van Kleef M, Van Zundert J. Meralgia Paresthetica. *Pain Pract*. 2011 May-Jun;11(3):302-8.
  64. Russo MJ, Firestone LB, Mandler RN, Kelly JJ Jr. Nerve conduction studies of the lateral femoral cutaneous nerve. Implications in the diagnosis of meralgia paresthetica. *Am J Electroneurodiagnostic Technol*. 2005 Sep;45(3):180-5.
  65. Lo YL, Pavanni R. Electrophysiological features in the management of meralgia paraesthetica. *Ann Acad Med Singap*. 1998 Jul;27(4):530-2.
  66. Seror P, Seror R. Meralgia paresthetica: clinical and electrophysiological diagnosis in 120 cases. *Muscle Nerve*. 2006 May;33(5):650-4.
  67. Onat SS, Ata AM, Ozcakar L. Ultrasound-Guided Diagnosis and Treatment of Meralgia Paresthetica. *Pain Physician*. 2016 May;19(4):E667-9.
  68. Beltran LS, Bencardino J, Ghazikhanian V, Beltran J. Entrapment neuropathies III: lower limb. *Semin Musculoskelet Radiol*. 2010 Nov;14(5):501-11. doi: 10.1055/s-0030-1268070. Epub 2010 Nov 11
  69. Harney D, Patijn J. Meralgia paresthetica: diagnosis and management strategies. *Pain Med*. 2007 Nov-Dec;8(8):669-77.

70. Wiezer MJ, Franssen H, Rinkel GJ, Wokke JH. Meralgia Paraesthetica: differential diagnosis and follow-up. *Muscle Nerve*. 1996 Apr;19(4):522-4.
71. Dureja GP, Gulaya V, Jayalakshmi TS, Mandal P. Management of meralgia paresthetica: A multimodality regimen. *Anesth Analg* 1995;80:1060-1.
72. Williams PH, Trzil KP. Management of meralgia paresthetica. *J Neurosurg*. 1991 Jan;74(1):76-80. doi: 10.3171/jns.1991.74.1.0076.
73. Hurdle MF, Weingarten TN, Crisostomo RA, Psimos C, Smith J. Ultrasound-guided blockade of the lateral femoral cutaneous nerve: technical description and review of 10 cases. *Arch Phys Med Rehabil* 2007;88:1362-4.
74. Rossmann T, Zessner-Spitzenberg J, Sandurkov C, Heber UM, Weninger WJ, Meng S. Ultrasound-Guided Injections at the Lateral Femoral Cutaneous Nerve: The Inguinal Ligament as a Barrier. *Pain Physician*. 2020 Jul;23(4):E363-E368.
75. Kiliç S, Özkan FÜ, Külcü DG, Öztürk G, Akpınar P, Aktas I. Conservative Treatment Versus Ultrasound-Guided Injection in the Management of Meralgia Paresthetica: A Randomized Controlled Trial. *Pain Physician*. 2020 Jun;23(3):253-262. Erratum in: *Pain Physician*. 2020 Nov;23(6):647.
76. Elavarasi A, Goyal V, Singh MB, Padma Srivastava MV. Is Triamcinolone an Easy and Efficient Way to Treat Meralgia Paresthetica? A Cohort Study. *Ann Indian Acad Neurol*. 2019 Jul-Sep;22(3):308-310.
77. Gurbuz H, Gultekin A. Medical and surgical treatment of meralgia paresthetica. *Pain Manag*. 2021 Apr;11(4):389-393. doi: 10.2217/pmt-2020-0085. Epub 2021 Feb 11.
78. Puig L, Alegre M, De Moragas JM. Treatment of meralgia paraesthetica with topical capsaicin. *Dermatology* 1995;191:73-4.
79. Calabrò RS, Casella C, Manuli A, Militi D, Gervasi G. Meralgia Paresthetica Successfully Treated with Palmithoylethanolamide. *Innov Clin Neurosci*. 2020 Jul 1;17(7-9):10-11.
80. Langford B, Mauck WD. Peripheral Nerve Stimulation: A New Treatment for Meralgia Paresthetica. *Pain Med*. 2021 Feb 4;22(1):213-216.
81. Abd-Elseyed A, Gyorfı MJ, Ha SP. Lateral Femoral Cutaneous Nerve Radiofrequency Ablation for Long-term Control of Refractory Meralgia Paresthetica. *Pain Med*. 2020 Nov 7;21(7):1433-1436.
82. Philip CN, Candido KD, Joseph NJ, Crystal GJ. Successful treatment of meralgia paresthetica with pulsed radiofrequency of the lateral femoral cutaneous nerve. *Pain Physician*. 2009 Sep-Oct;12(5):881-5.
83. Lee JJ, Sohn JH, Choi HJ, Yang JS, Lee KH, Do HJ, Lee SH, Cho YJ. Clinical Efficacy of Pulsed Radiofrequency Neuromodulation for Intractable Meralgia Paresthetica. *Pain Physician*. 2016 Mar;19(3):173-9.
84. Lu VM, Burks SS, Heath RN, Wolde T, Spinner RJ, Levi AD. Meralgia paresthetica treated by injection, decompression, and neurectomy: a systematic review and meta-analysis of pain and operative outcomes. *J Neurosurg*. 2021 Jan 15:1-11.
85. Malessy MJA, Eekhof J, Pondaag W. Dynamic decompression of the lateral femoral cutaneous nerve to treat meralgia paresthetica: technique and results. *J Neurosurg*. 2018 Dec 1:1-9. doi: 10.3171/2018.9.JNS182004. Epub ahead of print.
86. Schwaiger K, Panzenbeck P, Purschke M, Russe E, Kaplan R, Heinrich K, Mandal P, Wechselberger G. Surgical decompression of the lateral femoral cutaneous nerve (LFCN) for Meralgia paresthetica treatment: Experimental or state of the art? A single-center outcome analysis. *Medicine (Baltimore)*. 2018 Aug;97(33):e11914.
87. Morimoto D, Kim K, Kokubo R, Kitamura T, Iwamoto N, Matsumoto J, Sugawara A, Isu T, Morita A. Deep Decompression of the Lateral Femoral Cutaneous Nerve Under Local Anesthesia. *World Neurosurg*. 2018 Oct;118:e659-e665. doi: 10.1016/j.wneu.2018.06.252. Epub 2018 Jul 11.
88. Ahmed A, Arora D, Kochhar AK. Ultrasound-guided alcohol neurolysis of lateral femoral cutaneous nerve for intractable meralgia paresthetica: a case series. *Br J Pain*. 2016 Nov;10(4):232-237. doi: 10.1177/2049463716668811. Epub 2016 Sep 16.
89. Son BC, Kim DR, Kim IS, Hong JT, Sung JH, Lee SW. Neurolysis for meralgia paresthetica. *J Korean Neurosurg Soc*. 2012 Jun;51(6):363-6. doi: 10.3340/jkns.2012.51.6.363. Epub 2012 Jun 30.
90. Hanna A. Transposition of the lateral femoral cutaneous nerve. *J Neurosurg*. 2018 Apr 13:1-6. doi: 10.3171/2017.8.JNS171120. Epub ahead of print.
91. Hanna AS. Lateral femoral cutaneous nerve transposition: Renaissance of an old concept in the light of new anatomy. *Clin Anat*. 2017 Apr;30(3):409-412.
92. Schwaiger K, Panzenbeck P, Purschke M, Russe E, Kaplan R, Heinrich K, Mandal P, Wechselberger G. Surgical decompression of the lateral femoral cutaneous nerve (LFCN) for Meralgia paresthetica treatment: Experimental or state of the art? A single-center outcome analysis. *Medicine (Baltimore)*. 2018 Aug;97(33):e11914.
93. Morimoto D, Kim K, Kokubo R, Kitamura T, Iwamoto N, Matsumoto J, Sugawara A, Isu T, Morita A. Deep Decompression of the Lateral Femoral Cutaneous Nerve Under Local Anesthesia. *World Neurosurg*. 2018 Oct;118:e659-e665.
94. Payne R, Seaman S, Sieg E, Langan S, Harbaugh K, Rizk E. Evaluating the evidence: is neurolysis or neurectomy a better treatment for meralgia paresthetica? *Acta Neurochir (Wien)*. 2017 May;159(5):931-936.
95. Sanjaya A. Meralgia paresthetica: finding an effective cure. *Postgrad Med*. 2020 Jan;132(1):1-6. Epub 2019 Oct 6.