

Pathological and biochemical studies of experimental hypothyroidism in sheep

Khodadad Mostaghni^{1*}, Khalil Badiei¹, Azizollah Khodakaram-Tafti², and Ali Bashari Maafi¹

¹ Department of Clinical Sciences, School of Veterinary Medicine, Shiraz University, Shiraz, Iran

² Department of Pathobiology, School of Veterinary Medicine, Shiraz University, Shiraz, Iran

MOSTAGHNI, K., K. BADIEI, A. KHODAKARAM-TAFTI, A. B. MAAFI:
Pathological and biochemical studies of experimental hypothyroidism in sheep. Vet. arhiv 78, 209-216, 2008.

ABSTRACT

The objective of this experiment was to determine pathological and biochemical changes in hypothyroid sheep. Experiments were carried out using 12 Iranian crossbred sheep aged between 3-3.5 years old and weighing 45-65 kg. The animals were divided into two groups, 4 sheep as control and 8 as the experimental group. Hypothyroidism was induced in experimental animals by giving thiourea 50 mg/kg body mass daily for 4 weeks. Blood samples were taken weekly for T3 and T4 measurements. There was a highly significant decrease ($P<0.01$) in values of T3 and T4 in experimental animals as compared to the control group. At the end of the experiment all the animals of control and experimental groups were sacrificed and necropsied. Tissue samples were collected from the thyroid, kidney, liver, skin and spleen and stained by hematoxylin and eosin and sudan 3 and 4. In the experimental group the following changes were observed: the thyroid gland was moderately enlarged and firm in texture and darker in color. Histopathologically, the epithelial lining of the thyroid follicles showed hypertrophy and hyperplasia which projected into the lumen. The lumens of the follicles were empty of colloid. Kidneys were apparently normal but microscopically showed glomerular lipidosis and tubular changes including mild congestion and lipidosis. The liver was pale, anemic, friable and enlarged. The hepatocytes exhibited fatty change and some inclusion bodies in their nuclei. Moreover, hyperplasia of bile ducts and mononuclear cell infiltration of liver were seen. The skin was mainly normal in the majority of the cases but histologically one case showed hyperkeratosis of the epidermis, associated with excessive keratin formation within the hair follicles. In the spleen, the number and size of macrophages were increased and one case showed some petechial hemorrhages on its surface. The treated ewes showed significant hyperlipidemia ($P<0.01$) and hypercholesterolemia ($P<0.01$). A significant decline ($P<0.01$) was detected in HDL as well as a significant increase ($P<0.01$) in LDL serum levels of the treated ewes.

Key words: sheep, hypothyroidism, thyroid hormones, pathological changes

*Contact address:

Dr. K. Mostaghni, DVM, PhD, Department of Clinical Sciences, School of Veterinary Medicine, Shiraz University, Shiraz, Iran, Postal Code 71345, P.O. Box 1731, Phone: +98 7112 286 950; Fax: +98 7112 286 940; E-mail: mostaghniim@yahoo.com

Introduction

The thyroid gland is the most important endocrine gland for metabolic regulation (CUNNINGHAM, 2002). The thyroid hormones thyroxin (T4) and triiodothyronine (T3) are necessary for the growth, metabolism and functioning of virtually every cell in the body (SOJKA, 1995). Iodine is an essential trace element responsible for thyroid hormone synthesis that is responsible for regulation of lipid, carbohydrate and nitrogen metabolism as well as regulation of energy (SOKKAR et al., 2000). Hypothyroidism may be due to deficient iodine intake or secondarily conditioned by intake of goitrogens (RADOSTITS et al., 2000). There are two main types of goitrogens, 1) a thiocyanate type, which inhibits thyroidal uptake of iodine, 2) a thiouracil type, which interferes with the organic binding of iodine in the thyroid (WILSON, 1975). In the ruminant, hypothyroidism is the commonest type of thyroid disorder encountered (WILSON, 1975). The present study describes pathological, serum thyroid hormones and lipid profile in experimentally induced hypothyroidism in sheep.

Materials and methods

Twelve Iranian crossbred female sheep, aged 3-3.5 years old and weighing 45-65 kg were used. They were all fed a ration, based on hay and barley. Water was offered ad libitum. They were in good condition and clinically normal. Prior to the experiments, they were dewormed using albendazole (7.5 mg/kg). The animals were randomly divided into two groups, 4 sheep as control and 8 as the experimental group. Hypothyroidism was induced in experimental animals by giving thiourea (a goitrogenic substance) 50 mg/kg body mass daily for four weeks. For biochemical analysis, blood samples were taken weekly from the jugular vein and kept at room temperature for complete clotting and centrifuged for the separation of serum and stored at -20 °C. Triiodothyronine and thyroxin levels were assayed by radioimmunoassay (RIA) technique according to RODBARD and HUTT (1974). Concentrations of serum cholesterol, HDL and LDL were also analyzed (BURTIS et al., 2006). At the end of the experiment all the animals of the control and experimental groups were sacrificed and necropsied. After recording gross observations of the thyroid, kidney, liver, skin and spleen, tissue samples were taken from different sites of these organs and were fixed in 10% formalin. Tissue (5 µm) sections were prepared and stained by hematoxylin and eosin (H&E) and sudan 3 and 4 (without fixation by cryocut) to study the histopathological changes and confirm fatty change respectively.

Results are expressed as mean ± SE. Differences of data between control and treated ewes were assessed by independent t-test. Significances were accepted at $P < 0.01$ levels.

Results

The mean values of serum triiodothyronine (T3) and thyroxin (T4) of animals showed a significant ($P < 0.01$) decrease from the second week until the end of experiment (Table

1). A significant ($P<0.01$) decline was discernible in the high-density lipoprotein (HDL) serum levels of treated sheep, as well as a significant ($P<0.01$) increase in the low-density lipoprotein (LDL) serum levels (Table 1).

Table 1. The mean and standard errors of serum thyroid hormones and lipid profile in the hypothyroid sheep

Duration of experiment						
	Groups	Day 0	Week 1	Week 2	Week 3	Week 4
T3 (nmol/L)	Control	1.55 ± 0.03	1.74 ± 0.02	1.74 ± 0.02	1.74 ± 0.0	1.69 ± 0.02
T3 (nmol/L)	Treated	1.27 ± 0.01	0.74 ± 0.008*	0.06 ± 0.001*	0.0003 ± 0.0009*	<0.0001*
T4 (nmol/L)	Control	0.08 ± 0.002	0.08 ± 0.002	0.09 ± 0.001	0.09 ± 0.01	0.1 ± 0.001
T4 (nmol/L)	Treated	0.07 ± 0.004	0.02 ± 0.0009*	0.008 ± 0.002*	<0.0001*	<0.0001*
Total lipid (mg/L)	Control	1589 ± 19.9	1619 ± 10.2	1802 ± 16	1664 ± 59.5	1650 ± 35.7
Total lipid (mg/L)	Treated	1979 ± 14.1	1659 ± 26.2	2150 ± 44.1	2836 ± 33.7*	4176 ± 79.3*
Cholesterol (mmol/L)	Control	1.43 ± 0.14	1.59 ± 0.07	1.71 ± 0.16	1.54 ± 0.01	1.53 ± 0.04
Cholesterol (mmol/L)	Treated	1.68 ± 0.14	4.27 ± 0.42	3.92 ± 0.42	2.92 ± 0.19**	5.67 ± 0.05*
LDL (mmol/L)	Control	1.1 ± 0.16	1.49 ± 0.16	1.47 ± 0.13	1.47 ± 0.08	59.1 ± 1.90
LDL (mmol/L)	Treated	1.26 ± 0.13	2.81 ± 0.12	3.8 ± 0.2*	3.0 ± 0.06*	4.32 ± 0.05*
HDL (mmol/L)	Control	0.64 ± 0.02	0.77 ± 0.11	0.7 ± 0.03	0.65 ± 0.03	0.66 ± 0.04
HDL (mmol/L)	Treated	0.72 ± 0.2	0.55 ± 0.07	0.4 ± 0.04*	0.19 ± 0.03*	0.15 ± 0.02*

*Significant at $P<0.01$

Moderate enlargement of the thyroid gland was observed in all the experimental animals. The gland was firm in texture and darker in color than that in the control. Histopathologically the epithelial lining of the thyroid follicles showed hypertrophy and hyperplasia. The follicular lumens were devoid of colloid. The cells had eosinophilic

cytoplasm and hyperchromatic nucleus placed apically in some cases. The majority of the follicles were lined by multiple layers of cuboidal/columnar epithelial cells partly or completely packing their lumina (Fig. 1). The kidneys were apparently normal. Histopathology revealed glomerular lipidosis and mild to moderate degrees of degenerative changes in tubular epithelium. Tubular changes were characterized by mild congestion and fatty change of epithelial cells (Fig. 2). The livers of treated animals were pale, anemic and friable and enlarged as compared to those of control animals. In histopathological examination of the liver, the hepatocytes generally exhibited fatty change (Fig. 3). The cells of liver were swollen and enlarged with fat vacuolation of cytoplasm, especially at the periportal zone of the hepatic lobules. The other changes observed in the liver were bile duct hyperplasia, mononuclear cell infiltration and some inclusion bodies in degenerated hepatic nuclei. Central veins and sinusoids were dilated and engorged. The skin was normal in majority of the cases. Only one case showed atrophy of the epiderm associated with hyperkeratosis and excessive keratin formation within the hair follicles (Fig. 4). In one animal the spleen showed some petechial hemorrhages on its surface. Histopathologically, an increase in the number and size of macrophages was observed in the spleens of the hypothyroid sheep.

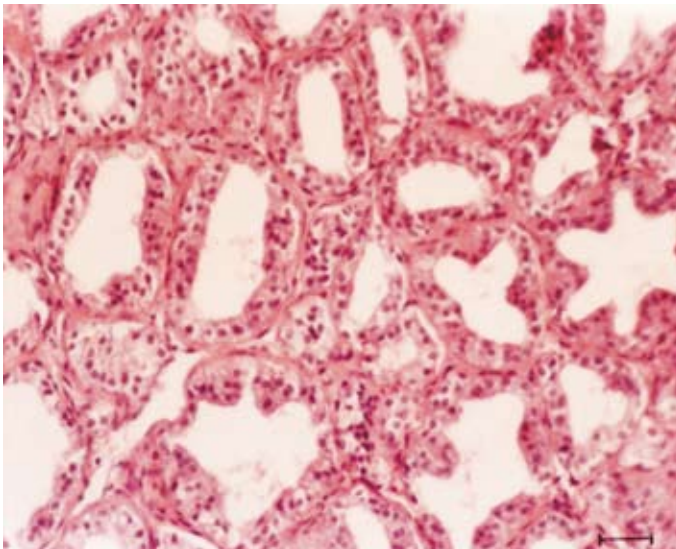


Fig. 1. Thyroid gland. Hyperplasia of the follicle-lining epithelial cells. H&E, $\times 320$, scale bar = 34 μm .

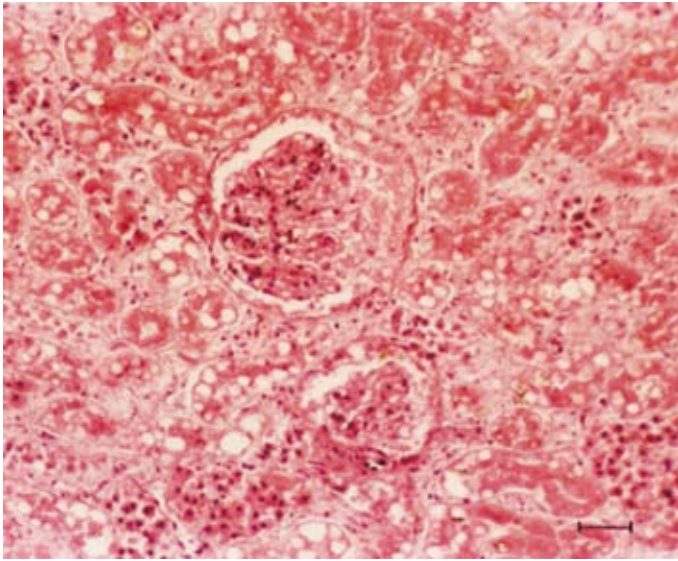


Fig. 2. Kidney. Glomerular lipidosis and fatty change of tubular epithelial cells. H&E, $\times 160$, scale bar = 62 μm .

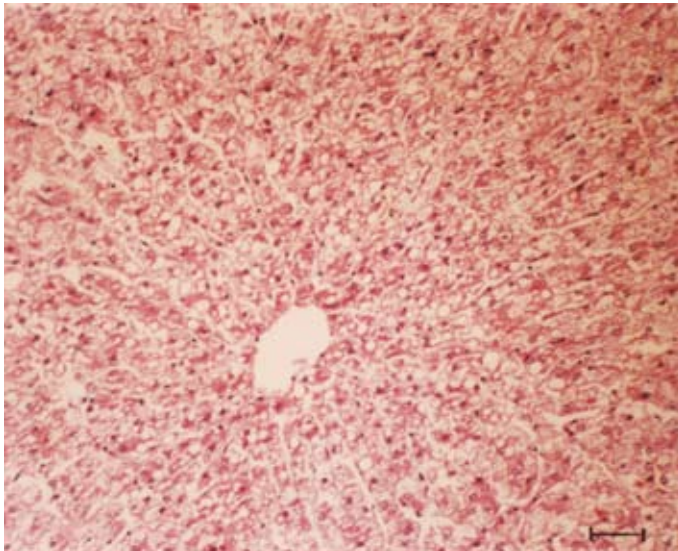


Fig. 3. Liver. Fatty changes in the hepatocytes. H&E, $\times 160$, scale bar = 62 μm .

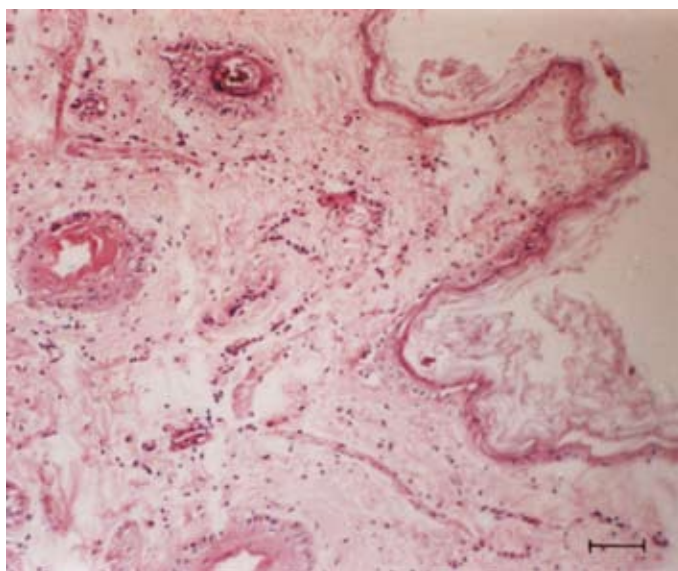


Fig. 4. Skin. Atrophy of the epidermis associated with hyperkeratosis of the epidermis and hair follicles. H&E, $\times 160$, scale bar = 62 μm .

Discussion

The significant fall in serum triiodothyronine (T3) and thyroxine (T4) in sheep is due to the interference of iodination of tyrosine by thiourea (SOKKAR et al., 2000). Hyperplasia and hypertrophy of the follicular cells were obviously due to the reduction in thyroid hormones in blood leading to activation of the pituitary to secrete more thyroid stimulating hormone (TSH) (ALAVI and ZIBAI, 1993; NASSERI and PRASAD, 1989; MGONGO et al., 1981). Significant hypercholesterolemia, decrease of HDL and increase of LDL was observed at the second week. These results are similar to the observations of SWENSON and REECE (1996), SOKKAR et al. (2000) and NASSERI and PRASAD (1987). They described that these changes may be due to a lowering of the basal metabolic rate resulting from hypothyroidism. The changes of HDL, LDL and cholesterol serum levels may be a result of lipolysis. One particular effect of thyroid hormones is the tendency to reduce plasma cholesterol levels. This appears to involve both increased cell uptake of low-density lipoproteins with associated cholesterol molecules and a tendency for increased degradation of both cholesterol and low-density lipoprotein (CUNNINGHAM, 2002). Renal glomeruli became plugged with lipid in hypothyroid animals, resulting in progressive renal failure (HASCHEK and ROUSSEAU, 1991). NASSERI and PRASAD (1989) did not report lipidosis in the kidney of hypothyroid sheep. The occurrence of inclusion bodies

in some degenerated hepatic nuclei could be a result of increased fragility of the nuclear membrane. There is the possibility of toxic effects of thiourea in producing the changes in the liver (RAMAKRISHNA and PRASAD, 1992). Vacuolation of hepatocytes and glomerular lipidosis may be due to lowered basal metabolic rate (JUBB et al., 1985; SOKKAR et al., 2000) and decreased lipid metabolism which occurs in hypothyroidism (JUBB et al., 1985; NASSERI and PRASAD, 1989). Although the epidermal layer was considered a target organ for the action of thyroxin (RAMAKRISHNA and PRASAD, 1992), only one case with atrophy of the epiderm associated with hyperkeratosis was seen in this study. The increase in the number and size of macrophages observed in the spleen of hypothyroid sheep may reveal hyperactivation of reticuloendothelial cells (SOKKAR et al., 2000). In conclusion, hypothyroidism in sheep is found to be responsible for pathological and biochemical changes in this study.

Acknowledgements

This work was sponsored by a grant from Shiraz University, Iran, No. 81-VE-1535-C220.

References

- ALAVI SHOUSHARI, A. M., S. ZIBAI (1993): Effects of hypothyroidism on the reproductive system of male lambs. *J. Vet. Fac. Univ. Tehran*. 48, 41-47.
- BURTIS, C. A., E. R. ASHWOOD, D. E. BRUNS (2006): *Tietz Textbook of Clinical Chemistry and Molecular Diagnostics*. 4th ed., Elsevier Saunders, St. Louis. pp. 942-956.
- CUNNINGHAM, J. G. (2002): *Textbook of Veterinary Physiology*. 3rd ed. W. B. Saunders Co., Philadelphia. pp. 342-348.
- HASCHEK, W. M., C. G. ROUSSEAU (1991): *Handbook of Toxicologic Pathology*. Academic press Inc., San Diego. pp. 711-737.
- JUBB, K. V. F., P. C. KENNEDY, N. PALMER (1985): *Pathology of Domestic Animals*. 3rd ed. Academic Press Inc., London. pp. 266-280.
- MGONGO, F. O., S. GOMBE, J. S. OGGA (1981): Thyroid status in cobalt and vitamin B12 deficiency in goats. *Vet. Rec.* 109, 51-53.
- NASSERI, A. A., M. C. PRASAD (1987): Experimental hypothyroidism in lambs. *Ind. J. Anim. Sci.* 57, 383-387.
- NASSERI, A. A., M. C. PRASAD (1989): Experimental hypothyroidism in sheep. *Pathomorphological studies*. *Ind. J. Anim. Sci.* 59, 958-960.
- RADOSTITS, O. M., C. C. GAY, D. C. BLOOD, K. W. HINCHCLIFF (2000): *Veterinary Medicine*. 9th ed. W.B. Saunders Co., Philadelphia. pp. 1503-1505.
- RAMAKRISHNA, C., M. C. PRASAD (1992): Pathomorphological study of experimental hypothyroidism in goats. *Ind. Vet. J.* 69, 111-114.

- RODBARD, D., D. M. HUTT (1974): Radioimmunoassays and Related Procedures in Medicine I. International Atomic Energy Agency. pp. 105-192.
- SOJKA, J. E. (1995): Hypothyroidism in horse. *Comp. Educ. Prac. Vet.* 17, 845-852.
- SOKKAR, S. M., A. H. SOROR, Y. F. AHMED, O. H. EZZO, M. A. HAMOUDA (2000): Pathology and biochemical studies on experimental hypothyroidism in growing lambs. *J. Vet. Med. B.*, 47, 639-652.
- SWENSON, J. G., W. O. REECE. (1996): *Dukes' Physiology of Domestic Animals*. 11th ed., Cornell University press, London. pp. 640.
- WILSON, J. G. (1975): Hypothyroidism in ruminants with special reference to fetal goiter. *Vet. Rec.* 97, 161-164.

Received: 29 May 2006

Accepted: 2 May 2008

MOSTAGHNI, K., K. BADIELI, A. KHODAKARAM-TAFTI, A. B. MAAFI: Patološka i biokemijska istraživanja pokusno izazvanoga hipotireoidizma u ovaca. *Vet. arhiv* 78, 209-216, 2008.

SAŽETAK

Svrha pokusa bila je istražiti patološke i biokemijske promjene u ovaca s hipotireoidizmom. U pokus je uzeto 12 iranskih križanih ovaca u dobi od 3 do 3,5 godine tjelesne mase 45 do 65 kg. Ovce su bile podijeljene u dvije skupine: četiri su uzete u kontrolnu, a osam u pokusnu skupinu. Hipotireoidizam je u pokusnih životinja bio potaknut davanjem 50 mg/kg tjelesne mase tioureje dnevno u tijeku četiri tjedna. Uzorci krvi uzimani su tjedno za mjerenje T3 i T4. Ustanovljeno je značajno smanjenje ($P < 0,01$) vrijednosti T3 i T4 u pokusnih životinja u odnosu na kontrolnu skupinu. Na kraju pokusa sve su životinje pokusne i kontrolne skupine bile žrtvovane i razučene. Uzeti su uzorci tkiva štitnjače, bubrega, jetre, kože i slezene te su pripremljeni histološki preparati obojeni hematoksilin-eozinom i sudan 3 i 4 postupkom. U pokusnoj skupini štitasta žlijezda bila je blago povećana, čvrste strukture i jače obojena. Epitel tireoidnoga folikula je hipertrofirao, a uočena je i hiperplazija projicirana u lumen. U lumenu folikula nije ustanovljen koloid. Bubrezi su makroskopski bili nepromijenjeni, ali je mikroskopski ustanovljena glomerularna lipidoza i tubularne promjene uključujući blagu kongestiju i lipidozu. Jetra su bila blijeda, anemična, prhka i povećana. U hepatocitima je ustanovljena masna degeneracija i inkluzijska tjelešca u jezgrama. Povrh toga ustanovljena je hiperplazija žučovoda i mononuklearna infiltracija jetrenoga tkiva. Koža je makroskopski bila normalna u većine životinja, ali je patohistološki u jednom slučaju ustanovljena hiperkeratoza epidermisa povezana s obilnom tvorbom keratina unutar dlačnih folikula. U slezeni je bio povećan broj makrofaga i njihova veličina, a u jednom slučaju ustanovljena su petehijalna krvarenja na površini. Pokusne ovce pokazivale su značajnu hiperlipidemiju ($P < 0,01$) i hiperkolesterolemiju ($P < 0,01$). Ustanovljen je značajan pad razine ($P < 0,01$) lipoproteina velike gustoće kao i značajno povećanje ($P < 0,01$) razine lipoproteina male gustoće u pokusnih ovaca.

Cljučne riječi: ovca, hipotireoidizam, tiroidni hormoni, patološke promjene
