

Zdenko Šarac¹, Ružica Zovko¹, Stipo Cvitanović¹, Kristina Goršeta², Domagoj Glavina²

Fusion of Unerupted Mesiodens with a Regular Maxillary Central Incisor: a Diagnostic and Therapeutic Challenge

Fuzija neizniknutog meziodensa s maksilarnim središnjim sjekutićem: dijagnostički i terapijski izazov

¹ University of Mostar, School of Dental Medicine, Mostar, Bosnia and Herzegovina
Stomatološki fakultet Sveučilišta u Mostaru, BiH

² Department of Pediatric and Preventive Dentistry, School of Dental Medicine, University of Zagreb, Croatia
Zavod za dječju i preventivnu stomatologiju Stomatološkog fakulteta Sveučilišta u Zagrebu, Hrvatska

Abstract

The mesiodens is the most frequent type of supernumerary tooth which can appear in the maxillary midline area. The etiology of mesiodentes is not fully understood. This report shows a case of incomplete fusion of an unerupted mesiodens with a permanent maxillary central incisor, aligned in the dental arch. Intraoral and radiographic examinations indicated fusion of the crown and cervical part of the root of the supernumerary tooth with the permanent incisor. The clinical situation was further complicated by the presence of another supernumerary tooth located palatally. The treatment approach has included two phase surgical therapy to extract the supernumerary teeth. Early diagnosis and appropriate surgical treatment of mesiodentes are important to decrease the risk of clinical complications. Pre-operative 3D imaging is strongly advisable since it allows accurate data to be obtained, and reduces the extent of surgery and the possibility of procedural complications. In most cases, a multidisciplinary collaboration is necessary for precise diagnosis and predictable treatment outcome.

Received: October 17, 2020

Accepted: July 7, 2021

Address for correspondence

Kristina Goršeta
University of Zagreb
School of Dental Medicine
Gundulićeva 5, 10000 Zagreb
Phone: +38514802110
Fax +38514802159
kgorseta@sfzg.hr

MeSH terms: Tooth Abnormalities; Supernumerary Tooth; Impacted Tooth; Unerupted Tooth; Fused Teeth; Tooth Extraction

Author keywords: Incisor Abnormalities; Impacted Teeth; Supernumerary Teeth; Mesiodens; Surgical Extraction

Introduction

Hyperodontia (supernumerary teeth) is defined as a dental anomaly with one or more additional teeth. Supernumerary tooth could form during the initial stage of tooth germ formation due to the interaction of environmental and genetic factors (1). Genetic predisposition plays a role in the development of this anomaly (2,3). A great number of abnormalities of teeth are congenital. Mesiodens is the most common type of supernumerary tooth found in the premaxillary region. Fusion is the union of two embryological separately developing teeth. Geminaciation is an anomaly caused by a single tooth germ that attempted to divide during its development, resulting in a bifid crown. Fusion can be complete or incomplete depending upon the stage of tooth development at the time of union (4). Fused teeth may lead to serious esthetic problems and malocclusions, especially when supernumerary elements are involved (5). Geminaciation is clinically similar to fusion, and they can be differentiated by assessing the number of teeth in the dentition (6). On the other hand, clinical and radiological

Uvod

Hiperdonacija (prekobrojni zubi) definira se kao anomalija broja zuba s jednim ili više dodatnih zuba. Prekobrojni zub mogao bi se stvoriti tijekom početne faze stvaranja zametka zuba zbog interakcije okolišnih i genetskih čimbenika (1). Genetska predispozicija veoma je važna u razvoju te anomalije (2, 3). Velik broj abnormalnosti zuba je prirodan. Mezioidens je najčešći tip prekobrojnog zuba u premaksilarnoj regiji. Fuzija je spoj dvaju embriološki odvojenih zuba u razvoju. Geminacija je anomalija koju uzrokuje zametak jednoga zuba koji se pokušava podijeliti tijekom razvoja, što rezultira bifidnom krunom zuba. Fuzija može biti potpuna ili nepotpuna, ovisno o stupnju razvoja zuba u trenutku spajanja (4). Srasli zubi mogu činiti ozbiljne estetske probleme i malokluzije, posebno kada je riječ o prekobrojnosti (5). Geminacija i fuzija klinički su slične, a mogu se razlikovati procjenom broja izniklih zuba (6). S druge strane, klinički i radiološki nalazi geminacije dvostruke su krune zuba i jedan korijen. Iznimno je teško razlikovati fuziju i geminaciju ako se pupoljak preko-

findings of gemination are double crowns and a single root. It is extremely difficult to differentiate between fusion and gemination when a supernumerary tooth bud is attached to the adjacent one; hence the term 'double teeth' is often used (4).

Millazzo and Alexander (7) suggested counting of teeth in a jaw and that the abnormal tooth should be counted as a single one. If we determine a normal number of teeth, it is gemination, and if it is a reduced number in dental arch then we diagnose fusion. The diagnosis established in this way can be wrong if it is a fusion of a normal and supernumerary tooth or if it is a gemination associated with hypodontia. However, those situations are really rare (8). Hagman (9) found only one described case of fusion with a supernumerary tooth. Badole, Shenoi and Parlikar (10) showed an endodontic treatment of fused permanent supernumerary tooth with divided root canals and a periapical process.

Knežević et al. (11) found the incidence of 0.2% of double teeth in a Croatian population. In a sample of Jordanian dental patients, the incidence of double teeth was 0.42%, and the maxillary central incisors were the most commonly affected with the incidence of 3.6% (12). Hamasha and Al-Khateeb (12) stated that recognizing the condition facilitates the prosthetic, periodontal, orthodontic, and surgical treatment. Multidisciplinary approach to planning and treatment contributes to a more successful therapy (13, 14). Published reports describe fusion of supernumerary with permanent teeth, mostly for teeth which are already completely erupted (13-17).

This study presents a case of incomplete fusion of an unerupted mesiodens with a permanent upper-central incisor placed in the dental arch. Another supernumerary tooth was placed palatally, which made the clinical procedure more complicated.

Case report

A 17-year-old boy was referred by orthodontist for further examination of the excessive teeth in a frontal region of the upper jaw with a recommendation for extraction. The medical history revealed that three years before he suffered from pain in a frontal region, which was taken care of by endodontic treatment of the tooth 21. The medical history confirmed that the patient was in good health. He denied hypersensitivity to drugs and anesthetic agents.

The intraoral examination revealed a labial displacement of the tooth 11, whereas supernumerary teeth were not erupted. A periapical radiological analysis confirmed the diagnosis of hyperdontia. The presence of osteolytic shadow in the periapical area of 11 and 21, was found (Figure 1). A clear case of tooth sensitivity 11 and 22 was determined by thermal test using ethyl-chloride spray (cold test). The patient was obviously concerned and mildly anxious. During the preoperative preparation the patient and his parents were informed about treatment objectives and procedures.

Surgical procedure was performed under local infiltration anesthesia with Ubistesin forte, containing Articain hydrochloride/Epinephrine 1/100 000 (3M ESPE, Seefeld, Germany). One-sided vestibular relieving incision along the edge of gingiva was performed, thus enabling visibility, and at the

brojnom zuba spoji sa susjednim, pa se često koristi izraz *dvostruki zubi* (4).

Milazzo i Alexander (7) predlažu da se izbroje zubi u čeljusti, a da se abnormalni zub broji kao jedan. Ako se pritom utvrdi normalan broj zuba, riječ je o geminaciji, a ako ih je manje u zubnom luku, dijagnosticira se fuzija. Tako postavljena dijagnoza može biti pogrešna ako se radi o nalazu fuzije normalnoga i prekobrojnoga zuba ili geminacije povezano s hipodontijom. No takve su situacije ekstremno rijetke (8). Hagman (9) je pronašao samo jedan opisani slučaj fuzije s prekobrojnim zubom. Badole, Shenoi i Parlikar (10) opisuju endodontski tretman prekobrojnoga i trajnoga zuba s fuzijom s razdvojenim korijenskim kanalima i periapikalnim procesom.

Knežević i suradnici (11) ustanovili su u hrvatskoj populaciji pojavnost dvostrukih zuba od 0,2 %. U uzorku jordanskih stomatoloških pacijenata učestalost dvostrukih zuba bila je 0,42 %, a maksimalni središnji sjekutići imali su najčešće incidenciju od 3,6 % (12). Hamasha i Al-Khateeb (12) smatraju da rana dijagnostika navedenih stanja olakšava protetsku, parodontološku, ortodontsku i kiruršku terapiju. Multidisciplinarni pristup u planiranju i liječenju pridonosi uspješnoj terapiji (13, 14).

U objavljenim izvještajima opisana je fuzija prekomjernoga zuba s trajnim zubima, uglavnom za one koji su već u cijelosti iznikli (13 – 17).

U ovom radu opisan je slučaj nepotpune fuzije neizniknutoga prekobrojnoga zuba s trajnim zubom u zubnome luku. Dijagnosticiran je još jedan palatinalno smješten prekobrojni zub koji je dodatno zakomplicirao kliničku sliku.

Prikaz slučaja

Sedamnaestogodišnjega pacijenta B. S. ortodont je poslao na pregled s kliničkim i radiološkim nalazom dvaju neizniknutih prekobrojnih zuba u frontalnoj regiji gornje čeljusti i s preporukom za ekstrakciju. Iz anamneze je bilo jasno da je unatrag tri godine trpio bolove u frontalnoj regiji koji su tada završili endodontskim liječenjem zuba 21. Anamneza je potvrdila da je pacijent dobrog zdravlja. Negirao je alergije i preosjetljivost na lijekove.

Intraoralnim pregledom ustanovljen je labijalni pomak zuba 11, a prekobrojni zubi nisu bili vidljivi u usnoj šupljini. Analizom panoramske radiološke snimke potvrđena je uputna dijagnoza hiperdoncije. Ustanovljena je i osteolitička sjena u periapikalnoj regiji 11 i 21 (slika 1.). Uredan nalaz senzibiliteta zuba 11 i 12 dobiven je ispitivanjem hladnoćom s pomoću etil-kloridnog spreja (test hladnoćom). Pacijent je bio vidno zabrinut i blago anksiozan. Tijekom predoperacijske pripreme pacijent i njegovi roditelji obaviješteni su o ciljevima i postupcima liječenja.

Kirurški postupak proveden je u lokalnoj infiltracijskoj anesteziji dvjema ampulama anestetika Ubistesin forte koje sadržavaju Artikain hidroklorid/Epinefrin 1/100 000 (3M ESPE, Seefeld, Njemačka). Jednostrani rasterećeni vestibularni rez uz rub gingive omogućio je vestibularnu preglednost

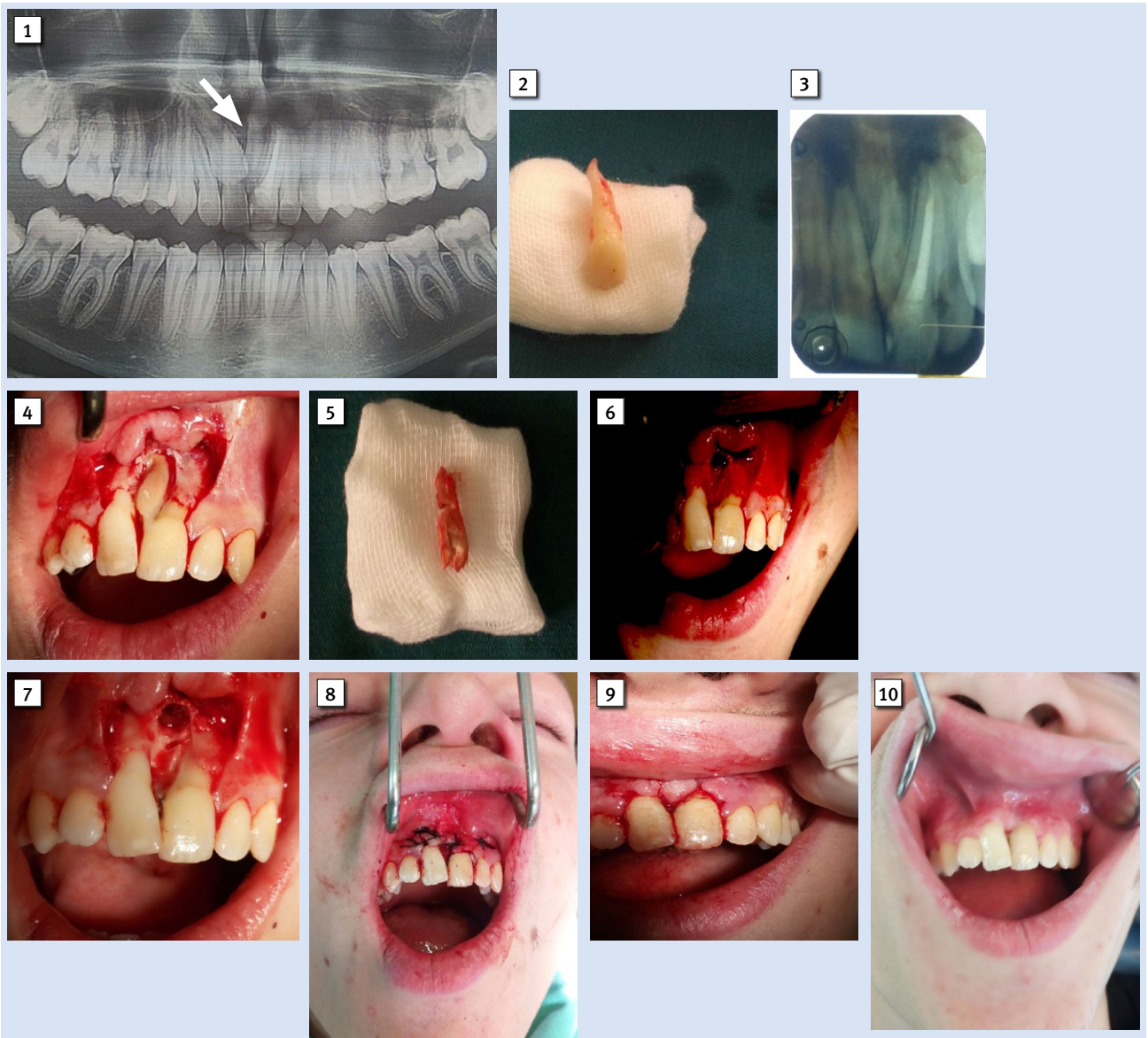


Figure 1 Panoramic radiograph showing the osteolytic shadow in the periapical region of teeth 11, 21, which overlaps with the structures of the nasal region and two supernumerary teeth.

Slika 1. Panoramska radiografija – osteolitička sjena u periapikalnom području zuba 11, 21 koja se preklapa sa strukturama nosne regije i dvama prekobrojnim zubima

Figure 2 Palatally located right supernumerary tooth after extraction.

Slika 2. Palatinalno smješten desni prekobrojni zub nakon ekstrakcije

Figure 3 Periapical radiograph showing a mesiodens in the interincisal region, and indicating the possibility of fusion with the crown of the tooth 21.

Slika 3. Periapikalna radiološka snimka – prekobrojni zub smješten je interincizalno i upućuje na moguće spajanje s krunom zuba 21

Figure 4 Vestibular incision was performed according to Nowak Peter, which allowed the overview of the entire crown and part of the root of supernumerary tooth.

Slika 4. Vestibularni rez učinjen prema Peteru Nowaku omogućio je pregled cijele krunice i dijela korijena prekobrojnog zuba

Figure 5 Vestibularly located mesiodens after separation and extraction.

Slika 5. Vestibularno smješten prekobrojni zub nakon odvajanja i ekstrakcije

Figure 6 Excess of fusion material left on tooth 21 was assessed as dentin and enamel.

Slika 6. Na zubu 21 ostao je suvišak fuzijske mase – vizualno je procijenjena kao dentinska i caklinska

Figure 7 Polished tooth 21 after removal of residual enamel and dentine.

Slika 7. Polirani zub 21 nakon uklanjanja zaostale cakline i dentina

Figure 8 Submucosal periosteal graft was placed interincisally on the position of the papilla, covered by raised mucosal flap, and secured with sutures.

Slika 8. Submukozno periostalni transplantat postavljen je na mjesto papile interincizalno, prekriven je podignutim mukoznim režnjem i postavljeni su šavovi

Figure 9 Eight days after surgery, there is a visible wound healing process.

Slika 9. Osam dana poslije operacije s vidljivim procesom cijeljenja rane

Figure 10 Six weeks later, the healing of the papilla and surrounding mucosa is visible in interincisal region

Slika 10. Nakon šest tjedana u interincizalnoj regiji uočava se cijeljenje zubne papile i okolne mukoze

ture was completed by suturing and controlling the placed graft (Figure 8).

Eight days later, the stitches were removed and the esthetics of interincisal region was satisfactory (Figure 9). Six weeks later, healing of the dental papilla and the surrounding mucosa was visible in the interincisal region (Figure 10).

Discussion

Fusion between the unerupted supernumerary tooth and the erupted permanent tooth is a rare occurrence (8, 9, 11, 12). In the presented case, the clinical examination could not determine fusion because both supernumerary teeth were unerupted. Later on, it was not easy to distinguish the fusion line on panoramic and targeted periapical radiographs. According to European Academy of Pediatric Dentistry (EAPD) guidelines (15) it seems reasonable that cone beam computed tomography (CBCT) could be applied in cases of unerupted, impacted and ectopic teeth. Its use could be considered in cases where it is likely to influence the management and where conventional radiographs fail to provide sufficient information (15, 16).

Rajab and Hamdan (17) estimated by clinical and radiological examination that 18.4% of the patients with hyperdontia had two supernumerary teeth among children aged 5-15 years in Jordan. Srivastava (18) stated that the occurrence of supernumerary teeth or fusion is not so rare among the population in India. Nevertheless, the occurrence of fusion of two supernumerary teeth in primary dentition is very rare (18). Cho (19) stated that in Hong Kong double teeth are more often seen in deciduous dentition than in permanent dentition. Knežević et al. (11) showed that there is a higher frequency of supernumerary teeth in the upper (71.4%) than in the lower jaw (28.6%) in population of Croatia, and that anomalies were more frequent unilaterally (85.7%) than bilaterally (14.3%).

During the treatment plan development, multidisciplinary consultations with orthodontist, pediatric dentist, and periodontist were held, including suggestions for orthodontic extraction of fused and rotated supernumerary tooth after separation. The orthodontist proposed the extraction of endodontically treated tooth 21 which was already aligned in the dental arch, but the surgeon and the pediatric dentist didn't agree and proposed two-phase extraction of supernumerary teeth. However, after evaluating different approaches to the treatment plan, it was decided to implement therapeutic procedure that would be uncomplicated and with a predictable outcome. According to all the statements in the literature, multidisciplinary approach was needed to establish the most appropriate treatment plan (13-14, 16). A two-phase treatment was useful because post-operative bone recovery was enabled after the first surgical procedure, which created a solid base on which the interincisal papilla could be formed in a better way. By using the two-phase surgical procedure, esthetic and functional criteria were met. The patient was satisfied with the final outcome of the therapy.

trolnom kliničkom pregledu poslije šest tjedana ustanovljeno je da su zubna papila i mukoza u interincizalnoj regiji zacijele u cijelosti (slika 10.).

Rasprava

Fuzija neizniknula prekobrojnoga i izniknula trajnoga zuba rijedak je nalaz (8, 9, 11, 12). U opisanom slučaju kliničkim se pregledom nije mogla utvrditi fuzija jer oba prekobrojna zuba nisu iznikla u usnu šupljinu. Poslije nije bilo jednostavno razlučiti kako odrediti liniju fuzije na panoramskim i ciljanim periapikalnim radiogramima. Prema smjernicama Europske akademije za dječju stomatologiju (EAPD) (15), čini se razumnim da se računalna tomografija konusne zrake (CBCT) može primijeniti u slučaju neizniknutih, impaktiranih i ektopičnih zuba. Njegova bi se uporaba mogla razmotriti i kada se pretpostavlja da će utjecati na način liječenja i kada konvencionalni radiografi ne daju dovoljno podataka (15, 16).

Rajab i Hamdan (17) procijenili su kliničkim i radiološkim pregledom među djecom u dobi od 5 do 15 godina u Jordanu da je 18,4 % pacijenata s hiperdoncijom imalo dva prekobrojna zuba. Srivastava (18) je pokazao da pojava prekobrojnih zuba ili fuzija nije tako rijetka u indijskoj populaciji. Ipak, fuzija dvaju prekobrojnih zuba u primarnoj denticiji vrlo je rijetka (18). Cho (19) je izjavio da se u Hong Kongu dvostruki zubi češće vide u mliječnoj nego u trajnoj denticiji. Knežević i ostali (11) pokazali su da je u hrvatskoj populaciji veća učestalost prekobrojnih zuba u gornjoj čeljusti (71,4 %) nego u donjoj (28,6%), a anomalije su češće jednostrano (85,7 %) nego obostrano (14,3 %).

Tijekom razrade plana liječenja obavljene su multidisciplinarnе konzultacije s ortodontom, dječjim stomatologom i parodontologom, uključujući i prijedloge za ortodontsko vađenje srasloga i rotiranoga prekobrojnoga zuba nakon separacije. Ortodont je predložio vađenje endodontski liječenoga zuba 21 koji je već bio u zubnom nizu, ali kirurg i dječji stomatolog nisu se složili i predložili su dvofazno vađenje prekobrojnih zuba. No nakon procjene različitih pristupa planu liječenja, odlučeno je primijeniti za pacijenta manje zahtjevan terapijski postupak s predvidljivim ishodom. Prema svim opisima u literaturi, multidisciplinarni pristup bio je potreban za pripremu najprikladnijega plana liječenja (13 – 14, 16). Dvofazni rad bio je koristan jer je nakon prvoga kirurškog zahvata omogućen poslijeoperacijski oporavak kostiju, što je stvorilo čvrstu podlogu na kojoj se bolje formirala interincizalna papila. Dvofaznim kirurškim postupkom zadovoljeni su estetski i funkcionalni kriteriji. Pacijent je bio zadovoljan konačnim ishodom terapije.

Conclusions

This report shows a case of fusion of an unerupted mesiodens with a permanent maxillary central incisor and one additional supernumerary tooth located palatally. The treatment approach has included two phase surgical extractions of supernumerary teeth. Early diagnosis and appropriate surgical treatment of mesiodentes are important to decrease the risk of orthodontic, periodontal, endodontic, and esthetic problems. Excellent functional and esthetic results obtained in this case are attributable to team work, where specialized experts contributed to the selection of the most appropriate treatment.

Conflict of interest

The authors declare no conflict of interest.

Author's contribution: Z. S., R. Z. S. C. – planned and performed the surgery procedure; Z. S. – completed the surgery treatment; Z. S., R. Z., S. C. – wrote the original draft; K. G., D. G. – wrote the concept and design, gave a critical review, worked on editing; Z. S., R. Z., S. C., K. G., D. G. – approved the final version of the article for publication. All authors discussed the case and contributed to the final manuscript.

Zaključak

Ovaj prikaz slučaja opisuje fuziju neizniknutoga meziodensa s trajnim maksilarnim središnjim sjekutićem i jednim dodatnim prekobrojni zubom smještenim nepčano. Pristup liječenju obuhvaćao je dvofaznu kiruršku ekstrakciju prekobrojnih zuba. Rano dijagnosticiranje i odgovarajuće kirurško liječenje meziodensa važno je da bi se smanjio rizik od ortodontskih, parodontoloških, endodontskih i estetskih problema. Izvršni funkcionalni i estetski rezultati dobiveni u ovom slučaju mogu se pripisati multidisciplinarnoj suradnji koja je rezultirala odabirom najprikladnijega mogućeg liječenja.

Sukob interesa

Autori nisu bili u sukobu interesa.

Doprinos autora: Z. S., R. Z. S. C. – planiranje i obavljanje kirurškog zahvata; Z. S. – završetak kirurškog liječenja; Z. S., R. Z., S. C. – pisanje – izvorni nacrt; K. G., D. G. – pisanje koncepta i dizajn, kritički pregled i uređivanje; Z. S., R. Z., S. C., K. G., D. G. – odobravanje konačne inačice članka za objavljivanje. Svi autori sudjelovali su u raspravi i pripremi konačne inačice rukopisa.

Sažetak

Meziodens je najčešći prekobrojni zub koji se može pojaviti u području središnje maksilarne linije. Etiologija nije potpuno razjašnjena. U ovom članku opisan je slučaj nepotpune fuzije neizniknutoga meziodensa s trajnim maksilarnim središnjim sjekutićem smještenim u zubnom luku. Intraoralni i radiografski pregledi upućivali su na spajanje krune i cervikalnog dijela korijena prekobrojnog zuba s trajnim sjekutićem. Kliničku sliku dodatno je kompliciralo još jedan palatalno smješten prekobrojni zub. Terapijski pristup uključivao je dvofaznu kiruršku terapiju uklanjanja prekobrojnih zuba. Rano dijagnosticiranje i odgovarajuće kirurško liječenje meziodensa važno je za smanjenje rizika od kliničkih komplikacija. Preporučuje se prijeoperacijsko 3D snimanje zato što omogućuje dobivanje točnih podataka i smanjuje opseg kirurškog zahvata te eventualne proceduralne komplikacije. U većini slučajeva prije je potrebna multidisciplinarna suradnja kako bi se dobila precizna dijagnoza, odabrala odgovarajuća terapija i postigao predvidiv ishod liječenja.

Zaprimljen: 17. listopada 2020.

Prihvaćen: 7. srpnja 2021.

Adresa za dopisivanje

Kristina Goršeta
Sveučilište u Zagrebu
Stomatološki fakultet
Gundulićeva 5
10 000 Zagreb
telefon: +38514802110
faks: +38514802159
kgorseta@sfzg.hr

MeSH pojmovi: anomalije zubi; prekobrojni zub; uklješteni zub; neiznikli zub; spojeni zubi; vađenje zuba
Ključne riječi: nepravilnosti sjekutića, impaktirani zubi, prekobrojni zubi, meziodens, kirurška ekstrakcija

References

- Zmener O. Root resorption associated with an impacted mesiodens: a surgical and endodontic approach to treatment. *Dent Traumatol.* 2006 Oct; 22(5): 279-82
- Grahn H, Granath LE. Numerical variation in primary dentition and their correlation with the permanent dentition. *Odont Revy.* 1961;12:348-57.
- Brook AH. Dental anomalies of number form and size. *J Int Assoc Dent Child* 1973;14:83–87.
- Chipashvili N, Vadachkoria D, Beshkenadze E. Geminatio or fusion? - challenge for dental practitioners (case study). *Georgian Med News.* 2011 May;(194):28-33.
- Demircioglu Guler D, SenTunc E, Arici N, Ozkan N. Multidisciplinary management of a fused tooth: a case report. *Case Rep Dent.* 2013;2013:634052.
- Rao P, Veena K, Chatra L, Shenai P. Twin tooth on either side: a case report of bilateral gemination. *Ann Med Health Sci Res.* 2013 Apr;3(2):271-3.
- Milazzo A, Alexander SA. Fusion, gemination, oligodontia and taurodontism. *J Pedod.* Winter 1982;6(2):194-9.
- Barac Furtinger V, Skrinjaric I. Double Teeth in Primary Dentition and Findings of Permanent Successors. *Acta Stomatol Croat.* 1991;1:39-43.
- Hagman FT. Anomalies of form and number, fused primary teeth, a correlation of the dentitions. *ASDC J Dent Child.* Sep-Oct 1988;55(5):359-61.
- Badole GP, Shenoi PR, Parlikar A. Endodontic management of central incisor associated with large periapical lesion and fused supernumerary root: a conservative approach. *Restor Dent Endod.* 2018 Oct 26;43(4):e44.
- Knežević A, Travan S, Tarle Z, Šutalo J, Janković B, Čiglar I. Double tooth. *Coll Antropol.* 2002 Dec;26(2):667-72.
- Hamasha AA, Al-Khateeb T. Prevalence of fused and geminated teeth in Jordanian adults. *Quintessence Int.* Jul-Aug 2004;35(7):556-9.
- Ozden B, Gunduz K, Ozer S, Oz A, OtanOzden F. The multidisciplinary management of a fused maxillary central incisor with a talon cusp. *Aust Dent J.* 2012;57(1):98-102.
- Hans MK, Shetty S, Chopra H. Bilateral fusion of permanent maxillary incisors. *Indian J Dent Res.* 2011 Jul-Aug;22(4):603-5.
- Kühnisch J, Anttonen V, Duggal MS, Spyridonos ML, Rajasekharan S, Sobczak M, Stratigaki E, Van Acker JWG, Aps JKM, Horner K, Tsiklakis K. Best clinical practice guidance for prescribing dental radiographs in children and adolescents: an EAPD policy document. *Eur Arch Paediatr Dent.* 2020 Aug;21(4):375-386.

16. Tsujino K, Shintani S. Management of a supernumerary tooth fused to a permanent maxillary central incisor. *Pediatr Dent*. May-Jun 2010;32(3):185-8.
17. Rajab LD, Hamdan MA. Supernumerary teeth: review of the literature and a survey of 152 cases. *Int J Paediatr Dent*. 2002 Jul;12(4):244-54.
18. Srivastava N. Fused supernumeraries in deciduous dentition: a case report. *J Indian Soc Pedod Prev Dent*. 2003 Mar;21(1):35-6.
19. Cho SY. Primary double tooth: report of a rare correlation with the permanent dentition. *Prim Dent Care*. 2007 Apr;14(2):48-50.