

Histochemistry of complex glycoproteins in the digestive tract mucosa of Atlantic bluefin tuna (*Thunnus thynnus* L.)

Zvonimir Kozarić^{1*}, Snježana Kužir¹, Zdravko Petrincec², Emil Gjurčević²,
Nikša Baturina³

¹Department of Anatomy, Histology and Embryology, Faculty of Veterinary Medicine, University of Zagreb, Zagreb, Croatia

²Department for Biology and Pathology of Fish and Bees, Faculty of Veterinary Medicine, University of Zagreb, Zagreb, Croatia.

³County Veterinary Inspector, County of Šibenik and Knin, Croatia

KOZARIĆ, Z., S. KUŽIR, Z. PETRINEC, E. GJURČEVIĆ, N. BATURINA: Histochemistry of complex glycoproteins in the digestive tract mucosa of Atlantic bluefin tuna (*Thunnus thynnus* L.). Vet. arhiv 77, 441-452, 2007.

ABSTRACT

The histological structure, as well as content and distribution of glycoproteins (GPs) in the digestive tract mucosa, of the Atlantic bluefin tuna were studied. The digestive tract is short in accordance with their predatory nature and consists of the oesophagus, stomach and intestine. The short oesophagus has deep longitudinal folds and contains an abundance of secretory cells which synthesize a large quantity of neutral as well as sulphated and silylated GPs. The stomach is an elongated sac-like structure with simple tubular glands surrounded by connective tissue. The neck cells of gastric glands synthesize a mixture of neutral and acidic GPs. The intestine is short with many intestinal villi. Many goblet cells are situated between superficial epithelial cells. The intestinal goblet cells were shown to secrete both neutral and acidic GPs.

Key words: Atlantic bluefin tuna, digestive tract, histology, mucosubstances, histochemistry

Introduction

The fish digestive tract shows a marked diversity of both morphology and function. This is in correlation with the different feeding habits as well as with the body shape (RAY and MOITRA, 1982; BUDDINGTON et al., 1997). Presence of mucosubstances in the digestive tract mucosa has been observed in most teleosts (DOMENEGHINI et al., 1998b; DOMENEGHINI et al., 1999; DOMENEGHINI et al., 2002). The gut mucins lubricate and protect the tunica mucosa against chemicals, parasites and acidity and form a diffusion

*Contact address:

Prof. Dr. Zvonimir Kozarić, Department of Anatomy, Histology and Embriology, Faculty of Veterinary Medicine, University of Zagreb, Heinzelova 55, 10000 Zagreb, Croatia. Phone: +385 1 2390 151; Fax: +385 1 2441 390; E-mail: kozaric@vef.hr

barrier for various ions (VEGETTI et al., 1999). MURRAY et al. (1994) suggest that mucins in the posterior oesophagus of some fish may play a role in pregastric digestion. FIERTAK and KILARSKI (2002) concluded that glycoconjugate composition of the Cyprinid digestive tract depends on the species and on the intestinal region and that there is no correlation between its composition and type of ingested food.

Bluefin tuna is an active predator that feeds mainly on fish, but cephalopods, crustaceans and molluscs could also comprise their food (MOROVIĆ, 1961; KYRTATOS, 1982; SANZ BRAU, 1990).

The purpose of the present study is to describe histology and histochemical distribution and quantity of GPs in the digestive tract of the Atlantic bluefin tuna, a commercially important reared fish species.

Materials and methods

Ten adult Atlantic bluefin tuna (*Thunnus thynnus* L.) weighing 120-180 kg were obtained from the Drvenik fish farm (Croatia). They were fed live fish. Samples of the digestive tract (the oesophagus, stomach and middle part of the intestine) were taken after dissection, fixed in buffered 10% formalin and embedded in paraffin. Dewaxed sections (8 µm) were stained with haematoxylin and eosin (HE) for general histological purposes. Periodic acid-Shiff (PAS) (McMANUS, 1948) was used to demonstrate neutral glycoconjugates. Alcian blue (AB) at pH 2.5 and 1.0 (LEV and SPICER, 1964) and metachromasia with toluidine blue (TB) were used to demonstrate various kinds of acid glycoconjugates (PEARSE, 1968).

Results

Oesophagus. The tunica mucosa shows deep longitudinal folds that extend across the entire length of the oesophagus. Differentiation exists between major and minor folds. The mucosa is lined with a type of stratified epithelium. Two basic cell types are present in the epithelial layer: basal and superficial epithelial cells, as well as saccular mucous cells. The most prominent and distinctive feature of the oesophagus epithelium is the presence of numerous mucous cells. These cells occupy almost the entire thickness of the epithelium. The epithelium rests on a thin but prominent basement membrane. The lamina propria is composed of connective tissue containing mostly collagen fibres, numerous flattened fibroblasts and other connective tissue cells. The histochemical methods employed showed high PAS-positive, AB (pH 2.5)-positive as well as TB metachromatic GPs in these cells. Furthermore, AB (pH 1.0)-positive content was observed only in mucous cells at the base of the folds (Fig. 1, 2, and 3).

Stomach. The tunica mucosa of the stomach exhibits characteristic longitudinal folds of epithelium and underlying connective tissue. The tunica mucosa is lined with simple

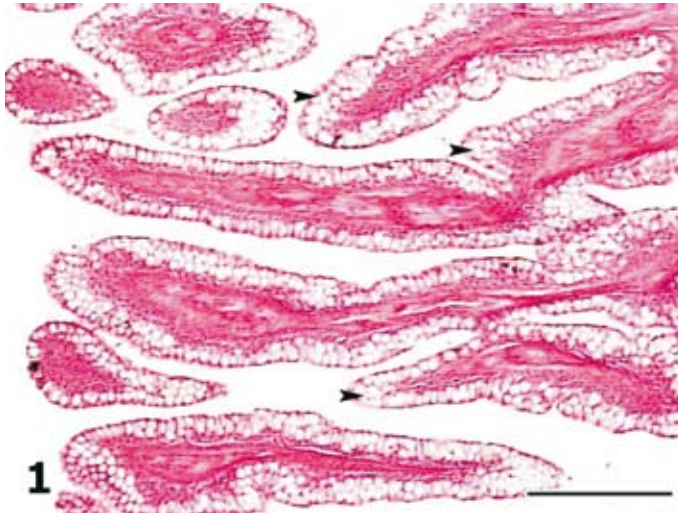


Fig. 1. Atlantic bluefin tuna, oesophagus is lined with stratified epithelium with many mucous cells (arrow head). H&E; scale bar = 200 μ m.

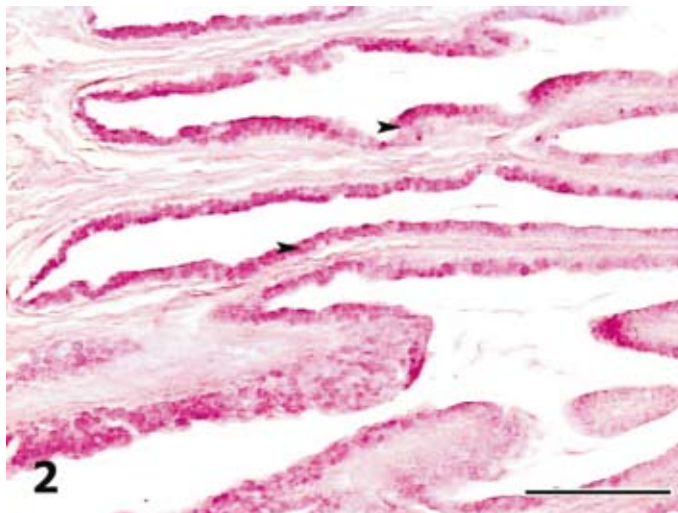


Fig. 2. Atlantic bluefin tuna, oesophagus, intensive stained mucous cells of mucosa (arrow head). PAS; scale bar = 200 μ m.

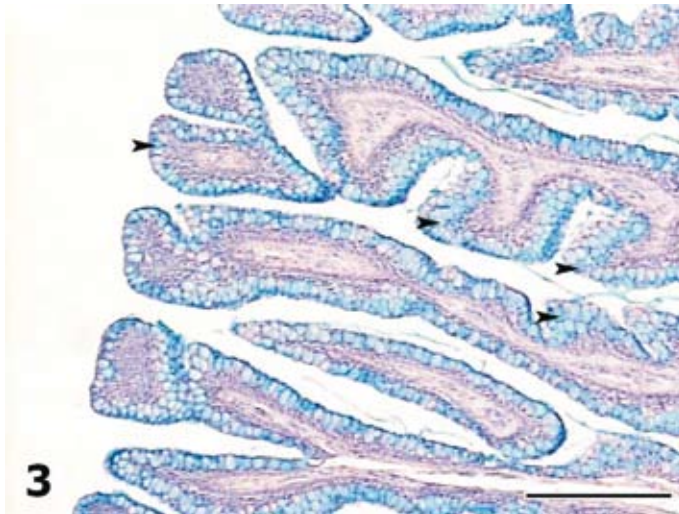


Fig. 3. Atlantic bluefin tuna, oesophagus, AB (2.5), mucous cells show strong AB reaction (arrow head). Scale bar = 200 μ m.

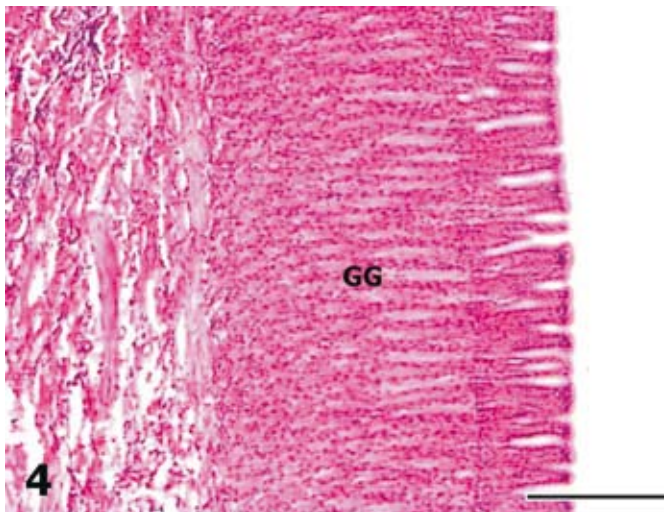


Fig. 4. Atlantic bluefin tuna, stomach gastric glands (GG). H&E; scale bar = 200 μ m.

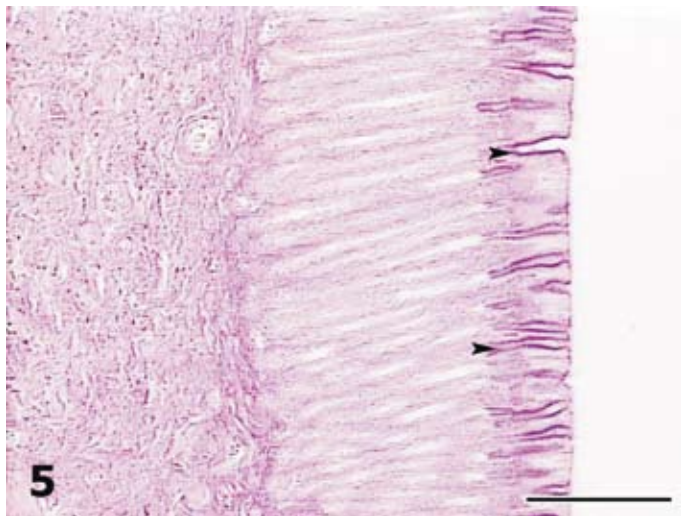


Fig. 5. Atlantic bluefin tuna, stomach, PAS-positive GPs are present in apical cytoplasm of epithelial cells as well as in neck cells (arrow head). PAS; scale bar = 100 μ m.

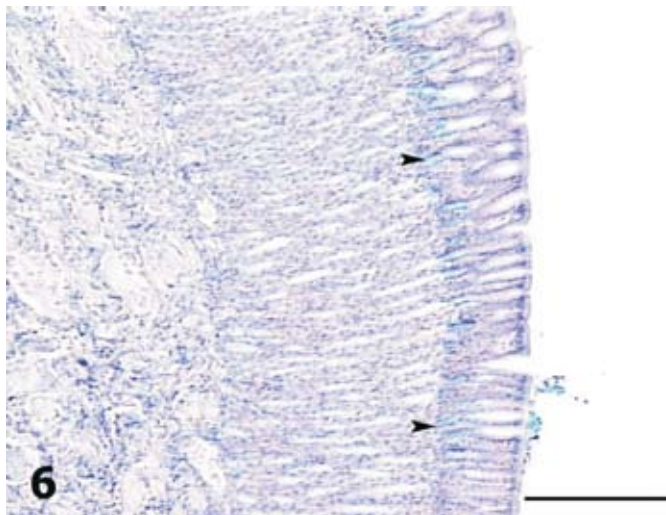


Fig. 6. Atlantic bluefin tuna, stomach, AB (2.5), acid GPs are visible in apical cytoplasm of epithelial cells as well as in neck cells (arrow head). Scale bar = 200 μ m.

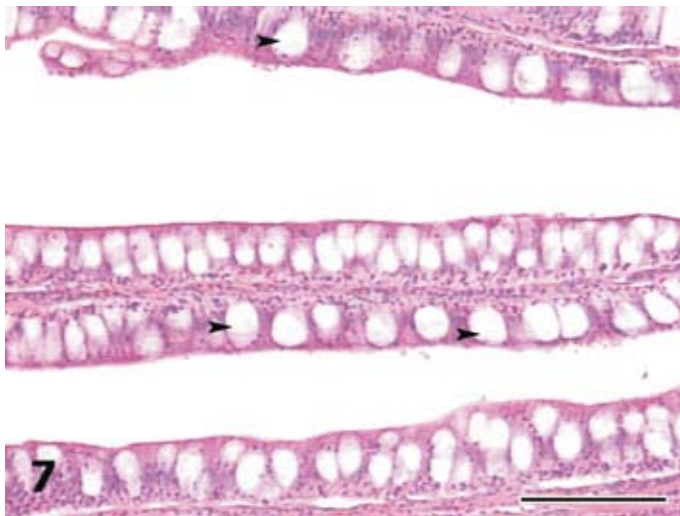


Fig. 7. Atlantic bluefin tuna, intestine, goblet cells (arrow head). H&E; scale bar = 200 μ m.

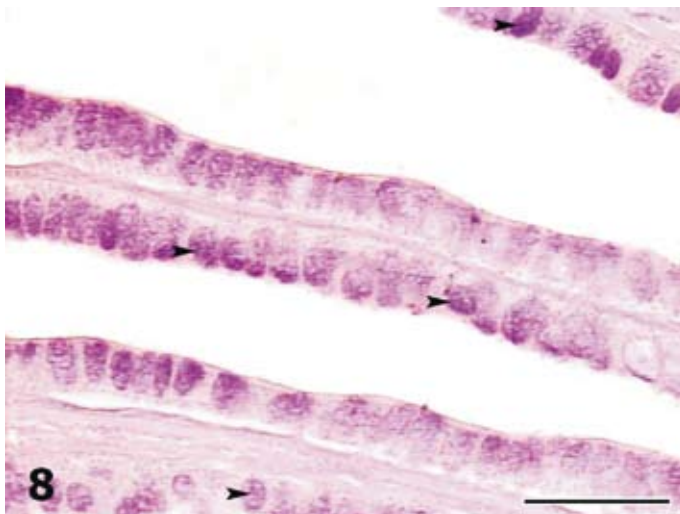


Fig. 8. Atlantic bluefin tuna, intestine, goblet cells contain neutral GPs. (arrow head). PAS; scale bar = 200 μ m.

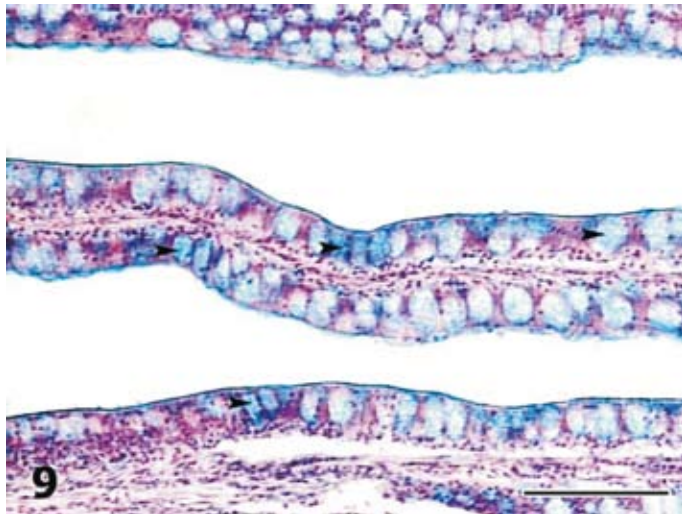


Fig. 9. Atlantic bluefin tuna, intestine, AB (2.5), acid GPs in goblet cells (arrow head).
Scale bar = 200 μ m.

columnar epithelium without mucous cells. The lamina propria possesses straight tubular glands consisting of single-type cells with fine granular cytoplasm. Gastric glands open into the crypts of the mucosal folds by a short neck. The apical part of the epithelial lining cells as well as the neck cells of the gastric glands show PAS and AB (pH 2.5) positive GPs. There is no presence of any kind of GPs in gastric glands (Fig. 4, 5, and 6).

Intestine. The intestine is short and of uniform histological structure throughout its entire length. The mucosa is folded into long and thin intestinal villi. Two basic types of cells are present in this epithelial layer: absorptive or columnar cells, and goblet cells. Typical goblet cells are the prominent component of the intestinal epithelium. The goblet cells are sandwiched between the absorptive cells and stain intensively with all histochemical methods employed (Fig. 7, 8, and 9).

Discussion

Mucous cells in fish oesophagus differentiate early during embryonic development and their appearance corresponds to the opening of the mouth. Mucous cells are found early in the developing oesophagus of *Sparus aurata* (DOMENEGHINI et al., 1998). Over that period, the cells are PAS negative but stained with alcian blue, and contain acid GPs only.

The oesophagus mucosa of the Atlantic bluefin tuna is lined with epithelium with numerous mucous cells. The mucous cells appear to have different secretions, stained with PAS and AB at both pH values. Acid, non-sulphated GPs containing sialic acid are stained metachromatically and appear red-purple. Periodic acid-Schiff and alcian blue positive mucous cells of the fish oesophagus were described by SCOCCO et al. (1998); DOMENEGHINI et al. (1999) and PARILLO et al. (2004). A large quantity of PAS-positive substances in mucous cells of Atlantic bluefin tuna point to the presence of GPs with oxidizable vicinal diols and/or glycogen. Acid mucosubstances stained with AB (2.5) and TB-metachromatic suggest the presence of GPs with sialic acid and GPs with O- sulfate esters. The sulphomucins present in the oesophagus would confer high viscosity to the mucus, which aids in trapping small particles (TIBBETTS, 1997).

The stomach of the Atlantic bluefin tuna shows uniform histological features. Superficial epithelial cells and simple tubular gastric glands in lamina propria form the mucosa. Gastric glands are arranged as straight tubular glands surrounded by connective tissue. A similar arrangement of gastric glands has been observed in other fish (DOMENEGHINI et al., 1998). The epithelial cells, as well as neck cells of gastric glands, show presence of neutral and acid GPs. The acid GPs are chiefly of the carboxylate and sialylated type. Neutral GP-s identified in the apical portion of the epithelial lining cells and in the gastric pits of the stomach of the Atlantic bluefin tuna could serve to protect the underlying mucosa layer from the acid environment and proteolysis and may also be involved in digestive activity, by easily absorbing digested substances, such as disaccharides and short-chain fatty acids (GRAU et al., 1992). The mucosubstances facilitate the movement of large-sized food particles as well as protecting the gastric mucosa from mechanical injury. The presence of both neutral and acid mucosubstances were observed in superficial gastric epithelium of the white sturgeon (DOMENEGHINI et al., 1999), and developing larvae and adults of *Sparus aurata* (DOMENEGHINI et al., 1998).

The tubular gastric glands of bluefin tuna show the presence of only one type of secretory cells, but no presence of any kind of GPs. Many authors agree that the gastric glands of teleosts contain only one type of secretory cells (RAY and MOITRA, 1982; GISBERT et al., 1999). ARELLANO et al. (2001) reported the presence of light and dark cells in the gastric glands of *Solea senegalensis*. It is generally thought that fish gastric glands synthesize both pepsinogen and acid (SMITH, 1989) and that neutral mucosubstances have a buffering effect on high acidity of the stomach contents (SCOCCO et al., 1996).

The intestine of bluefin tuna shows a uniform histological structure throughout its entire length. The intestinal mucosa consists of a single layer of columnar cells with many mucous goblet cells. The intestinal goblet cells synthesize neutral and acidic GPs. The acid GPs contain sialic acid and sulphated esters. A large amount of TB metachromatic substances in goblet cells points to the presence of sialic acid-rich nonsulfated GPs.

First goblet cells can be observed early during the differentiation of the fish intestinal mucosa (GARCIA HERNANDEZ et al., 2001). Presence of mucous-producing goblet cells in the intestinal mucosa has been reported in many fish studied earlier (NARASIMHAM and PARVATHESWARAO, 1974; RAY and MOITRA, 1982; DOMENEGHINI et al., 1998; NACHI et al., 1998; DOMENEGHINI et al., 1999; MORRISON and WRIGHT, 1999). The mucous secreted by goblet cells in the intestine may have many functions. Acid GPs have been shown to coincide with increased viscosity of mucus in the fish alimentary tract (TIBBETTS, 1997) and lubricate the undigested materials for onward progression into the rectum. NARASIMHAM and PARVATHESWARAO (1974) suggested a possible role of intestinal mucins in osmoregulation. The studies of RIBELLES et al. (1995) have shown that the quality of gut mucosubstances is directly related to environmental conditions, which in turn may directly affect the function of the alimentary tract. The presence of mucosubstances, especially those sulphated in the intestine, possibly regulates the transfer of proteins or a fragment of them, as well as of ions and fluids (SIRE and VERNIER, 1992; SEGNER et al., 1994; DOMENEGHINI et al., 1998). A possible role of mucosubstances in intestinal absorption processes is supported by the findings of BOŽIĆ et al. (2001) who observed that starvation induces an increase in the number of intestinal goblet cells in carp. PARILLO et al. (2004) hypothesize that the sulphated GP-s may be involved in the processes of morphofunctional differentiation of the alimentary tract of *Umbrina cirrosa* fry.

This investigation, as well as previous ones, demonstrates that the quality of gut mucosubstances varies in different regions of the Atlantic bluefin tuna alimentary canal and sustains functional harmony of the digestive tract.

Acknowledgements

The authors would like to thank the Drvenik Fish Farm for providing the material for investigation. This study was supported by the Ministry of Sciences, Education and Sport, Republic of Croatia.

References

- ARELLANO, J. M., V. STORCH, C. SARASQUETE (2001): Histological and histochemical observations in the stomach of the Senegal sole, *Solea senegalensis*. *Histol. Histopathol.* 16, 511-521.
- BOŽIĆ, F., E. SREBOČAN, Z. KOZARIĆ (2001): Starvation- induced pathobiology in the gut of carp (*Cyprinus carpio* L.). *Berl. Münch. Tierärztl. Wochr.* 114, 134-138.
- BUDDINGTON, R. K., Å. KROGDAHL, A. M. BAKKE-Mc KELLEP (1997): The intestines of carnivorous fish: structure and function and the relations with diet. *Acta Physiol. Scand.* 161 (*Suppl.* 638), 67-80.

- DOMENEGHINI, C., R. PANNELLI STRANINI, A. VEGGETTI (1998): Gut glycoconjugates in *Sparus aurata* L. (Pisces, Teleostei). A comparative histochemical study in larval and adults ages. *Histol. Histopathol.* 13, 359-372.
- DOMENEGHINI, C., S. ARRIGHI, G. RADAELLI, G. BOSI, G. S. MASCARELLO (1999): Morphological and histochemical peculiarities of the gut in white sturgeon, *Acipenser transmontanus*. *Eur. Histochem.* 43, 135-145.
- DOMENEGHINI, C., G. RADAELLI, S. ARRIGHI, A. Di GIANCAMILLO, M. PAZZAGIA, F. MASCARELLO (2002): Morphological and histochemical differences in the structure of alimentary canal in feeding and runt (feed deprived) white sturgeon (*Acipenser transmontanus*). *J. Appl. Ichthyol.* 18, 341-346.
- FIERTAK, A., W. M. KILARSKI (2002): Glycoconjugates of the intestinal goblet cells of four cyprinids. *Cell. Mol. Life Sci.* 59, 1724-1733.
- GARCIA HERNÁNDEZ, M. P., M. T. LOZANO, M. T. ELBAL, B. AGULLEIRO (2001): Development of the digestive tract of sea bass (*Dicentrarchus labrax* L.). Light and electron microscopic studies. *Anat. Embr.* 204, 39-57.
- GISBERT, E., M. C. SARASQUETE, P. WILLIOT, F. CASTELLO-ORVAY (1999): Histochemistry of the development of the digestive system of Siberian sturgeon during early ontogeny. *J. Fish Biol.* 55, 596-616.
- GRAU, A., S. CRESPO, M. C. SARASQUETE, M. L. GONZALES DE CANALES (1992): The digestive tract of the amberjack *Seriola dumerii* Risso: a light and scanning electron microscope study. *J. Fish Biol.* 41, 287-303.
- KYRTATOS, N. A. (1982): Investigation on fishing and biology of the most important fishes of the region around the Aegean Sea. *Island of Tinos. Thalassogeographica* 5, (spec. publ.) 88.
- LEV, R., S. S. SPICER (1964): Specific staining of sulphate groups with alcian blue et low pH. *J. Histochem. Cytochem.* 12, 309.
- McMANUS, J. F. A. (1948): Histological and histochemical uses of periodic acid. *Stain Technol.* 23, 99-108.
- MOROVIĆ, D. (1961): Contribution to the knowledge of the nutrition of blue-fin tuna (*Thunnus thynnus* L.) in the Adriatic from fishes caught with ring nets. *Proceedings and Technical Papers of the General Fisheries Council for the Mediterranean* 6, 155-157.
- MORRISON, C. M., J. R. WRIGHT Jr (1999): A study of the histology of the digestive tract of the Nile tilapia. *J. Fish Biol.* 54, 597-606.
- MURRAY, H. M., G. M. WRIGHT, G. P. GOFF (1994): A study of the posterior oesophagus in the winter flounder, *Pleuronectes americanus*, and the yellow tail flounder, *Pleuronectes ferrugineus*: morphological evidence of pregastric digestion? *Canad. J. Zool.* 72, 1191-1198.
- NARASIMHAM, C., V. PARATHESWARAO (1974): Adaptation to osmotic stress in a fresh-water euryhaline teleost, *Tilapia mossambica*. X. Role of mucopolysaccharides. *Acta histochem.* 51, 37-49.

- PARILLO, F., A. M. GARGIULO, O. FAGIOLI (2004): Complex carbohydrates occurring in the digestive apparatus of *Umbrina cirrosa* (L.) fry. *Vet. Research Comm.* 28, 267-278.
- PEARSE, A. E. G. (1968): *Histochemistry. Theoretical and Applied.* J. & A. Churchill Ltd. London.
- RAY, A. K., S. K. MOITRA (1982): On the morpho-histology of the alimentary tract in the Indian Climbing Perch, *Anabas tautudineus* (Bloch), in relation to food and feeding habits. *Gegenbaurs morph. Jahrb.* 128, 778-798.
- RIBELLES, A., M. C. CARRASCO, M. ROSETY, M. ALDANA (1995): A histochemical study of the biological effects of sodium dodecyl sulfate on the intestine of the gilthead seabream, *Sparus aurata* L. *Ecotox. Environ. Safety* 32, 131-138.
- SANZ BRAU, A. (1990): Sur la nourriture des jeunes thons rouges *Thunnus thynnus* (L. 1758) des côtes du Golfe de Valence. *Rapports Commission internationale pour l'exploration scientifique de la mer Méditerranée* 32, 274.
- SCOCCO, P., D. ACCILI, G. MENGHI, P. CECCARELLI (1998): Unusual glycoconjugates in the oesophagus tilapine polyhybrid. *J. Fish Biol.* 53, 39-48.
- SCOCCO, P., P. CECCARELLI, G. MENGHI (1996): Glycohistochemistry of the *Tilapia* sp. stomach. *J. Fish Biol.* 49, 584-593.
- SENGER, H., V. STORCH, M. REINECKER, W. KLOAS, W. HANKE (1994): The development of functional digestive and metabolic organs in turbot, *Scophthalmus maximus*. *Mar. Biol.* 119, 471-486.
- SIRE, M. F., J. M. VERNIER (1992): Intestinal absorption of protein in teleost fish. *Com. Biochem. Physiol.* 103A, 771-781.
- SMITH, L. S. (1989): Digestive functions in teleost fishes. In: *Fish nutrition*, 2nd ed. (Halver, J. E., Ed.). Academic Press London. pp. 331-421.
- TIBBETTS, I. R. (1997): The distribution and function of mucous cells and their secretions in the alimentary tract of *Arrhamphus sclerolepis* Kreffti. *J. Fish Biol.* 50, 809-820.
- VEGGETTI, A., A. ROWLERSON, G. RADAELLI, S. ARRIGHI, C. DOMENEGHINI (1999): Post-hatching development of the gut and lateral muscle in the sole, *Solea solea* (L.). *J. Fish Biol.* 55 (Suppl. A), 44-65.

Received: 24 May 2005

Accepted: 28 September 2007

KOZARIĆ, Z., S. KUŽIR, Z. PETRINEC, E. GJURČEVIĆ, N. BATURINA: Histokemija složenih mukopolisaharida sluznice probavnoga trakta tune (*Thunnus thynnus* L.). *Vet. arhiv* 77, 441-452, 2007.

SAŽETAK

Istražena je histologija i histokemija složenih mukopolisaharida sluznice probavnoga trakta tune (*Thunnus thynnus* L.). Probavna cijev tune je relativno kratka što je u skladu s njezinim načinom prehrane i sastoji se od jednjaka, želuca i kratkoga crijeva. Jednjak je kratak s duboko naboranom sluznicom. U epitelu sluznice nalaze se mnoge jednostanične žlijezde sa sadržajem koji pokazuje histokemijske značajke neutralnih, sulfatnih

Z. Kozarić et al.: Histochemistry of complex glycoproteins in the digestive tract mucosa of Atlantic bluefin tuna (*Thunnus thynnus* L.)

i sijaličnih mukopolisaharida. Želudac je vrećasta struktura s mnogim tubuloznim žlijezdama u lamini propriji. Prisutnost neutralnih i kiselih mukopolisaharida opaža se samo u vratnom dijelu žlijezda. Crijevo je prekriveno brojnim resicama s mnogim vrčastim stanicama ispunjenim neutralnim i kiselim mukopolisaharidima.

Ključne riječi: tuna, probavni trakt, histologija, mukopolisaharidi, histokemija
