

# ENTEROCOCCUS FAECALIS CORNEAL ULCERS WITH ENDOPHTHALMITIS AND CONSEQUENT BILATERAL BLINDNESS AS A RESULT OF UNRECOGNISED INTENTIONAL SELF-INJURY - A CASE REPORT

Sanja Masnec<sup>1,2</sup>, Sania Vidas Pauk<sup>1</sup>, Mia Jurilj<sup>3</sup>, Miro Kalauz<sup>1,2</sup>, Tomislav Kuzman<sup>1,2</sup>,  
Ivan Škegro<sup>1,2</sup>, Tomislav Jukić<sup>1,2</sup>, Sonja Jandroković<sup>1,2</sup>,  
Sven Seiwert<sup>4</sup> & Marija Barišić Kutija<sup>1</sup>

<sup>1</sup>Department of Ophthalmology, Zagreb University Hospital Center, Zagreb, Croatia

<sup>2</sup>School of Medicine, University of Zagreb, Zagreb, Croatia

<sup>3</sup>Department of Neurosurgery, University Hospital Center Sestre Milosrdnice, Zagreb, Croatia

<sup>4</sup>Department of Pathology, School of Medicine, University of Zagreb, Zagreb, Croatia

\* \* \* \* \*

## INTRODUCTION

Corneal and conjunctival inflammation accompanied with scarring and neovascularization is a final and advanced stage of numerous etiologically different severe anterior eye conditions - infectious, inflammatory, mechanical, chemical, iatrogenic, congenital, etc., but it can also be part of severe systemic diseases, which can also target the eye - disorders of autoimmune etiology, Stevens-Johnson syndrome (SJS), systemic infections, etc. Lastly, different forms of self-injury due to psychiatric disorders (obsessive-compulsive disorder, psychosis, etc.) might also be considered, especially in cases of nonspecific progressive anterior eye damage of unresolved and unclear etiology (American Academy of Ophthalmology 2014a, American Academy of Ophthalmology 2014b, Rau 2008). Due to the whole spectrum of possible differential diagnoses, it is often hard to set the proper one. Unfortunately, undiagnosed and inadequately treated advanced anterior eye disease can result in permanent and severe destruction of eye structures and functions.

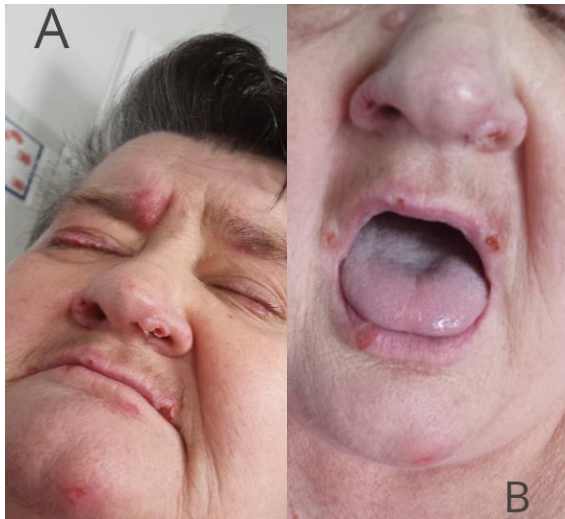
This case report presents a patient with severe bilateral progressive corneal ulcers and consequently bilateral blindness caused by a rare condition – unrecognized intentional self-injury since the patient denied this behavior and ignored the recommended psychiatric assessment. A team approach and thorough evaluation are essential to set the proper and timely diagnosis in cases with unresolved or unclarified etiology with constant deterioration of symptoms and clinical findings. Sometimes it is necessary to take steps such as deprivation of legal capacity, surveillance, or involuntary hospitalization due to psychiatric and other medical support. In our case, this might have prevented bilateral blindness in an already handicapped patient. Extreme obesity and, therefore, immobility of the patient are additional problems but should not be an obstacle to the availability of good quality medical care.

## CASE PRESENTATION

A 56-year-old woman was admitted to our hospital in September 2015 due to a rapidly developing and progressive corneal ulcer in the left eye. She was obese (BMI 47 kg/m<sup>2</sup>), otherwise healthy. Before the appearance of her symptoms, that same year in March, she underwent spa weight loss and face beauty treatments. In April, she started noticing visual acuity impairment in both eyes and reported her vision as “blurry”. An ophthalmologist in her hometown diagnosed and treated her with an initial diagnosis of unspecific keratoconjunctivitis. Her condition improved, however, adherence to control examinations was very low. In January 2015, due to ongoing pain in her shoulders, a doctor prescribed diclofenac twice a day. After ten days, skin vesicles, crusts and exfoliations appeared on her abdominal skin and fingers. She also complained of deterioration of her visual acuity on both eyes and pain in her left eye.

When she was admitted to our Ophthalmology Department, her best-corrected visual acuity was 0.7 logMAR on the right eye and counting fingers at 1 meter on the left eye. Clinical findings on the right eye were mild conjunctival hyperemia with superficial punctate keratopathy. Examination of the left eye revealed a corneal ulcer, radial superficial blood vessels on the cornea, and severe conjunctival reaction. Tear break-up time on both eyes was 6 seconds, and the Schirmer test with topical anesthesia was within normal limits, as well as other ocular findings. Her lid margins on the left eye were erythematous, accompanied by tarsal conjunctiva papillary reaction, and nodular and ulcerative, erythematous eyelid skin lesions with central crusts. Similar skin lesions were also detected on earlobes, brows, left nostril, lips, and abdominal skin (Figures 1A and 1B).

Recent drug usage (medical history of taking diclofenac) and rapid progression of the constellation of

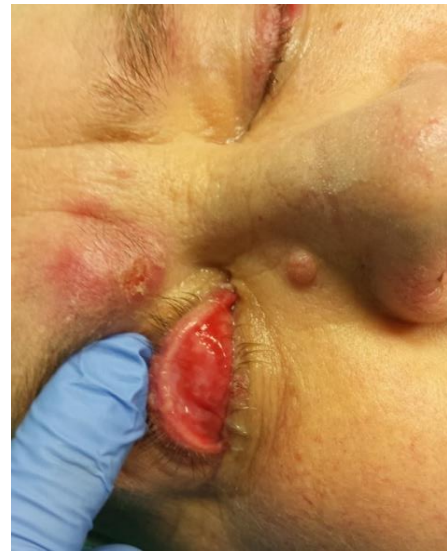

**Figure 1.** Distribution of face skin lesions placed on eyelids, brows, left nostril and both lips. They have a nodular appearance with central crust and ulceration. Oral mucosa is normal

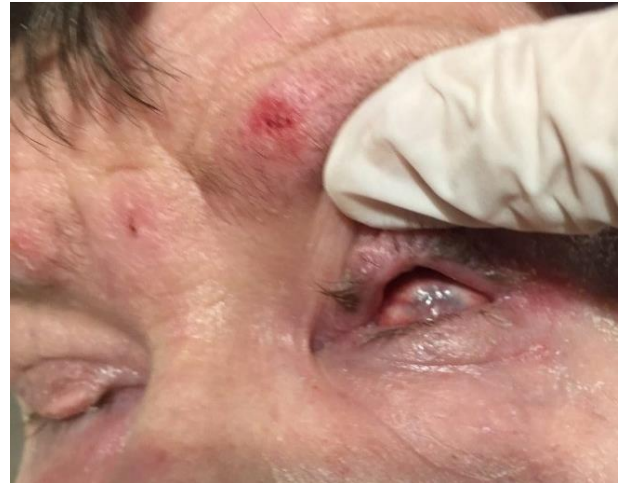symptoms and signs raised concern for Stevens-Johnson syndrome (SJS). Earlobe, skin, and lower lip mucosa biopsies were performed. The pathology report did not show any complement or antibody (immunoglobulin) deposits, and tissue changes were described as unspecific with no signs of vacuolar degeneration of the basal epidermis. Results of allergy tests (diclofenac) were also negative. Therefore, SJS was excluded. Acanthamoeba was suspected due to a history of spa treatments, but repeated corneal scrapings and conjunctival swabs were negative. In meanwhile, corneal swab and culture revealed *Enterococcus faecalis* (*E. faecalis*) in her left eye. During hospitalization, topical therapy according to antibiogram was included: tobramycin drops and ointment and artificial tears for her right eye and fortified ampicillin drops, ciprofloxacin eye drops, betadine 5%, artificial tears, and subconjunctival dexamethasone injections for her left eye.

Other systemic diseases, as the cause of the patient's eye condition, were considered. During hospitalization, the patient was evaluated by a dermatologist, immunologist, internist, and otolaryngologist. Laboratory results regarding complement C3 and C4 components, anti-nuclear antibody (ANA), anti-dsDNA, SS-A, SS-B, ANCA, and antibodies came negative. The ELISA desmoglein and bullous pemphigoid antibodies were negative (Dsg1, Dsg3, BP 180, BP 230), which excluded autoimmune bullous diseases and other systemic immunological disorders such as systemic lupus erythematosus and other connective tissue diseases. According to clinicians, changes in her skin were most likely from self-manipulation, but the patient decisively denied it.

When the left cornea showed substantial improvement, she was referred to the ophthalmologist in her hometown and recommended to use local antibiotics



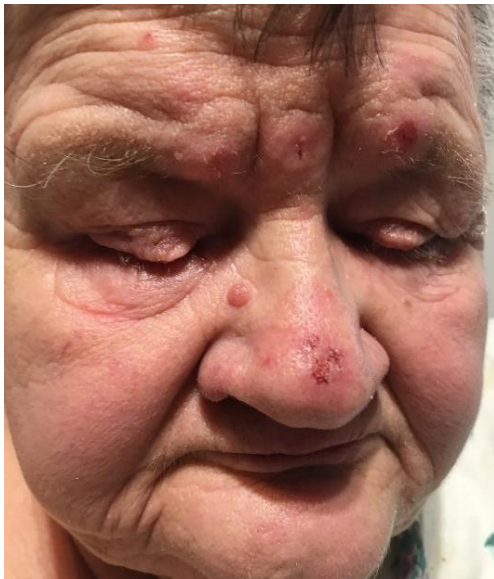**Figure 2.** Papillary reaction and scarring of tarsal conjunctiva. Typical skin lesion on the base of the eyelashes



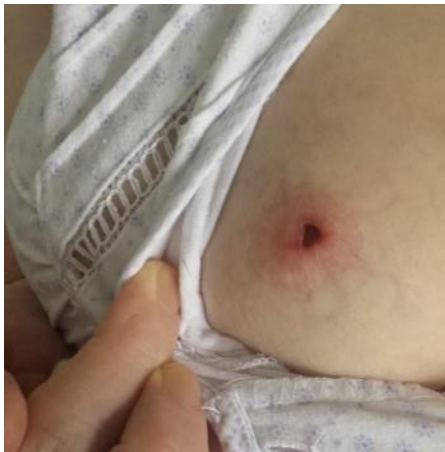**Figure 3.** Left eye corneal scarring with superficial and deep stromal vessels and ocular surface inflammation

and intensive artificial tears therapy. The right eye showed no pathological findings on discharge from the hospital. The patient ignored the recommended follow-up examination until she noticed deterioration.

She was admitted to our Clinic for the second time in November 2015 due to a corneal ulcer of the right eye. The best-corrected visual acuity on the right eye was hand movements and on the left eye light perception. Eyelids of her right eye and her right cornea now appeared the same as earlier described in the left eye, which in the meanwhile progressed to corneal scarring and diffuse superficial and deep stromal vessels (Figures 2 and 3). Fundus wasn't obtained due to anterior segment changes, but ultrasound scans of both eyes and eye cavities did not show any specific pathology. Facial and body skin showed more epidermal lesions and erythematous infiltrations than before (Figures 4 and 5). Part of her right earlobe was missing (Figure 6).

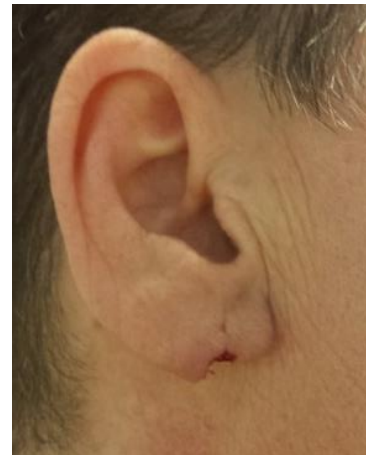

**Figure 4.** Nodular lesions on upper eyelids and multiple excoriations of facial skin

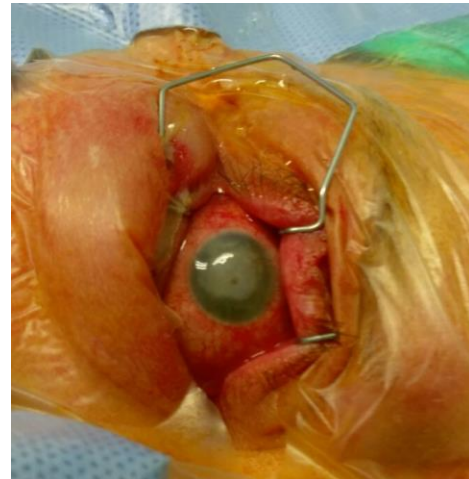

**Figure 5.** Ulcerative skin lesions on breasts

The serologic studies for infectious etiology included herpes simplex and zoster viruses, cytomegalovirus, Epstein-Barr virus, *Treponema pallidum*, *Borrelia burgdorferi*, tuberculosis, or human immunodeficiency virus infection were negative. Pathohistological findings of nostril skin, right eyelid, and normal buccal mucosa again showed unspecific skin granulomatous changes and normal mucosa. Once again, corneal and multiple skin lesion cultures from the right eye were positive to *E. faecalis*. Initially, the same fortified antibiotic therapy was given to her as previously described for the left eye, and amniotic membrane transplantation was performed. Unfortunately, she developed right eye endophthalmitis (Figure 7). The anterior chamber and vitreous humor culture were also positive to *E. faecalis*. PCR of aqueous humor was negative to HSV 1, HSV 2, and VZV. Treatment included topical fortified vancomycin, ampicillin, intravenous and intravitreal antibiotics according to antibiogram.



**Figure 6.** Right earlobe tissue defect most likely caused by self-injury



**Figure 7.** Corneal ulcer and hypopyon of the right eye due to development of endophthalmitis

All these findings, negative biopsies, and *E. faecalis* positive cultures, once again, led us to suspect combined mechanical and infective damage of corneas and skin due to constant rubbing and scratching of her eyes and skin with unclean hands. However, the patient vehemently denied this behavior. Psychiatric care was also provided, she was diagnosed with the anxiety-depressive disorder, and appropriate therapy was administered. No signs of other psychiatric disorders and dissociated behaviors were found, while the patient denied them. She was discharged from the hospital after the resolution of eye inflammation. A thorough psychiatric assessment was recommended to be done in her hometown, but she ignored it. Later on, her BMI increased to 65 kg/m<sup>2</sup>, which made her immobile.

In the further treatment course at our Clinic, she was hospitalized several times, and all intentions were directed towards restoring her vision. Penetrating keratoplasty (PKP) and cataract surgery were performed on both eyes. Despite systemic corticosteroid therapy, she developed repetitive corneal graft rejection. After many

persistent hetero-anamnestic questions, the patient's sister, who took care of her lately, confessed that the patient constantly inflicted wounds on her skin all over her body (intentionally tearing off pieces of skin with her fingernails) and her eyes. Unfortunately, the final confirmation of the suspected diagnose was set too late because the patient ended up with poor outcomes: no light perception on the right eye and light perception on the left eye with phthisis of both eyes. She passed away in 2018 due to chronic respiratory failure as a consequence of morbid obesity.

## DISCUSSION

This is a unique case report of a patient who presented with severe ocular surface inflammation accompanied with bilateral *E. faecalis* corneal ulcers (complicated with right eye endophthalmitis) and unspecific ulcerative skin lesions all around her body, who ended up blind in a short period of time. When she was admitted to our Clinic for the first time, the condition in her left eye was already severe. Skin lesions on her eyelids, face, and body accompanied by eye pathology made us consider a systemic condition as the underlying cause of her current status. However, biopsy, immunological testing, serology testing, and diagnostic procedures refuted our diagnosis. Acanthamoeba infection was also suspected due to a history of spa treatments, but repeated corneal scrapings, conjunctival swabs, skin lesion cultures, as well as anterior chamber and vitreous humor cultures demonstrated only *Enterococcus faecalis*.

*E. faecalis* endophthalmitis accompanied with a corneal ulcer is a rare condition. It is mainly of post-traumatic, post-surgery, or endogenous origin (Chen 2021, Mundy 2000, Ejdervik-Lindblad 1992, Uchio 1992, Noh 2019, Kuriyan 2014, Kim 2003). *E. faecalis* is typically found in the urinary and gastrointestinal tract and rarely colonizes ocular structures and adjacent surfaces. Although enterococci have been considered to have relatively low virulence, they can cause serious infections such as endocarditis, sepsis, and vision-threatening endophthalmitis with poor visual outcomes due to increasing antimicrobial resistance (3). Visual acuity outcomes were generally poor, with no light perception in 50% of cases.

In our patient, simultaneous eye and skin conditions led us to perform a thorough diagnostic evaluation that significantly postponed the detection of true underlying cause of the disease. Intentional self-injury was suspected only when all other blood tests came up negative, pathohistological findings were unspecific and no endogenous cause for *E. faecalis* contamination was found (no sign of endocarditis, sepsis, or urinary tract infection). Moreover, even on psychiatric evaluation, the patient denied her destructive behavior and

potentially obsessive or psychotic behavior, so proper treatment could not be undertaken. Nevertheless, a further psychiatric assessment was recommended in her hometown after discharge from our hospital, which the patient ignored. Her primary care physician and relatives did not recognize the patient's poor cooperation and low adherence to recommended medical support. Later on, when she became blind, extremely obese and immobile, her sister started taking care of her and discovered that she constantly causes deep wounds on her skin and eyes by scraping deeply into the skin, tearing skin parts by pushing fingernails into her eyes and eyelids. Intentional self-injury caused by rubbing her eyes with dirty hands promoted ocular surface inflammation and inoculation of *E. faecalis*. A combination of constant mechanical eye surface trauma and *E. faecalis* infection resulted in severe, fulminant bilateral ocular corneal ulcers, right eye endophthalmitis, and ulcerative lesions of the eyelids, face, and body. Despite all the therapeutic, conservative, and surgical protocols taken, since the primary underlying cause of the disease (intentional chronic eye injury) was present too long, she ended up blind in several months.

## CONCLUSION

This case report highlights the importance of persistent and thorough team approach to come to the right underlying cause of the disease, especially in cases with rare diagnoses and additional aggravating circumstances such as patient's denial of specific behavior, immobility due to the morbid obesity and very poor adherence to recommended medical assessment and follow-up.

By setting the correct diagnosis timely, follow-up and treatment can be adequately guided before irreversible eye damage occurs. Although it is very rare, intentional self-injury disorder has to be considered in progressive ocular surface and skin damage with unresolved or unclarified etiology. However, if the patient is not cooperative and denies such behavior, it becomes a true diagnostic challenge. On the discharge from hospital, with recommendations in discharge letter, primary care physician takes over the crucial role to recognize an unreliable patient with severely endangered health and has to organize proper care – if necessary, all the way to deprivation of legal capacity, surveillance, or involuntary hospitalization due to psychiatric and other medical assessment and support. The patient's extreme obesity and immobility are significant additional problems that should not affect the treatment options and outcome. In our case, proper, timely assessment and care might have prevented bilateral blindness, which impaired patient's entire psychophysical systemic condition.

**Acknowledgements:** None.

**Conflict of interest:** None to declare.

**Contribution of individual authors:**

Sanja Masnec, Sania Vidas Pauk & Marija Barišić Kutija contributed to the manuscript's concept, design, and writing.

Sanja Masnec, Sania Vidas Pauk, Mia Jurilj, Miro Kalauz, Tomislav Kuzman, Ivan Škegro, Tomislav Jukić, Sonja Jandroković, Sven Seiwerth & Marija Barišić Kutija had substantial contributions to literature search and analysis, revised the manuscript critically for important intellectual content.

All authors approved the final version.

**References**

1. American Academy of Ophthalmology: *Clinical approach to ocular surface disorders*. In McGuire A (ed). *Basic and Clinical Science Course (BCSC) 2014-2015: External Disease and Cornea*. San Francisco: American Academy of Ophthalmology 2014a; 37-83
2. American Academy of Ophthalmology: *Structure and function of the external eye and cornea*. In McGuire A (ed). *Basic and Clinical Science Course (BCSC) 2014-2015: External Disease and Cornea*. San Francisco: American Academy of Ophthalmology 2014b; 3-11
3. Rau G, Seedor JA, Shah MK, Ritterband DC, Koplín RS: *Incidence and clinical characteristics of enterococcus keratitis*. *Cornea* 2008; 27:895-9. doi:10.1097/ICO.0b013e31816f633b.
4. Chen KJ, Lai CC, Chen HC, Chong YJ, Sun MH, Chen YP, et al.: *Enterococcus faecalis Endophthalmitis: Clinical Settings, Antibiotic Susceptibility, and Management Outcomes*. *Microorganisms* 2021; 9:918. doi:10.3390/microorganisms9050918
5. Mundy LM, Sham DF, Gilmore MS: *Relationship between enterococcal virulence and antimicrobial resistance*. *Clin Microbiol Rev* 2000; 13:513-522
6. Ejdervik-Lindblad B, Lindberg M, Hakansson E: *Enterococcal endophthalmitis following cataract extraction treated with ampicillin intravitreally*. *Acta Ophthalmol* 1992; 70:842-843
7. Uchio E, Inamura M, Okada K, Hatano H, Saeki K, Ohno S: *A case of endogenous Enterococcus faecalis endophthalmitis*. *Jpn J Ophthalmol* 1992; 36:215-221
8. Noh GM, Nam KY, Lee SU, Park ID, Lee SJ: *Recurrent Enterococcus faecalis Endophthalmitis*. *Korean J Ophthalmol* 2019; 33:200-201. doi:10.3341/kjo.2018.0071
9. Kuriyan AE, Sridhar J, Flynn HW Jr, Smiddy WE, Albini TA, Berrocal AM et al.: *Endophthalmitis caused by Enterococcus faecalis: clinical features, antibiotic sensitivities, and outcomes*. *Am J Ophthalmol* 2014; 158:1018-23. doi:10.1016/j.ajo.2014.07.038
10. Kim US, Yu SY, Kwak HW: *Two cases of Enterococcus faecalis endophthalmitis*. *J Korean Ophthalmol Soc* 2003; 44:523-528

Correspondence:

Prof. Miro Kalauz, MD, PhD  
Department of Ophthalmology, Zagreb University Hospital Center  
Kišpatićeva 12, 10 000 Zagreb, Croatia  
E-mail: miro.kalauz@gmail.com