

# Challenges in the diagnosis of mandible metastasis: a case report

## Izazovi u dijagnostici metastaza mandibule: prikaz slučaja

Sara Gudelj<sup>1\*</sup>, Margita Belušić-Gobić<sup>1,2</sup>

**Abstract. Aim:** To report the clinical course of a patient with long-lasting pain and swelling of mandible who was subsequently diagnosed with large cell neuroendocrine carcinoma (LCNEC) of the lung and to point out the importance of expanding the diagnostic approach.

**Case report:** A 61-year-old female patient was referred to the Department of maxillofacial surgery due to severe pain in the area of temporomandibular joint (TMJ) spreading to the upper and lower jaw. Physical examination revealed tenderness, swelling and pain of the preauricular area. MR imaging showed anterior disc displacement with degenerative signs on the left side which indicated arthrocentesis. It resulted with clinical improvement that lasted for 1.6 years. Newly made orthopantomogram revealed unclear changes of the left mandibular corpus. Due to the unclear diagnosis patient underwent biopsy on two occasions, which excluded IgG4 disease, other rheumatology and hematology diseases as well as the tumor. Five years after the initial admission, the patient stated the occasional dyspnea and cough leading to administration of the chest RTG, showing visible round mass in the upper left lobe of the lung. PET/ CT showed accumulation of radiopharmaceutical substance in the corresponded area, affected regional and distant lymph nodes and accumulation within mandible. Somatostatin receptor scintigraphy confirmed the diagnosis, which may indicate the possibility of distant malignancies. Wedge resection of the lung mass was performed and pathohistological examination confirmed the large-cell neuroendocrine carcinoma (LCNEC) stage 3. Chemotherapy was administrated. Patient referred to an emergency medical tract due to the threatening cardiac tamponade and died 11 days after. **Conclusions:** Mandibular metastases are often presented by atypical signs and symptoms and often present the first sign of the malignant disease. Broad spectrum of examinations must be performed in order to prove or exclude distant malignancies so the best therapy option can be provided.

**Key words:** carcinoma, neuroendocrine; lung neoplasms; mandible; neoplasm metastasis

**Sažetak. Cilj:** Cilj je ovog članka prikazati klinički tijek pacijentice s dugotrajnom boli i oticanjem donje čeljusti kojoj je naknadno dijagnosticiran neuroendokrini karcinom velikih stanica pluća (engl. *large-cell neuroendocrine carcinoma*; LCNEC) i ukazati na važnost proširenja dijagnostičkog pristupa. **Prikaz slučaja:** Šezdesetjednogodišnja pacijentica upućena je na Odjel za maksilofacijalnu kirurgiju zbog jakih bolova u području čeljusnog zgloba (engl. *temporomandibular joint*; TMJ) koji se šire na gornju i donju čeljust. Fizikalnim pregledom otkrivena je osjetljivost, otekline i bol preaurikularnog područja. MR snimanje pokazalo je anteriorni pomak diska s degenerativnim znakovima na lijevoj strani. Obavljena artrocenteza rezultirala je kliničkim poboljšanjem koje je trajalo 1,6 godina. Na novoučinjenim panoramskim snimkama čeljusti uočene su promjene nejasne etiologije, lijeve strane mandibule. Zbog nejasne dijagnoze, u dva navrata izvršena je biopsija kosti koja je isključila IgG4 bolest, druge reumatološke i hematološke bolesti, kao i tumor. Pet godina nakon početnog prijama, zbog pojave dispneje i kašlja upućuje se na radiogram (RTG) prsnih organa koji pokazuje vidljivu okruglu masu u gornjem lijevom režnju pluća. PET/CT je pokazao nakupljanje radiofarmaka u navedenom području, zahvaćene regionalne i udaljene limfne čvorove te akumulaciju unutar mandibule. Scintigrafija somatostatinskih receptora potvrdila je navedeno, što upućuje na mogućnost prisutnosti udaljenih metastaza u

<sup>1</sup> University of Rijeka, Faculty of Medicine, Rijeka, Croatia

<sup>2</sup> Clinical Hospital Center Rijeka, Department of Maxillofacial surgery, Rijeka, Croatia

**\*Dopisni autor:**

Sara Gudelj  
University of Rijeka, Faculty of Medicine  
Braće Branchetta 20, 51000 Rijeka, Croatia  
E-mail: sara.gudelj@student.uniri.hr

<http://hrcak.srce.hr/medicina>

području mandibule. Izvršena je klinasta resekcija plućne mase koja je patohistološkom analizom definirana kao neuroendokrini karcinom velikih stanica. Nakon dijagnostičke obrade aplicirana je kemoterapija. Nekoliko mjeseci nakon toga pacijentica se zaprima u ambulantu hitne pomoći zbog prijeteće tamponade srca te umire jedanaest dana nakon incidenta. **Zaključci:** Metastaze na donjoj čeljusti često se prezentiraju atipičnim znakovima i simptomima te mogu predstavljati prvi znak zloćudne bolesti. Detaljnom kliničkom obradom potrebno je dokazati ili isključiti maligne metastaze kako bi se pacijentima pružila najbolja moguća skrb.

**Ključne riječi:** karcinom pluća; mandibula; metastaze; neuroendokrini tumori

Jawbones are a rare site for metastases from primary malignant tumours elsewhere in the body. As certain types of lung cancer are more likely to cause metastatic disease, they must be included in differential diagnosis especially in patients with history of jaw pain and swelling.

## INTRODUCTION

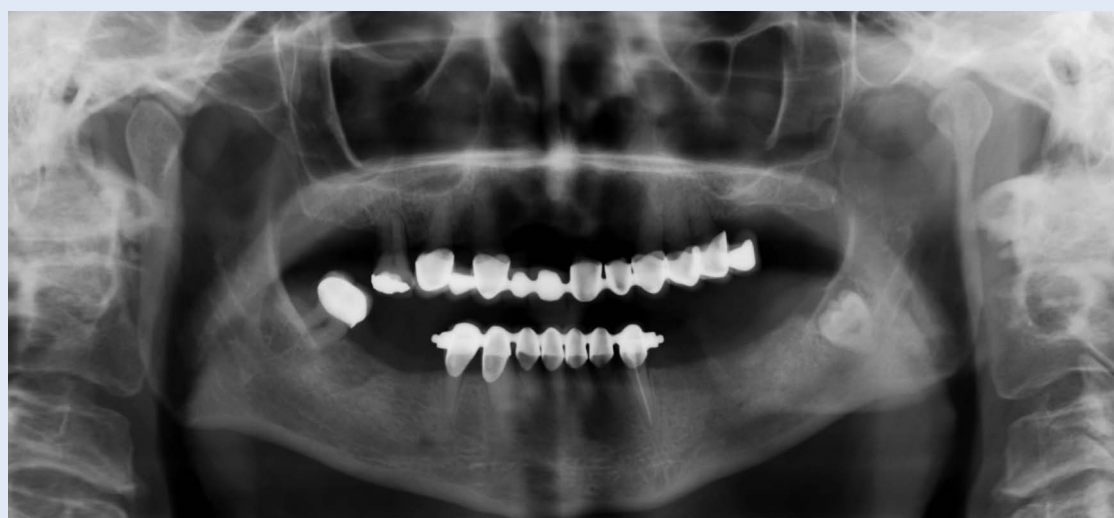Metastatic tumours of the oral cavity are noteworthy because they are uncommon and correspond to only 1% of oral tumours. They are far more frequently reported in the jawbones, than those in the oral mucosa. In cases of metastases to the jawbones there is a slight female predilection. In the male population, the observed ratio is 1.6:1 for the metastases to the oral mucosa<sup>1</sup>. According to Glaser, most common sources of tumors metastasizing to the jawbones were the breast for women and lung for men, both preferring the premolar-molar area<sup>2</sup>. The biggest challenge is their clinical presentation, which can often mislead clinician and extend the diagnostic approach. Most of the literature presents the informations in isolated case reports, where there is not enough data about pulmonary large cell neuroendocrine carcinoma metastases. Pulmonary large cell neuroendocrine carcinoma (LCNEC) represents a minority (3%) of primary lung malignancies. LCNEC has been grouped with other neuroendocrine tumors (NET) of the lung in the most recent 2015 WHO classification of thoracic tumors<sup>3</sup>. Lung NETs can be classified into four subtypes: well- differentiated, low-grade

typical carcinoids (TCs); well-differentiated, intermediate-grade atypical carcinoids (ACs); poorly differentiated, high-grade large cell neuroendocrine carcinomas (LCNECs); and poorly differentiated, high-grade SCLCs<sup>4</sup>. Mandibular metastatic carcinoma is an evidence of a widespread disease and patients with proven lesion of LCNEC are more likely to develop recurrent disease. Overall 5-year survival rate is 13% to 57% according to cancer stage and it has not appreciably improved over the last 30 years<sup>5</sup>. As certain types of lung cancer are more likely to cause metastatic disease, they must be included in differential diagnosis especially in patients with history of jaw pain and swelling. The purpose of our case report is therefore to describe the clinical course and outcome of a patient with clinical history of jaw swelling and pain with later diagnosed large cell neuroendocrine carcinoma (LCNEC). Since this case represents a rare condition, diagnosis was extensive and the outcome was uncertain. Not all of the diagnostic methods could prove that the mandibular lesion is in fact metastasis.

## CASE REPORT

A sixty-one year old female patient was referred to the maxillofacial surgery clinic in August 2013, with a dull pain in the area of the left temporomandibular joint (TMJ) spreading to the upper and lower jaw. Extraoral exam revealed tenderness of the left preauricular area to palpation, deviation of the mandible to the left side while opening the mouth and mild pain of masticatory muscles. Intraoral exam revealed painful palpation of the premolar-molar region with inflammation of the surrounding area.

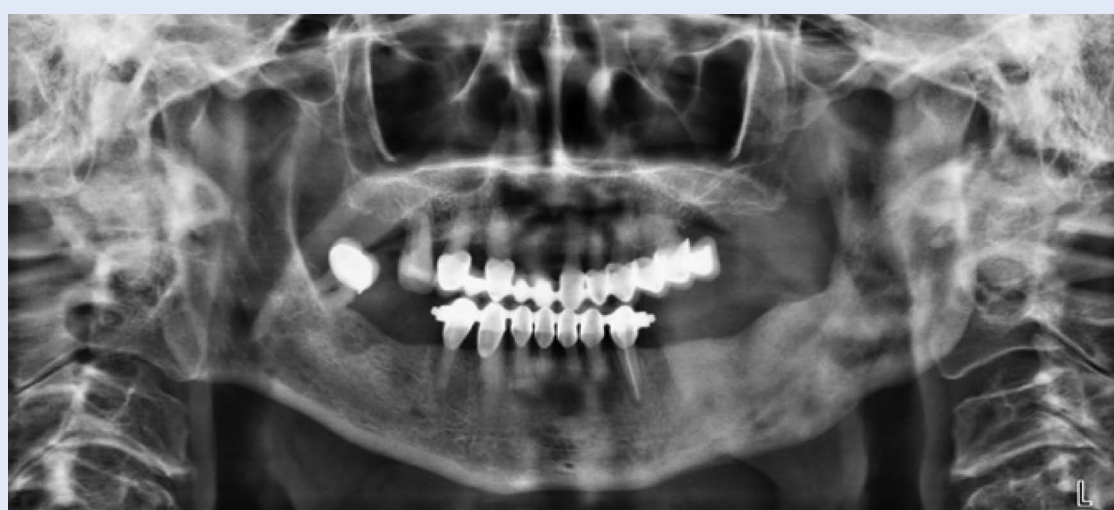Orthopantomogram revealed an impacted tooth #38 (Figure 1). She additionally reported changes in occlusion of the distal part of the jaw and difficulty chewing food. The patient underwent tooth extraction followed by Amoxicillin® therapy. Her medical history was compounded and included essential hypertension, second degree AV block, supraventricular tachycardia with extrasystole, bilateral adrenal hyperplasia, thyroid gland enlargement without function abnormalities, built-in pacemaker, hyperlipoproteinemia, chronic kidney disease (stage 3) and chronic obstructive pulmo-



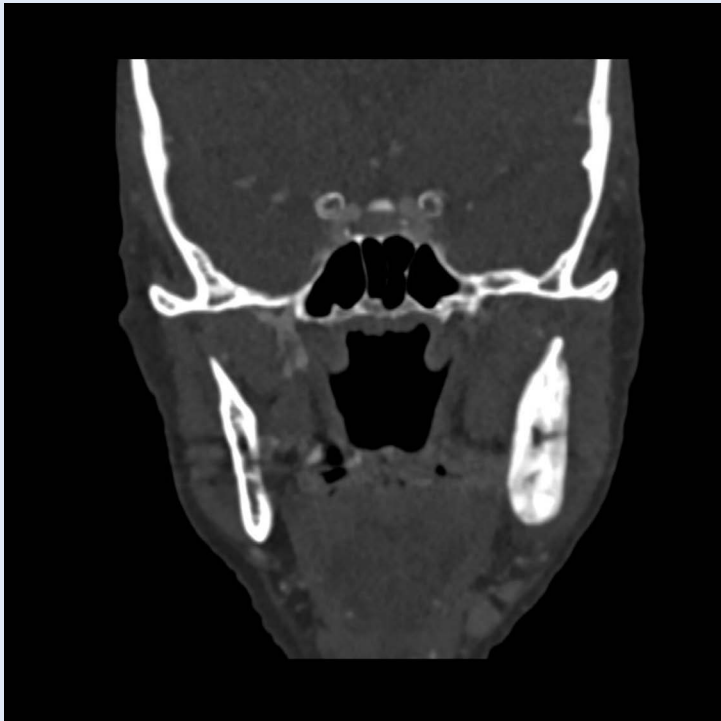
**Figure 1.** Orthopan showing the condition before impacted tooth extraction.

nary disease (COPD). She was a heavy smoker for about 50 years with no history of alcohol or drug abuse. Since there was no clinical improvement in symptoms after tooth extraction, and physical examination revealed persistent pain and tenderness of the temporomandibular area, the patient was referred for further diagnosis. The patient underwent MR and arthroscopy in 2014 which indicated disc perforation of the left TMJ with osteophytes and extensive degenerative changes. Initial diagnosis was temporomandibular disorder. Arthrocentesis was performed, which resulted in significant clinical improvement that lasted for 1.6 years. The patient was evaluated again in 2016

due to the recurrent painful symptoms with pain intensity 8\10 on the pain scale. A combination of acupuncture treatment and pain medications were administered as well as the recommendation of neurological and otorhinolaryngological examination because of the possible trigeminal neuralgia diagnosis. Within a 2 year period, her symptoms progressed to the point where her left side of the face was visibly enlarged and swollen. The patient was noticeably thinner due to the poor food intake. In December, 2018 the panoramic radiography confirmed left mandibular jaw lesion 2 x 2 x 0.3 cm<sup>3</sup> with ill-defined margins and long transition zone (Figure 2). The computed tomography (CT)



**Figure 2.** Orthopan showing the condition after impacted tooth extraction. Note the lesion involving left mandibular corpus, angle, and ascending ramus of the left mandible.



**Figure 3.** DECT, coronal plane of the viscerocranium. Notice the asymmetry at the expense of a more voluminous representation of the left mandible.

scans showed evident asymmetries of the left side due to the pathological remodeling of the bone in a form of a ground glass and a hypodense lesion without infiltration of soft tissues, which, according to the morphological picture, corresponds to fibrous dysplasia (Figure 3). The incisional biopsy of lesion was performed in January 2019 and specimen was sent to the pathology department which found fragments of sclerotic bone with osteoid deposition. Due to unclear finding, the patient underwent biopsy by needle puncture and aspiration of the bone marrow with clinical suspicion of rare genetic disease, IgG4-related disease or possible tumor. All of the hematological parameters were normal as well as the repeated biopsy of the mandible with no evident tumor. In March, 2019 PET scan of the body revealed nodule 11 x 15 mm in the upper left lobe of the lung with high pathological signal of FDG (fluorodeoxyglucose) metabolism. Furthermore, several small FDG negative nodules suspicious of primary malignant process with satellite lesions and cavitory lesion in the upper right lobe of the lung were found. Findings were communicated to the thoracic surgery tumor board, who performed wedge resection of the left

superior lobe in August, 2019. The tumor cells from the original lung mass exhibited an immunohistochemical staining for the neuroendocrine marker, synaptophysin as well as chromogranin A. Histology evaluation reported neuroendocrine large cell carcinoma with positive CD56 cells and thyroid transcription factor (TTF), stage 3, with positive resection edges. Repeated PET and SPECT scan in October, 2019 confirmed the diagnosis of metastatic disease with newly formed regional lymph node metastases (left paratracheal 15 mm and preaortal 20 mm) and mandibular sclerosis. In the somatostatin receptor scintigraphy, patient had pathological accumulation within the area of the left bronchus bifurcation as well as within the left ramus of mandible which continued to the soft tissues around mandible. The course of management included chemotherapy which caused severe anemia. In March, 2020 the patient was referred into the emergency service because of dyspnea and pain in the left side of the chest. The examination revealed threatening cardiac tamponade. She died eleven days after, at the age of 68.

## DISCUSSION

Previous reports show that the jawbones are a rare site for metastases from primary malignant tumours elsewhere in the body. Hirshberg states that the primary site differs between genders: for women, it is the breast (42%), adrenal (8.5%), colorectum (8%), female genital organs (7.5%) and thyroid gland (6%) carcinomas: for men, it is the lung (33.2%), followed by the prostate (12%), kidney (10.3%), bone (9.2%) and adrenal gland (9.2%) carcinomas<sup>1</sup>.

According to a study by Bodner et al., which included eight patients, in nearly 30% of the cases, distal metastases in the mandible are the first sign of the primary malignant lesion<sup>6</sup>. Our patient presented only with mandibular swelling which corresponds the stated fact. Given the atypical clinical picture, the biggest challenge is the diagnosis. Jaw lesions may sometimes give a vague presentation, such as persistent pain and swelling, TMJ dysfunction, inferior alveolar nerve paresthesia or anesthesia and trismus. Severe and increasing pain may mimic familiar clinical enti-

ties that include myofascial pain syndrome, toothache, trigeminal neuralgia, osteomyelitis or primary tumour of the jaw like plasmacytoma. Sometimes, lesion can be entirely asymptomatic, patients do not feel pain and, therefore come relatively late for treatment<sup>2</sup>. Since the diagnosis of mandibular changes is often misleading, protocol includes physical examination, broad spectrum of imaging methods as well as the Axis II screening instruments which are used in cases of persistent pain lasting 6 months or longer<sup>7</sup>. If the physical examination and imaging findings are equivocal, invasive methods must be applied. The best options are often biopsy of the lesion and biochemistry markers<sup>2</sup>. In the case presented, patient's evaluation involved numerous specialists, who excluded primary plasmacytoma and other jaw malignancies. The biopsy of the mandible was negative in two occasions and 5 months before the clinical finding of primary lung lesion. LCNEC is an uncommon and aggressive neoplasm often associated with advanced disease and poor prognosis. Most often occurs in the seventh decade of life with an average age of 65. The majority of patients diagnosed with LCNEC have a history of smoking<sup>8</sup>. Given the fact that neuroendocrine carcinomas can cause mechanical and functional symptoms, clinicians must assemble and evaluate all of the relevant data. Clausen and Poulsen reported a case series of mandibular metastases, proving that metastatic involvement of the jaw is not uncommon and is often overlooked or misinterpreted. Distant metastases are most commonly found within brain and bones<sup>9</sup>. Nevertheless, they often present the first symptom of tumour at all, and must be suspected in patients with swelling and pains in this area<sup>8</sup>. Regarding diagnostic protocols, due to the rarity of the lesion and various clinical presentations, clinicians are still in search of a consensus.

As reported by other studies, lack of radiographic changes does not exclude the possible presence of metastatic lesion and clinicians must follow meticulous work-up of mandible lesions in order to improve management and survival rate<sup>1,2,9</sup>. Moreover, biochemical markers and somatostatin receptor scintigraphy are helpful as well as the immunoperoxidase staining using p63, Ki67,

CK 5, CK 6, neuroendocrine markers (synaptophysin, chromogranin A and CD56) and TTF-1<sup>10,11</sup>. These markers are typically found in neuroendocrine tumors. They can be used in patients with or without distinct hormone-related symptoms<sup>12</sup>. In order to evaluate hormonal symptoms suggesting NET, diagnostic algorithm must be completed with plasma biochemical markers such as serotonin, urinary 5-hydroxyindoleacetic acid, adrenocorticotrophic hormone, cortisol and insulin growth factor 1. Enumerated markers are usual-

Since mandibular lesions will often present with local signs and symptoms clinicians should first exclude local causes and look at the big picture. Such a shift in perspective could modify the diagnostic approach in order to set early diagnosis and potentially reduce mortality rate.

ly elevated in case of liver metastases, and less than 5% of NETs exhibit hormonally related symptoms<sup>13</sup>. The patient, in this report, had no hormonal symptoms and liver imaging was without clear pathological appearance. Therefore, there was no clinical indications, according to the oncologist, for evaluation of hormonal markers. However, due to threatening heart tamponade, which was a suspected cause of death, the question of carcinoid heart disease arises. Validation of such hypothesis could have been done by previously mentioned hormonal markers. Given all the presented information, it is reasonable to conclude that diagnosis of mandibular metastases is a complex endeavour. Metastatic jaw lesions will often have symptoms persisting for 40 months in average, before the metastasis is discovered<sup>2</sup>. Clinicians should first exclude local cause of symptoms and look at the big picture. Such a shift in perspective could modify the diagnostic approach in order to set early diagnosis and potentially reduce mortality rate.

## CONCLUSION

The diagnosis of jaw metastasis is a challenge. In patients with long-term symptoms within jaw, such as the pain and swelling that do not respond to therapy, increased caution in diagnosis and reg-

ular monitoring are required. It is recommended to take into account the broad differential diagnosis as well as the experiences of other clinicians described precisely through such case reports.

**Conflicts of Interest:** Authors declare no conflicts of interest.

## REFERENCES

1. Hirshberg A, Leibovich P, Buchner A. Metastatic tumors to the jawbones: analysis of 390 cases. *J Oral Pathol Med* 1994;23:337-41.
2. Glaser C, Lang S, Pruckmayer M, Millesi W, Rasse M, Marosi C et al. Clinical manifestations and diagnostic approach to metastatic cancer of the mandible. *Int J Oral Maxillofac Surg* 1997;26:365-8.
3. Travis WD, Brambilla E, Burke AP, Marx A, Nicholson AG. Introduction to The 2015 World Health Organization Classification of Tumors of the Lung, Pleura, Thymus, and Heart. *J Thorac Oncol* 2015;10:1240-42.
4. Rektman N. Neuroendocrine tumors of the lung: an update. *Arch Pathol Lab Med* 2010;134:1628-38.
5. Ram P, Penalver JL, Lo KBU, Rangaswami J, Pressman GS. Carcinoid Heart Disease: Review of Current Knowledge. *Tex Heart Inst J* 2019;46:21-27.
6. Bodner L, Sion-Vardy N, Geffen DB, Nash M. Metastatic tumors to the jaws: a report of eight new cases. *Med Oral Patol Oral Cir Bucal* 2006;11:132-5.
7. Schiffman E, Ohrbach R, Truelove E, Look J, Anderson G, Goulet JP et al. Diagnostic Criteria for Temporomandibular Disorders (DC/TMD) for Clinical and Research Applications: recommendations of the International RDC/TMD Consortium Network\* and Orofacial Pain Special Interest Group†. *J Oral Facial Pain Headache* 2014;28:6-27.
8. Baine MK, Rektman N. Multiple faces of pulmonary large cell neuroendocrine carcinoma: update with a focus on practical approach to diagnosis. *Transl Lung Cancer Res* 2020;9:860-78.
9. Clausen F, Poulsen H. Metastatic carcinoma of the jaws. *Acta Pathol Microbiol Scand* 1963;57:361-74.
10. Carvalho L. Reclassifying bronchial-pulmonary carcinoma: differentiating histological type in biopsies by immunohistochemistry. *Rev Port Pneumol* 2009;15:1101-19.
11. O'Byrne KJ, Schally AV, Thomas A, Carney DN, Steward WP. Somatostatin, its receptors and analogs, in lung cancer. *Chemotherapy* 2001;47:78-108.
12. Eriksson B, Oberg K, Stridsberg M. Tumor markers in neuroendocrine tumors. *Digestion* 2000;62:33-8.
13. Gustafsson BI, Kidd M, Chan A, Malfertheiner MV, Modlin IM. Bronchopulmonary neuroendocrine tumors. *Cancer* 2008;113:5-21.