



# MICROSURGICAL MANAGEMENT OF RECURRENT INTRACRANIAL ANEURYSMS FOLLOWING ENDOVASCULAR TREATMENT: A SINGLE INSTITUTION ILLUSTRATIVE CASE SERIES AND LITERATURE REVIEW

Krešimir Rotim<sup>1,2,3</sup>, Vladimir Kalousek<sup>4</sup>, Filip Vrban<sup>1</sup> and Bruno Splavski<sup>1,2,3</sup>

<sup>1</sup>Department of Neurosurgery, Sestre milosrdnice University Hospital Center, Zagreb, Croatia;

<sup>2</sup>University of Applied Health Sciences, Zagreb, Croatia;

<sup>3</sup>Josip Juraj Strossmayer University of Osijek, Faculty of Medicine, Osijek, Croatia;

<sup>4</sup>Department of Radiology, Sestre milosrdnice University Hospital Center, Zagreb, Croatia

**SUMMARY** – Microsurgical clipping and endovascular coiling are both effective management modalities for intracranial aneurysms, whereas recent procedures are mainly directed towards endovascular treatment because of its minimally invasive nature. However, such a treatment has been associated with a bigger risk of recurrent aneurysmal growth and re-bleeding urging a selection of optimal strategies to overcome these hazards. It seems that the most appropriate method of choice is microsurgical clipping, which is much more technically challenging due to recurrent aneurysm demanding configuration created by the initial coiling. Herein, we present an illustrative institutional case series of recurrent intracranial aneurysms following endovascular treatment, and discuss the controversies and benefits of their subsequent microsurgical management, based on our experience and on literature review. Considering the results reported in this paper, it seems that careful selective microsurgical neck clipping with/without aneurysmal sac resection and coil extraction remains the preferred management option for recurrent intracranial aneurysms, resulting in high obliteration rates, long-term occlusion stability, and low morbidity/mortality. In conclusion, to bring a satisfactory outcome, the multidisciplinary management of recurrent intracranial aneurysms after endovascular treatment should be adjusted to aneurysm morphology/size/location, and individualized according to patient needs.

**Key words:** *Intracranial aneurysm, recurrent; Endovascular treatment; Microsurgical clipping; Outcome*

## Introduction

Microsurgical clipping and endovascular coiling are both effective choices in the management of intracranial aneurysms, whereas recent procedures are mainly directed towards endovascular treatment because of its minimally invasive nature<sup>1</sup>. However, such a treatment has been associated with a bigger risk of

recurrent aneurysmal growth and re-bleeding<sup>1</sup>, which represents a unique management challenge and requires a skilled team of professionals consisting of vascular neurosurgeons and intervention neuroradiologists<sup>2</sup>.

A variety of risk factors associated with aneurysm recurrence exist, including comorbidities such as diabetes and arterial hypertension, habits such as cigarette smoking, as well as aneurysm specific morphology<sup>3</sup>. Therefore, recurrent aneurysms have an augmented possibility of regrowth and subsequent rerupture<sup>4</sup>, urging a selection of suitable management strategies, which are crucial when such a recurrence occurs. Com-

Correspondence to: *Bruno Splavski, MD, PhD*, Department of Neurosurgery, Sestre milosrdnice University Hospital Center, Vinogradska c. 29, HR-10000 Zagreb, Croatia  
E-mail: splavuno@gmail.com

Received September 14, 2021, accepted November 29, 2021

plete sac occlusion of recurrent aneurysm after endovascular treatment has been shown to be less effective when compared to microsurgical clipping<sup>5</sup>. According to the results of the International Subarachnoid Aneurysm Trial (ISAT), aneurysmal neck remnants and sac recanalization, as well as re-bleeding after coiling, were significantly more often in comparison with microsurgical clipping<sup>1,6</sup>. This was confirmed by the results of the Cerebral Aneurysm Rerupture After Treatment (CARAT) study, which also underlined that the risk of residual aneurysm rupture was dependent on the degree of neck obliteration, and that it was significantly increased in aneurysm having a suboptimal occlusion<sup>7</sup>. Hence, contrary to primary intracranial aneurysm, a recurrent one is more prone to re-bleeding, as well as much more technically demanding due to its poor configuration possibly created by the initial coiling.

Herein, we present a case series of recurrent intracranial aneurysms following endovascular treatment, and discuss the controversies and benefits of their microsurgical management in relation to our experience and to recent literature data.

## Material and Methods

A retrospective single-institution analysis of illustrative case series of recurrent intracranial aneurysms generated after endovascular treatment was performed. Patient demographics and comorbidities, as well as aneurysm morphology, size and location were recorded. The indications for and the type of endovascular procedures performed prior to clipping were also studied. Aneurysm angiographic patterns, microsurgical strategies, and outcome of patients having such aneurysms were provided too.

The intensity of meningeal response to aneurysmal subarachnoid hemorrhage (SAH), status of neurological deficit, and patient awareness level were assessed by Hunt-Hess scoring (HH) on a 0-5 scale<sup>8</sup>. Procedure-related complications occurring during and after the initial and/or subsequent treatments were also recorded.

According to the Glasgow Outcome Scale Extended (GOSE)<sup>9</sup> at hospital discharge and at follow-ups, the outcome was dichotomized into favorable (GOSE 5-8) and unfavorable (GOSE 1-4). This descriptive 8-point outcome measure separates outcome categories into lower and upper alignments permitting better distinction of recovery<sup>9</sup>.

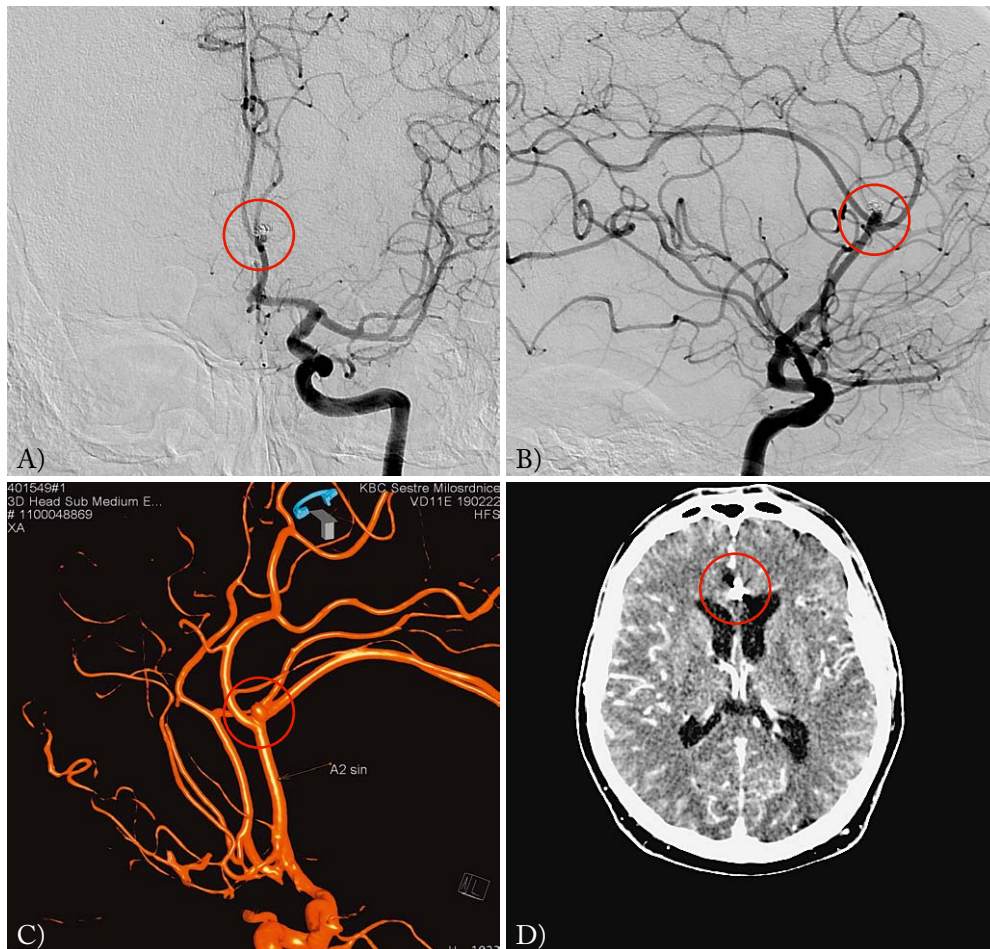
## Illustrative Case Series

### Case 1

A 57-year-old male was admitted to the hospital as an emergency due to ruptured aneurysm on the left pericallosal artery and consequent SAH two years prior to microsurgical treatment. His past medical history included arterial hypertension and no other chronic illnesses. He was HH I at admission having no neurological deficit. Immediate endovascular procedure was carried out and the aneurysm sac was occluded with 3 coils. His post-procedural recovery was uneventful and he had upper full recovery (GOSE 8) at 6-month follow-up when post-procedural digital subtraction angiography (DSA) of cerebral vessels was performed showing coil-occluded aneurysmal sac at A2 segment of the left anterior cerebral artery (ACA) with minor residual filling of the aneurysmal neck. However, the residual aneurysm substantially enlarged at one-year check-up, measuring 2.95 mm in diameter of aneurysmal sac (Fig. 1 A, B, C). Accordingly, microsurgical aneurysm revision was proposed and bifrontal, more left-side oriented craniotomy was performed. Aneurysm site on the left pericallosal artery was located through interhemispheric approach with control of the neuronavigation system. Coils protruding throughout the aneurysmal sac were visible but left intact. A titanium clip was selectively placed across the aneurysmal neck, while intraoperative fluorescein imaging confirmed no further aneurysmal filling with maintained patency of the parent vessel. Computerized tomography (CT) brain scan disclosed no abnormalities and no signs of brain ischemic lesion. No additional neurological deficit was observed. The patient was discharged fully recovered (GOSE 8). Follow-up computed tomographic angiography (CTA) performed at 6-month check-up after clipping showed stable distal ACA aneurysmal occlusion (Fig. 1 D).

### Case 2

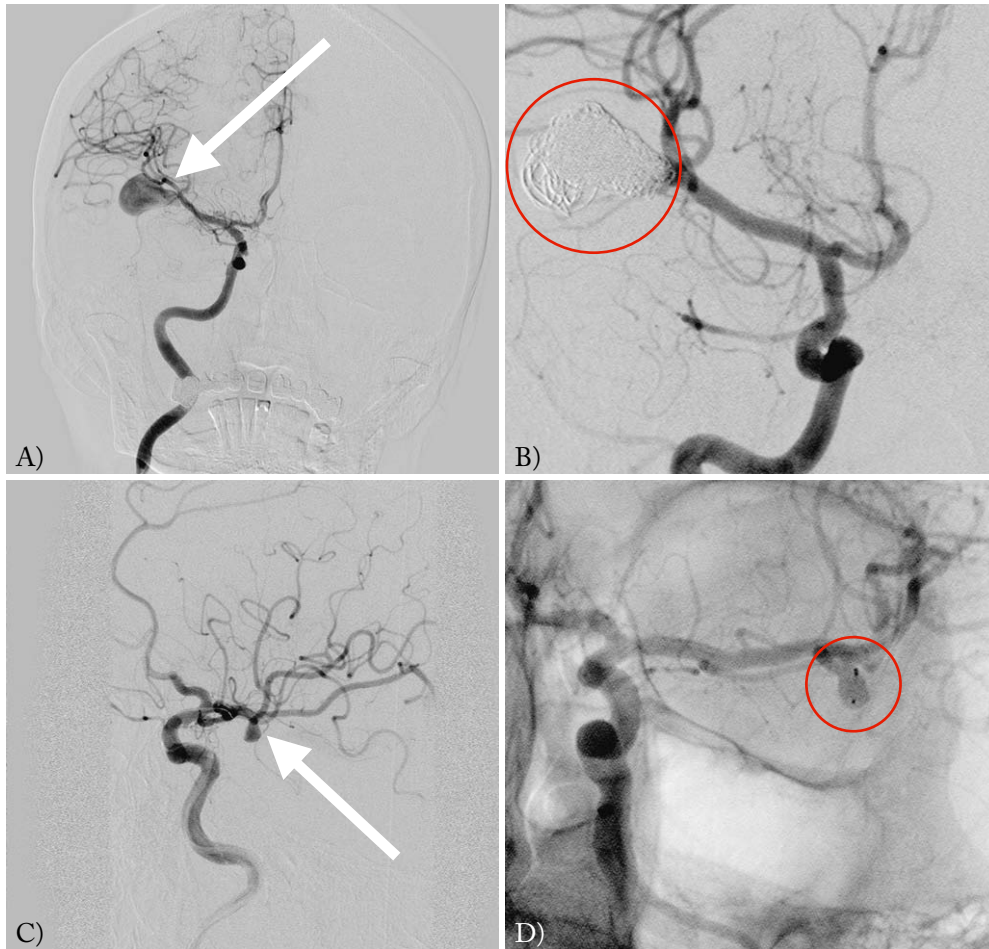
An otherwise healthy 54-year-old female was admitted to the hospital as an emergency two years prior to microsurgical treatment due to a giant ruptured aneurysm located at the bifurcation of the right middle cerebral artery (MCA) and measuring 2.7 cm in diameter, which was accompanied by subsequent SAH. She was HH II at admission, having no major neurological



*Fig. 1. Digital subtraction angiography (DSA) of cerebral vessels performed at one-year follow-up after coiling, showing substantially enlarged residual aneurysm at A2 segment of the left anterior cerebral artery (ACA) measuring 2.95 mm in diameter of aneurysmal sac (red rings): the anteroposterior (A), lateral (B), and three-dimensional (C) DSA projections; computed tomographic angiography (CTA) performed at 6-month follow-up after clipping, showing stable aneurysmal occlusion (D) (red ring).*

deficit. Following urgent diagnostic workup, which included pan-cerebral DSA (Fig. 2 A), an immediate endovascular procedure was carried out. The aneurysm sac was completely occluded with 20 coils (Fig. 2 B), while intra-procedural bleeding was reduced with low systemic intravenous heparinization. Afterwards, the patient was discharged fully recovered (GOSE 8). However, magnetic resonance angiography (MRA) performed at 6-month follow-up identified an additional non-ruptured small aneurysm on the opposite MCA bifurcation. Therefore, she underwent repeated cerebral vessel DSA, which revealed stable occlusion

of the previously coiled right MCA giant aneurysm, but also confirmed the opposite side wide-neck MCA aneurysm formation (Fig. 2 C), which was successfully treated by Woven EndoBridge (WEB) embolization system consisting of self-expanding mesh ball titanium implant (Fig. 2 D), followed by the administration of double antiplatelet therapy, which was discontinued after a month. Nonetheless, post-procedural 3D DSA performed at one-year follow-up showed coil-occluded aneurysmal recurrence of the right MCA having residual filling of the neck (Fig. 3 A). Hence, the patient was selected for microsurgical treatment.



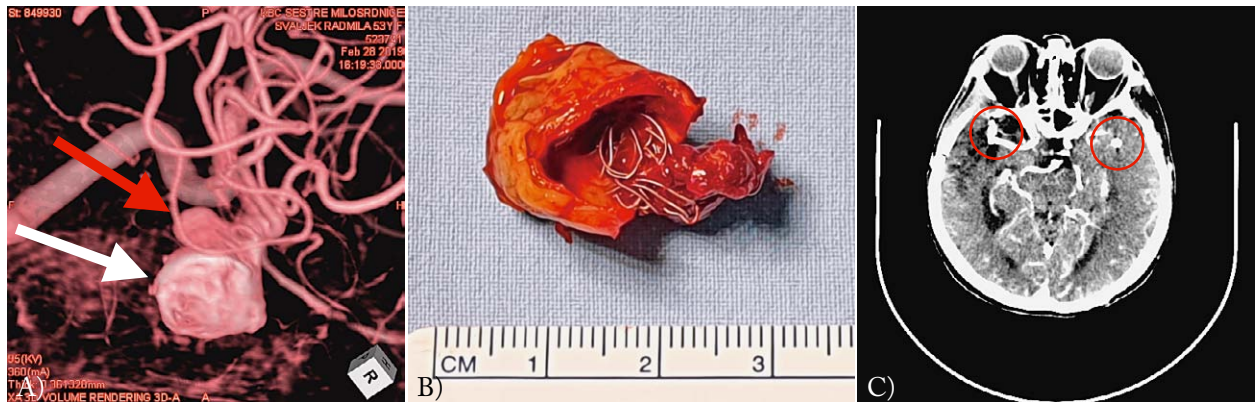*Fig. 2. Initial pan-cerebral digital subtraction angiography (DSA) showing giant ruptured aneurysm located at the bifurcation of the right middle cerebral artery (MCA) measuring 2.7 cm in diameter (A) (white arrow); intra-procedural DSA confirming the aneurysm sac completely occluded with 20 coils (B) (red ring); repeated cerebral vessel DSA revealing the opposite side wide-neck MCA aneurysm formation (C) (white arrow); intra-procedural DSA depicting Woven EndoBridge (WEB) embolization of the left MCA aneurysm at its bifurcation (D) (red ring).*

Right-sided pterional osteoplastic craniotomy was performed. Coils protruding throughout the aneurysmal sac, as well as aneurysmal recurrence located at the neck of the coiled aneurysm were visualized. A permanent titanium clip was selectively placed upon the aneurysmal neck, while intraoperative fluorescein imaging and Doppler ultrasonography confirmed no further aneurysmal filling, along with preserved parent vessel patency. The aneurysm sac was completely resected together with the coils (Fig. 3 B). The immediate postoperative course was uneventful. Follow-up CT brain scan disclosed no postoperative ischemic

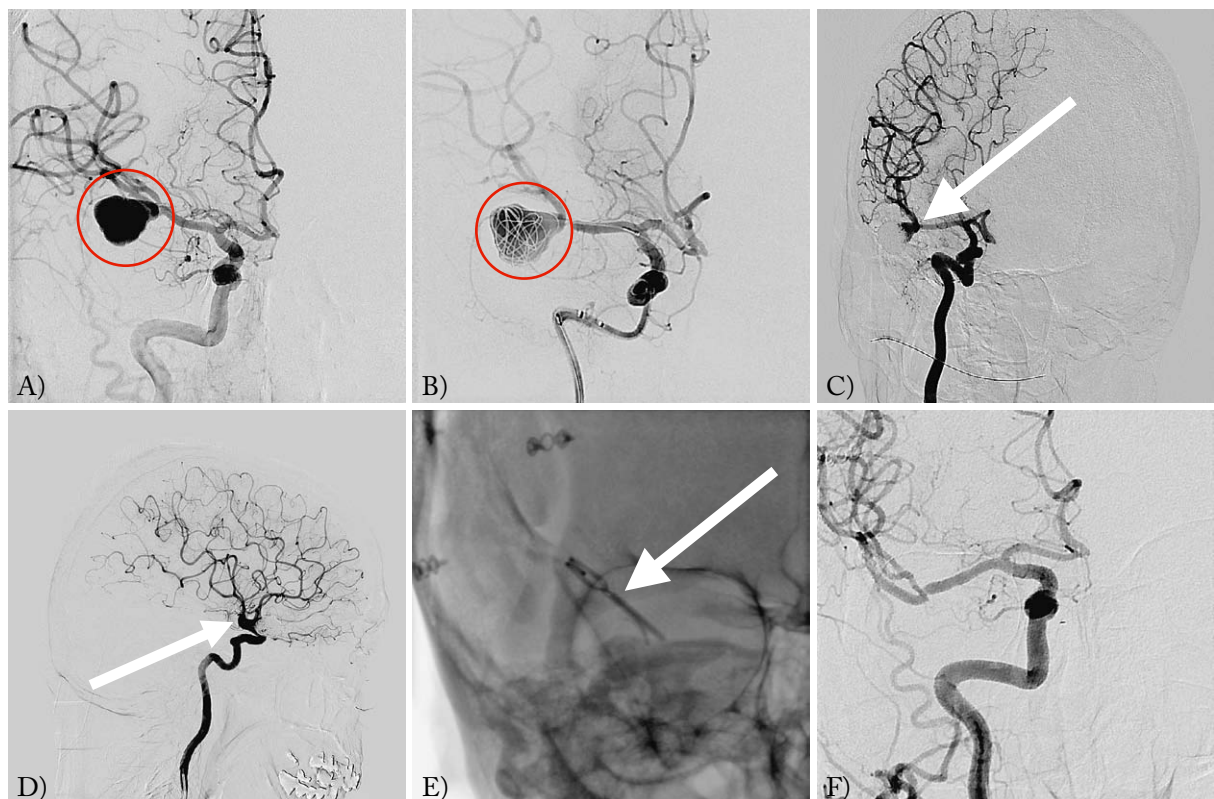
cerebral lesion. She was discharged fully recovered (GOSE 8) having no neurological deficit. CTA of cerebral vessels performed at 6-month follow-up revealed stable occlusion and no signs of revascularization of both aneurysms, the one on the right MCA that was successfully clipped and resected, and another one on the left MCA, which was occluded by WEB (Fig. 3 C).

### Case 3

A 61-year-old female was admitted to the hospital as an emergency due to the ruptured aneurysm of the



*Fig. 3. Follow-up 3D digital subtraction angiography (3D DSA) showing coil-occluded aneurysmal sac of the right MCA (white arrow) with residual filling of the neck (red arrow) (A); a photo of the completely resected aneurysm illustrating aneurysmal sac filled with coils protruding throughout the aneurysmal wall (B); follow-up computed tomographic angiography (CTA) of cerebral vessels revealing stable occlusion and no signs of revascularization of both aneurysms (C) (red rings).*



*Fig. 4. Urgent cerebral digital subtraction angiography (DSA) confirming ruptured aneurysm of the right MCA bifurcation (A) (red ring); intra-procedural DSA showing the occluded aneurysm filled with 35 coils (B) (red ring); post-procedural DSA in anteroposterior (C) and lateral (D) projections revealing slight coil compaction and recanalization of aneurysmal neck after coiling (white arrows); postoperative fluoroscopy illustrating a huge strait titanium clip selectively placed upon the aneurysmal neck (E) (white arrow); follow-up DSA showing complete aneurysmal occlusion with no signs of relapse (F).*

right MCA bifurcation visible on urgent cerebral DSA (Fig. 4 A), and accompanied by SAH and intracerebral hematoma (ICH) located in the right temporal lobe, a year prior to microsurgical treatment. Her past medical history included arterial hypertension and hypothyroidism. She had also suffered a heart attack (myocardial infarction) a year before hospital admission, where she was HH I and with no neurological deficit. Immediate endovascular procedure was carried out and the aneurysm was occluded with 35 coils (Fig. 4 B). Afterwards, she recovered fully and was discharged from the hospital soon. However, post-procedural DSA performed at 1.5-year follow-up revealed slight coil compaction and recanalization of the aneurysmal neck (Fig. 4 C and D), which were an indication for microsurgical clipping. Right-sided pterional osteoplastic craniotomy was performed and the aneurysm was completely resected together with the coils protruding throughout the aneurysmal sac. A huge strait titanium clip was selectively placed upon the aneurysmal neck (Fig. 4 E). Intraoperative fluorescein imaging confirmed preserved parent vessel patency, with no further aneurysmal filling. The immediate postoperative course was uneventful. Follow-up CT brain scan disclosed no postoperative ischemic cerebral lesion. She was discharged fully recovered (GOSE 8) having no neurological deficit. DSA of cerebral vessels performed at 3-month follow-up showed complete aneurysmal occlusion with no signs of relapse (Fig. 4 F).

## Discussion

Although initial endovascular treatment of intracranial aneurysms is an advantageous minimally invasive procedure having low morbidity, it may be burdened with the increased possibility of related complications including aneurysmal incomplete occlusion, coil compaction, high rates of recanalization, relapse and re-bleeding, endangering long-term stability of coil embolization<sup>10-12</sup>. However, one should always consider the possibility of aneurysm recurrence regardless of the mode and time of primary procedure<sup>13</sup>. A systematic literature review, as well as the Barrow Ruptured Aneurysm Trial (BRAT), indicated that roughly 20% of coiled aneurysms may recur, whereas almost half of them will undergo additional management<sup>14,15</sup>. Another BRAT study found that the rates of coiled aneurysm occlusion decreased and their recur-

rence increased over time, urging retreatment<sup>16</sup>. In this case series study, aneurysmal recurrence following endovascular treatment was recorded after two years in two patients, and after a year in the remaining one patient. Several studies have revealed that aneurysm size and location are associated with its recurrence<sup>12,17-19</sup>. The bigger the aneurysmal sac and neck size, the lower was the degree of aneurysm occlusion, and aneurysmal rupture and stent-assisted coiling were identified as strong indicators of aneurysm recurrence<sup>20</sup>. All aneurysms from our series were ruptured ones, while a giant MCA aneurysm was recorded in one patient (Case 2). No stent-assisted coiling was performed in our patients. Aneurysmal remnants and regrowth, re-bleeding, mass effect after coiling, as well as migration of the coils represent clear indications for repeated treatment, including microsurgical clipping<sup>21</sup>. No aneurysmal re-rupture, mass effect or coil migration were observed in our patients. Hence, aneurysmal recanalization was a sole indication for microsurgical intervention. When microsurgical management of recurrent intracranial aneurysms is performed, the parent vessel patency has to be considered<sup>4</sup>. The crucial challenge to maintain vessel patency is to dissect the aneurysm in the field of fibrosis, which is induced by coils extruded during the endovascular treatment. This makes accurate clip placement rather difficult<sup>4</sup> because intra-aneurysmal coil masses may sometimes be adherent to the aneurysm wall<sup>22,23</sup>. To define aneurysmal neck better, coil removal is often necessary, which has sometimes been found as an adverse outcome factor after clipping and associated with higher morbidity<sup>4,24,25</sup>. Nonetheless, this procedure mainly enables secure clip closure of the aneurysm<sup>26</sup>, although it is often technically challenging and more risky over time as coils become firmly incorporated into the aneurysm sac<sup>27,28</sup>. However, we managed to dissect the aneurysm sac together with the coils in it in two out of three of our patients successfully, while in the remaining patient with 3 coils situated within the sac of pericallosal artery aneurysm, the coils were left intact after selective neck clipping (Case 1). In all patients, the parent vessel patency was preserved, which was checked by intraoperative fluorescein imaging and Doppler ultrasonography.

Bearing in mind our results, it seems that careful selective microsurgical neck clipping with or without aneurysmal sac resection and coil extraction remains the preferred management option for recurrent intra-

cranial aneurysms following endovascular treatment, resulting in high obliteration rates and low morbidity/mortality, which is consistent with the results from relevant literature<sup>21,29-31</sup>.

At the end, we would like to address certain study limitations primarily arising from the small sample size, making recommendations for the best management of recurrent intracranial aneurysms after endovascular treatment difficult.

In conclusion, to ensure long-term occlusion stability, to reduce morbidity/mortality, and to bring a satisfactory outcome, the management of recurrent intracranial aneurysms after endovascular treatment should be adjusted to aneurysm morphology, size and location, and individualized according to patient needs, as well as meticulously discussed in an experienced multidisciplinary team of experts.

## References

- Molyneux AJ, Kerr RS, Birks J, Ramzi N, Yarnold J, Sneade M, *et al.* Risk of recurrent subarachnoid haemorrhage, death, or dependence and standardised mortality ratios after clipping or coiling of an intracranial aneurysm in the International Subarachnoid Aneurysm Trial (ISAT): long-term follow-up. *Lancet Neurol.* 2009;8:427-33. doi: 10.1016/S1474-4422(09)70080-8.
- Rotim K, Splavski B, Kalousek V, Jurilj M, Sajko T. Endovascular management of intracranial aneurysms of distal arterial branches: illustrative case series and literature retrospection. *Acta Clin Croat.* 2020;59:712-20. doi: 10.20471/acc.2020.59.04.18.
- Huang DZ, Jiang B, He W, Wang YH, Wang ZG. Risk factors for the recurrence of an intracranial saccular aneurysm following endovascular treatment. *Oncotarget.* 2017;8(20):33676-82. doi: 10.18632/oncotarget.16897.
- Kutty RK, Kumar A, Yamada Y, Tanaka R, Kannan S, Ravisanakar V, *et al.* Management of recurrent aneurysms after endovascular coiling: a Fujita experience. *Asian J Neurosurg.* 2019;14(4):1151-6. doi: 10.4103/ajns.AJNS\_105\_19.
- Chen KS, Wilson TJ, Stetler WR, Davis MC, Giles DA, Kahn EN, *et al.* Management of recurrent aneurysms following endovascular therapy. *J Clin Neurosci.* 2015;22:1901-6. doi: 10.1016/j.jocn.2015.04.012.
- Molyneux AJ, Kerr RS, Yu LM, Clarke M, Sneade M, Yarnold JA, *et al.* International Subarachnoid Aneurysm Trial (ISAT) of neurosurgical clipping *versus* endovascular coiling in 2143 patients with ruptured intracranial aneurysms: a randomised comparison of effects on survival, dependency, seizures, rebleeding, subgroups, and aneurysm occlusion. *Lancet.* 2005;366:809-17. doi: 10.1016/S0140-6736(05)67214-5.
- Johnston SC, Dowd CF, Higashida RT, Lawton MT, Duckwiler GR, Gress DR. Predictors of rehemorrhage after treatment of ruptured intracranial aneurysms: the Cerebral Aneurysm Rerupture After Treatment (CARAT) study. *Stroke.* 2008;39:120-5. doi: 10.1161/STROKEAHA.107.495747.
- Hunt WE, Hess RM. Surgical risk as related to time of intervention in the repair of intracranial aneurysms. *J Neurosurg.* 1968;28:14-20. doi: 10.3171/jns.1968.28.1.0014.
- Wilson JTL, Pettigrew LEL, Teasdale GM. Structured interviews for the Glasgow Outcome Scale and the Extended Glasgow Outcome Scale: guidelines for their use. *J Neurotrauma.* 1997;15(8):573-85. doi: 10.1089/neu.1998.15.573.
- König RW, Kretschmer T, Antoniadis G, Seitz K, Braun V, Richter HP, *et al.* Neurosurgical management of previously coiled recurrent intracranial aneurysms. *Zentralbl Neurochir.* 2007;68(1):8-13. doi: 10.1055/s-2007-968164.
- Pirayesh A, Ota N, Noda K, Petrakakis I, Kamiyama H, Tokuda S, *et al.* Microsurgery of residual or recurrent complex intracranial aneurysms after coil embolization – a quest for the ultimate therapy. *Neurosurg Rev.* 2021;44(2):1031-51. doi: 10.1007/s10143-020-01290-7.
- Yu LB, Fang ZJ, Yang XJ, Zhang D. Management of residual and recurrent aneurysms after clipping or coiling: clinical characteristics, treatments, and follow-up outcomes. *World Neurosurg.* 2019;122:e838-e846. doi: 10.1016/j.wneu.2018.10.160.
- Rotim K, Raguž M, Rotim A, Splavski B, Kalousek V. Late aneurysm relapse after microsurgical treatment of middle cerebral artery aneurysm: a case report and literature review of treatment options. *Acta Clin Croat.* 2020;59:532-8. doi: 10.20471/acc.2020.59.03.19.
- Ferns SP, Sprengers ME, van Rooij WJ, Rinkel GJ, van Rijn JC, Bipat S, *et al.* Coiling of intracranial aneurysms: a systematic review on initial occlusion and reopening and retreatment rates. *Stroke.* 2009;40:e523-9. doi: 10.1161/STROKEAHA.109.553099.
- Spetzler RF, McDougall CG, Zabramski JM, Albuquerque FC, Hills NK, Russin JJ, *et al.* The Barrow Ruptured Aneurysm Trial: 6-year results. *J Neurosurg.* 2015;123:609-17. doi: 10.3171/2014.9.JNS141749.
- Spetzler RF, McDougall CG, Zabramski JM, Albuquerque FC, Hills NK, Nakaji P, *et al.* Ten-year analysis of saccular aneurysms in the Barrow Ruptured Aneurysm Trial. *J Neurosurg.* 2019;1-6. doi:10.3171/2016.9. doi:10.3171/2018.8.JNS181846.
- Campi A, Ramzi N, Molyneux AJ, Summers PE, Kerr RS, Sneade M, *et al.* Retreatments of ruptured cerebral aneurysms in patients randomized by coiling or clipping in the International Subarachnoid Aneurysm Trial (ISAT) *Stroke.* 2007;38:1538-44. doi: 10.1161/STROKEAHA.106.466987.
- Dorfer C, Gruber A, Standhardt H, Bavinzski G, Knosp E. Management of residual and recurrent aneurysms after initial endovascular treatment. *Neurosurgery.* 2012;70:537-53. doi: 10.1227/NEU.0b013e3182350da5.
- Raymond J, Guilbert F, Weill A, Georganos SA, Juravsky L, Lambert A, *et al.* Long-term angiographic recurrences after

- selective endovascular treatment of aneurysms with detachable coils. *Stroke*. 2003;34:1398-403. doi: 10.1161/01.STR.0000073841.88563.E9.
20. Ogilvy CS, Chua MH, Fusco MR, Reddy AS, Thomas AJ. Stratification of recanalization for patients with endovascular treatment of intracranial aneurysms. *Neurosurgery*. 2015;76:390-5. doi: 10.1227/NEU.0000000000000651.
  21. Arnaout OM, El Ahmadi TY, Zammar SG, El Tecle NE, Hamade YJ, Aoun RJ, *et al.* Microsurgical treatment of previously coiled intracranial aneurysms: systematic review of the literature. *World Neurosurg*. 2015;84:246-53. doi: 10.1016/j.wneu.2015.02.027.
  22. Izumo T, Matsuo T, Morofuji Y, Hiu T, Horie N, Hayashi K, *et al.* Microsurgical clipping for recurrent aneurysms after initial endovascular coil embolization. *World Neurosurg*. 2015;83(2):211-8. doi: 10.1016/j.wneu.2014.08.013.
  23. Shi L, Yuan Y, Guo Y, Yu J. Intracranial post-embolization residual or recurrent aneurysms: current management using surgical clipping. *Interv Neuroradiol*. 2016;22(4):413-9. doi: 10.1177/1591019916647193.
  24. Bulsara KR, Hoh B, Rosen C, Tanikawa R, Carpenter J. Preliminary observation on predicting the need for coil extraction during microsurgery: the clip-coil ratio. *Acta Neurochir (Wien)*. 2010;152(3):431-4. doi: 10.1007/s00701-009-0559-z.
  25. Shtaya A, Dasgupta D, Millar J, Sparrow O, Bulters D, Duffill J. Outcomes of microsurgical clipping of recurrent aneurysms after endovascular coiling. *World Neurosurg*. 2018;112:e540-e547. doi: 10.1016/j.wneu.2018.01.077.
  26. Nakamura M, Montibeller GR, Götz F, Krauss JK. Microsurgical clipping of previously coiled intracranial aneurysms. *Clin Neurol Neurosurg*. 2013;115(8):1343-9. doi: 10.1016/j.clineuro.2012.12.030.
  27. Gurian JH, Martin NA, King WA, Duckwiler GR, Guglielmi G, Viñuela F. Neurosurgical management of cerebral aneurysms following unsuccessful or incomplete endovascular embolization. *J Neurosurg*. 1995;83:843-53. doi: 10.3171/jns.1995.83.5.0843.
  28. Zhang YJ, Barrow DL, Cawley CM, Dion JE. Neurosurgical management of intracranial aneurysms previously treated with endovascular therapy. *Neurosurgery*. 2003;52:283-95. doi: 10.1227/01.neu.0000043643.93767.86.
  29. Daou B, Chalouhi N, Starke RM, Barros G, Yaqoub L, Do J, *et al.* Clipping of previously coiled cerebral aneurysms: efficacy, safety, and predictors in a cohort of 111 patients. *J Neurosurg*. 2016;125(6):1337-43. doi: 10.3171/2015.10.JNS151544.
  30. Lee J, Kim ST, Shim YW, Back JW, Ko JH, Lee WH, *et al.* Microsurgical treatment for the recurrent cerebral aneurysm initially treated using coil embolization. *J Cerebrovasc Endovasc Neurosurg*. 2020;22(3):165-75. doi: 10.7461/jcen.2020.22.3.165.
  31. Waldron JS, Halbach VV, Lawton MT. Microsurgical management of incompletely coiled and recurrent aneurysms: trends, techniques, and observations on coil extrusion. *Neurosurgery*. 2009;64(5 Suppl 2):301-15. doi: 10.1227/01.NEU.0000335178.15274.B4.

### Sažetak

## MIKROKIRURŠKO LIJEČENJE RECIDIVIRAJUĆIH INTRAKRANIJSKIH ANEURIZMA NASTALIH NAKON ENDOVASKULARNIH POSTUPAKA: ILUSTRATIVNI PRIKAZ SERIJE BOLESNIKA I PREGLED LITERATURE

*K. Rotim, V. Kalousek, F. Vrban i B. Splavski*

Mikrokirurški i endovaskularni postupci podjednako su uspješne metode liječenja intrakranijskih aneurizma. Ipak, u novije se vrijeme u njihovom liječenju sve više rabe različite endovaskularne metode zbog svoje minimalne invazivnosti. Međutim, ovi su terapijski postupci povezani s povećanim rizicima recidivirajućeg aneurizmatičkog rasta i ponovne rupture, što pobuđuje potrebu odabira najpovoljnijih strategija za sprječavanje ovakvih rizika. Čini se kako je mikrokirurško selektivno postavljanje klipse na vrat recidivirajuće aneurizme najprikladnija metoda izbora, unatoč tomu što je tehnički izazovna zbog zahtjevnog oblika aneurizme nastalog uslijed prethodnog postavljanja zavojnica u aneurizmatičku vreću. Prikazujući ilustrativnu seriju bolesnika, u radu predstavljamo naša iskustva u liječenju recidivirajućih intrakranijskih aneurizma nastalih nakon endovaskularnog liječenja te raspravljamo prednosti i nedostatke naknadnog mikrokirurškog liječenja temeljem pregleda literature. U skladu s rezultatima ovoga rada, čini se kako je pažljivo mikrokirurško selektivno postavljanje klipse na vrat aneurizme s resekcijom aneurizmatičke vreće i uklanjanjem zavojnica ili bez toga preporučena mogućnost liječenja recidivirajućih intrakranijskih aneurizma, koja osigurava visok stupanj obliteracije i dugoročnu stabilnost okluzije aneurizmatičke vreće, kao i nisku razinu pobola i smrtnosti. Zaključujemo kako multidisciplinarno liječenje recidivirajućih intrakranijskih aneurizma nastalih nakon endovaskularnih postupaka treba biti prilagođeno obliku, veličini i smještaju aneurizme, kao i primjereno potrebama svakog pojedinog bolesnika.

**Ključne riječi:** *Intrakranijska aneurizma, recidivirajuća; Endovaskularno liječenje; Mikrokirurško liječenje; Ishod*