

Martina Čalušić Šarac¹, Sandra Anić Milošević², Domagoj Vražić³, Marko Jakovac⁴

Impact of Gingival Margin Asymmetries on the Smile Esthetic Perception of Dental Specialists, Doctors of Dental Medicine, Students, and Laypeople: a Comparative Pilot Study

Utjecaj asimetričnoga položaja ruba gingive središnjih maksilarnih sjekutića na percepciju osmijeha specijalista, doktora i studenata dentalne medicine te laika

¹ Osijek-Baranja County Health Center

Dom zdravlja Osječko-baranjske županije

² University of Zagreb, School of Dental Medicine, Department of Orthodontics

Zavod za ortodontiju Stomatološkog fakulteta Sveučilišta u Zagrebu

³ University of Zagreb, School of Dental Medicine, Department of Periodontology

Zavod za parodontologiju Stomatološkog fakulteta Sveučilišta u Zagrebu

⁴ School of Dental Medicine, Department of Fixed Prosthodontics

Zavod za fiksnu protetiku Stomatološkog fakulteta Sveučilišta u Zagrebu

Abstract

Objective: To evaluate the perceptions of altered incisor gingival position among dental specialists, dentists, dental students, and laypeople. **Material and methods:** Four digital smile photographs with altered gingival margin position of the right maxillary incisor (0, 1, 2, and 3 mm) were presented to a sample of 232 respondents (71.1% female; 28.9% male): 42 dental specialists, 63 dentists, 33 dental students (1st to 3rd year), 38 dental students (4th to 6th year) and 56 laypeople. The questionnaire consisted of four randomly displayed photographs, administered via Google Form, and respondents were asked to rate the images on a scale from 1 to 5, from the least attractive to the most attractive. A statistical analysis was performed using the TIBCO Statistica program (v. 13.3. 0, TIBCO Software Inc., Palo Alto, CA, USA; 2017). According to the Shapiro- Wilk's test, the data were not distributed normally. The Kruskal-Wallis test with post hoc multiple comparisons with the Bonferroni adjustment were used to compare group esthetic scores and to determine the threshold levels of deviation at which each group was discriminated between esthetic and non-esthetic situations. **Results:** Median values of esthetic scores decreased in all groups as the gingival asymmetries increased. Dental professionals were significantly more critical of esthetics than laypeople in all levels of asymmetry. The greatest difference was found for 2 mm of gingival asymmetry ($p=0.002$). **Conclusion:** From the results of our study, we can conclude that the perception of gingival asymmetries in the esthetic zone of smile differs among dental specialists, doctors, students, and laypeople. Dental specialists, doctors, and clinical students were more critical of these asymmetries, while preclinical students and laypeople noticed only 2 mm or more of gingival asymmetry of central incisors.

Received: January 19, 2022

Accepted: March 14, 2022

Address for correspondence

Marko Jakovac, DMD, MSc, PhD
University of Zagreb
School of Dental Medicine
Department of Fixed Prosthodontics
Gundulićeva 5, 10 000 Zagreb, Croatia
jakovac@sfz.hr**MeSH terms:** Gingiva; Incisor; Dental Esthetics; SmilingMarko Jakovac - <http://orcid.org/0000-0002-2098-4890>
Martina Čalušić Šarac - <https://orcid.org/0000-0003-1323-1433>Domagoj Vražić - <http://orcid.org/0000-0003-4766-048X>
Sandra Anić Milošević - <http://orcid.org/0000-0003-2641-2364>

Introduction

It is said that beauty is in the eyes of the beholder, it is not unified, but it depends on the person who is observing it. The criteria for a beautiful smile vary from person to person even when they are of the same profession. An attractive smile should have symmetric and minimal gingival display, teeth in correct proportion, form, and position, proper shade and color, no interproximal spaces, and harmony between the lower lip and incisal edges of maxillary anterior teeth (1). The ideal shape of the gingival margin is characterized by sev-

Uvod

Kaže se da je ljepota u pogledu promatrača, odnosno ona nije unificirana nego ovisi o osobi koja je promatra. Kriteriji za lijep osmijeh razlikuju se od osobe do osobe, pa čak i kada su one jednake naobrazbe. Atraktivan osmijeh trebao bi uključivati minimalno vidljivu i simetričnu gingivu, zube u pravilnim proporcijama, pravilnog oblika, položaja i boje, bez razmaka te luk osmijeha koji prati zakrivljenost donje usnice (1). Idealnu formu gingivnoga ruba obilježava nekoliko čimbenika od kojih se prema jednomu marginalni rub gingive

eral factors, one of which is that the gingival margin of the upper central incisors should be at the same level (2). Although we learn to apply these principles in our daily work during our education, it is difficult to apply them if they are not quantified and supported by scientific research. Numerous studies have been conducted to examine the perception of smile among specialists, dentists, and laypeople (1, 3, 4, 5). Kokich reported that orthodontists notice specific dental discrepancies easier than laypeople, while dentists and laypeople are similarly critical to maxillary arch deviation, marginal gingival distance, and the gingiva-lips distance (4).

Gingival asymmetry can lead to an unbalanced appearance of a smile (6). The objectives of many studies are to determine the acceptable level of asymmetry and when to perform either periodontal or orthodontic treatment. It has been reported that laypeople do not notice the 1.5 mm of gingival asymmetry, therefore the procedures such as periodontal surgery or orthodontic tooth movement accompanied by composite restoration are often indicated by excessive specialist care, rather than a real esthetic problem. For asymmetries exceeding 2 mm, these procedures are recommended, with an orthodontic approach being preferred because the bone and periodontal tissue move together with the intrusion or extrusion of the tooth (3). In a similar study conducted by Kokich and Kiyak laypeople failed to detect gingival asymmetry of maxillary central incisors from 1.5 mm to 2 mm, while an asymmetry of 0.5 mm was noticed by orthodontists (7).

The aim of this study was to examine how dental education in Croatia affects smile perception. The hypothesis was that laypeople would be less concerned about deviations from ideal gingival symmetries than clinical students, dentists, and dental specialists, while the perception of preclinical students would be similar to that of laypeople.

Material and methods

The research was conducted after the approval of the Ethics Committee of the School of Dental Medicine, University of Zagreb. The image of an attractive female smile, according to objective criteria (1) was taken with a Nikon D750 camera with a macro 105 mm lens, and digitally processed in the computer program Adobe Photoshop 6 (version 6.0, San Jose, California, USA) wherein three modifications were made. The levels of maxillary central incisors gingiva are symmetrical on the original image. In the first modified image, the gingival level of the right central incisor was lowered by 1 mm, 2 mm in the second image, and 3 mm in the third image, all relative to the left incisor (Figure 1). In order to transfer the values to the image in the correct ratio, a millimeter-scale was transferred to the image, also using a Photoshop computer program (Figure 2). A total of 232 respondents: 42 dental specialists, 63 dentists, 33 dental students (1st to 3rd year), 38 dental students (4th to 6th year), and 56 laypeople participated in the study. Voluntary participants were recruited on social media during August and September of 2021. Exclusion criteria for laypeople were professional dentistry knowledge, such as dental technicians and dental hygienists. The ques-

gornjih središnjih sjekutića treba nalaziti u istoj razini (2). Iako tijekom svojega školovanja učimo primjenjivati ta načela u svakodnevnom radu, vrlo ih je teško primijeniti ako nisu kvantificirana i poduprta znanstvenim istraživanjima. U mnogim se studijama ispitivala percepcija osmijeha kod specijalista ili doktora dentalne medicine te laika (1, 3, 4, 5). Kokich i suradnici pokazali su da ortodonti uočavaju specifične dentalne estetske diskrepancije brže od laika, a doktori dentalne medicine i laici podjednako su kritični prema devijaciji sredine maksilarnoga luka, diskrepanciji marginalne gingive i udaljenosti gingive od gornje usnice (4). Asimetrija gingive može dovesti do neuravnoteženoga izgleda osmijeha (6). U kojoj mjeri je ta asimetrija prihvatljiva, kada treba reagirati i primijeniti bilo parodontološku, bilo ortodontsku terapiju, tema je mnogih znanstvenih studija. Objavljeno je da laici ne primjećuju razliku u razini marginalne gingive u iznosu od 1,5 milimetra, pa su zahvati kao oni u parodontnoj kirurgiji ili ortodontski pomak zuba praćen kompozitnom restauracijom kod asimetrija od 0,5 milimetara do 1,5 milimetara, često indicirani pretjeranom brigom specijalista, prije nego realnim estetskim problemom. U slučaju asimetrija koje prelaze dva milimetra preporučaju se navedeni zahvati, pri čemu se prednost daje ortodontskom pristupu jer se pri intruzijskom ili ekstruzijskom pomaku zuba kost i parodontno tkivo pomiču zajedno sa zubom (3). U sličnoj studiji koju su proveli Kokich i Kiyak laici nisu uspjeli detektirati asimetriju od 1,5 do 2 milimetra u razini gingive središnjih sjekutića, a asimetriju od 0,5 milimetara najprije su zamijetili specijalisti ortodoncije (7).

Cilj ove studije bio je istražiti kako dentalno obrazovanje u Hrvatskoj utječe na percepciju osmijeha. Postavljena je hipoteza da će laici biti manje kritični prema odstupanjima od idealne gingivne simetrije od studenata viših godina, doktora i specijalista dentalne medicine, te da će percepcija studenata nižih godina biti slična onoj laika.

Materijal i metode

Istraživanje je provedeno nakon odobrenja Etičkoga povjerenstva Stomatološkog fakulteta Sveučilišta u Zagrebu. Fotografija atraktivnoga ženskoga osmijeha, prema objektivnim kriterijima (1) snimljena je fotoaparatom Nikon D750 s makroobjektivom od 105 milimetara. Nakon toga digitalno je obrađena u računalnom programu Adobe Photoshop Lightroom 6 (version 6.0, San Jose, Kalifornija, SAD) te su učinjene tri modifikacije. Razina marginalnoga ruba gingive središnjih sjekutića na izvornoj fotografiji na istoj je razini. Na prvoj modificiranoj fotografiji razina gingive na desnome središnjem maksilarnom sjekutiću spuštena je za 1 mm; na drugoj fotografiji za dva milimetra, a na trećoj za tri milimetra, sve u odnosu prema lijevom sjekutiću (slika 1.). Kako bi se vrijednosti mogle u točnom omjeru prenijeti na fotografiju, na nju je preneseno milimetarsko mjerilo, također s pomoću računalnog programa Photoshop (slika 2.).

U istraživanju su sudjelovala 232 ispitanika – 42 specijalista, 63 doktora dentalne medicine, 33 studenta od 1. do 3. godine, 38 studenata od 4. do 6. godine te 56 laika. Ispitanici su birani na društvenim mrežama u kolovozu i rujnu 2021. godine. Iz istraživanja isključeni su ispitanici (iz skupi-

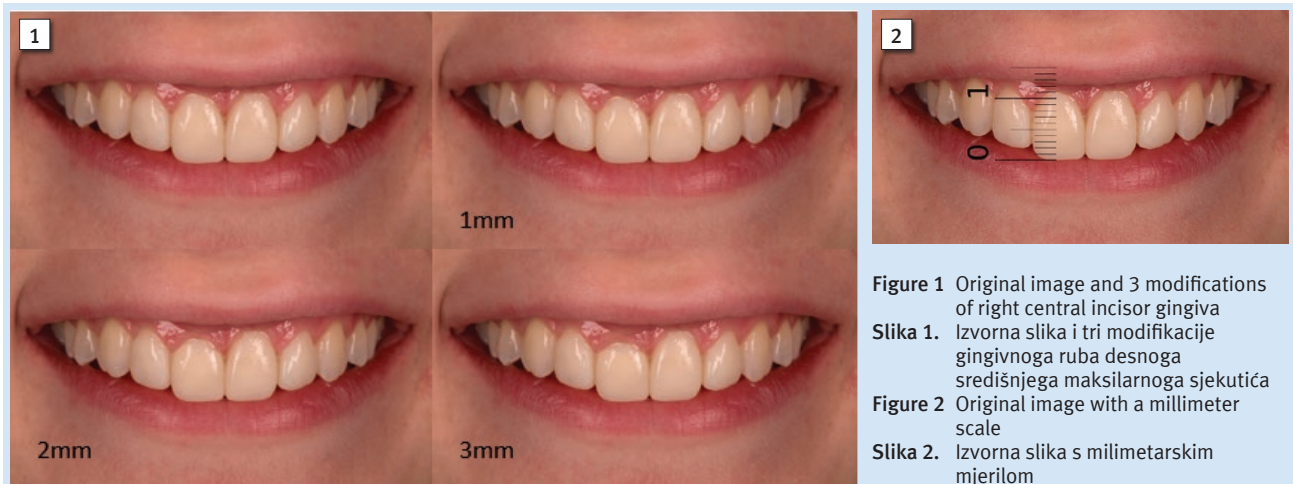


Figure 1 Original image and 3 modifications of right central incisor gingiva

Slika 1. Izvorna slika i tri modifikacije gingivnoga ruba desnoga središnjega maksilarnoga sjekutića

Figure 2 Original image with a millimeter scale

Slika 2. Izvorna slika s milimetarskim mjerilom

tionnaire consisted of 7 questions about demographic and socio-economic characteristics of respondents and 4 photographs (Figure 1), displayed in random order.

Before selecting the appropriate testing, the equivalence of survey responses on different media was assessed. Twenty-four test respondents needed to rate the same image on a computer, mobile phone, and paper with an interval of 7 days between tests. Since there were no statistically significant differences between the answers on different media ($p=0.63$, repeated-measures ANOVA) and a good level of agreement with average measure Intraclass Correlation Coefficient (ICC) of 0.864 with a 95% confidence interval from 0.709 to 0.944 was reached, we decided to use either computer or mobile devices for testing.

The questionnaire was formed using Google Forms and distributed via social media applications. Respondents were asked to rate the images from 1 to 5, or from least attractive to most attractive. They were instructed to rate the photos based on their first impressions and not to return to previous questions.

Statistical analysis

A statistical analysis of the data was performed using the TIBCO Statistica program (v. 13.3. 0, TIBCO Software Inc., Palo Alto, CA, USA; 2017). According to the Shapiro-Wilk's test the data were not distributed normally. Descriptive statistical data were reported as medians and interquartile ranges. The Kruskal-Wallis test including post hoc multiple comparisons with Bonferroni adjustment was used to compare group esthetic scores and to determine the threshold levels of deviation at which each group discriminated between esthetic and un-esthetic situations. The tested hypothesis was that there was no difference between the esthetic scores for digitally altered smiles for each group of raters ($p = 0, 05$).

Results

According to the results of this study, 71.1 % of the participants were female, and 28.9 % of them were male. The median age of the participants was 33 years (IQR 25-36).

ne laika) koji su imali dentalno obrazovanje, kao što su dentalni tehničari ili higijeničari. Upitnik se sastojao od sedam pitanja vezanih za socioekonomski i demografski status te četiri nasumično poredane fotografije (slika 1.). Prije ispitivanja provedena je kalibracija odgovora prikupljenih iz različitih medija. Dvadeset i četiri ispitanika morala su ocijeniti istu fotografiju na mobilnome uređaju, osobnom računalu i papiru, s odmakom od sedam dana između testiranja. Fotografije u digitalnom obliku podijeljene su putem Googleova obrasca. S obzirom na to da nije postojala statistički značajna razlika između odgovora na različitim medijima ($p = 0,63$; ponovljena mjerenja ANOVA-om), te je postignuta dobra razina podudarnosti s prosječnim iznosom koeficijenta korelacije unutar klase (ICC) od 0,864 s 95-postotnim intervalom pouzdanosti od 0,709 do 0,955, odlučeno je da će se istraživanje provoditi putem digitalnih medija, odnosno mobilnih telefona i osobnih računala.

Upitnik je pripremljen u Googleovu obrascu i distribuiran putem društvenih mreža. Ispitanici su fotografije ocjenjivali od 1 do 5, odnosno od najmanje atraktivne do najatraktivnije. Zamoljeni su da ocjene daju na temelju prvoga dojma te da se nakon ocjenjivanja na njih ne vraćaju.

Statistička analiza

Statistička analiza podataka provedena je u programu TIBCO Statistica (v. 13.3. 0, TIBCO Software Inc, Palo Alto, CA, SAD; 2017.). Prema Shapiro-Wilkovu testu podatci nisu bili normalno raspoređeni. Deskriptivna statistika prikazana je kao medijani i interkvartilni rasponi. Kruskal-Wallisov test s post hoc višestrukim usporedbama s Bonferronijevim prilagodbom upotrijebljen je za usporedbu estetskih bodova i za utvrđivanje granice pri kojoj su određene devijacije prihvatljive ispitnim skupinama. Testirana hipoteza bila je da nema razlike između estetskih ocjena za digitalno promijenjene osmijehe za svaku skupinu ocjenjivača ($p = 0,05$).

Rezultati

Prema rezultatima ovog istraživanja, 71,1 % ispitanika bile su žene, a 28,9 % muškarci. Srednja dob ispitanika bila je 33 godine (IQR 25 – 36).

Table 1 Descriptive statistics
Tablica 1. Deskriptivna statistika

Asymmetry • Asimetrija	Group • Skupina	N	Median* • Medijan*	IQR	Mean • Prosjek	Std. Dev.	95% CI	Min.	Max.	P
0 mm	Specialists • Specijalisti	41	5.0	4.0-5.0	4.6	0.5	0.4-0.6	4.0	5.0	
	Dentists • Dr. med. dent.	66	5.0	4.0-5.0	4.5	0.7	0.6-0.9	2.0	5.0	
	Students (1-3y) • Studenti (1.- 3. g.)	32	5.0	4.0-5.0	4.5	0.7	0.5-0.9	3.0	5.0	
	Students (4-6y) • Studenti (4.- 6. g.)	37	5.0	4.0-5.0	4.7	0.5	0.4-0.7	3.0	5.0	
	Laypeople • Laici	56	5.0	4.0-5.0	4.5	0.7	0.6-0.9	2.0	5.0	0.063
1 mm	Specialists • Specijalisti	41	4.0 ^{ab}	3.0-4.0	3.5	0.9	0.7-1.1	1.0	5.0	
	Dentists • Dr. med. dent.	66	3.0 ^b	3.0-4.0	3.5	0.7	0.6-0.9	2.0	5.0	
	Students (1-3y) • Studenti (1.- 3. g.)	32	4.0 ^{ac}	3.0-5.0	4.0	0.8	0.6-1.0	3.0	5.0	
	Students (4-6y) • Studenti (4.- 6. g.)	37	4.0 ^{ab}	3.0-4.0	3.8	0.9	0.7-1.1	2.0	5.0	
	Laypeople • Laici	56	4.0 ^{ac}	3.5-4.0	3.9	0.8	0.7-1.0	1.0	5.0	0.001
2 mm	Specialists • Specijalisti	41	2.0 ^a	2.0-3.0	2.2	0.9	0.7-1.1	1.0	5.0	
	Dentists • Dr. med. dent.	66	2.0 ^a	2.0-3.0	2.4	0.7	0.6-0.9	1.0	4.0	
	Students (1-3y) • Studenti (1.- 3. g.)	32	3.0 ^{ab}	2.0-3.0	2.8	0.9	0.7-1.2	1.0	5.0	
	Students (4-6y) • Studenti (4.- 6. g.)	37	3.0 ^{ab}	2.0-3.0	2.4	0.8	0.6-1.0	1.0	4.0	
	Laypeople • Laici	56	3.0 ^b	2.0-4.0	2.9	1.0	0.8-1.2	1.0	5.0	<0.001
3 mm	Specialists • Specijalisti	41	1.0 ^a	1.0-2.0	1.6	0.8	0.7-1.0	1.0	5.0	
	Dentists • Dr. med. dent.	66	2.0 ^{ab}	1.0-2.0	1.9	0.8	0.7-0.9	1.0	4.0	
	Students (1-3y) • Studenti (1.- 3. g.)	32	2.0 ^{ab}	1.0-3.0	2.1	0.8	0.7-1.1	1.0	3.0	
	Students (4-6y) • Studenti (4.- 6. g.)	37	2.0 ^{ab}	1.0-2.0	1.8	0.8	0.7-1.0	1.0	4.0	
	Laypeople • Laici	56	2.0 ^b	1.5-3.0	2.2	0.9	0.7-1.1	1.0	4.0	0.003

* Kruskal-Wallis test with post hoc multiple comparisons with Bonferroni adjustment were used to compare group esthetic scores. Shared superscripts (a, b, c) indicate $p > 0.05$ with no significant differences between variables, whereas values that do not share letters in superscript within the same asymmetry amount (1mm/2mm/ 3 mm) differ significantly ($p < 0.05$). • Kruskal-Wallisov test s post hoc višestrukim usporedbama s Bonferronijevom prilagodbom upotrijebljen je za usporedbu grupnih estetskih ocjena. Zajednički superskripti (a, b, c) označavaju $p > 0,05$, bez značajnih razlika između varijabli, a vrijednosti koje ne dijele slova u superskriptu unutar su istoga iznosa asimetrije (1 mm/2 mm/3 mm) značajno se razlikuju ($p < 0,05$).

There was no difference in esthetic scores between groups for photographs with symmetrical gingiva of central maxillary incisors, but esthetic scores for all levels of gingival asymmetries differed significantly between participant groups. Descriptive statistics and median values of esthetic scores of images with 0, 1, 2 and 3 mm of gingival asymmetries are presented in Table 1.

Gingival asymmetry of 2 mm was necessary before laypeople rated it non-esthetic. The threshold for pre-clinical students was also 2 mm of asymmetry. Specialists, dentists, and students from 4th to 6th year were able to detect gingival asymmetry of 1 mm and rated it significantly less esthetic ($p < 0,003$).

Discussion

Batra et al. reported: "The untrained eye seemed to be more sensitive to changes in the central incisors than in the lateral incisors or canines and when the changes were unilateral rather than bilateral." (8). The goal of modern dental professionals is to satisfy the esthetic requirements of patients in addition to treatment (9). Accepting these requirements can be a guide to improve dental esthetics (10). Gingival asymmetry can be treated by a multidisciplinary approach, but it is necessary to know how much asymmetry is acceptable to our patients. Previous studies showed that dental specialists were more critical of gingival asymmetries than laypersons (3, 7, 11). The results of our study are in agreement with these

Nije bilo razlike u estetskim ocjenama među skupinama za fotografije sa simetričnom gingivom središnjih maksimalnih sjekutića, ali se ocjene za sve razine gingivalnih asimetrija značajno razlikuju između ispitnih skupina. Deskriptivna statistika i medijani estetskih ocjena fotografija s 0, 1, 2 i 3 milimetra asimetrije gingive prikazani su u tablici 1.

Asimetrija gingive od dva milimetra bila je potrebna da bi je laici ocijenili neestetskom. Prag prihvatljive asimetrije za studente nižih godina studija također je bio dva milimetra. Specijalisti, doktori dentalne medicine i studenti od 4. do 6. godine uspješni su detektirati gingivnu asimetriju od jednoga milimetra i ocijeniti je značajno manje estetskom ($p < 0,003$).

Rasprava

Batra i suradnici izvijestili su kako se čini da je neuvježbano oko osjetljivije na promjene na središnjim, nego na bočnim sjekutićima ili očnjacima i kada su promjene unilateralne, a ne bilateralne (8). Zadaća suvremenoga doktora dentalne medicine jest, uz liječenje, zadovoljiti i estetske zahtjeve pacijenata (9). Prihvaćanje tih zahtjeva može biti vodič za poboljšanje dentalne estetike (10). Asimetrija gingive može se liječiti multidisciplinarnim pristupom, no potrebno je znati u kojem je opsegu prihvatljiva pacijentima. U dosadašnjim studijama istaknuto je da su doktori dentalne medicine kritičniji prema asimetriji gingive nego laici (3, 7, 11). Rezultati našeg istraživanja u skladu su s navedenim studija-

findings as we reported that specialists could detect 1 mm of gingival asymmetry, unlike laypeople who were unable to see gingival asymmetry less than 2 mm. Dental students present a higher level of awareness towards dental esthetics (12), and their perception is different depending on their stage of education. Preclinical students rated the asymmetry of 2 mm non-esthetic, similarly to laypeople. This may be due to a lack of dental courses in their first years of studies because students are then mostly focused on general medicine courses. From 4th to 6th year, students attend more dental courses and clinical practicals; hence they are more critical to small deviations from an ideal smile. Many studies were conducted to investigate the students' perceptions of altered smile esthetics (13, 14, 15) but these studies comprised only symmetric situations. The results obtained in our study show that we should have a very good communication with patients to avoid "overtreating" them if they have gingival asymmetry of 2 mm or less. If gingival asymmetry of central maxillary incisors exceeds 2 mm, a treatment is needed- either orthodontic or periodontal. The orthodontic intrusion of the teeth has been considered problematic for many years, but today it is a safe and commonly used procedure during fixed orthodontic treatment. Intrusion of a single tooth requires light continuous forces in young patients and light interrupted forces in adult patients, as the apical bone region of some adult patients tend to be more compact (16). Intrusion of a tooth should be followed by a composite restoration or veneer. From the periodontal point of view, the esthetics of soft tissues around the teeth is greatly impacted by undisturbed supracrestal tissue attachment, previously known as biologic width, which consists of junctional epithelium and supracrestal connective tissue attachment (17). The clinical dimension can vary among patients for same group types of teeth, and can show higher clinical value than histologically accepted mean dimension of 3 mm, as demonstrated by Perez in 2008 (18). This should be taken into consideration when planning clinical crown lengthening procedures, which is mostly performed through periodontal surgery and can demonstrate significant soft tissue rebound through a healing period of 6 to 12 months (19,20) or gingival recession (21). These procedures include apically repositioned flap that usually includes bone resection, gingivectomy, and gingivoplasty which can be performed with conventional scalpel, electrosurgery, or dental laser (22).

The tested hypothesis has been supported by findings in this research. The threshold level for gingival asymmetry of central incisors was 2mm for laypeople and preclinical students, while the threshold level for clinical students, dentists, and dental specialists was 1mm. Our results indicate that dental education in Croatia affects students' perception of smile. On a higher level of education, dental students notice smaller deviations from an ideal smile.

The first limitation of this study is a small number of participants in groups with students and specialists, which is not consistent with similar studies (23). The second limitation is the unfavorable distribution of participants' age and gender. It was not possible to test whether there are differences between genders, or different ages of participants within groups (specialists, dentists, students, and laypeople).

ma jer su specijalisti detektirali jedan milimetar gingivalne asimetrije, za razliku od laika koji nisu uočili onu manju od dva milimetra. Studenti dentalne medicine imaju višu razinu svijesti o dentalnoj estetici (12), a njihova percepcija se razlikuje s obzirom na stupanj obrazovanja. Pretklinički studenti ocijenili su asimetriju od dva milimetra neestetskom, slično kao i laici. Razlog za to može biti nedostatak dentalnih kolegija na prvim godinama studija jer su studenti tada usmjereni na opću medicinu. Studenti od 4. do 6. godine pohađaju više dentalnih tečajeva i kliničkih vježbi te su zato kritičniji kada je riječ o malim odstupanjima od idealnog osmijeha. Provedena su mnoga istraživanja kako bi se ispitala percepcija studenata o promijenjenoj estetici osmijeha (13, 14,1 5), no uključivala su samo simetrične situacije. Rezultati našeg istraživanja pokazuju da je potrebna vrlo dobra komunikacija s pacijentima kako ih se ne bi preopteretilo liječenjem ako imaju gingivnu asimetriju od dva milimetra ili manje. Ako gingivalna asimetrija središnjih maksilarnih sjekutića prelazi dva milimetra, potrebno je liječenje – ortodontsko ili parodontološko. Ortodontska intruzija zuba godinama se smatrala izazovnim pomakom, no danas je to siguran i uobičajen zahvat tijekom liječenja fiksnom ortodontskom napravom. Intruzija jednoga zuba zahtijeva laganu kontinuiranu silu za mlade pacijente i laganu isprekidanu silu za odrasle zato što je apikalno područje kosti nekih odraslih pacijenata obično kompaktnije (16). Intruziju zuba treba slijediti kompozitni ili protetički nadomjestak. S parodontološkog stajališta, na estetiku mekih tkiva oko zuba uvelike utječe intaktni pričvrstak suprakrestalnoga tkiva, poznat kao biološka širina, koji se sastoji od spojnoga epitela i suprakrestalnoga vezivnoga tkiva (17). Klinička dimenzija može varirati među pacijentima za istu skupinu zuba i pokazati veću kliničku vrijednost od histološki prihvaćene srednje dimenzije od tri milimetra, kao što je pokazao Perez 2008. godine (18). Navedeno treba uzeti u obzir pri planiranju zahvata za produljenje kliničke krune zuba koji se najčešće obavlja na odjelu za parodontalnu kirurgiju, a može značajno oporaviti meko tkivo tijekom cijeljenja koje traje od 6 do 12 mjeseci (19, 20) ili recesije gingive (21). Zahvat uključuje apikalno repositionirani režanj koji obično podrazumijeva resekciju kosti, gingivektomiju i gingivoplastiku koja se može učiniti konvencionalnim skalpelom, elektrokirurškim nožem ili dentalnim laserom (22).

Rezultati istraživanja potvrdili su hipotezu – prag estetske prihvatljivosti za gingivnu asimetriju središnjih sjekutića jest dva milimetra za laike i pretkliničke studente, a za studente viših godina studija, doktore i specijaliste dentalne medicine iznosi jedan milimetar. Rezultati ove studije pokazuju da dentalno obrazovanje u Hrvatskoj utječe na percepciju osmijeha kada je riječ o studentima. Oni na višoj razini obrazovanja primjećuju manja odstupanja od idealnog osmijeha.

Prvo ograničenje ovoga istraživanja jest mali broj ispitanika u skupinama sa studentima i specijalistima, što nije u skladu sa sličnim studijama (23). Drugo je ograničenje nepovoljna raspodjela dobi i spola sudionika. Nije bilo moguće provjeriti postoje li razlike između spolova ili različite dobi sudionika unutar skupina (specijalisti, doktori dentalne medicine, studenti i laici).

Conclusions

From the results of our study, we can conclude that perception of gingival asymmetries in the esthetic zone of smile differs among dental specialists, doctors, students, and laypeople. Dental specialists, doctors, and clinical students are more critical of these asymmetries, while preclinical students and laypeople notice only 2 mm or more of gingival asymmetry of central incisors. We should, therefore, communicate with our patients in order to find the best way to finish our dental treatment, without “overtreating” them but trying to please both their demands and ours.

Conflict of interest

None declared.

Acknowledgement

Partial information from this study has been presented at the *2nd SIDO - 18th AIDOR International Congress* in Florence, Italy, from the 11th to 13th of November 2021. (https://sido_aidor_congresso2021.sido.it/en/ContributiScientifici/Posters/Authors).

Author's contribution: M.J, M.Č.Š. - conceptualized and wrote the study; S.A.M. - scientific and intellectual contribution, review of the first draft; D.V. - scientific contribution

Zaključak

Rezultati studije sugeriraju da se percepcija gingivalnih asimetrija u estetskoj zoni osmijeha razlikuje između specijalista, doktora, studenata dentalne medicine i laika. Specijalisti, doktori dentalne medicine i studenti viših godina studija kritičniji su prema tim asimetrijama, a studenti nižih godina i laici primjećuju dva milimetra ili više gingivalne asimetrije središnjih sjekutića. Zato bismo trebali razgovarati s našim pacijentima kako bismo pronašli najbolji način da završimo terapiju, bez pretjeranih zahvata, a da zadovoljimo i njihove i naše zahtjeve.

Sukob interesa

Autori nisu bili u sukobu interesa.

Zahvala

Djelomične informacije iz ove studije predstavljene su na 2. SIDO-u – 18. međunarodnom kongresu AIDOR-a u Firenci (Italija) od 11. do 13. studenoga 2021. (https://sido_aidor_congresso2021.sido.it/en/ContributiScientifici/Posters/Autori)

Doprinos autora: M. J, M. Č. Š. – osmislili i napisali studiju; S. A. M. – znanstveni i intelektualni doprinos, osvrt na prvi nacrt; D. V. – znanstveni doprinos

Sažetak

Svrha rada: Ispitati percepciju asimetričnoga položaja gingive među specijalistima, doktorima i studentima dentalne medicine te laicima. **Materijali i metode:** Četiri fotografije osmijeha s izmijenjenom razinom gingive desnoga središnjega gornjega sjekutića (0, 1, 2 i 3 mm) pokazane su uzorku od 232 ispitanika (71,1 % žena i 28,9 % muškaraca). Među njima su bila 42 specijalista dentalne medicine, 63 doktora dentalne medicine, 33 studenta dentalne medicine od 1. do 3. godine studija, 38 studenata dentalne medicine od 4. do 6. godine studija te 56 laika. Upitnik, u obliku Googleova obrasca, sadržavao je četiri nasumično poredane fotografije koje su ispitanici ocjenjivali ljestvicom od 1 (najmanje atraktivno) do 5 (najviše atraktivno). Statistička analiza učinjena je u programu TIBCO Statistica (v.13.3.0, TIBCO Software Inc, Palo Alto, CA, SAD; 2017). Rezultati Shapiro-Wilkova testa pokazali su da podatci ne prate normalnu razdiobu. Kruskal-Wallisov test s višestrukim post hoc testiranjima, koji su uključili i Bonferronijevu prilagodbu, primijenjeni su za usporedbu estetskih ocjena i za određivanje granice pri kojoj su određene devijacije prihvatljive ispitnim skupinama. **Rezultati:** S porastom iznosa gingivalne asimetrije, srednje vrijednosti estetskih bodova (ocjena) padaju u svim ispitnim skupinama. Ispitanici s dentalnim obrazovanjem bili su značajno kritičniji u ocjenjivanju svih stupnjeva asimetrije. Najveća razlika utvrđena je za asimetriju u iznosu od dva milimetra ($p = 0,002$). **Zaključak:** Rezultati studije pokazuju da se percepcija gingivalne asimetrije u estetskoj zoni osmijeha razlikuje između specijalista, doktora, studenata dentalne medicine i laika. Specijalisti, doktori i studenti dentalne medicine viših godina kritičniji su prema navedenim asimetrijama, a studenti nižih godina i laici primjećuju tek gingivalnu asimetriju središnjih sjekutića od dva milimetra.

Zaprimljen: 19. siječnja 2022.

Prihvaćen: 14. ožujka 2022.

Adresa za dopisivanje

dr. sc. Marko Jakovac, dr. med.
Sveučilište u Zagrebu
Stomatološki fakultet
Zavod za fiksnu protetiku
Gundulićeva 5
10 000 Zagreb, Hrvatska
jakovac@sfzg.hr

MeSH pojmovi: gingiva; sjekutići; dentalna estetika; osmijeh

References

- Machado AW, Moon W, Gandini LG. Influence of maxillary incisor edge asymmetries on the perception of smile esthetics among orthodontists and laypersons. *Am J Orthod Dentofacial Orthop.* 2013;143(5):658-64.
- Kokich VG. Esthetics: the orthodontic-periodontic restorative connection. *Semin Orthod.* 1996;2(1):21-30.
- Pinho S, Ciriaco C, Faber J, Lenza MA. Impact of dental asymmetries on the perception of smile esthetics. *Am J Orthod Dentofacial Orthop.* 2007;132(6):748-53.
- Kokich VO Jr, Kiyak HA, Shapiro PA. Comparing the perception of dentists and lay people to altered dental esthetics. *J Esthet Dent.* 1999;11(6):311-24.
- Khan M, Kazmi SMR, Khan FR, Samejo I. Analysis of different characteristics of smile. *BDJ Open.* 2020; 5:6:6. doi: 10.1038/s41405-020-0032-x.
- Chu SJ, Tan JHP, Stappert CF, Tarnow DP. Gingival zenith position and levels of the maxillary anterior dentition. *Journal compilation 2009. Wiley periodicals, INC.* 2009;21(2):113-120.
- Kokich VO, Kokich VG, Kiyak HA. Perceptions of dental professionals and laypersons to altered dental esthetics: asymmetric and symmetric situations. *Am J Orthod Dentofacial Orthop.* 2006;130(2):141-51.
- Batra P, Daing A, Azam I, Miglani R, Bhardwaj A. Impact of altered gingival characteristics on smile esthetics: Laypersons' perspectives by Q sort methodology. *Am J Orthod Dentofacial Orthop.* 2018;154(1):82-90.
- Umer F, Khan FR, Khan, A. “Zlatni omjer” vidljivoga zubnog osmijeha u pakistanskoj populaciji: eksperimentalno istraživanje. *Acta Stomatol Croat.* 2010;44 (3):168-77.
- Kristek Zorić E, Žagar M, Knezović Zlatarić D. Influence of Gender

- on the Patient's Assessment of Restorations on the Upper Anterior Teeth. *Acta stomatol Croat.* 2014;48(1):33-41.
11. Alomari SA, Alhaija ESA, AlWahadni AM, Al-Tawachi AK. Smile microesthetics as perceived by dental professionals and laypersons. *Angle Orthod.* 2022;92(1):101-109.
 12. Laus I, Kovačević Pavičić D, Brumini M, Perković V, Pavlić A, Špalj S. Effects of Visual Stimuli from Media on the Perception of Dentofacial Esthetics. *Acta stomatol Croat.* 2020;54(3):283-293.
 13. Aljefri M, Williams J. The perceptions of preclinical and clinical dental students to altered smile aesthetics. *BDJ Open.* 2020;14;6:16. doi: 10.1038/s41405-020-00045-2.
 14. Abu Alhaija ES, Al-Shamsi NO, Al-Khateeb S. Perceptions of Jordanian laypersons and dental professionals to altered smile aesthetics. *Eur J Orthod.* 2011;33(4):450-6.
 15. España P, Tarazona B, Paredes V. Smile esthetics from odontology students' perspectives. *Angle Orthod.* 2014;84(2):214-24.
 16. Graber LW, Vanarsdall RL, Vig KWL, Huang GJ. *Orthodontics: Current Principles and Techniques.* 6th ed. St. Louis: Elsevier, 2017. 71 p.
 17. Jepsen S, Caton JG, Albandar JM, Bissada NF, Bouchard P, Cortellini P, Demirel K, de Sanctis M, Ercoli C, Fan J, Geurs NC, Hughes FJ, Jin L, Kantarci A, Lalla E, Madianos PN, Matthews D, McGuire MK, Mills MP, Preshaw PM, Reynolds MA, Sculean A, Susin C, West NX, Yamazaki K. Periodontal manifestations of systemic diseases and developmental and acquired conditions: Consensus report of workgroup 3 of the 2017 World Workshop on the Classification of Periodontal and Peri-Implant Diseases and Conditions. *J Periodontol.* 2018;89(1):237-48.
 18. Perez JR, Smukler H, Nunn ME. Clinical dimensions of the supraosseous gingivae in the healthy periodontium. *J Periodontol.* 2008;79(12):2267-72.
 19. Deas DE, Moritz AJ, McDonnell HT, Powell CA, Mealey BL. Osseous surgery for crown lengthening: a 6-month clinical study. *J Periodontol.* 2004;75(9):1288-94.
 20. Pontoriero R, Carnevale G. Surgical crown lengthening: a 12-month clinical wound healing study. *J Periodontol.* 2001;72(7):841-8.
 21. Brägger U, Lauchenauer D, Lang NP. Surgical lengthening of the clinical crown. *J Clin Periodontol.* 1992;19(1):58-63.
 22. Majzoub ZAK, Romanos A, Cordioli G. Crown lengthening procedures: a literature review. *Semin Orthod.* 2014; 20(3):188-207.
 23. Koseoglu M, Bayindir F. Effects of gingival margin asymmetries on the smile esthetic perception of dental professionals and laypeople. *J Esthet Restor Dent.* 2020; 32(5):480-6.