

## MYELOID SARCOMA IN THE CENTRAL NERVOUS SYSTEM: CASE REPORT AND REVIEW OF THE LITERATURE

Walter Struhal<sup>1</sup>, Stefan Oberndorfer<sup>1</sup>, Heinz Lahrmann<sup>1</sup>, Elisabeth Lindeck-Pozza<sup>1</sup>, Barbara Hess<sup>1</sup>, Vera Nussgruber<sup>1</sup>, Rainer Pöhl<sup>2</sup>, Thomas Dobner<sup>3</sup> and Wolfgang Grisold<sup>1</sup>

<sup>1</sup>Department of Neurology; <sup>2</sup><sup>3</sup>rd Medical Department of Oncology, Kaiser Franz Josef Spital; <sup>3</sup>Department of Neurosurgery, Krankenanstalt Rudolfstiftung, Vienna, Austria

**SUMMARY** – Myeloid sarcomas are rare manifestations of mainly myeloblastic leukemia. Their occurrence in the central nervous system is exceptional and current literature is limited to case studies. A case is added herewith and a review was performed to investigate clinical characteristics and treatment options of central nervous system myeloid sarcoma. A 61-year-old female with acute myeloblastic leukemia (FAB M5) and progressive left sided hemiparesis showed a right parieto-occipital epidural lesion mimicking meningioma. Partial resection was performed to reveal a myeloid sarcoma. Reviewing the literature we identified 44 cases with sufficient description of the diagnosis, treatment and follow up to one year. In these patients different treatment regimens were applied. However, when systemic chemotherapy or irradiation was included in the treatment regimen, patients showed the best 1-year survival proportion.

**Key words:** *Leukemia myeloid – complications; Meningeal neoplasms – diagnosis; Central nervous system – pathology*

### Introduction

Myeloid sarcomas are tumor masses composed of leukemic myeloblasts or immature myeloid cells<sup>1</sup>. These rare tumors develop in several organs, mainly the skin, and might bear an extent mass effect on the surrounding structures. Myeloid sarcomas are most frequently associated with acute myeloid leukemia (AML), but may also occur in myeloproliferative and myelodysplastic syndromes<sup>2</sup>, in bone marrow transplanted patients<sup>3</sup>, or without a known cause (isolated myeloid sarcoma). Two thirds of patients with isolated myeloid sarcoma develop AML within a median time of 9 months<sup>4</sup>.

In rare cases, myeloid sarcomas develop in the brain, spinal or meningeal tissue<sup>5</sup>. These central nervous system (CNS) manifestations arise most frequently during the course of active disease or upon remission of leukemia<sup>6</sup>.

It appears to be an established tradition in the current literature to give an opinion about the many synonyms for the entity we call myeloid sarcoma. We do not want to break with this tradition but have collected all synonyms we came across in the literature from 1970. These are: myeloid sarcoma, granulocytic sarcoma, chloroma, myeloblastoma, chloromyeloma, chloromyelosarcoma, granulocytic leukosarcoma, or myelosarcoma. The commonly used terms are “granulocytic sarcoma”<sup>7</sup> and “chloroma”<sup>8</sup>. However, we felt it might be worthwhile following the WHO classification and used the term “myeloid sarcoma”<sup>9</sup>.

The aim of this study was to add one more case of CNS myeloid sarcoma to the limited literature, and to review CNS myeloid sarcomas published in the last decades.

### Methods

For the review, a Pubmed query was performed employing the above mentioned synonyms. We evaluated all hits reporting myeloid sarcoma patients aged 18 years

Correspondence to: *Walter Struhal, MD*, Department of Neurology, AKH Linz, Krankenhausstraße 9, A-4021 Linz, Austria  
E-mail: [walter.struhal@akh.linz.at](mailto:walter.struhal@akh.linz.at)  
Received September 12, 2007, accepted February 21, 2008

or older. Sixty five reports on 76 patients with myeloid sarcomas related to the CNS and published in English were found between 1970 and December 2006. Due to several limitations of accuracy such as short duration of follow up, and missing clinical data, only 44 out of 76 case descriptions could be included for a structured review.

We evaluated: (I) sex, (II) age, (III) first clinical or radiological interpretation, (IV) localization, (V) underlying hematological disease, (VI) therapy administered, and (VII) time of survival from the diagnosis of granulocytic sarcoma. Only cases with documented survival data, or at least one year follow up, were included in statistical analysis. In order to evaluate the outcome of different treatment regimens, calculation of one year survival proportion was performed.

## Results

### Case report

A 61-year-old female patient was admitted to a local hospital for febrile state, weight loss, increased sweating and fatigue lasting for a week. White blood count

suggested leukemia and bone marrow biopsy revealed acute myeloid leukemia (AML FAB M5). She received induction therapy (cytosine arabinoside and idarubicin) and was planned for a second chemotherapy cycle, which she rejected. Ten months later she noticed weakness in her left leg followed by weakness in her left arm. She refused to seek medical advice. Initially symptoms progressed slowly; she could walk but needed help on climbing stairs. Three months later she experienced rapid deterioration of left hemiparesis during several days and was admitted to a local hospital. At admission she showed hemiplegia of the left extremities, and a neglect syndrome on the left side. MRI scan showed a right sided parieto-occipital lesion fulfilling radiological criteria for meningioma (Fig. 1a), and she was referred to neurosurgery. Complete resection was impossible due to soft tissue properties of the tumor. Histological workup revealed a myeloid sarcoma, positive for myeloperoxidase, CD 68, CD45, CLA. Chromosome analysis showed a normal result. Postoperatively contrast CCT demonstrated residual myeloid sarcoma and whole brain irradiation (20 Gy) was performed. In addition, she received corticosteroid therapy and physiotherapy. CCT one month after radiation showed complete regression of the resid-

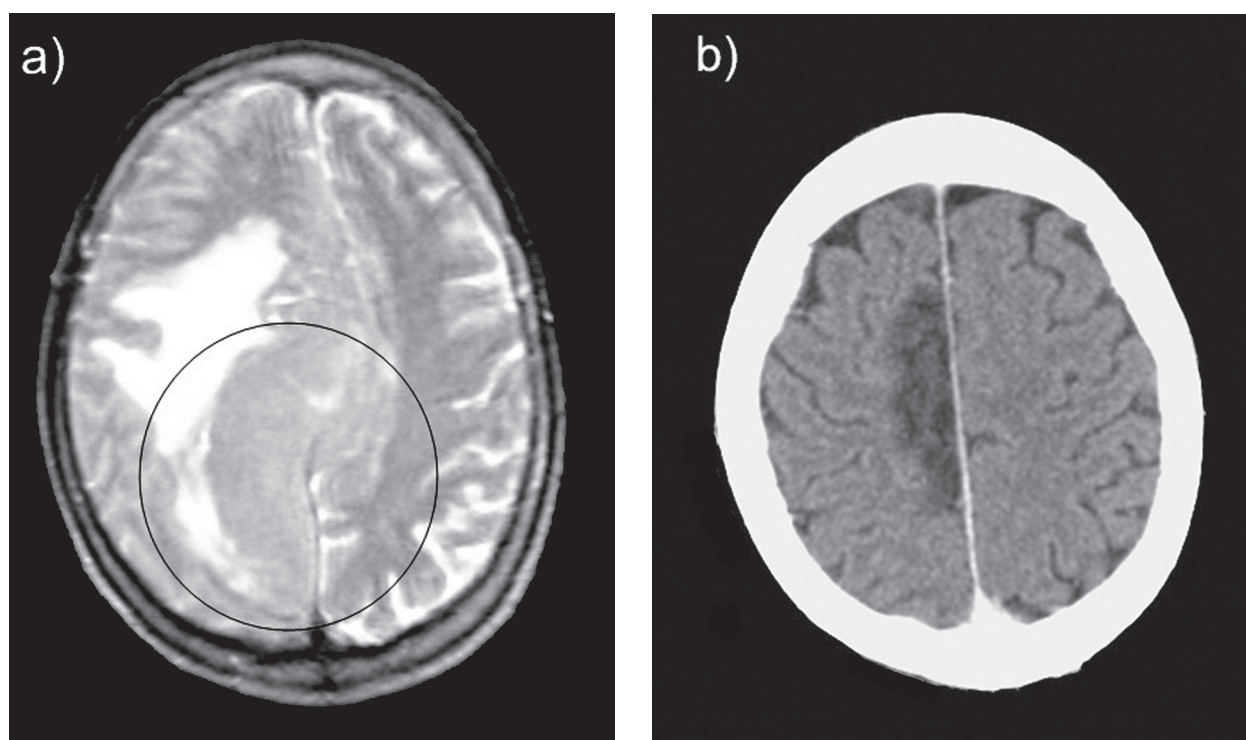


Fig. 1. (a) MRI T2 weighted preoperative image: large parieto-occipital tumor; radiological interpretation: meningioma; (b) CT scan 1 month after radiation: parieto-occipital defect, no midline shift.

uals (Fig. 1b). Her neurological conditions stayed unchanged for one month after the operation and gradually improved thereafter. After two additional months she had no neuropsychological deficit left and only moderate hemiparesis, she could walk and was able to be discharged home under the care of her relatives. However, she refused systemic chemotherapy and her leukemia relapsed after 7 months. Subsequently she died at home due to progression of leukemia.

## Review

With respect to analysis of all other parameters, only 44 reviewed cases plus our case could be included. Median age of these 45 cases was 36 (range: 18-77) years; there were 15 female and 30 male patients (ratio: 1/2); total median survival time was 6 months. Survival in patients with myeloid sarcoma in the brain (20 patients, 6.5 months) was similar to patients with myeloid sarcoma in the spinal cord (25 patients, 6 months).

Variable treatment regimes were applied. In most cases several treatment modalities were combined. Only 12 out of 40 cases were treated with monotherapy (surgery, irradiation or intrathecal chemotherapy). Three patients received no treatment due to poor clinical condition. Most frequently (11 cases) a combination of systemic chemotherapy and local irradiation was used (Ta-

ble 1). Looking at individual treatment strategies, best results were obtained when systemic chemotherapy or irradiation was applied (Table 2).

## Discussion

Myeloid sarcoma in AML patients is regularly described in the literature, but CNS manifestations are rare. For diagnosing myeloid sarcoma and distinguishing between its variants immunohistochemistry is the most powerful tool and regarded as essential. Our case was positive for CD45 demonstrating the leukocytic origin of the neoplastic cells, myeloperoxidase, which is often observed in myeloblastic variants and CD68, a nonspecific antigen of monocytes and macrophages<sup>1</sup>. The immunophenotype of our case might be therefore interpreted as myelomonoblastic variant.

MRI findings of our patient were initially misinterpreted as meningioma, fulfilling radiological criteria, such as broad contact of tumor to the meninges, tumor capsules, meningeal contrast enhancement, and edema. This differential diagnosis had already been reported<sup>10</sup>, and is worth considering in leukemia patients.

Due to the rare occurrence, generally accepted guidelines regarding the treatment of CNS myeloid sarcomas are missing. Analysis of the current literature revealed several distinct features. Various treatment strategies

Table 1. Treatment regimens in myeloid sarcoma: individual treatment regime, location and survival in months (range)

Therapeutic regimes applied	n	Site		Survival range (months)
		Cranial	Spinal	
<b>No therapy</b>	3	2	1	<1 – 1
<b>One therapeutic option applied</b>				
Intrathecal chemotherapy	1		1	1
Irradiation	2	1	1	3 -14
Surgery	9	5	4	<1-14
<b>Two therapeutic options applied</b>				
Chemotherapy systemic and intrathecal	1		1	20
Irradiation and systemic chemotherapy	11	3	8	1 – 39
Surgery and systemic chemotherapy	1	1		1
Surgery and intrathecal chemotherapy	1		1	2
Surgery and irradiation	2	1	1	8 –114
<b>Three therapeutic options applied</b>				
Irradiation, systemic chemotherapy, intrathecal chemotherapy	2	1	1	6 – 10
Surgery, irradiation, chemotherapy (intrathecal, systemic)	1	1		>21
Surgery, irradiation, intrathecal chemotherapy	1	1		5
Surgery, irradiation, systemic chemotherapy	10	4	6	1 - >121

Table 2. Outcome of different treatment modalities – linkage between therapies and 1-year survival proportion

Treatment modality	n	Site		Survival range (months)
		Cranial	Spinal	1 yr survival proportion
Systemic chemotherapy (always together with other therapies)	26	10	16	46%
Therapies other than systemic chemotherapy	19	10	9	16%
Irradiation (either single therapy or together with other therapies)	29	12	17	45%
Therapies other than irradiation	16	8	8	13%
Intrathecal chemotherapy (either as single therapy or together with other therapies)	7	3	4	29%
Therapies other than intrathecal chemotherapy	38	17	21	34%
Surgery (either single therapy or together with other therapies)	25	13	12	36%
Therapies other than surgery	20	7	13	30%

were used, mostly systemic or intrathecal chemotherapy, irradiation or surgery (Table 1). In our case, treatment after the diagnosis of myeloid sarcoma was limited to surgery and irradiation, although systemic chemotherapy was suggested.

The review of 45 cases of myeloid sarcoma in the CNS revealed no clear advantage of any combination of the treatment options available (Table 2); however, the patients receiving systemic chemotherapy might have an advantage with 46% one year survival as compared with 16% one year survival in patients who were treated with other methods. Yamamoto *et al.*, having reported one case and reviewed another 7 cases in 1999, state that systemic chemotherapy plays an important role in the treatment of CNS myeloid sarcoma<sup>11</sup>. The present review, now containing 45 cases, emphasizes the statement that systemic chemotherapy could be useful. A possible explanation for the favorable effect of systemic chemotherapy could be that the presence of isolated myeloid sarcoma heralds bone marrow relapse<sup>11,12</sup>. Therefore, addressing the underlying hematologic disease by systemic chemotherapy might increase overall survival.

In addition, focal irradiation might have a favorable effect on one year survival (45% with irradiation as compared with 13% without it).

Seven patients reported in the literature (3 cerebral and 4 spinal) were treated additionally with intrathecal chemotherapy. Two of them had positive cerebrospinal fluid (CSF)<sup>13,14</sup>, in 2 cases CSF details are not given<sup>15,16</sup>, and 3 had negative CSF (2 spinal manifestations and 1 cranial manifestation)<sup>11,17,18</sup>. The reason for intrathecal chemotherapy was not discussed in these cases. As my-

eloid sarcoma is a solid tumor, the administration of intrathecal chemotherapy is unclear in CSF negative cases.

Concerning prognosis of myeloid sarcoma (median overall survival, 6 months), it is worth noting that 7 non leukemic patients (e.g., myelodysplasia) had very short survival (median 2 months). In the literature, a poor prognosis was outlined in a series of non leukemic patients with myeloid sarcoma manifestations outside the CNS, which supports our finding<sup>2</sup>.

Translocation between chromosome 8 and 21 [t(8;21)] occurs in about 7% of patients with AML<sup>19</sup>. It was stated by other authors that t(8;21) might play a role in the development of myeloid sarcoma<sup>20</sup>. Our case was tested for translocation with negative result. In the review, 4 of 30 AML patients were known to have t(8;21).

Reviewing our case together with 44 CNS myeloid sarcoma reports published in the past decades showed similar outcome in patients with intracranial or spinal manifestations of myeloid sarcoma. Although different treatment methods including chemotherapy (systemic, intrathecal), irradiation and surgery were employed, systemic chemotherapy and irradiation might have a slight advantage with respect to survival. However, the data currently available do not allow for any evidence based recommendation to give. However, in AML patients with contrast enhancing intra- or extraparenchymatous CNS lesion, myeloid sarcoma should be suspected and surgery or biopsy is recommended, at least for histology or relief from neurologic symptoms. Concerning subsequent treatment for myeloid CNS sarcoma, we propose a treatment algorithm for patients in stable clinical

condition including initial steroid administration after histologic diagnosis depending on the neurologic deficit, followed by focal irradiation and systemic chemotherapy.

## References

- AUDOUIN J, COMPERAT E, Le TOURNEAU A, CAMILLERI-BROET S, ADIDA C, MOLINA T, *et al.* Myeloid sarcoma: clinical and morphologic criteria useful for diagnosis. *Int J Surg Pathol* 2003;11:271-2
- MEIS JM, BUTLER JJ, OSBORNE BM, MANNING JT. Granulocytic sarcoma in nonleukemic patients. *Cancer* 1986;58:2697-709.
- BEKASSY AN, HERMANS J, GORIN NC, GRATWOHL A. Granulocytic sarcoma after allogeneic bone marrow transplantation: a retrospective European multicenter survey. Acute and Chronic Leukemia Working Parties of the European Group for Blood and Marrow Transplantation. *Bone Marrow Transplant* 1996;17:801-8.
- IMRIE KR, KOVACS MJ, SELBY D, LIPTON J, PATTERSON BJ, PANTALONY D, *et al.* Isolated chloroma: the effect of early antileukemic therapy. *Ann Intern Med* 1995;123:351-3.
- NEIMAN RS, BARCOS M, BERARD C, BONNER H, MANN R, RYDELL RE, *et al.* Granulocytic sarcoma: a clinicopathologic study of 61 biopsied cases. *Cancer* 1981;48:1426-37.
- SUZER T, COLAKOGLU N, CIRAK B, KESKIN A, COSKUN E, TAHTA K. Intracerebellar granulocytic sarcoma complicating acute myelogenous leukemia: a case report and review of the literature. *J Clin Neurosci* 2004;11:914-7.
- RAPPAPORT H. Tumors of the hematopoietic system. 1966.
- KING A. Case of chloroma. *Monthly J Med* 1853;17:97-104.
- VARDIMAN JW, LEE HARRIS N, BRUNNING RD. The World Health Organization (WHO) classification of the myeloid neoplasms. *Blood* 2001;100:2292-302.
- GUERMAZI A, LAFITTE F, MIAUX Y, ADEM C, BONNEVILLE JF, CHIRAS J. The dural tail sign - beyond beyond meningioma. *Clin Radiol* 2005;60:171-88.
- YAMAMOTO K, HAMAGUCHI H, NAGATA K, HARA M, TONE O, TOMITA H, *et al.* Isolated recurrence of granulocytic sarcoma of the brain: successful treatment with surgical resection, intrathecal injection, irradiation and prophylactic systemic chemotherapy. *Jpn J Clin Oncol* 1999;29:214-8.
- BYRD JC, WEISS RB. Recurrent granulocytic sarcoma. An unusual variation of acute myelogenous leukemia associated with 8;21 chromosomal translocation and blast expression of the neural cell adhesion molecule. *Cancer* 1994;73:2107-12.
- LAGRANGE M, GASPARD MH, LAGRANGE JL, MICHIELS JF, HOFMAN P, THYSS A, *et al.* Granulocytic sarcoma with meningeal leukemia but no bone marrow involvement at presentation. A report of two cases with characteristic cerebrospinal fluid cytology. *Acta Cytol* 1992;36:319-24.
- SAPER CB, JAROWSKI CI. Leukemic infiltration of the cerebellum in acute myelomonocytic leukemia. *Neurology* 1982;32:77-80.
- MOSTAFAVI H, LENNARSON PJ, TRAYNELIS VC. Granulocytic sarcoma of the spine. *Neurosurgery* 2000;46:78-83.
- SUWA H, HANAKITA J, MIZUNO M, SHIBATA O, NAMURA S, OHTSUKA T, *et al.* Intraparenchymal granulocytic sarcoma in acute monocytic leukemia; case report (Japanese). *No Shinkei Geka* 1992;20:691-5.
- KRISHNAN K, ROSS CW, ADAMS PT, PEREIRA A, ROTH MS. Neural cell-adhesion molecule (CD 56)-positive, t(8;21) acute myeloid leukemia (AML, M-2) and granulocytic sarcoma. *Ann Hematol* 1994;69:321-3.
- WODZINSKI MA, COLLIN R, WINFIELD DA, DALTON A, LAWRENCE AC. Epidural granulocytic sarcoma in acute myeloid leukemia with 8;21 translocation. *Cancer* 1988;62:1299-300.
- BYRD JC, WEISS RB, ARTHUR DC, LAWRENCE D, BAER MR, DAVEY F, *et al.* Extramedullary leukemia adversely affects hematologic complete remission rate and overall survival in patients with t(8;21)(q22;q22): results from Cancer and Leukemia Group B 8461. *J Clin Oncol* 1997;15:466-75.
- BYRD JC, EDENFIELD WJ, SHIELDS DJ, DAWSON NA. Extramedullary myeloid cell tumors in acute nonlymphocytic leukemia: a clinical review. *J Clin Oncol* 1995;13:1800-16.

## Sažetak

## MIJELOIDNI SARKOM SREDIŠNJEGA ŽIVČANOG SUSTAVA: PRIKAZ SLUČAJA I PREGLED LITERATURE

*W. Struhal, S. Oberndorfer, H. Lahrman, E. Lindeck-Pozza, B. Hess, V. Nussgruber, R. Pöhl, Th. Dobner i W. Grisold*

Mijeloidni sarkomi su rijetke pojavnosti uglavnom mijeloblastične leukemije. Njihova pojava u središnjem živčanom sustavu je iznimna, pa je dotična literatura danas ograničena na studije pojedinih slučajeva. Mi opisujemo još jedan slučaj, dok je pregled literature poslužio kako bismo ispitali značajke i mogućnosti liječenja mijeloidnog sarkoma središnjega živčanog sustava. U žene stare 61 godinu s akutnom mijeloblastičnom leukemijom (FAB M5) i progresivnom lijevostranom hemiparezom utvrđena je desnostrano parieto-okcipitalno epiduralno oštećenje koje je sličilo meningiomu. Učinjena je djelomična resekcija koja je otkrila mijeloidni sarkom. Pregledom literature utvrdili smo 44 slučaja s dostatnim opisom dijagnoze, liječenja i praćenja do jedne godine. Kod tih bolesnika primijenjeni su različiti načini liječenja. Međutim, bolesnici su imali najbolji postotak jednogodišnjeg preživljenja kad je protokol liječenja uključivao sustavnu kemoterapiju ili zračenje.

Ključne riječi: *Leukemija mijeloidna – komplikacije; Meningealne novotvorine – dijagnostika; Središnji živčani sustav – patologija*