



# METHEMOGLOBINEMIA – A CASE REPORT AND LITERATURE REVIEW

Ida Ivek<sup>1</sup>, Tomislav Knotek<sup>1</sup>, Toni Ivičić<sup>1</sup>, Barbara Rubinić<sup>1</sup>, Paola Bajlo<sup>1</sup>, Jasmin Hamzić<sup>1</sup>

<sup>1</sup>Emergency Department, University Hospital Centre Zagreb, Zagreb, Croatia

**SUMMARY** – The objective of this case report is to present a patient with acquired methemoglobinemia due to poisoning of an unknown cause. A 55-year-old man was brought to the Emergency Department, University Hospital Center Zagreb, with an unwell appearance, cyanotic, restless, and presented with a quantitative consciousness disorder. An initial assessment showed decreased oxygen saturation (SpO<sub>2</sub> 85 [%]), while point-of-care arterial blood gas (ABG) analysis assessed normal partial pressure of oxygen (pO<sub>2</sub>). Severe lactic acidosis with a compensatory drop in partial pressure of carbon dioxide (pCO<sub>2</sub>) and high rates of methemoglobin were found. Supportive oxygen therapy and crystalloid solutions were administered, which resulted in rapid clinical recovery within 40 minutes of the initial assessment. Clinical recovery was accompanied by normalized ABG test results taken serially. Typical antidotes, methylene blue and vitamin C, were not administered due to rapid clinical improvement. Methemoglobinemia can be congenital (hereditary) or acquired (toxic). Both conditions are rarely seen in emergency departments, nevertheless, they should be approached properly since methemoglobinemia can be a severe, and fatal, condition. Methemoglobinemia symptoms are the results of inadequate oxygen transport. The diagnosis was confirmed by co-oximetry, while three clinical entities suspected methemoglobinemia: refractory hypoxia, “cyanosis-saturation gap” and dark brown blood. This paper reports our patient’s clinical presentation, discusses the causes and mechanisms of possible poisoning, and reviews recent guidelines for methemoglobinemia management.

*Key words: lactic acidosis, methemoglobinemia, poisoning*

## Introduction

Methaemoglobinaemia is not the first among differential diagnoses that crosses a clinician’s mind when assessing a cyanotic and hypoxemic patient. In this case report, we will present a patient with acquired methemoglobinemia, explain the pathophysiology of methemoglobinemia and the diagnostic process, together with specific and supportive treatment for such patients.

## Case report

A 55-year-old man was brought to the emergency department of the University Hospital Center Zagreb.

He was delirious, with an altered state of consciousness (Glasgow Coma Scale =11) and presented with pronounced grey skin and a disheveled appearance. According to the physician from the Emergency Medical Service (EMS), the patient was found in this condition at a tram station, and passers-by called an ambulance. While being transported, he lost consciousness at times, urinated, and had diarrhea on several occasions. During the initial assessment in the emergency room, it was not possible to obtain a medical history data from the patient due to his altered mental status. The patient maintained normal blood pressure (RR 134/88 mmHg) and heart rate (c/p 88/min) but was tachypneic, hypoxic (SpO<sub>2</sub> 90 [%]), and hypothermic (T 34.5 [°C]). The examination was difficult due to the patient’s extreme restlessness and uncooperativeness. Except for cold and pale-grey skin, no specific pathological signs were observed. Human fix-

Correspondence to: *Ida Ivek, MD*; Emergency Department, University Hospital Center Zagreb, Kišpatićeva 12, 10000 Zagreb, Croatia  
E-mail: idaivek@gmail.com

Table 1. Initial ABG on room air – results.

pH 7.04	pCO <sub>2</sub> 3.1 kPa	pO <sub>2</sub> 12.2 kPa	SaO <sub>2</sub> 85%	BE ecf -23 mmol/L	HCO <sub>3</sub> <sup>-</sup> 5.2 mmol/L
Na <sup>+</sup> 147mmol/L	K <sup>+</sup> 4.0 mmol/L	Lac >20 mmol/L			

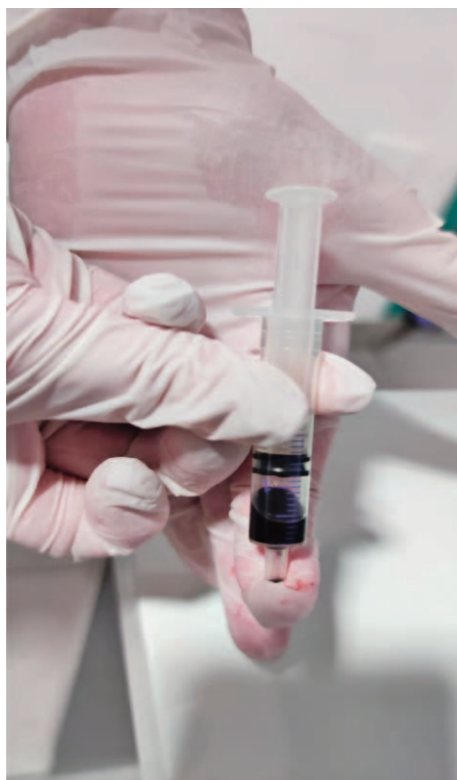

Figure 1. Dark brown blood color of a patient with methaemoglobinaemia.

Copyright © 2022 The Authors

tion, intramuscular haloperidol injection (1 ampoule in total), and IV diazepam infusion (1 ampoule in 500mL saline) were administered, and a urinary catheter was inserted. Upon obtaining an arterial blood specimen, a dark brown blood color was noticed (Figure 1). An arterial blood gas (ABG) analysis at room air (see Table 1) showed marked acidemia (pH 7.04), normal partial pressure of oxygen (pO<sub>2</sub> 12.2 [kPa]), reduced oxygen saturation (SpO<sub>2</sub> 85 [%]), reduced partial pressure of carbon dioxide (pCO<sub>2</sub> 3.1 [kPa]) and bicarbonate ion (HCO<sub>3</sub><sup>-</sup> 5.2 [mmol/L]), excess bases (BE ecf -23.0 [mmol/L]) and markedly elevated lactates (Lac > 20 [mmol/L]). Oxygen was delivered via an oxygen mask with a flow of 15 L/min. In addition, 75 mL of bicarbonate ion in 500 mL of 5% glucose solution and 1000 mL of heated crystalloid solution

(PlasmaLyte) were administered. Reassessment of vital signs indicated hypotension (RR 88/61 mmHg), tachycardia (c/p 115/min) and reduced oxygen saturation (SpO<sub>2</sub> 90 [%]), despite the maximal oxygen flows via a non-rebreather mask. The ECG showed atrial fibrillation, 150 beats/min, normal electrical axis and diffuse ST-segment displacement. Mild macrocytic anemia and leukocytosis (Lkc=17.6 [x10<sup>9</sup>/L]), hypokalemia (K=3.0 [mmol/L]), mildly elevated creatine kinase (CK=225 [U/L]) and the presence of ethanol in the blood (ALC=0.6 [g/L]) were found, while other parameters were within the limit of physiological intervals, including cardioselective enzymes. A toxicology screen determined only the presence of nicotine and lidocaine (due to urinary catheter placement), but not all psychoactive substances were included in the analysis. The ABG test was repeated (Table 2) 40 minutes after the initial monitoring. Severe acidosis with increased anion gap (pH 7.14) was still present, now with elevated partial oxygen pressure (pO<sub>2</sub> 36.6 [kPa]), normal oxygen saturation (SpO<sub>2</sub> 99.8 [%]) and normal partial pressure of carbon dioxide (pCO<sub>2</sub> 4.1 [kPa]). Lactate values were still increased (Lac 16.7 [mmol/L]), as well as excess bases (BE ecf -18.4 [mmol/L]) and bicarbonate ion (HCO<sub>3</sub><sup>-</sup> 9.8 [mmol/L]), but with a normalization tendency compared to the initial values. An elevated percentage of methemoglobin (MetHb 36.4 [%]) was observed. During the observation of our patient in the emergency unit, pH and lactate values normalized (pH 7.42, Lac 1.3 [mmol/L]), and his mental status improved. In an interview with the patient, we found out that he drank 0.5L of water from a hydrant at the main station, after which he fell ill. We cannot claim with certainty that water from a hydrant was the definite cause of poisoning. We later discovered that he was homeless with no regular income and did not suffer from chronic diseases and did not take chronic drug therapy. The patient was admitted to the post-intensive care unit at the Department of Internal Medicine, University Hospital Center Zagreb. Serial monitoring of the patient's acid-base status was continued. A decrease in the percentage of methemoglobin, normal-

Table 2. ABG test results on a non-rebreather mask with a 15L/min flow.

pH 7.14	pCO <sub>2</sub> 4.1 kPa	pO <sub>2</sub> 36.6 kPa	SaO <sub>2</sub> 99.8%	BE ecf -18.4 mmol/L	HCO <sub>3</sub> <sup>-</sup> 9.8 mmol/L
Na <sup>+</sup> 145 mmol/L	K <sup>+</sup> 3.6 mmol/L	Lac 16.7 mmol/L	MetHb 36.4%		

ization of vital signs and adequate response to the given therapy were recorded. The paroxysm of atrial fibrillation spontaneously converted to a sinus rhythm that was later maintained permanently. During hospitalization, the patient was briefly sub febrile on several occasions. The patient had no signs of infection, no increase in inflammatory parameters was observed, so there was no indication for antibiotic therapy. Due to the favorable clinical course with the use of oxygen therapy and intravenous replacement of crystalloid solutions, there was no need to use antidotes - methylene blue and vitamin C. The social service was contacted. The patient recovered fully and was discharged from the hospital five days after admission.

## Discussion

Methaemoglobinaemia is a rare disorder characterized by the oxidation of divalent iron to the trivalent form (from ferrous to ferric form) in the hemoglobin molecule. Oxygen can bind to hemoglobin only in divalent (ferrous) form, and as a result of binding, oxygen is temporarily oxidized to ferric form. Various substances, which will be listed later, can cause hemoglobin to remain permanently in a ferric form and thus no longer be able to bind oxygen. Therefore, the symptoms of methemoglobinemia are a direct consequence of inadequate oxygen transport. The specific mechanism is an allosteric change in the hemoglobin molecule. In addition, due to further changes in the oxygen-hemoglobin dissociation curve (a change in oxygen dissociation to the left), there is reduced peripheral oxygen release<sup>1</sup>, hypoxia, and functional anemia<sup>2</sup> with no decrease in hemoglobin level. Methaemoglobinaemia can occur as a result of a congenital defect or as an acquired disorder. Acquired disorders are more common and occur as a result of exposure to substances that directly or indirectly oxidize hemoglobin. Congenital causes of methemoglobinemia arise from an autosomal recessive variant of the CYB5R3 gene or an autosomal dominant variation of genes encoding a globin molecule known as HbM disease. Hereditary methemoglobinemia, as a consequence of mutations in

Table 3. Drugs and substances that can result in the development of methemoglobinemia

Drug group	Representatives (common causes are bold)
Local anesthetics	<b>Benzocaine</b> (often used in endoscopic procedures) Prilocaine, tetracaine, lidocaine
Nitrates	<b>Nitroglycerin</b> <b>Inhaled nitric oxide</b> Nitroprusside, oral nitrates, amyl-nitrate
Antibiotics	<b>Dapsone</b> Rifampicin, sulfonamides, antimalarials
Other drugs	<b>Rasburicase</b> (especially in G6PD deficiency) Oncological drugs: cyclophosphamide Metoclopramide Various drugs in which some oxidizing substance is used in the making
Environmental causes	Fertilizers, herbicides Plastic (various types) Paints and rubber

the CYB5R3 gene, leads to NADH-cytochrome-reductase deficiency, with up to 80 different variants of this disorder known today.<sup>3,4</sup> Autosomal dominant disease involving various genes encoding alpha-globin, beta-globin, and gamma-globin leads to the formation of M-hemoglobin, in which structural abnormalities of globin lead to auto-oxidation of iron, and thus to the occurrence of methemoglobinemia. Patients suffering from this disease are cyanotic but usually asymptomatic<sup>5</sup>. Acquired methemoglobinemia results from drug intake or exposure to toxins lead to accelerated oxidation of hemoglobin from ferrous to ferric form.<sup>6</sup> Table 3 lists the most common drugs that can lead to the development of methemoglobinemia.

The clinical presentation of methemoglobinemia is various and depends on the percentage of methemoglobin, a patient's usual hemoglobin level, and cardio-




Figure 2. Brown blood color shade scale for a rough assessment of methaemoglobinaemia.

Source: Shihana F, Dissanayake D, Buckley N, Dawson A. A Simple Quantitative Bedside Test to Determine Methemoglobin. *Annals of emergency medicine*. 2009. 55. 184-9. 10.1016/j.annemerg-med.2009.07.022.

Available from: [https://www.researchgate.net/figure/Color-chart-for-the-measurement-of-methemoglobin-The-color-chart-was-prepared-according\\_fig2\\_26884296](https://www.researchgate.net/figure/Color-chart-for-the-measurement-of-methemoglobin-The-color-chart-was-prepared-according_fig2_26884296) [accessed 26 Feb, 2022]

Copyright © 2009 The Authors

Available under: Creative Commons Attribution 4.0 International

vascular reserve. The normal percentage of methemoglobin is below 25%. Patients with levels between 3 and 15% are usually asymptomatic, and cyanosis is rare. Patients with methemoglobin levels between 20-30% are always symptomatic, with mild symptoms such as fatigue, tachypnea, dyspnea, tachycardia, anxiety, dizziness, qualitative disturbance of consciousness, nausea, and vomiting. At levels above 40%, life-threatening and serious symptoms occur, such as epileptic seizures, coma, arrhythmias, elevated lactate levels, and death. The final diagnosis is made using co-oximetry, but clinical suspicion itself can be made based on the following three entities:<sup>7</sup>

- Refractory hypoxia: methemoglobinemia can typically be suspected in a patient with oxygen saturation between 82-86%, who is at high oxygen flows (FiO<sub>2</sub> 100%), and no other explanation for hypoxia
- “Cyanosis-saturation gap”: methemoglobinemia leads to the development of central cyanosis (attention to the color of the tongue). Oxygen saturation of 80-90% usually does not lead to cyanosis, so patients with 80-90% saturation who present with central cyanosis are clinically suspicious of methemoglobinemia
- Brown blood color: methemoglobinemia causes a change of blood color to chocolate-like. Also, if we put a patient’s blood on white gauze, the blood will remain brown when dry, unlike deoxygenated blood, which will absorb oxygen in the air and turn red again

As noted, the diagnosis of methemoglobinemia was made based on co-oximetry. Unlike standard pulse

oximeters that measure light absorption at two wavelengths, co-oximetry measures light absorption at four wavelengths: 600nm (carboxyhemoglobin), 631nm (methemoglobin), 660nm (deoxyhemoglobin), and 940 nm. Based on this analysis, multiple disorders can be diagnosed - both carboxyhaemoglobinaemia and methemoglobinemia.<sup>8</sup> In addition to this formal test, simple tests can be used for rough assessment, which, based on the color of the blood on a white paper, provide an estimate of the level of methemoglobinemia.<sup>9</sup> Figure 2 shows the blood color shades scale of brown, which could be helpful in everyday clinical work.<sup>9</sup> Finally, calculation of the so-called “saturation gap” (the difference between the measured saturation and that measured with a pulse oximeter), could also be useful. A difference of more than 5% may raise a suspicion of methemoglobinemia.

Treatment of methemoglobinemia is primarily based on supportive care and discontinuation of the drug or substance use that leads to this condition. Definitive treatment involves the reduction of methemoglobin to a non-oxidized state using methylene blue, which is the drug of choice for the treatment of methemoglobinemia. Methylene blue, along with nicotinamide-adenine dinucleotide phosphate (NADPH), is a co-factor of the enzyme NADPH-methemoglobin reductase. It works by accepting an electron from NADPH and in this form reduces trivalent iron from ferric form to ferrous form.<sup>10</sup> The use of methylene blue is indicated in symptomatic methemoglobinemia regardless of methemoglobin level, and in cases where the methemoglobin level is above 30%. The drug is contraindicated in patients with glucose-6-phosphate dehydrogenase (G6PD) deficiency, and caution is required in patients at risk of developing serotonin syndrome. Methylene blue is a monoamine oxidase (MAO) inhibitor and can lead to the development of serotonin syndrome in interaction with other drugs. The drug dose is 1-2 mg/kg IV over five minutes, while the clinical effect is visible within a few minutes. Cyanosis resolves within one hour after application. When applying the drug, there may be a “drop” in oxygen saturation, because methylene blue turns the blood blue, and it falsely reduces the saturation value measured via pulse oximetry. The drug can be administered again after 60 minutes if the patient is still cyanotic, although a dose failure of 2 mg/kg raises suspicion of G6PD deficiency. Rebound-methaemoglobinaemia

may recur within 12 hours after drug administration, after which continuous infusion of methylene blue may be considered.<sup>11</sup> In patients with G6PD deficiency, treatment is more complex. It is important to note that this deficit occurs in African Americans but also presents in people from the Mediterranean region.<sup>12</sup> These patients lack NADPH, due to G6PD deficiency, and therefore methylene blue either has no effect at all, or has some effect, but the further application of already low NADPH levels will lead to lower glutathione levels, leading to hemolysis. In these patients, treatment with high doses of vitamin C (1.5-3g IV every six hours) may be attempted. In addition, riboflavin (vitamin B2), which acts as an electron acceptor, can be added to the therapy. The use of methylene blue may also be considered, but with caution. If all of the treatment modalities listed fail, complete erythrocyte transfusion and hyperbaric chamber transplantation may be considered. Methylene blue can be redosed if needed. Caution should be exercised when the drug level comes close to 7ml/kg as there is a risk of drug toxicity.<sup>13</sup> At toxic or subtoxic doses, methylene blue may worsen methemoglobinemia and hemolysis, which occurs because of the bioaccumulation of methylene blue, leading to a reversal of the reductive action. Side effects of methylene blue are as follows: systemic and/or pulmonary hypertension (via a reaction that prevents nitric oxide-mediated vasodilation), motor restlessness, dyspnea, nausea, vomiting, sweating, and anaphylaxis.

## Conclusion

Methaemoglobinaemia is a rare disorder characterized by elevated levels of methemoglobin, a hemoglobin molecule that contains an oxidized form of iron that cannot bind oxygen and results in an inadequate oxygen supply to tissues. There are two forms of the disease - genetic and acquired methemoglobinemia. Genetic methemoglobinemia is a chronic disease that leads to numerous morbidities, and patients are mostly characterized by cyanosis without associated other symptoms. Acquired methemoglobinemia, on the other hand, is an acute condition that is most often the result of poisoning by certain drugs and compounds, which can be fatal. The severity of symptoms depends on the percentage of methemoglobin in the blood, and clinical presentation varies from fatigue, anxiety, dizzi-

ness, and cyanosis, to qualitative disorders of consciousness, epileptic seizures, arrhythmia, and coma. Unexplained symptoms of refractory hypoxia, cyanosis-saturation gap, and chocolate-colored blood may raise suspicion of methemoglobinemia, but the definitive diagnosis is made using co-oximetry and detecting methemoglobin levels in the blood. Treatment of methemoglobinemia is based on supportive care and discontinuation of the drug or substance that led to this condition. Despite being a rare condition, acquired methemoglobinemia can be a life-threatening condition and emergency services should be provided with antidotes - methylene blue and vitamin C.

## Informed consent

Informed consent for publication of this paper was given by the patient verbally.

## References

1. Wright RO, Lewander WJ, Woolf AD. Methemoglobinemia: etiology, pharmacology, and clinical management. *Ann Emerg Med.* 1999 Nov;34(5):646-56. doi: 10.1016/s0196-0644(99)70167-8. PMID: 10533013.
2. Ludlow JT, Wilkerson RG, Nappe TM. Methaemoglobinaemia. In: StatPearls. StatPearls Publishing, Treasure Island (FL); 2021. PMID: 30726002.
3. Percy M, Lappin T. Recessive congenital methaemoglobinaemia: cytochrome b5 reductase deficiency. *Br J Haematol.* 2008;0(0):080305033838221-???. doi:10.1111/j.1365-2141.2008.07017.x
4. van Zwieten R, Verhoeven A, Roos D. Inborn defects in the antioxidant systems of human red blood cells. *Free Radical Biology and Medicine.* 2014;67:377-386. doi:10.1016/j.freeradbiomed.2013.11.022
5. Kulozik AE. Haemoglobin variants and the rarer haemoglobin disorders. *Pediatric Hematology; Wiley;* 2006: 231- 254
6. Iolascon A, Bianchi P, Andolfo I, Russo R, Barcellini W, Fermo E., et al. Recommendations for diagnosis and treatment of methemoglobinemia. *Am J Hematol.* 2021;96(12):1666-1678. doi:10.1002/ajh.26340.
7. EMCrit A, Farkas J. Methaemoglobinaemia [Internet]. EMCrit Project. 2022 [cited 21 February 2022]. Available from: <https://emcrit.org/ibcc/Methaemoglobinaemia/>
8. Cortazzo J, Lichtman A. Methemoglobinemia: A Review and Recommendations for Management. *J Cardiothorac Vasc Anesth.* 2014;28(4):1043-1047. doi:10.1053/j.jvca.2013.02.005
9. Shihana F, Dissanayake D, Buckley N, Dawson A. A Simple Quantitative Bedside Test to Determine Methemoglobin. *Ann Emerg Med.* 2010;55(2):184-189. doi:10.1016/j.annemergmed.2009.07.022

10. Anderson ST, Hajduczek J, Barker SJ. Benzocaine-induced methemoglobinemia in an adult: accuracy of pulse oximetry with methemoglobinemia. *Anesth Analg.* 1988 Nov;67(11):1099-101. PMID: 3189900.
11. Severe Methaemoglobinaemia and Hemolytic Anemia from Aniline Purchased as 2C-E (4-ethyl-2,5-dimethoxyphenethylamine), a Recreational Drug, on the Internet — Oregon, 2011 [Internet]. Cdc.gov. 2022 [cited 21 February 2022]. Available from: [https://www.cdc.gov/mmwr/preview/mmwrhtml/mm6105a1.htm?s\\_cid=mm6105a1\\_w](https://www.cdc.gov/mmwr/preview/mmwrhtml/mm6105a1.htm?s_cid=mm6105a1_w)
12. Rehman A, Shehadeh M, Khirfan D, Jones A. Severe acute haemolytic anaemia associated with severe methaemoglobinaemia in a G6PD-deficient man. *BMJ Case Rep.* 2018:bcr-2017-223369. doi:10.1136/bcr-2017-22336
13. Groeper K, Katcher K, Tobias JD. Anesthetic management of a patient with methemoglobinemia. *South Med J.* 2003 May;96(5):504-9. doi: 10.1097/01.smj.0000051342.99317.99. PMID: 12911193.

### Sažetak

## METHEMOGLOBINEMIJA – PRIKAZ SLUČAJ I PREGLED LITERATURE

*Ida Ivek, Tomislav Knotek, Toni Ivičić, Barbara Rubinić, Paola Bajlo i Jasmin Hamzić*

Svrha ovog rada je prikaz slučaja pacijenta sa stečenom methemoglobinemijom uslijed trovanja nepoznatog uzroka. 55-godišnji muškarac zapuštenog izgleda dovežen je u Objedinjeni hitni bolnički prijem (OHBP) Kliničkog bolničkog centra (KBC) Zagreb cijanotičan, nemiran i kvalitativno promijenjenog stanja svijesti. U inicijalnoj obradi nađena je snižena saturacija kisikom (SaO<sub>2</sub> 85[%]), dok je plinska analiza arterijske krvi ukazivala na zadovoljavajuće vrijednosti parcijalnog tlaka kisika. Nađena je teška laktacidoza s kompenzatorno sniženim parcijalnim tlakom ugljikovog dioksida, a zamijećen je i visok postotak methemoglobina. Na primijenjenu suportivnu oksigenoterapiju te terapiju kristaloidnim otopinama, pacijentovo se kliničko stanje rapidno oporavlja unutar četrdesetak minuta, što se prati i normalizacijom serijski evaluiranog acidobaznog statusa. S obzirom na povoljan klinički tijek, nije bilo potrebe za primjenom antidota – metilenskog modrila i vitamina C. Postoje urođena (genetska) i stečena (toksična) methemoglobinemija. Oba stanja se rijetko viđaju na hitnom prijemu, a stečena methemoglobinemija može biti životno ugrožavajuće stanje. Simptomi methemoglobinemije izravna su posljedica neadekvatnog transporta kisika. Dijagnoza se postavlja na temelju ko-oksimetrije, ali sama klinička sumnja može se postaviti na temelju sljedeća tri entiteta: refraktorne hipoksije, „cyanosis-saturation gap“ i smeđe boje krvi. U ovom radu osvrnut ćemo se na klinički tijek našeg pacijenta, dotaći se potencijalnih mehanizama trovanja i uzroka toksične methemoglobinemije te prikazati recentne preporuke za zbrinjavanje ovakvih slučajeva.

Ključne riječi: *laktacidoza, methemoglobinemija, trovanje*