



Mirna Radović¹, Lidia Gavić², Daniel Jerković³, Davor Željezić⁴, Jasna Puizina⁵, Ivan Srzentić⁶, Ema Puizina Mladinić³, Antonija Tadin²

Clinical Prospective Assessment of Genotoxic Effects of Dental Implants in Gingival Epithelial Cells

Procjena genotoksičnosti i citotoksičnosti dentalnih implantata na gingivnim epitelnim stanicama

¹ Private dental practice, Solin, Croatia

Privatna dentalna ordinacija, Solin, Hrvatska

² Department of Restorative Dental Medicine and Endodontics, Study of Dental Medicine, School of Medicine, University of Split, Split, Croatia

Katedra za restaurativnu dentalnu medicinu i endodonciju Studija dentalne medicine Medicinskog fakulteta Sveučilišta u Splitu, Hrvatska

³ Department of Maxillofacial Surgery, Clinical Hospital Centre Split, Split, Croatia

Odjel za maksilofacijalnu kirurgiju Kliničkoga bolničkoga centra Split, Hrvatska

⁴ Mutagenesis Unit, Institute for Medical Research and Occupational Health, Zagreb, Croatia

Jedinica za mutagenezu Instituta za medicinska istraživanja i medicinu rada, Zagreb, Hrvatska

⁵ Department of Biology, Faculty of Science, University of Split, Split, Croatia

Odjel za biologiju Prirodoslovno-matematičkoga fakulteta Sveučilišta u Splitu, Hrvatska

⁶ Private dental practice, Zadar, Croatia

Privatna dentalna ordinacija, Zadar, Hrvatska

Abstract

Objectives: Although titanium-based implants are considered bioinert, it has been found that they are subject to corrosion and wear. This study aimed to evaluate the cytotoxic and genotoxic potential of two implant systems in gingival epithelial cells. **Material and methods:** Gingival swabs were taken three times from 91 subjects. The first swab was taken before dental implant placement, the second swab 90 days after dental implant placement and the third swab 21 days following the healing abutment placement. DNA damage was analyzed using the micronucleus test. Tested dental implants with corresponding healing abutments were Ankylos and Dentium SuperLine. **Results:** Of all scored forms of cytogenetic damage in gingival cells of individuals after implementation of tested dental implant systems, only an increase in the number of binucleated cells ($P \leq 0.001$) was significant in contrast to control values for both tested implant systems, 90 days after dental implant placement and 21 days following the healing abutment placement. **Conclusion:** It may be concluded that there are no titanium-based implant dependent cytogenetic damage in gingival epithelial cells. A slight increase in cytogenetic damage has been observed but it is of no biological relevance and might be associated with healing abutment induced effect.

Received: March 24, 2022

Accepted: July 20, 2022

Address for correspondence

Antonija Tadin, DDS, MSc, PhD,
Assistant Professor
University of Split, School of Medicine
Study of Dental Medicine
Department of Restorative Dental
Medicine and Endodontics
Soltanska 2, 21000 Split, Croatia
Phone: +38598609191,
E-mail: atadin@mefst.hr

MeSH Terms: Dental Implants;
Titanium; Corrosion; Micronucleus
Tests; Gingiva; Epithelial Cells
Author Keywords: Biocompatibility;
Micronucleus Assay

Mirna Radović, ORCID ID: 0000-0001-6776-7546

Lidia Gavić, ORCID ID: 0000-0003-2882-934X

Daniel Jerković, ORCID ID: 0000-0002-6431-1815

Davor Željezić, ORCID ID: 0000-0002-8214-0212

Jasna Puizina, ORCID ID: 0000-0001-7097-7261

Ivan Srzentić, ORCID ID: 0000-0002-0864-8317

Ema Puizina Mladinić, ORCID ID: 0000-0001-5596-9415

Antonija Tadin, ORCID ID: 0000-0002-5365-9816

Introduction

The use of dental implants has increased in recent years and this trend is expected as the consequence of the ageing of the world's population and dental therapies improvement. Titanium and titanium alloys are the most frequently used materials for manufacturing dental implants today due to their desirable physical and mechanical properties and favorable biocompatibility. The biocompatibility of titanium as an implant material is associated with protective and stable layer of oxides that spontaneously build on the surface of the

Uvod

Korištenje dentalnih implantata u terapiji bezubosti u stalnom je porastu što je posljedica općeg starenja populacije i napretka dentalne tehnologije i terapije. Većina današnjih implantata proizvodi se od titanija i njegovih legura zbog poželjnih fizičkih i mehaničkih svojstava te dobre biokompatibilnosti. Biokompatibilnost titanija, kao materijala za proizvodnju implantata, povezana je sa zaštitnim i stabilnim slojem titanijeva dioksida koji se spontano stvara na površini implantata na zraku i/ili u fiziološkim tekućinama. Taj sloj

implant in air and/or physiological fluids. This layer is a potent barrier against the dissolution of the metal. Owing to this barrier, titanium exhibits excellent resistance to corrosion (1-3).

Titanium Grades 1, 2, 3 and 4 are titanium materials that are commercially referred as pure titanium. They usually contain some carbon, oxygen, nitrogen and iron. These elements enhance the mechanical properties of pure titanium considerably and are found in varying amounts ranging from Grade I to Grade IV. Thus, mechanical characteristics such as implant strength, creep resistance and formability can be improved by combining titanium with specific elements (e.g. aluminum, Al; vanadium, V; tantalum, Ta; zirconium, Zr). The two alloys that are most frequently used are Ti-6Al-4V and Ti-6Al-4V-ELI (extra low interstitial alloys) (4).

Surrounding tissue reactions to an implant are mainly related to the effects of the load and its stability. However, the surface attributions of the substrate, e.g. composition, roughness, wettability and morphology are also crucial factors that play a role in affecting the state of homeostasis in cells surrounding the implant (5, 6). Surface-roughness has impact on the osseointegration of titanium dental implants and different processes correlated to providing a roughened surface may lead to the release of cytotoxic aluminum ions into the peri-implant tissue. Some studies on metal particle release from dental implants have confirmed an association between the inflammatory response in peri-implant tissues and particles derived from dental implants in the same surrounding (7,8). There are several ways of discharging these particles from dental implants. They are released during implant placement, due to the wear of implant surface, due to polishing and finishing of the implant surface or the corrosive effect of therapeutic substances. Cyclic micro-movements appear at the contact surfaces of the implant components, especially at the level of implant-abutment connection. That can result in tribocorrosion, process of degradation by corrosion and wear processes on titanium surfaces, often leading to a significant increase in material loss. Mechanical wear can destroy the passive protective layer of titanium oxide that is formed on its surface. In consequence, metal becomes more prone to corrosion. Subsequently, it becomes more vulnerable to mechanical wear. Mechanical wear also facilitates corrosion (9-12). Immune system may recognize micro- and nano-particles released from an alloy as a result of degradation of the dental implant system as foreign bodies. By stimulating the activation of several mediators, including cytokines, an inflammatory response in the peri-implant tissues may be provoked (12, 13).

Dental materials could release small amount of their components into the oral cavity. Therefore, proper regulations have to ensure that the risk from genotoxicity/mutagenicity of dental materials is at the lowest possible level. Detailed biocompatibility records are needed to assess the comprehensive risks of the above-mentioned released compounds (14-16). As stated above, the aim of this *in vivo* study was to evaluate biocompatibility, in terms of cytogenetic damage of implants and healing abutments from two different implant systems in gingival epithelial cells. At the beginning of the

spriječava degradaciju metala i zbog toga titanij posjeduje odličnu otpornost na koroziju (1-3).

Komercijalno čisti titanijevi materijali nazivaju se čistim titanijem I., II., III. i IV. razreda, a mogu sadržavati i neke elemente u tragovima kao što su ugljik, kisik, dušik i željezo koji znatno poboljšavaju njegova mehanička svojstva. Njihov udio raste od I. do IV. razreda. Mehanička svojstva kao što su čvrstoća implantata, dinamička čvrstoća te mogućnost oblikovanja mogu se poboljšati dodavanjem određenih elemenata (aluminij – Al; vanadij – V; tantal – Ta; cirkonij – Zr) čistom titaniju, odnosno legiranjem titanija. Dvije legure titanija su Ti-6Al-4V i Ti-6Al-4V-ELI (ekstra niske međuprostorne legure) (4).

Reakcija okolnoga tkiva na implantat dominantno ovisi o učincima kao što su opterećenje i stabilnost implantata. I svojstva površine implantata kao što su sastav, hrapavost, vlažnost i morfologija površine ključni su čimbenici u postizanju homeostaze stanica okolnoga tkiva (5, 6). Hrapavost površine implantata djeluje na proces oseintegracije, a različiti postupci koji se primjenjuju za hrapavljenje površine mogu potaknuti otpuštanje citotoksičnih aluminijevih iona u periimplantatna tkiva. U prijašnjim istraživanjima autori su dokazali povezanost upalnoga odgovora stanica periimplantatnoga tkiva s prisutnošću čestica otpuštenih s implantata u okolno tkivo (7, 8). Nekoliko je načina da se čestice materijala implantata otpuste u okolno tkivo. To može biti uglavnom tijekom procesa ugradnje, zatim zbog trošenja same površine implantata, zbog poliranja površine ili korozivnog učinka terapijskih tvari. Na dodirnoj površini komponenti implantata događaju se ciklični mikropokreti, osobito na spoju implantata i nadogradnje (abutmenta). Oni mogu rezultirati tribokorozijom, tj. procesom degradacije titanijeve površine zbog korozije i trošenja, što često uzrokuje znatan gubitak materijala. Mehaničko trošenje može uništiti pasivni sloj titanijeva dioksida s površine pa metal postaje skloniji koroziji, a time i mehaničkom trošenju. Mehaničko trošenje zatim dodatno pospešuje koroziju (9 – 12). Imunosni sustav prepoznaje mikro i nanočestice oslobođene s površine titanijeve legure kao strano tijelo te aktivacijom nekoliko medijatora upale, uključujući citokine, pokreće upalni odgovor periimplantatnoga tkiva (12, 13).

Dentalni materijali mogu otpustiti manju količinu svojih komponenti u oralnu šupljinu. Zato se ispravnom regulacijom mora osigurati minimalna razina genotoksičnosti/mutagenosti materijala za tkivo. Za procjenu rizika od spomenutih potencijalno toksičnih komponenti potrebni su detaljni podatci o biokompatibilnosti (14 – 16). Uzimajući u obzir spomenute podatke, cilj ove studije *in vivo* jest evaluirati biokompatibilnost u smislu citogenetskoga oštećenja koje mogu prouzročiti implantati i gingivni formeri od dvaju različitih implantoloških sustava na epitelnim stanicama gingive. Na početku istraživanja nulta hipoteza bila je da dentalni implantati na bazi titanija i gingivni formeri od dvaju različitih implantoloških sustava neće na epitelnim stanicama gingive prouzročiti nikakav genotoksični i citotoksični učinak.

study, the following null hypothesis was established: titanium-based dental implants and healing abutments from two different implant systems would not have any genotoxic and cytotoxic effects on gingival epithelial cells.

Material and methods

Study Design

This prospective, randomized clinical trial with two parallel study groups was conducted between January 2020 and April 2021 in private dental practices in collaboration with the Department of Restorative Dental Medicine and Endodontics, Study of Dental Medicine, University of Split, Croatia. It was approved by the University Ethics Committee (No: 2181-198-03-04-20-0041) which also confirmed that the study was in full accordance with ethical principles including the World Medical Association Declaration of Helsinki (version 2013), and met all additional requirements. The study was also registered at clinical trials (ClinicalTrials.gov, Study ID number: NTC04540991). The participation was voluntary, anonymous, without any financial support, and all participants were introduced to the background and the aim of the study. All participants gave their informed consent in writing before inclusion in the investigation.

Participants

This study comprised a total of 91 patients of mean age 53.8 ± 9.9 . Participants' demographic data are presented in Table 1. The main inclusion criterion was the absence of tooth/teeth in the mandibular molar or premolar region where the tested implants were placed. Additional characteristics of the participants were: belonging to ASA I or ASA II group (according to the American Society of Anesthesiologists), the absence of titanium and penicillium hypersensitivity, the absence of prosthetic restoration/replacement or ortho-

Materijal i metode

Ustroj istraživanja

Ova prospektivna, randomizirana klinička studija s dvjema paralelnim ispitivanjem skupinama provedena je između siječnja 2020. godine i travnja 2021. godine u privatnim ordinacijama dentalne medicine te u suradnji s Katedrom za restaurativnu dentalnu medicinu i endodonciju studija Dentalne medicine Medicinskog fakulteta Sveučilišta u Splitu. Istraživanje, koje je u skladu s etičkim vrijednostima i Helsinškom deklaracijom Svjetskoga medicinskoga udruženja (verzija 2013.), odobrilo je Etičko povjerenstvo Medicinskoga fakulteta u Splitu (No: 2181-198-03-04-20-0041). Sudjelovanje u istraživanju bilo je dobrovoljno, anonimno i bez naknade, a svi sudionici bili su obaviješteni o njegovoj svrsi te su potpisali informirani pristanak.

Ispitanici

Istraživanje je provedeno na 91 ispitaniku srednje dobi – $53,8 \pm 9,9$ godina. Njihovi demografski podatci nalaze se u tablici 1.

Glavni kriterij uključenja ispitanika u studiju bio je nedostatak jednoga zuba u donjoj čeljusti u molarnoj ili premolarnoj regiji. Osim potrebe za implantološkom terapijom, dodatni kriteriji bili su dobrovoljni pristanak za sudjelovanje u istraživanju, punoljetnost, pripadanje pacijenata u skupinu ASA I ili ASA II (prema Američkome anesteziološkome druš-

Table 1 Prevalence of sociodemographic characteristics among participants
Tablica 1. Prevalencija sociodemografskih karakteristika među ispitanicima

Characteristics		Dentium SuperLine	Ankylos
Gender	Male	16 (35.6)	19 (41.3)
	Female	29 (64.4)	27 (58.7)
Age, years		52.0 ± 10.1	54.1 ± 9.5
Smoking (≤ 10 cigarettes per day)	Non smoker	22 (48.9)	27 (58.7)
	Smoker	23 (51.1)	19 (41.3)
Alcohol intake	Never	6 (13.3)	6 (13.1)
	≤ 12 units/ week	16 (35.6)	19 (41.3)
	13-24 units/week	9 (20.0)	10 (21.7)
	≥ 25 units/week	14 (31.1)	11 (23.9)
Meat consumption	≤ 1 /week	8 (15.5)	9 (19.6)
	1-3/week	15 (33.3)	14 (30.4)
	4-6/week	15 (33.3)	14 (30.4)
	≥ 1 /day	8 (17.7)	9 (19.6)
Fruit consumption	4-6/week	18 (40.0)	17 (37.0)
	≥ 1 /day	27 (60.0)	29 (63.0)
Vegetable's consumption	1-3/week	18 (40.0)	21 (45.6)
	4-6/week	9 (20.0)	7 (15.2)
	≥ 1 /day	18 (40.0)	18 (39.1)

Data are presented as whole numbers and percentages or mean (SD). • xxx

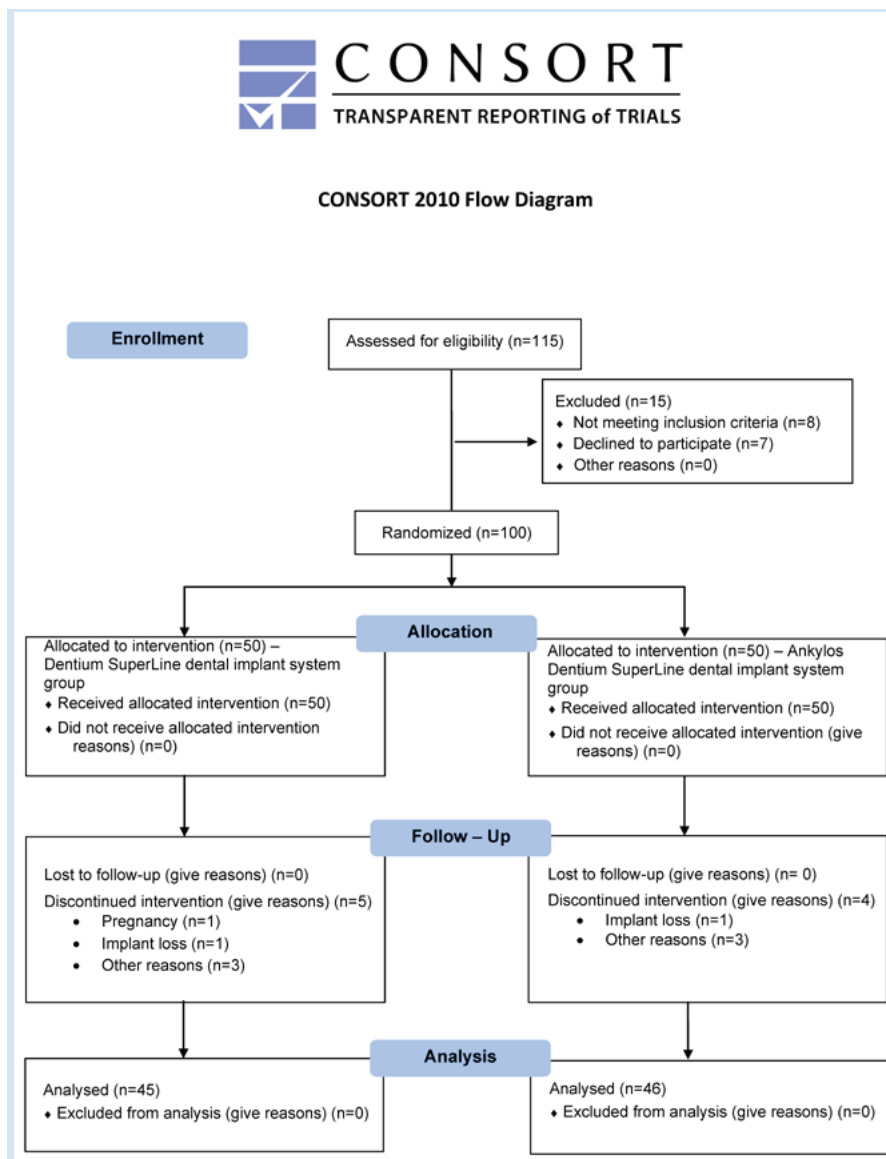


Figure 1 Flowchart of participant's recruitment and follow-up.

Slika 1. Dijagram uključivanja sudionika i praćenja

odontic appliances in the oral cavity/dental amalgam fillings, the absence of oral precancerous lesions and the absence of bisphosphonates and corticosteroids used in therapy. Exclusion criteria were the presence of systemic disease (e.g. uncontrolled diabetes, oral mucosal diseases, untreated gingivitis and periodontitis, endodontic lesions), pocket depths ≥ 4 mm on adjacent teeth, bruxism, poor oral hygiene, pregnant and lactating women, antibiotic therapy in the last three months, taking any other pharmaceuticals that have been proved to accelerate DNA damage, using mouthwash that contains alcohol. The CONSORT (Consolidated Standards of Reporting Trials) study flowchart is presented in Figure 1.

Detailed medical and dental histories were taken from each participant. In a structured questionnaire tailored to this study, all participants provided data regarding the age, gender, personal factors (general health, a medication used), lifestyle factors (smoking, alcohol consumption) and eating habits.

In order to analyze the strength of the test for the dependent Student's t-test (differences of the examined groups in

tvu ASA I označava zdrave pacijente, a ASA II one s blagom sistemskom bolešću bez funkcionalnih ograničenja), pacijenti bez alergije na titanij, bez protetičkih i ortodontskih nadomjestaka u usnoj šupljini, bez prekanceroznih lezija u usnoj šupljini, bez zračenja u području glave i vrata i bez korištenja bisfosfanata i kortikosteroida u terapiji.

Od svakog ispitanika uzeta je podrobna medicinska i dentalna anamneza. Svi su također ispunili strukturirani upitnik prilagođen ovom istraživanju koji je obuhvaćao podatke vezane za demografske čimbenike (dob i spol), osobne čimbenike (zdravstveno stanje, uporaba lijekova, izloženost zračenju), životne navike (pušenje, konzumacija alkohola) te prehrambene i oralno-higijenske navike. Kriteriji za isključenja obuhvaćali su sistemske bolesti (npr. nekontrolirani dijabetes, bolesti sluznice, neliječeni gingivitis i parodontitis, endodontske lezije), pušenje više od 10 cigareta na dan, dubinu džepova ≥ 4 mm na susjednim zubima, bruksizam, nedovoljne oralno-higijenske navike, trudnice i dojilje, korištenje antibiotika u posljednja tri mjeseca te tekućina za ispiranje usne šupljine koje sadržavaju alkohol te povijest zračenja u području gla-

the ROC analysis of binuclear changes) according to the following parameters: significance level $\alpha = 0.05$, an equal number of subjects in both groups, the effect of Cohen's size $d = 0.587$ (according to the obtained results), at least 37 participants per group had to be included in the test for 80% of the test power. A sample of 50 participants per study group was chosen to compensate for possible withdrawal, or loss.

Materials and surgical procedure

Patients were randomly assigned to one of the groups depending on the dental implant system used in the therapy. Ankylos dental implants (Dentsplay Sirona, Charlotte, USA) were used in the first group of patients and Dentium SuperLine (Dentium Co., Seoul, Korea) in the second group ($n = 46$ and $n = 45$, respectively). These two implant systems were chosen because they are the most frequently used implant systems in Croatia.

ve i vrata.

Analizom snage testa za zavisni t-test (razlike ispitivanih skupina u ROC analizi staničnih promjena mikronukleusa) prema sljedećim parametrima: razina značajnosti $\alpha = 0,05$, jednak broj ispitanika u objema skupinama, učinak veličine Cohena $d = 0,587$ (prema dobivenim rezultatima), u ispitivanju je za 80-postotnu snagu testa potrebno uključiti najmanje 37 ispitanika po skupini.

Materijali i kirurški postupak

Ispitanici su bili podijeljeni u dvije brojčano slične skupine, ovisno o sustavu dentalnih implantata korištenih u terapiji. U prvoj skupini za ugradnju upotrijebljeni su dentalni implantati Ankylos (Dentsplay Sirona, Charlotte, SAD), a u drugoj Dentium SuperLine (Dentium Co., Seoul, Koreja) ($n = 46$ i $n = 45$, slijedom). Ti implantološki sustavi odabrani su zato što su među najčešće korištenima u Hrvatskoj. Sastavi njihovih materijala, kako su naveli proizvođači, nalaze se u tablici 2.

Postavljanje implantata obavljeno je u skladu s uputama

Table 2 Composition of dental implant systems used in the study
Tablica 2. Sastav sustava dentalnih implantata korištenih u istraživanju

Dental Implant System	Manufacture	Composition	
		Dental implant	Healing abutment
Ankylos	Dentsplay Sirona, Charlotte, USA	Titanium Grades 2	Ti-6Al-4V
Dentium SuperLine	Dentium Co., Seoul, Korea	Titanium Grades 4	Titanium Grades 4

The composition of the products used, as written by the manufacturer, is shown in Table 2. The generation of the random allocation sequence was performed by computer software. Group allocation was concealed from the evaluating investigator during the analytical stage of the project.

The implants were placed following each implant system manufacturer's instructions, and the treatment was performed according to the patient's standards and indications. Surgical procedures on all patients were performed by the same operator with the same surgical approach, protocol and instrumentation.

A pre-operative panoramic radiograph was obtained for each patient. The surgeries were performed under local anesthesia with 4% articaine solution containing 1:100000 adrenaline (Ubistesin, 3M ESPE, Neuss, Germany). All patients were given oral antibiotic therapy of 2 gr per day for seven days, starting 24 hours prior to the intervention (Augmentin®, Glaxo-SmithKline Beecham, Brentford, UK). To ensure post-surgical oral hygiene, the patients were advised to rinse the oral cavity with 0.2% chlorhexidine (Miradent, Mouth Rinse paraguard chx, Hager Pharma GmbH, Duisburg, Germany) until the removal of sutures. The sutures were removed ten days after implantation. The implants were healing by being submerged for 12 weeks based on the surgeon's clinical judgment, indications given and the need and preference of the patients. After healing, healing abutments were placed. The used healing abutments were sterilized only once.

proizvođača o uporabi pojedinog sustava implantata, a zahvat je učinjen prema standardima i indikacijama pacijenta. Sve operacijske zahvate obavio je isti operater s jednakim kirurškim pristupom, protokolom i instrumentarijem. Promjer i dužina implantata te razina ugradnje odabrani su u skladu s pacijentovom indikacijom. Operacija je obavljena u lokalnoj anesteziji (4-postotni artikain s adrenalinom u omjeru 1 : 100 000 (Ubistesin, 3M ESPE, Neuss, Njemačka), a sustavni antibiotici (Augmentin®, Glaxo-SmithKline Beecham, Brentford, UK) ordinirani su prema standardnoj proceduri (2 g na dan tijekom 7 dana, s početkom 24 sata prije zahvata). Da bi se osigurala postkirurška oralna higijena, pacijentima je preporučeno ispiranje usne šupljine 0,2-postotnim klorheksidinom (Miradent, Hager Pharma GmbH, Duisburg, Njemačka) sve do uklanjanja šavova. Šavovi su uklonjeni od 7 do 14 dana poslije implantacije. Implantati su cijelili potopljeni 12 tjedana na temelju kliničke prosudbe kirurga, danih indikacija i potrebe te sklonosti pacijenata. Nakon cijeljenja postavljeni su gingivni formeri. Korišteni gingivni formeri do tada su sterilizirani samo jedanput.

Sample collection and a micronucleus assay in gingival epithelial cells

To reduce individual variations, patients were observed longitudinally, and participants served as their own control. Samples of gingival epithelial cells were collected from each participant's implementation site using the swab technique at three different time points: a control swab was taken just before the placement of dental implant (T0); the second swab was taken 90 days after implantation, that is, immediately before the placement of the healing abutment (T1), and the third swab was taken 21 days after the placement of the healing abutment (T2).

One hour before the sampling, the participants abstained from consuming any food and drinks. After rinsing the oral cavity three times with tepid water to remove exfoliated cells, a T0 swab was taken by gently brushing the gingiva around the place indicated for implant placement, and, after that T1 and T2 around the implant with a cytobrush (Cytobrush Plus; GmbH, Dietramszell-Linden, Germany). The samples were subsequently applied to coded laboratory glass slides.

The cells applied to microscopic slides were allowed to air-dry and were fixed in ethanol: glacial acetic acid (3:1) at 4°C for a minimum of 20 minutes. Staining of the slides followed the procedure described by Thomas *et al.* (15) and nuclei were stained with Schiff's reagent for 60 min in the dark setting, at room temperature (Feulgen-technique), whereas the cytoplasm was stained with Fast Green from Feulgen kit (lot FE-05/19, Biognost, Zagreb, Croatia) for 10-15 seconds. Nuclear anomalies, such as micronucleus, karyorrhexis (nuclear disintegration indicating apoptosis), karyolysis (dissolution of the nucleus mostly showing necrosis and apoptosis), pyknosis (nuclear shrinkage due to apoptosis), condensed chromatin (DNA complexed with proteins and apoptosis), nuclear buds (precursors of micronuclei, or high density of DNA repair complexes), broken eggs (nuclei that appear cinched) and binucleated cells (indicating the impaired speed of cell proliferation) were estimated and qualified according to Tolbert *et al.* (16). The analysis of 2000 gingival epithelial cells per participant was performed.

Statistical analysis

The SPSS 25.0 (IBM SPSS, Armonk, NY, USA) and Excel (Microsoft, Redmond, Washington, USA) were used for statistical data analysis. Descriptive statistics were used to determine basic statistical parameters (mean values, standard deviations). The differences among tested variables were evaluated by the Kruskal-Wallis one-way analysis of variance (difference between the evaluation periods) and the Mann-Whitney U test (difference between the dental implant systems). A multiple regression analysis was used to assess the effect of predictor variables (age, gender, eating habits, implant system, smoking, alcohol) on dependent variables (cytogenetic damage). The results are presented in the form of Pareto diagrams. The significance level was set at 0.05.

Uzorkovanje stanica i mikronukleus test

Da bi se smanjile interindividualne varijacije, pojedinci su promatrani longitudinalno, svaki ispitanik djelovao je kao svoja kontrola. Uzorci gingivnih epitelnih stanica s mjesta implantacije uzeti su od svakog ispitanika tehnikom četkanja u trima različitim vremenima: kontrolni bris uzet je neposredno prije postavljanja dentalnoga implantata (T0); 90 dana poslije implantacije, a neposredno prije postavljanja gingivnoga formera (T1); 21 dan poslije postavljanja gingivnoga formera (T2).

Od svih sudionika u istraživanju zatraženo je da se jedan sat prije uzorkovanja suzdrže od pušenja, jela te konzumacije alkoholnih pića. Neposredno prije uzorkovanja svi su tri puta isprali usnu šupljinu vodom iz slavine kako bi isprali mrtve odljuštene stanice. Primjenom citološke četkice (Cytobrush Plus, GmbH, Dietramszell-Linden, Njemačka), nježnim četkanjem gingivne sluznice oko mjesta predviđenoga za implantat, a poslije i oko samoga implantata, uzet je bris gingivnih epitelnih stanica nakon čega su stanice stavljene na predmetno stakalce razmazane.

Stanice su na predmetnom stakalcu fiksirane otopinom etanola i octene kiseline (3 : 1), na temperaturi od 4 °C te ostavljene 20 minuta nakon čega su obojene prema proceduri Thomasa i suradnika (15), a nukleusi su se bojili Schiffovim reagensom 60 minuta u tami na sobnoj temperaturi (Feulgenova tehnika). Citoplazma je pak od 10 do 15 sekunda bojena Fast Greenom iz Feulgenova seta (lot FE-05/19, Biognost, Zagreb, Hrvatska).

Za svakog ispitanika analizirano je 2000 epitelnih stanica za pojedino razdoblje uzorkovanja u duplikatu. Učestalost nuklearnih anomalija, odnosno mikronukleusa, binuklearnih stanica, stanica s kondenziranim kromatinom, piknotičnih stanica, kariolize, kariorekse i jezgrinih pupoljaka, procijenjena je i kvalificirana prema Tolbertu i suradnicima (16). Oni su odredili i sljedeće kriterije za identifikaciju mikronukleusa: (a) zaobljen, gladak obujam koji upućuje na membranu; (b) veličinom manji od trećine promjera jezgre, ali dovoljno velik da mu se prepoznaju boja i oblik; (c) intenzitetom obojenja mora odgovarati obojenju jezgre; (d) slične teksture kao jezgra; (e) u istoj fokalnoj ravnini s jezgrom i (f) odsutnost preklapanja i bilo kakva spajanja s jezgrom.

Statistička obrada podataka

Za statističku obradu podataka korišten je programski paket SPSS 25.0 (IBM SPSS, Armonk, NY, SAD) i Excel, dio programskoga paketa Microsoft Office (Microsoft, Redmond, Washington, SAD). Za određivanje osnovnih statističkih parametara (srednje vrijednosti, standardne devijacije) primijenjena je deskriptivna statistika. Razlike među ispitivanim varijablama utvrđivane su Kruskal-Wallisovom jednosmjernom analizom varijance (razlika među ispitivanim vremenskim razdobljima) i Mann-Whitneyjevim U testom (razlika među implantološkim sustavima). Multipla regresijska analiza korištena je za procjenu učinka prediktorskih varijabli (dob, spol, prehrambene navike, implantološki sustav, pušenje, alkohol) na zavisne varijable (citogenetsko oštećenje). Rezultati su prikazani u obliku Paretova dijagrama.

U svim testovima razina značajnosti bila je $P < 0,05$.

Results

The study involved 91 subjects, of whom 35 were men and 56 women, aged 32 to 71 years. The participants were randomly divided into two groups depending on the used dental implant system. The Ankylos group comprised 27 females and 19 males; aged 32–71 (mean age 54.1 ± 9.5 years). The Dentium SuperLine group comprised 29 females and 16 males; aged 39–71 (mean age 52.0 ± 10.1 years).

The results of the micronucleus test are shown in Table 3. The results of Kruskal–Wallis one-way analysis of variance showed the difference between sampling times T0 (before implant insertion) compared to T1 (90 days after insertion of the implant) and T2 sampling time points (21 days after healing abutment placement), for the number of binuclear cells ($P \leq 0.001$) for both tested implant systems.

The analysis of Mann–Whitney U test indicated no statistically significant difference between two estimated implant systems for non-cytogenetic endpoints in the time T0 before implant placement. The difference was observed for nuclear buds ($P = 0.004$) and binucleated cells ($P = 0.021$) at sampling time T1 (90 days after implant placement) and also for nuclear buds ($P = 0.034$) in T2 time (21 days after healing abutment placement).

The dependence of the micronucleus test parameters on all predictor variables in the total test group was determined by the general regression model and presented in the form of Pareto diagrams (Figure 2 and Figure 3). The influence on the incidence of the number of cells with micronucleus, of all observed demographic variables encountered as predictor variables, were observed for gender – female ($\beta = -0.342$, $SE = 0.112$, $P = 0.004$), dental implant system ($\beta = 0.263$, $SE = 0.112$, $P \leq 0.001$), alcohol ($\beta = -0.242$, $SE = 0.066$, $P \leq$

Rezultati

U istraživanju je sudjelovao 91 ispitanik, 35 muškaraca i 56 žena u dobi od 32 do 71 godine. Bili su nasumično podijeljeni u dvije skupine, ovisno o korištenom implantološkom sustavu. Skupina Ankylos sastojala se od 27 žena i 19 muškaraca u dobi od 32 do 71 godine (srednja dob $54,1 \pm 9,5$). Skupina Dentium SuperLine sastojala se od 29 žena i 16 muškaraca u dobi od 39 do 71 godine (srednja dob $52,0 \pm 10,1$).

Rezultati mikronukleusnoga testa nalaze se u tablici 3. Rezultati Kruskal–Wallisove jednosmjerne analize varijance pokazuju razliku između testiranoga razdoblja T0 (prije ugradnje implantata) u usporedbi s razdobljima T1 (90 dana poslije ugradnje implantata) i T2 (21 dan poslije postavljanja gingivnoga formera), za broj binuklearnih stanica ($P \leq 0,001$) za oba testirana implantološka sustava.

Analiza Mann–Whitneyjeva U testa nije pokazala statistički značajne razlike između dvaju ispitivanih implantoloških sustava za citogenotoksične promjene u razdoblju T0 prije postavljanja implantata. Razlika je pronađena za jezgrine pupove ($P = 0,004$) i binuklearne stanice ($P = 0,021$) u razdoblju T1 (90 dana poslije postavljanja implantata) te također za jezgrine pupove ($P = 0,034$) u razdoblju T2 (21 dan poslije postavljanja gingivnoga formera).

Ovisnost parametara mikronukleusnoga testa o svim prediktorskim varijablama u ukupnoj ispitnoj skupini utvrđena je generalnim regresijskim modelom i prikazana u obliku Paretova dijagrama (slike 2. i 3.). Utjecaj na incidenciju broja stanica s mikronukleusom od svih promatranih demografskih varijabli kao prediktorskih varijabli su spol – žene ($\beta = -0,342$, $SE = 0,112$, $P = 0,004$), implantološki sustav ($\beta = 0,263$, $SE = 0,112$, $P \leq 0,001$), konzumacija alkohola

Table 3 Frequencies of nuclear abnormalities in exfoliated gingival epithelial cells at different time points
Tablica 3. Učestalosti nuklearnih abnormalnosti u oljuštenim epitelnim stanicama gingive u različitim vremenskim točkama

Tested cytogenetic damages	Time of sampling			
	T0	T1	T2	
Number of cells with micronuclei	Dentium SuperLine	1 (1.5)	1 (1)	1 (1)
	Ankylos	1 (2)	1 (1)	2 (1)
Number of cells with nuclear buds	Dentium SuperLine	0 (1)	0 (1) ^a	0 (1) ^a
	Ankylos	0 (1)	1 (1) ^b	1 (1) ^b
Number of cells broken eggs	Dentium SuperLine	0 (1)	0 (1)	0 (1)
	Ankylos	0 (1)	1 (1)	1 (1)
Number of binucleated cells	Dentium SuperLine	4 (1) ^A	5 (2) ^{Ba}	5 (2) ^C
	Ankylos	5 (2) ^A	6 (1) ^{Bb}	6 (1) ^B
Number of cells with karyorrhexis	Dentium SuperLine	1 (3)	1 (3)	3 (2.5)
	Ankylos	3 (2)	3 (0.75)	3 (3)
Number of cells with karyolysis	Dentium SuperLine	7 (4)	7 (4)	6 (4)
	Ankylos	3 (4)	3 (4)	7 (4)
Number of cells with condensed chromatin	Dentium SuperLine	2 (2)	2 (2)	2 (2)
	Ankylos	2 (2)	2 (1)	2 (1.25)
Number of cells with pyknosis	Dentium SuperLine	4 (2)	2 (2)	4 (4)
	Ankylos	4 (2)	4 (2)	4 (2.25)

Data are presented as median and interquartile range.

*Different upper capital letters indicate a significant difference among the evaluation periods, and different lower-case letters indicate a significant difference among the treatment groups ($P < 0.05$). Abbreviations: T0, sample before the treatment – baseline; T1, 90 days after implant insertion; T2, 21 days following the healing abutment placement.

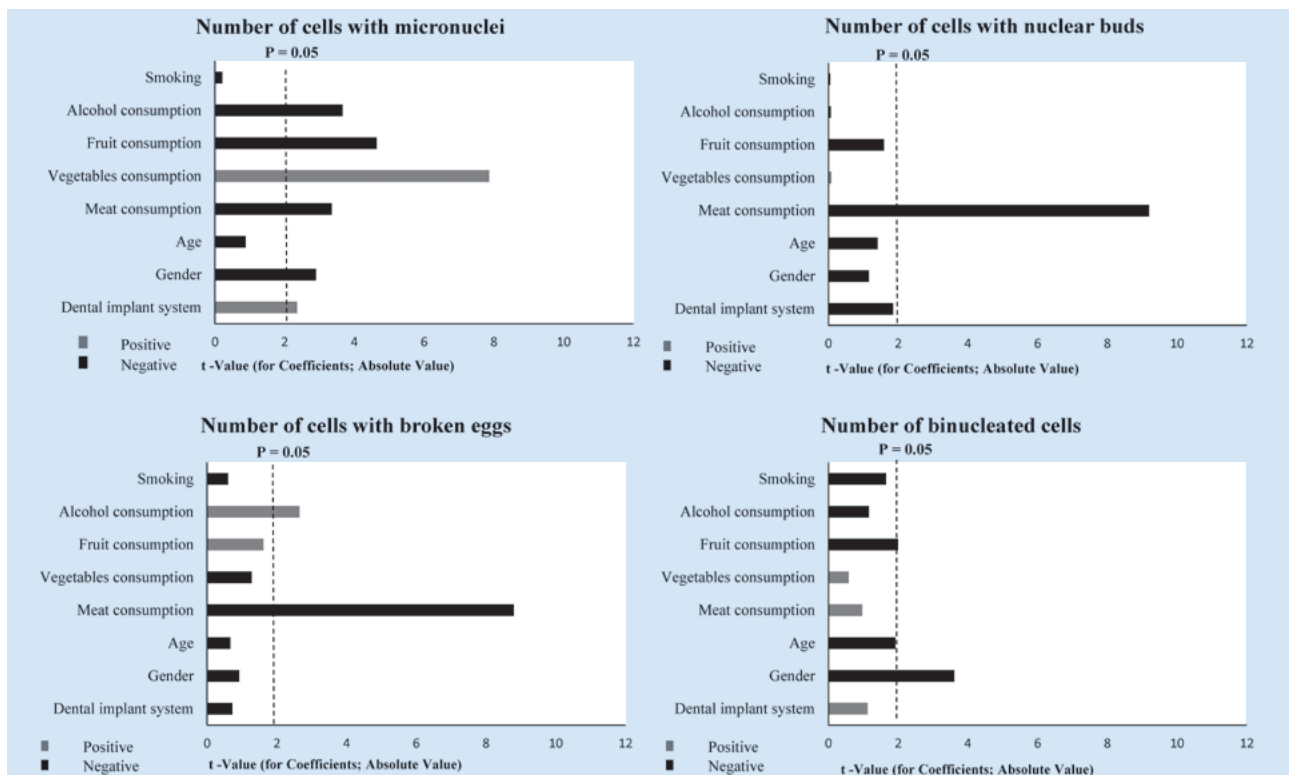


Figure 2 Multiple regression analysis results. There is a significant association between cytogenetic endpoints in gingival epithelial cells (number of micronuclei, broken eggs, nuclear buds, and binucleated cells) and demographic and lifestyle factors as possible predictors.

Slika 2. Rezultati višestruke regresijske analize; značajna povezanost citogenetskih oštećenja u epitelnim stanicama gingive (mikronukleus, binuklearne stanice, slomljeno jaje, jezgrin pup) s demografskim čimbenicima i čimbenicima načina života kao mogućim prediktorima

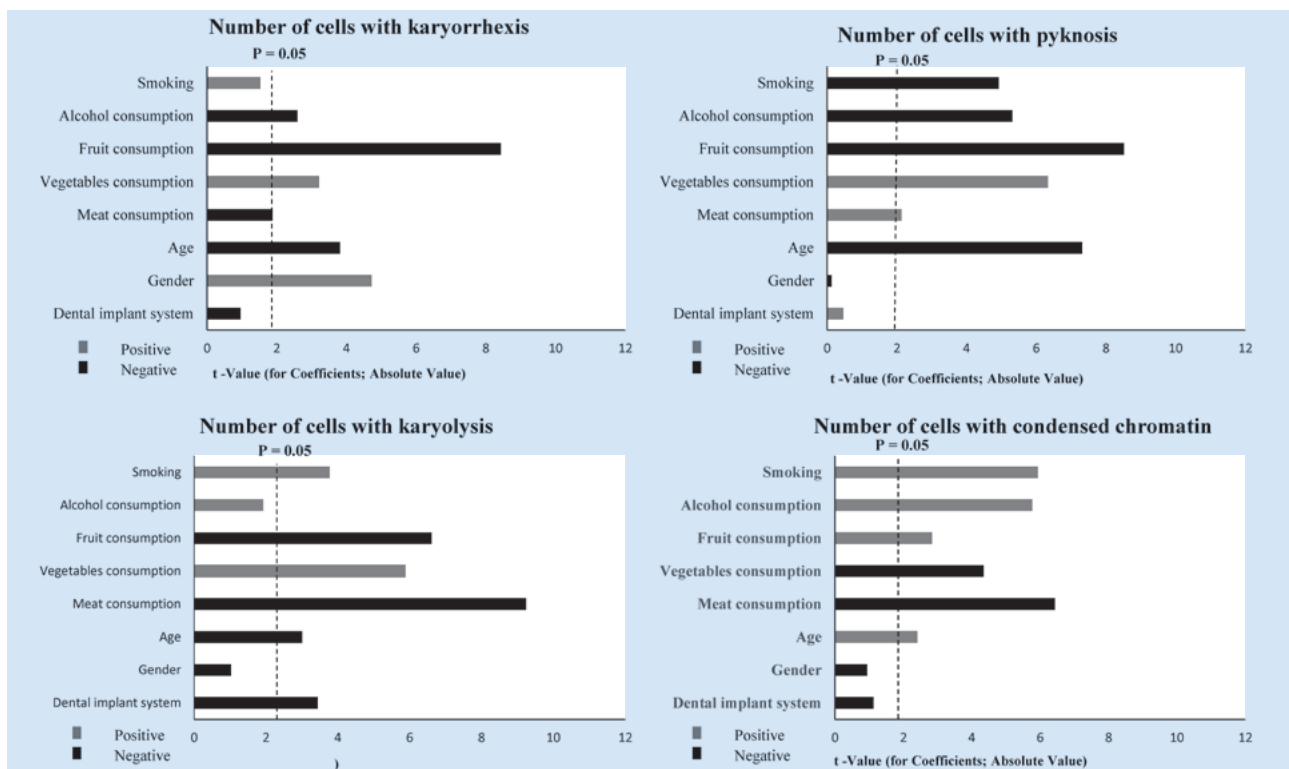


Figure 3 Multiple regression analysis results. There is a significant association between cytogenetic endpoints in gingival epithelial cells (karyorrhexis, pyknosis, karyolysis, and condensed chromatin) with demographic and lifestyle factors as possible predictors.

Slika 3. Rezultati višestruke regresijske analize; značajna povezanost citogenetskih oštećenja u epitelnim stanicama gingive (piknotička stanica, stanice s kondenziranim kromatinom, kariolitična stanica i stanica s kariohetičnim kromatinom) s demografskim čimbenicima i čimbenicima načina života kao mogućim prediktorima

0.001), fruit ($\beta = 1.143$, $SE = 0.246$, $P \leq 0.001$), vegetables ($\beta = 0.633$, $SE = 0.082$, $P \leq 0.001$) and meat ($\beta = -0.182$, $SE = 0.054$, $P \leq 0.001$) consumption.

Discussion

The aim of this prospective study was to evaluate the cytotoxic and genotoxic alterations in gingival epithelial cells after the application of a titanium-based dental implant system. Patients who underwent dental implant placement were divided into two groups based on the type and manufacturer of the implant system. For one group, the implant system was Ankylos (cpTi Grade II – dental implant, Ti–6Al–4V – healing abutment), and for the other Dentium (cpTi Grade IV – dental implant and healing abutment). To compare the changes in gingival epithelial cells at the site of the implant, cytological scrapings of the oral mucosa were collected at three time points: just before implant placement, 90 days after implantation, but immediately before placement of the healing abutment and 21 days after the placement of healing abutments. Genotoxicity and cytotoxicity were assessed by a micronucleus test – the most commonly used and reliable assay in terms of evaluating the induction of chromosomal aberrations *in vivo*, and *in vitro*, and in detecting possible carcinogens.

The research results show that both implant systems, Ankylos and Dentium SuperLine, cause a statistically significant increase in the number of binuclear cells three months after their implantation compared to the control scrapings taken before implantation ($P \leq 0.001$ and $P \leq 0.001$, respectively). Furthermore, a statistically significant increase in the number of binuclear cells has been observed in both implant systems after healing abutment placement compared to the control group prior to implant placement ($P \leq 0.001$ and $P \leq 0.001$, respectively). However, since standard variations of statistically different endpoints are in the range of variation between the mean values of these endpoints for the two groups compared, and although statistically significant, the results may not be considered as biologically or clinically relevant. Therefore, the null hypothesis stating that implant systems do not cause genotoxic or cytotoxic damage can be accepted.

Karahalil et al. (17) assessed the genotoxic effects of titanium alloy dental implants on the gingival epithelial cells of 37 participants using the micronucleus test. Their results showed a slight increase in the incidence of micronuclei ($P = 0.047$) in the second swab taken a few weeks after the implant placement procedure. They concluded that the degree of particle release from the implant was too low to cause more severe DNA damage or genotoxicity.

The increased parameters obtained after placement of the healing abutment can be related to several factors. Since the oral cavity is a complex environment, corrosive substances from dietary, human saliva and oral biofilms may accumulate in retentive areas of dental implant systems promoting corrosion at their surfaces. Since the healing abutment is in direct contact with gingival epithelial cells, corrosion of the implant may adversely affect surrounding cells (10). Furthermore, micromovements occur during mastication at the site

la ($\beta = -0.242$, $SE = 0.066$, $P \leq 0.001$), konzumacija voća ($\beta = 1.143$, $SE = 0.246$, $P \leq 0.001$), povrća ($\beta = 0.633$, $SE = 0.082$, $P \leq 0.001$) i mesa ($\beta = -0.182$, $SE = 0.054$, $P \leq 0.001$).

Rasprava

Cilj ove prospektivne studije bio je procijeniti citotoksični i genotoksični učinak dvaju dentalnih implantoloških sustava temeljenih na titaniju na gingivnim epitelnim stanicama. Ispitanici su bili podijeljeni u dvije skupine, ovisno o korištenom implantološkom sustavu. Jednoj skupini ugrađen je implantološki sustav Ankylos (cpTi razreda II – implantat, Ti–6Al–4V – gingivni former), a drugoj Dentium (cpTi razreda IV – implantat i gingivni former). Brisovi oralne sluznice s mjesta implantacije uzeti su neposredno prije ugradnje implantata, zatim 90 dana poslije, a neposredno prije postavljanja gingivnoga formera te 21 dan poslije njegova postavljanja. Genotoksičnost i citotoksičnost bile su procjenjivane mikronukleusnim testom, minimalno invazivnom, razmjerno jednostavnom i pouzdanom metodom kojom se uspješno bilježe sva jezgrena oštećenja u uvjetima *in vivo* i *in vitro*.

Rezultati istraživanja pokazuju da oba implantološka sustava – Ankylos i Dentium – statistički značajno povećavaju broj binuklearnih stanica tri mjeseca poslije njihova postavljanja u odnosu prema kontrolnome brisu uzetom prije implantacije ($P \leq 0.001$ i $P \leq 0.001$, slijedom). Gingivni former kod obaju implantoloških sustava (Ankylos i Dentium) statistički značajno povećava broj binuklearnih stanica u odnosu prema kontrolnome brisu prije postavljanja implantata ($P \leq 0.001$ i $P \leq 0.001$, slijedom). Te rezultate, iako su statistički značajni, ne možemo smatrati ni biološki ni klinički relevantnima da bismo na temelju njih zaključili da su implantati genotoksični ili citotoksični jer su povećanja spomenutih parametara, gledajući apsolutne vrijednosti, još uvijek preniska. Zato prihvaćamo nultu hipotezu postavljenu na početku istraživanja da implantati, odnosno implantološki sustavi ne uzrokuju ni genotoksična ni citotoksična oštećenja.

Karahalil i suradnici (17) proveli su istraživanje u kojemu su ispitivali genotoksičnost dentalnih implantata od titanijevе legure na gingivnim epitelnim stanicama 37 ispitanika koristeći se mikronukleusnim testom. Njihovi rezultati pokazali su blagi porast mikronukleusa ($P = 0.047$) u drugom brisu uzetom nekoliko tjedana poslije ugradnje implantata te su zaključili da je razina otpuštanja čestica s implantata bila preniska da bi oštetila DNK, odnosno genotoksičnost.

Povećani parametri poslije postavljanja gingivnoga formera mogu biti povezani s nekoliko čimbenika. Oralna šupljina složen je biookoliš, određene tvari iz prehrane, sline i oralnoga biofilma mogu se akumulirati na retentivnim dijelovima implantata i/ili gingivnoga formera s čije površine tada potiču koroziju. S obzirom na to da je gingivni former u izravnom kontaktu s gingivnim epitelnim stanicama, korozija implantata šteti okolnim gingivnim stanicama (10). Nadalje, na kontaktu implantata i gingivnoga formera događa se mikropokret tijekom žvakanja i posljedično tomu frikcija, što urušava cjelovitost površinskoga zaštitnoga sloja titanijeva dioksida. Taj slijed događaja potiče daljnju koroziju, a korozija pak inducira frikciju. Nekoliko različitih procesa (trošenje,

of the implant and healing abutment junction. Consequently, the friction that impairs the integrity of the protective layer of titanium dioxide occurs. This event promotes further corrosion and corrosion induces friction. Multiple processes (wear, friction and corrosion) in contact with biological tissues and fluids result in a bio-tribocorrosion, a relatively new research field that combines the fundamentals of tribology (friction, wear, and lubrication) and corrosion (8, 10, 18).

Ribeiro *et al.* (19) artificially induced corrosion in several implants of different manufacturers by immersing them in a solution of acetic acid and NaCl after which the Chinese hamster's ovarian cells were exposed to that solution. After performing the comet test, they concluded that none of the dental implants used in their study demonstrated genotoxicity. Several studies have shown the genotoxic, and cytotoxic potential of TiO₂ particles (1–100 nm) released as a result of bio-tribocorrosion (20, 21). Similar findings were obtained in a study by Tavares *et al.* (22) reporting that the implant surface without finishing treatment has a thinner layer of TiO₂ and is, therefore, more susceptible to corrosion. That contributes to a significantly higher release of particles and ions that mediate the formation of free radicals, oxidative stress and DNA oxidation as primary genotoxic events.

Wang *et al.* (23) based on the results obtained from several different genotoxicity tests, including the micronucleus test *in vitro*, suggested that ultra-fine nanoparticles of TiO₂ (<100 nm) cause genotoxic and cytotoxic damage in human lymphoblastoid cells. Maloney *et al.* (24) and Kumazawa *et al.* (25) found that vanadium (V), aluminium (Al), cobalt (Co), chromium (Cr) and nickel (Ni) are genotoxic at a higher concentration. In contrast, cobalt (Co) induced a cell death. Camacho-Alonso *et al.* (26) conducted the micronucleus assay on buccal epithelial cells aiming to detect genotoxicity as a result of metal ion release in patients with titanium dental implants, and various metal restorations in the mouth. Although increased concentrations of metal ions were found in all subjects, no genotoxic damage was found in any of the subjects.

The reason why some studies consisting of patients undergoing implantation showed positive cyto/genotoxic effects and others not, may lie in the fact that in advanced economies healing abutments are used only once. When placed in the cavity for the first time, they release biologically active particles formed only by physiological corrosion. On the other hand, in less economically powered societies healing abutments are recycled and subjected to several sterilization cycles resulting in a higher level of proneness to corrosion and a higher level of particles available for being released, for each implantation. In addition to the influence of the composition of the material itself on corrosion, there is the issue of both the impact of the sterilization process and the number of repeated sterilizations on material composition and corrosion. Allsobrook *et al.* (27) investigated the effect of recurrent sterilization on the corrosion of titanium drills used for the surgical implantation procedure. He concluded that such drills are subject to material loss and particle release. Furthermore, some other authors have proved that autoclave sterilization promotes surface corrosion (28, 29). To our best knowledge, there are no publi-

frikcija i korozija) u kontaktu s biološkim tkivima i tekućinama rezultira biotribokorozijom, razmjerno novoistraživanim znanstvenim područjem koje spaja temelje tribologije (trošenje, frikcija i vlaženje) i korozije (8, 10, 18).

Ribeiro i suradnici (19) izazvali su koroziju u nekoliko implantata različitih proizvođača držeći ih u otopini octene kiseline i natrijeva klorida (NaCl) nakon čega su toj otopini izložili epitelne stanice jajnika kineskoga hrčka. Nakon provedbe komet-testa, tj. mikrogel elektroforeze zaključili su da ni jedan dentalni implantat koji je bio uključen u ispitivanje nije prouzročio genotoksičnost. U nekoliko istraživanja dokazan je genotoksičan i citotoksičan potencijal čestica TiO₂ (1 – 100 nm) oslobođenih kao posljedica biotribokorozije (20, 21).

Slične podatke dobili su i Tavares i suradnici (22) jer su uvidjeli da površina implantata bez završne obrade ima tanji sloj TiO₂ te je tako podložnija koroziji, a otpuštene čestice i ioni utječu na nastanak slobodnih radikala, oksidacijskoga stresa i oksidacije DNK, što rezultira genotoksičnim događajima.

Nadalje, Wang i suradnici (23) zaključili su na temelju svojega istraživanja i rezultata dobivenih iz nekoliko različitih testova citotoksičnosti, među kojima i Cytokinesis block micronucleus (CBMN) testa, da su ultrafine, tj. nanočestice TiO₂ (< 100 nm u promjeru) prouzročile genotoksična i citotoksična oštećenja u ljudskim limfoblastoidnim stanicama. Maloney i suradnici (24) te Kumazawa i suradnici (25) ustanovili su da su vanadij (V), aluminij (Al), kobalt (Co), krom (Cr) i nikal (Ni) citotoksični u većim koncentracijama, a kobalt (Co) uzrokuje staničnu smrt.

Camacho-Alonso i suradnici (26) ispitivali su mikronukleusni testom na bukalnim epitelnim stanicama postoje li genotoksična oštećenja u pacijenata s titanijevim dentalnim implantatima i različitom metalnom restauracijom u ustima zbog otpuštanja metalnih iona. Iako su kod svih ispitanika, osim kontrolne skupine koja je jedino imala implantate u ustima, nađene povećane koncentracije metalnih iona, kod nijednoga nisu pronađena genotoksična oštećenja.

Objašnjenje zašto su određena istraživanja koja su pratila ispitanike kojima su ugrađivani implantati pokazala cito/genotoksične učinke, a druga nisu, može biti u činjenici da se u gospodarski razvijenijim zemljama gingivni formeri upotrebljavaju isključivo jedanput. Kada se prvi put unesu u usnu šupljinu, otpuštaju biološki aktivne čestice stvorene isključivo fiziološkom korozijom. U gospodarski slabije razvijenim zemljama gingivni se formeri steriliziraju i ponovno koriste, što ih čini podložnijima koroziji. Zato, osim utjecaja sastava materijala na koroziju, postavlja se i pitanje utjecaja postupka sterilizacije i broja opetovanih sterilizacija na sastav materijala i koroziju.

Allsobrook i suradnici (27) istraživali su utjecaj ponavljanih sterilizacija na koroziju titanijevih svrdala za kirurški postupak implantacije i zaključili su da su takva svrdla podložna gubitku materijala i otpuštanju čestica. Drugi autori dokazali su da sterilizacija u autoklavu pospješuje površinsku koroziju (28, 29). Iako u literaturi nismo našli nijedan rad o utjecaju opetovanih postupaka sterilizacije na sastav materijala gingivnih formera, pretpostavljamo da postoji sličan obrazac djelo-

cations on the influence of repeated sterilization procedures on the material composition of the healing abutments; hence there could also be a similar pattern with drills.

Increased values of binuclear cells after implant and healing abutment placement could also be explained by accelerated cell proliferation in the inflammatory phase of wound healing, which is inevitable after surgical manipulation of tissue. The patient has to be subjected to two surgical procedures; the first, when the implant is being inserted into the bone, and second when the healing abutment is placed (30). Additionally, it has been found that inflammation can also be triggered by released particles from the TiO₂ layer disrupted by the tribocorrosion which the immune system recognizes as antigen and triggers the inflammatory reaction with cytokine release (10,11,12). Among the different types of cytokines released, there are mitogenic cytokines, primarily IL-1 β that accelerate cell proliferation (12). De Barros Lucena *et al.* (31) proved the accumulation of biofilm inside the implant structure in 52.6% of placed and completely closed implants before the placement of the healing abutment and prosthetic superstructure. Using the DNA-DNA hybridization technique, they confirmed the presence of 40 species of bacteria on the implants, of which 77.4% were present in the mandible. The next step in this sequence of events is that lipopolysaccharides present in the membrane of Gram-negative bacteria act as ligands for Toll-like receptors (TLRs) of gingival epithelial cells (32). Moreover, Eskan *et al.* (33) found that an increased expression of TLR4 receptors on gingival epithelial cells positively correlated with increased IL-1 β production, inflammation itself and accelerated cell proliferation. The last step in this pathophysiological sequence of events is that accelerated cell proliferation leads to more frequent errors in cytokinesis and therefore, larger numbers of binuclear cells are recorded.

Certain studies have shown that failure of implant therapy can be caused by an inflammatory reaction in the surrounding tissue as a response to corrosion of the titanium alloy (34, 35). There is also a systemic disease associated with titanium. Berglund and Carlmark (36) studied a group of 30 subjects exhibiting the yellow nails, bronchial obstruction and lymphedema. They concluded that the cause of the syndrome is a high level of titanium (Ti)

The primary source of titanium ions was corrosion caused by galvanism between titanium implants and gold and amalgam restorations in the mouth as well as from corrosion caused by fluoride oxidation.

This trial has certain number of limiting factors. It is recommended to include more implant systems, more participants and to establish a long-term follow up of cell changes around the implant site. It would also be advisable to observe clinical and biochemical (gingival fluid) parameters and genotoxicity to evaluate the levels of tissue inflammation around the implant.

Conclusion

It may be concluded that the placement of both implants into the oral cavity, and the placement of the healing abut-

vanja kao i sa svrdlima, čime dodatno potkrepljujemo objašnjenje dobivenih rezultata.

Povećane vrijednosti binuklearnih stanica poslije ugradnje implantata te postavljanja gingivnih formera mogu se objasniti ubrzanom proliferacijom stanica u upalnoj fazi cijeljenja rane koja je neizbježna nakon kirurškoga manipuliranja tkivom, kako u prvom kirurškom zahvatu implantacije, tako i u drugom kirurškom zahvatu „otvaranja“ implantata i postavljanja gingivnoga formera (30). Dodatno je otkriveno da upalu mogu potaknuti i oslobođene čestice iz sloja TiO₂ narušenoga navedenim postupcima koje imunostni sustav prepoznaje kao strana tijela te pokreće upalnu reakciju koja posljedično uzrokuje oslobađanje citokina (10-12). Među različitim vrstama oslobođenih citokina su i mitogeni citokini, ponajprije IL-1 β , koji ubrzavaju proliferaciju stanica (12). Imamo teoriju da osim čestica TiO₂, još nešto utječe na povećanje citokina IL-1 β . Naime, de Barros Lucena i suradnici (31) dokazali su akumulaciju biofilma u unutrašnjosti implantata kod 52,6 % umetnutih i potpuno zatvorenih implantata prije samog postavljanja gingivnoga formera i proteičke suprastrukture. Tehnikom DNK hibridizacije potvrdili su prisutnost 40 vrsta bakterija na implantatima i od toga je 77,42 % bilo u mandibuli. Sljedeći korak u tom slijedu jest da lipopolisaharidi u membrani gram-negativnih bakterija djeluju kao ligandi za receptore Toll like (TLR) gingivnih epitelnih stanica (32). Štoviše, Eskan i suradnici (33) utvrdili su da je povećana ekspresija receptora TLR4 na gingivnim epitelnim stanicama u korelaciji s povećanom produkcijom IL-1 β , a time i samom upalom te ubrzanom proliferacijom stanica. Posljednji korak u ovoj patofiziološkoj shemi jest da ubrzana proliferacija stanica rezultira češćim pogreškama u citokinezi i da je posljedica toga veći broj binuklearnih stanica.

Autori određenih istraživanja dokazali su da neuspjeh implantološke terapije može biti prouzročen upalnom reakcijom u okolnom tkivu kao odgovorom na koroziju titanijeve legure (34, 35). Postoji i jedna sistemska bolest povezana s titanijem. Berglund i Carlmark (36) pripisali su titaniju pojavu sindroma žutoga nokta kada su u noktima 30 ispitanika, koji su osim žutih noktiju imali i bronhijalnu opstrukciju i limfedem, dokazali visok sadržaj titanija. Kao glavni izvor titanijevih iona naveli su koroziju prouzročenu galvanizmom između titanijevih implantata i zlatne i/ili amalgamske restauracije u ustima te koroziju izazvanu oksidacijom fluora.

Ovo istraživanje ima i određen broj ograničavajućih čimbenika. Potrebno je povećati uzorak ispitivanih proizvođača implantata, proširiti istraživanje na veći broj ispitanika i uspostaviti dugoročno praćenje promjena poslije postavljanja suprastrukture i završetka cijele terapije. Bilo bi također dobro pratiti kliničke i biokemijske (sulkusna tekućina) parametre i genotoksičnost za procjenu upalne reakcije oko implantata.

Zaključak

Može se zaključiti da ugradnja implantata i postavljanje gingivnoga formera obaju ispitivanih implantoloških sustava

ments affect cell homeostasis and genome stability. It is most significantly observed in an increase in binucleated cells for both tested dental implant systems. However, the observed effects could not be assigned to the impact of the released Ti particles. It may also be mediated by surgical procedures that have to be undertaken, which lead to inflammation of surrounding tissue, and the cells affected by inflammation show a cyto/genotoxic effect. However, by applying the weight of the evidence approach to evaluate the results of this study, we can say that although there has been a significant increase recorded in previously stated cyto/genotoxic events, they are not biologically relevant.

Conflict of Interest

The authors have no conflicts of interest to declare.

Data Availability Statement

The data supporting the findings of this study are available from the corresponding author upon reasonable request.

Funding

The authors declared that this study has received no financial support.

Authors Contribution: M.R. contributed to acquisition of data, drafting the article, critical revision of the article, approval of the paper; D.J., I.S., J.P., and E.P.M. contributed to concept and design of the study, acquisition of data, drafting the article, and final approval of the article, while L.G, D.Z. and A.T. contributed to concept and design, acquisition of data, analysis and interpretation of data, drafting the article or revising it critically for important intellectual content, and final approval of the version to be published.

u oralnu šupljinu utječe na homeostazu stanica i genomsku stabilnost. To se najviše ogleda u povećanju broja binuklearnih stanica u oba implantološka sustava. Ipak, zapaženo se ne može pripisati utjecaju otpuštenih titanijevih čestica, nego možda i kirurškom zahvatu koji dovodi do upale okolnoga periimplantatnoga tkiva zbog čega stanice zahvaćene upalom pokazuju cito/genotoksičan učinak. Na temelju dobivenih rezultata, koristeći se snagom dokaza, možemo istaknuti da titanijevi dentalni implantati poslije postavljanja ne izazivaju citotoksične i genotoksične učinke na gingivnim stanicama te da se uočeni blagi učinci ne mogu smatrati biološki relevantnima.

Sukob interesa

Autori nisu bili u sukobu interesa.

Izjava o dostupnosti podataka

Podatci koji podupiru nalaze iz ove studije mogu se na zahtjev dobiti od dopisnoga autora.

Financiranje

Autori su izjavili da ova studija nije dobila nikakvu financijsku potporu.

Doprinos autora: M. R. – prikupljanje podataka, pisanje članka, kritička revizija članka, odobrenje rada; D. J., I. S., J. P. i E. P. M. – osmišljavanje i izrada studije, prikupljanje podataka, pisanje članka i konačno odobrenje članka; L. G, D. Z. i A. T. – koncepcija i dizajn, prikupljanje podataka, analiza i interpretacija podataka, pisanje članka ili njegova kritička revizija te konačno odobrenje verzije koja će biti objavljena.

Sažetak

Cilj istraživanja: Iako se titanijevi dentalni implantati smatraju bioinertnima, potvrđeno je da su podložni koroziji i trošenju. Cilj ovog istraživanja jest procjena citotoksičnoga i genotoksičnoga potencijala dviju vrsta implantoloških sustava na gingivnim epitelnim stanicama. **Materijal i metode:** Uzorci oljuštenih gingivnih stanica uzeti su od 91 ispitanika u trima razdobljima. Prvi bris uzet je prije postavljanja implantata, drugi 90 dana poslije njegove ugradnje, a treći 21 dan poslije postavljanja nadogradnje za oblikovanje gingive, tj. gingivnoga formera. Oštećenje DNK procijenjeno o je mikronukleusnim testom. Ispitivani dentalni implantati s gingivnim formerima bili su Ankylos i Dentium SuperLine. **Rezultati:** Dobiveni rezultati pokazuju da se poslije postavljanja objiju vrsta ispitivanih dentalnih implantata (Ankylos i Dentium) znatno povećava broj binuklearnih stanica ($P \leq 0,001$) u odnosu prema početnim vrijednostima i to 90 dana poslije postavljanja implantata i 21 dan poslije postavljanja gingivnoga formera. **Zaključak:** Na temelju dobivenih rezultata može se zaključiti da titanijevi dentalni implantati nakon postavljanja ne izazivaju citotoksične i genotoksične učinke na gingivnim stanicama. Uočeni blagi učinci ne mogu se smatrati biološki relevantnima.

Zaprimljen: 24. ožujka 2022.

Prihvaćen: 20. srpnja 2022.

Adresa za dopisivanje

Antonija Tadin,
Sveučilište u Splitu, Medicinski
fakultet
Studij dentalne medicine
Katedra za restaurativnu dentalnu
medicinu i endodonciju
Šoltanska 2, 21 000 Split, Hrvatska
tel: +38598609191,
faks: +38521557624,
atadin@mefst.hr

MeSH pojmovi: zubni implantati; titanij; korozija; mikronukleusni test; gingiva; epitelne stanice

Autorske ključne riječi: biokompatibilnost, dentalni implantat

References

- Clark D, Levin L. Dental implant management and maintenance: How to improve long-term implant success? *Quintessence Int.* 2016; 47(5):417-423.
- Velasco-Ortega E, Jos A, Camean AM, Pato-Mourello J, Segura-Egea JJ. In vitro evaluation of cytotoxicity and genotoxicity of a commercial titanium alloy for dental implantology. *Mutat Res.* 2010 Sep 30;702(1):17-23.
- Karci BL, Oncu E. Comparison of Osteoimmunological and Microbiological Parameters of Extra Short and Longer Implants Loaded in the Posterior Mandible: A Split Mouth Randomized Clinical Study. *Acta Stomatol Croat.* 2021 Sep;55(3):238-247.
- Osman RB, Swain MV. A Critical Review of Dental Implant Materials with an Emphasis on Titanium versus Zirconia. *Materials (Basel).* 2015;8(3):932-958.

- Howlett CR, Evans MD, Walsh WR, Johnson G, Steele JG. Mechanism of initial attachment of cells derived from human bone to commonly used prosthetic materials during cell culture. *Biomaterials*. 1994; 15(3):213-222.
- Franchi M, Bacchelli B, Martini D. Early detachment of titanium particles from various different surfaces of endosseous dental implants. *Biomaterials*. 2004 May;25(12):2239-46.
- Bressan E, Ferroni L, Gardin C. Metal Nanoparticles Released from Dental Implant Surfaces: Potential Contribution to Chronic Inflammation and Peri-Implant Bone Loss. *Materials (Basel)*. 2019 Jun 25;12(12):2036.
- Souza JC, Barbosa SL, Ariza EA. How do titanium and Ti6Al4V corrode in fluoridated medium as found in the oral cavity? *Mater Sci Eng C Mater Biol Appl*. 2015 Feb;47:384-93.
- Noronha Oliveira M, Schunemann WVH, Mathew MT. Can degradation products released from dental implants affect peri-implant tissues? *J Periodontol Res*. 2018; 53(1):1-11.
- Dini C, Costa RC, Sukotjo C, Takoudis CG, Mathew MT, Barão VAR. Progression of Bio-Tribocorrosion in Implant Dentistry. *Front Mech Eng*. 2020;6:1
- Broggini N, McManus LM, Hermann JS. Peri-implant inflammation defined by the implant-abutment interface. *J Dent Res*. 2006 May;85(5):473-8.
- Kim KT, Eo MY, Nguyen TTH, Kim SM. General review of titanium toxicity. *J Dent Res*. 2006 May;85(5):473-8.
- Wachi T, Shuto T, Shinohara Y, Matono Y, Makihiro S. Release of titanium ions from an implant surface and their effect on cytokine production related to alveolar bone resorption. *Toxicology*. 2015; 327:1-9.
- Gavić L, Goršeta K, Buterin A, Glavina D, Želježić D, Tadin A. Assessment of Cytotoxic and Genotoxic Effect of Fissure Sealants in Buccal Epithelial Cells. *Acta Stomatol Croat*. 2021 Mar;55(1):10-17.
- Thomas P, Holland N, Bolognesi C. Buccal micronucleus cytome assay. *Nat Protoc*. 2009;4(6):825-37.
- Tolbert PE, Shy CM, Allen JW. Micronuclei and other nuclear anomalies in buccal smears: methods development. *Mutat Res*. 1992;271(1):69-77.
- Karahalil B, Kadioglu E, Tuzuner-Oncul AM, Cimen E, Emerce E, Kisinisci RS. Micronucleus assay assessment of possible genotoxic effects in patients treated with titanium alloy endosseous implants or miniplates. *Mutat Res Genet Toxicol Environ Mutagen*. 2014 Jan 15;760:70-2.
- Broggini N, McManus LM, Hermann JS. Peri-implant inflammation defined by the implant-abutment interface. *J Dent Res*. 2006;85(5):473-478.
- Ribeiro DA, Matsumoto MA, Padovan LE, Marques ME, Salvadori DM. Genotoxicity of corrosion eluates obtained from endosseous implants. *Implant Dent*. 2007;16(1):101-109.
- Ribeiro AR, Gemini-Piperni S, Travassos R. Trojan-Like Internalization of Anatase Titanium Dioxide Nanoparticles by Human Osteoblast Cells. *Sci Rep*. 2016 Mar 29;6:23615.
- Okuda-Shimazaki J, Takaku S, Kanehira K, Sonezaki S, Taniguchi A. Effects of titanium dioxide nanoparticle aggregate size on gene expression. *Int J Mol Sci*. 2010 Jun 7;11(6):2383-92.
- Tavares JC, Cornélio DA, da Silva NB. Effect of titanium surface modified by plasma energy source on genotoxic response in vitro. *Toxicology*. 2009 Aug 3;262(2):138-45.
- Wang JJ, Sanderson BJ, Wang H. Cyto- and genotoxicity of ultra-fine TiO₂ particles in cultured human lymphoblastoid cells. *Mutat Res*. 2007;628(2):99-106.
- Maloney WJ, Smith RL, Castro F, Schurman DJ. Fibroblast response to metallic debris in vitro. Enzyme induction cell proliferation and toxicity. *J Bone Joint Surg Am*. 1993; 75(6):835-844.
- Kumazawa R, Watari F, Takashi N, Tanimura Y, Uo M, Totsuka Y. Effects of Ti ions and particles on neutrophil function and morphology. *Biomaterials*. 2002 Sep;23(17):3757-64.
- Camacho-Alonso F, Sánchez-Siles M, Gilbel-del Águila O. No Evidence of Genotoxic Damage in a Group of Patients with Titanium Dental Implants and Different Metal Restorations in the Oral Cavity. *Clin Implant Dent Relat Res*. 2015;17(4):811-821.
- Allsobrook OF, Leichter J, Holborrow D, Swain M. Descriptive study of the longevity of dental implant surgery drills. *Clin Implant Dent Relat Res*. 2011 Sep;13(3):244-54.
- Carvalho AC, Queiroz TP, Okamoto R, Margonar R, Garcia IR Jr, Magro Filho O. Evaluation of bone heating, immediate bone cell viability, and wear of high-resistance drills after the creation of implant osteotomies in rabbit tibias. *Int J Oral Maxillofac Implants*. 2011 Nov-Dec;26(6):1193-201.
- Harris BH, Kohles SS. Effects of mechanical and thermal fatigue on dental drill performance. *Int J Oral Maxillofac Implants*. 2001 Nov-Dec;16(6):819-26.
- Li J, Chen J, Kirsner R. Pathophysiology of acute wound healing. *Clin Dermatol*. 2007 Jan-Feb;25(1):9-18.
- de Barros Lucena GA, de Molon RS, Moretti AJ, Shibli JA, Rêgo DM. Evaluation of Microbial Contamination in the Inner Surface of Titanium Implants Before Healing Abutment Connection: A Prospective Clinical Trial. *Int J Oral Maxillofac Implants*. 2018; 33(4):853-862.
- Song B, Zhang YL, Chen LJ. The role of Toll-like receptors in periodontitis. *Oral Dis*. 2017 Mar;23(2):168-180.
- Eskan MA, Benakanakere MR, Rose BG. Interleukin-1beta modulates proinflammatory cytokine production in human epithelial cells. *Infect Immun*. 2008 May;76(5):2080-9.
- Sidambe AT. Biocompatibility of Advanced Manufactured Titanium Implants-A Review. *Materials (Basel)*. 2014 Dec 19;7(12):8168-8188.
- Albrektsson T, Zarb G, Worthington P, Eriksson AR. The long-term efficacy of currently used dental implants: a review and proposed criteria of success. *Int J Oral Maxillofac Implants*. 1986 Summer;1(1):11-25.
- Berglund F, Carlmark B. Titanium, sinusitis, and the yellow nail syndrome. *Biol Trace Elem Res*. 2011 Oct;143(1):1-7.