



Mia Smoljan Basuga^{1,2}, Marko Marelić³, Tomislav Badel⁴, Ivana Škrinjar⁵, Božana Lončar Brzak⁵, Antonio Klemenčić², Mirjana Flegarić Bradić², Matea Prenc^{1,2}, Dijana Zadravec^{1,2}

Significance of Calcifications in Projection of Carotid Arteries on Orthopantomography for Detection of Carotid Artery Stenosis

Značaj prikaza vrijednosti kalcifikacija u projekciji karotidnih arterija na ortopantomogramu u otkrivanju stenoze karotidnih arterija

¹ Department of General and Dental Radiology, School of Dental Medicine, University of Zagreb, Zagreb, Croatia
Katedra za opću i dentalnu radiologiju Stomatološkog fakulteta Sveučilišta u Zagrebu, Hrvatska

² Department of Diagnostic and Interventional Radiology, University Hospital Center Sestre milosrdnice, Zagreb, Croatia
Klinički zavod za dijagnostičku i intervencijsku radiologiju KBC-a Sestre milosrdnice, Zagreb, Hrvatska

³ Andrija Štampar School of Public Health, School of Medicine, University of Zagreb, Zagreb, Croatia
Katedra za medicinsku sociologiju i ekonomiku zdravstva Škole narodnoga zdravlja Andrija Štampar – Medicinski fakultet Sveučilišta u Zagrebu, Hrvatska

⁴ Department of Removable Prosthodontics, School of Dental Medicine, University of Zagreb, Zagreb, Croatia
Zavod za mobilnu protetiku Stomatološkog fakulteta Sveučilišta u Zagrebu, Hrvatska

⁵ Department of Oral Medicine, School of Dental Medicine, University of Zagreb, Zagreb, Croatia
Zavod za oralnu medicinu Stomatološkog fakulteta Sveučilišta u Zagrebu, Hrvatska

Abstract

Introduction: Orthopantomography is amongst the most commonly used dental imaging modalities. Calcifications in the projection of carotids on orthopantomographs are found in 3-15% of general population and commonly represent calcified atherosclerotic plaques. Carotid atherosclerotic changes are one of the most frequent causes of stroke, which is the second most common cause of death and the leading cause of disability globally. Our aim was to determine the relationship between calcifications in the projection of carotids on orthopantomographs, carotid stenosis and stroke, and the correlation between stroke risk factors, calcifications on orthopantomographs and the degree of carotid stenosis. **Materials and methods:** Doppler ultrasound and brain MRI were performed in 41 patients with unilateral or bilateral calcifications on orthopantomographs. Anamnestic data relevant to stroke risk were gathered. **Results:** Significant stenosis >50% was found in almost 15% of our patients. There was a significant correlation between hypertension and carotid calcifications. No statistically significant correlation between calcifications and significant stenosis was found. Patients with previous stroke were approximately 5 years older than those without stroke. **Conclusion:** Preliminary results show no statistically significant correlation between calcifications on orthopantomography and significant carotid stenosis, but further investigation is needed.

Received: July 14, 2022

Accepted: August 11, 2022

Address for correspondence

Dijana Zadravec
University of Zagreb
School of Dental Medicine
Department of General and Dental
Radiology
10 000 Zagreb, Croatia
zadravec@sfzg.hr

MeSH Terms: Vascular Calcification;
Carotid Stenosis; Panoramic
Radiography

Author Keywords: Calcifications;
Orthopantomography

Mia Smoljan Basuga: ORCID: <https://orcid.org/0000-0002-5996-423X>

Marko Marelić: ORCID: <https://orcid.org/0000-0003-2596-3359>

Tomislav Badel: ORCID: <https://orcid.org/0000-0001-5872-1132>

Ivana Škrinjar: ORCID: <https://orcid.org/0000-0001-8076-7591>

Božana Lončar Brzak: ORCID: <https://orcid.org/0000-0001-6096-6796>

Antonio Klemenčić: ORCID: <https://orcid.org/0000-0002-8881-445X>

Mirjana Flegarić Bradić: ORCID: <https://orcid.org/0000-0001-9839-704X>

Matea Prenc: ORCID: <https://orcid.org/0000-0002-1240-9626>

Dijana Zadravec: ORCID: <https://orcid.org/0000-0001-5425-328X>

Introduction

Stroke is the second most common cause of death and the leading cause of adult disability worldwide. In 2019, there have been 12.2 million strokes and 6.5 million stroke-related deaths globally (1,2). There are 1.1 million strokes and consequently 440.000 deaths in the European Union annually (3).

Atherosclerotic changes of extracranial arteries, especially carotids, are one of the most common causes of stroke. They are associated with clot formation at the site of a plaque or, more commonly, with the embolization distally, and

Uvod

Moždani udar drugi je najčešći uzrok smrti i vodeći uzrok invalidnosti u odrasloj populaciji u svijetu. U 2019. godinu globalno je bilo 12,2 milijuna moždanih udara i 6,5 milijuna smrti povezanih s moždanim udarom (1, 2). Na godinu u Europskoj uniji od moždanoga udara oboli 1,1 milijun ljudi, a posljedično umre 440 000 (3).

Aterosklerotske promjene ekstrakranijalnih arterija, posebice karotida, jedan su od najčešćih uzroka moždanoga udara. Povezane su sa stvaranjem ugruška na mjestu plaka ili če-

therefore responsible for approximately 50% of all ischemic strokes (4). The most important risk factors for atherosclerosis are age, male sex, hypertension, dyslipidemia, diabetes mellitus, high body mass index (BMI), metabolic syndrome, previous cardiovascular and cerebrovascular diseases, hypercoagulable state, physical inactivity and smoking (5,6). Atherosclerotic changes of carotids are most commonly found at the bifurcation and in the proximal 1-2cm of the internal carotid artery (7,8). The plaques can calcify and thus can be seen radiographically.

Orthopantomography (OPG) is one of the most frequently used X-ray imaging methods in dental medicine. Due to its large field of view, the most susceptible area for carotid atherosclerotic plaques is shown on most OPGs. Calcified plaques are usually seen as one or more nodular, verticolinear or irregular mineral opacities, 1.5cm inferior and 2.5cm posterior to mandibular angle, at the level of C3 and C4 vertebra, unilaterally or bilaterally (8,9). They should radiomorphologically be differentiated from the hyoid bone, styloid process, thyroid cartilage, epiglottis, stylohyoid and stylomandibular ligament calcifications, tonsilloliths, sialoliths, calcified lymph nodes, and especially the triticeal cartilage (8-14). The prevalence of calcifications in the projection of carotids on OPGs ranges from 3-15% in general population (4,8,12,15,16), but it is higher in diabetics, persons with metabolic syndrome (11,17), in physically inactive individuals (18) and smokers (18,19).

Color Doppler ultrasound (CD-US) is considered to be the method of choice for diagnosing carotid artery atherosclerotic changes, and determining their degree of stenosis by numerous authors (4,5,16,19), due to its high sensitivity and specificity (98%, respectively 88% for PSV (*peak systolic velocity*) ≥ 130 cm/s and stenosis $\geq 50\%$, and 90%, respectively 94% for PSV ≥ 200 cm/s and stenosis $\geq 70\%$) (20). It is highly-available and allows for the real-time analysis of vessel morphology, inner plaque structure, blood flow direction and velocity, as well as the estimation of the stenosis degree.

Brain magnetic resonance imaging (MRI) is the dominant imaging modality for brain parenchyma due to its superior contrast resolution for soft tissues, and therefore is a very sensitive method for detecting the signs of brain vessel atherosclerotic disease and stroke.

A number of studies have mentioned the clinical importance of noticing the calcifications in the projection of carotids on orthopantomographs (4,5,11-13,15,20) due to the correlation between the atherosclerotic carotid plaques and stroke (5,6,11,12,21), but the relationship between the calcifications and the significant carotid artery stenosis ($>50\%$) remains indeterminate (4,15,22-24).

In this study we evaluated the correlation between the calcifications in the projection of carotid arteries on OPGs and the carotid stenosis degree on CD-US. Our hypothesis was that the presence of calcifications in the projection of carotids on OPGs indicated a carotid stenosis $>50\%$ on CD-US. We also analyzed the relationship between stroke risk factors, calcifications in the carotid artery projection on OPGs and the degree of carotid stenosis, as well as the frequency of gathered sociodemographic data, habits and previous

šće s distalnom embolizacijom, te su odgovorne za približno 50 % ishemijskih moždanih udara (4). Najvažniji čimbenici rizika za aterosklerozu su dob, muški spol, hipertenzija, dislipidemija, dijabetes melitus, visoki indeks tjelesne mase (BMI), metabolički sindrom, prethodne kardiovaskularne i cerebrovaskularne bolesti, hiperkoagulativna stanja, tjelesna neaktivnost i pušenje (5, 6). Aterosklerotske promjene karotida najčešće se nalaze na bifurkaciji i u proksimalnih 1 do 2 cm unutarne karotidne arterije (7, 8). Plakovi mogu kalcificirati i stoga biti vidljivi na rendgenskim snimkama.

Ortopantomografija jedna je od najčešće korištenih rendgenskih slikovnih metoda u dentalnoj medicini. Područje karotidnih arterija najpodložnije nastanku aterosklerotskih plakova vidi se na većini ortopantomograma zbog velikoga polja snimanja. Kalcificirani plakovi obično se prikazuju kao jedno ili više nodularnih, vertikolonearnih ili nepravilnih mineralnih zasjenjenja 1,5 cm inferiorno i 2,5 cm posteriorno mandibularnome kutu, u razini kralježaka C3 i C4, jednostrano ili obostrano (8, 9). Radiomorfološki potrebno ih je razlikovati od jezične kosti, stiloidnoga nastavka, tireoidne hrskavice, epiglotisa, kalcifikacija stilohipoidnoga i stilomandibularnoga ligamenta, tonsilolita, sijalolita i kalcificiranih limfnih čvorova, a posebno triticealne hrskavice (8 – 14). Prevalencija kalcifikacija u projekciji karotidnih arterija na ortopantomogramima kreće se od 3 do 15 % u općoj populaciji (4, 8, 12, 15, 16), ali je veća u dijabetičara, osoba s metaboličkim sindromom (11, 17), tjelesno neaktivnih osoba (18) i pušača (18, 19).

Obojeni doplerski ultrazvuk (CD-UZV) mnogobrojni autori (4, 5, 16, 19) smatraju metodom izbora za dijagnostiku aterosklerotskih promjena karotidnih arterija i određivanje stupnja stenozе zbog njegove visoke osjetljivosti i specifičnosti (98 %, odnosno 88 % za najvišu sistoličku brzinu – PSV (engl. *peak systolic velocity*) ≥ 130 cm/s i stenozu ≥ 50 %, te 90 %, odnosno 94 % za PSV ≥ 200 cm/s i stenozu ≥ 70 %) (20). To je visoko dostupna metoda koja omogućuje analizu morfologije krvnih žila, unutarnje strukture plaka, smjera i brzine protoka krvi u stvarnom vremenu i određivanje stupnja stenozе arterije.

Magnetska rezonancija (MR) mozga dominantna je slikovna metoda za prikaz moždanoga parenhima zbog visoke kontrastne rezolucije za meka tkiva pa je zato vrlo osjetljiva za prikaz moždanoga udara i znakova aterosklerotskih promjena krvnih žila u mozgu.

U nizu studija autori ističu kliničku važnost uočavanja kalcifikacija u projekciji karotidnih arterija na ortopantomogramima (4, 5, 11 – 13, 15, 20) zbog povezanosti aterosklerotskih plakova karotida i moždanoga udara (5, 6, 11, 12, 21), no korelacija kalcifikacija i značajne stenozе karotidnih arterija ($>50\%$) još je uvijek nedovoljno istražena (4, 15, 22 – 24).

U ovoj studiji ispitivana je povezanost kalcifikacija u projekciji karotidnih arterija na ortopantomogramima i stupnja karotidne stenozе na CD-UZV-u. Postavljena je hipoteza da prisutnost kalcifikacija u projekciji karotidnih arterija na ortopantomogramu upućuje na stenozu karotidnih arterija $> 50\%$ na CD-UZV-u. Analiziran je i odnos čimbenika rizika za moždani udar, kalcifikacija u projekciji karotidnih ar-

cerebrovascular/cardiovascular diseases of the examinees. The prevalence of stroke on brain MRI among the patients with carotid artery calcifications has also been investigated, as well as the difference among the risk factors and the stenosis degree between the patients with the stroke and the patients with no previous stroke.

Material and methods

The study has been conducted at the Department of General and Dental Radiology, School of Dental medicine, University of Zagreb, and at the Department of Diagnostic and Interventional Radiology, University Hospital Center (UHC) Sestre milosrdnice in Zagreb. It has been approved by the Ethics Committee of UHC Sestre milosrdnice in Zagreb, and by the Ethics Committee of School of Dental Medicine, University of Zagreb.

Participants

Examinees in this study were patients with either unilateral or bilateral calcifications in the projection of carotids on the OPGs. All OPGs were previously taken due to dental indications, at the UHC Sestre milosrdnice and at the School of Dental Medicine, University of Zagreb. The patients have all been informed and have consented to participate in the study.

We are showing the preliminary results of this study, gathered on 41 patients.

Procedures

743 digital OPGs in DICOM format, obtained in September and October 2021, have been analyzed by a board-certified radiologist, using the digital orthopantomography software (Scanora). Unilateral or bilateral calcifications in the projection of carotids, radiomorphologically suspicious for atherosclerotic plaques (Figure 1), have been detected in 60 patients (8.07%). 41 patients consented to participate in the study and fulfilled the study inclusion criteria (no contraindications for MRI, 50 year old or older).

CD-US of carotid arteries and the brain MRI have been performed at the Department of Diagnostic and Interventional Radiology, UHC Sestre milosrdnice, Zagreb, Croatia. Carotid CD ultrasound was performed using a GE Healthcare Logiq S8 from 2018, and MRI with a Siemens Aera 1.5T

terija na ortopantomogramima i stupnja karotidne stenozе i učestalost prikupljenih sociodemografskih obilježja, navika i dosadašnjih cerebrovaskularnih/kardiovaskularnih bolesti ispitanika. Također smo željeli odrediti prevalenciju preboljelog moždanoga udara na MR-u mozga bolesnika s kalcifikacijama karotidnih arterija te razliku između čimbenika rizika i stupnja stenozе bolesnika s preboljelim moždanim udarom i onih bez prethodnoga moždanog udara.

Materijal i metode

Istraživanje je provedeno na Katedri za opću i dentalnu radiologiju Stomatološkog fakulteta Sveučilišta u Zagrebu te u Zavodu za dijagnostičku i intervencijsku radiologiju KBC-a Sestre milosrdnice u Zagrebu. Odobrilo ga je Etičko povjerenstvo KBC-a Sestre milosrdnice te Etičko povjerenstvo Stomatološkog fakulteta Sveučilišta u Zagrebu.

Ispitanici

U istraživanje su uključeni pacijenti s jednostranim ili obostranim kalcifikacijama u projekciji karotidnih arterija na ortopantomogramima. Ortopantomogrami su snimljeni zbog stomatoloških indikacija u KBC-u Sestre milosrdnice i na Stomatološkom fakultetu Sveučilišta u Zagrebu. Svi ispitanici pristali su sudjelovati u studiji i potpisali su informirani pristanak.

Prikazani su preliminarni rezultati studije prikupljeni za 41 pacijenta.

Metode

U rujnu i listopadu 2021. snimljena su 743 digitalna ortopantomograma u DICOM formatu koja su pregledali specijalisti kliničke radiologije koristeći se softverom za digitalnu ortopantomografiju (Scanora). Unilateralne ili bilateralne kalcifikacije u projekciji karotidnih arterija, radiomorfološki suspektne za aterosklerotske plakove (slika 1.), otkrivene su kod 60 pacijenata (8,07 %). U istraživanju je pristao sudjelovati 41 pacijent s ispunjenim kriterijima za uključivanje u studiju (bez kontraindikacija za MR, 50 godina ili više).

CD-UZV karotidnih arterija i MR mozga učinjeni su u Zavodu za dijagnostičku i intervencijsku radiologiju KBC-a Sestre milosrdnice, Zagreb, Hrvatska. Ispitanici su pregledani doplerskim ultrazvukom na uređaju GE Healthcare Logiq S8 iz 2018. godine, a MR mozga učinjen je na aparatu Sie-

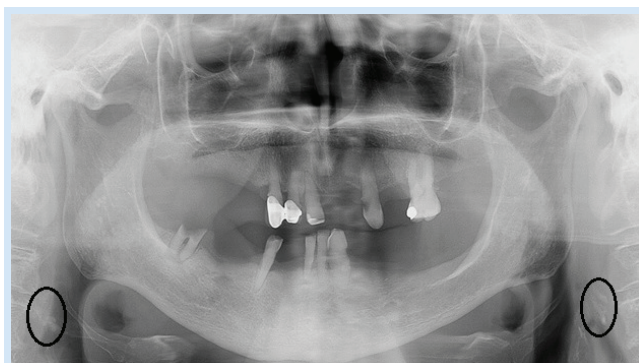


Figure 1 Orthopantomograph showing calcifications in projection of carotids, suggestive of calcified atherosclerotic plaques.

Slika 1. Ortopantomogram pokazuje kalcifikacije u projekciji karotidnih arterija koje upućuju na kalcificirane aterosklerotske plakove

from 2018. The exams were conducted and read by experienced radiologists.

Bilateral common, internal and proximal external carotids have been examined with ultrasound, using a linear, high-frequency probe. Grayscale ultrasound, CD ultrasound and spectral analysis have been performed. The flow velocities and arterial spectres in common carotid artery (CCA), internal carotid artery (ICA) and external carotid artery (ECA) on both sides have been determined, as well as the degree of stenosis. The patients have been divided into two categories – the first group consisted of patients with stenosis <50%, and the second group of those with stenosis >50% (considered clinically significant). The criteria for >50% stenosis were PSV >125cm/s, with the additional criteria being ICA/CCA PSV ratio between 2 and 4 and ICA EDV >40cm/s, based on the Society of Radiologists in Ultrasound (SRU) consensus (25).

Pulsed spin-echo sequences (sagittal T1-weighted images, axial T2-weighted images), inversion recovery sequence FLAIR (*fluid attenuated inversion recovery*), especially sensitive to periventricular and peripheral brain lesions, and the gradient sequence T2*GRE for the detection of hemosiderin deposits, have been used in the brain MRI protocol. Changes in brain morphology and signal intensities concordant with previous lacunar, small, or large territorial brain infarcts were analyzed.

Anamnestic data on age, sex, height and weight, smoking, physical activity and existing hypertension, diabetes mellitus, hyperlipidemia, cardiovascular and cerebrovascular diseases, i.e. examinees' sociodemographic characteristics, functions and previous diseases and treatments relevant for cerebrovascular disease have also been gathered.

Statistical analysis

Variable intercorrelation has been done by point-biserial correlation coefficient for dichotomous variables, and by Phi coefficient for two dichotomous variables. The Fisher and Mann-Whitney U test were conducted for correlation of stenosis degree on CD-US for ACC, ACI and ACE bilaterally and the calcifications on OPGs on both sides. The correlation of age and weight with the stroke has been performed using the Welch t-test, and the correlation between the stroke and the other risk factors has been done using the Fisher test. The statistically significant level was set at $p=0.05$. The statistical analyses were performed using IBM SPSS Statistics 26 software.

Results

Forty-one subjects, among which twenty-eight women (68.3%) and thirteen men (31.7%) participated in the study, with the mean age of 66 years (range 52-80). All of them had calcifications in the projection of carotid arteries on OPGs, either unilaterally (N=20; 48.8%) or bilaterally (N=21; 51.2%).

mens Aera 1.5T iz 2018. godine. Nalaze su očitavali iskusni radiolozi.

Unutarnji i proksimalni dijelovi vanjskih karotidnih arterija obostrano su pregledani ultrazvukom s pomoću linearne visokofrekventne sonde. Obavljeni su pregledi ultrazvukom u sivoj skali, CD-UZV i spektralna analiza. Određene su brzine protoka i arterijski spektri u zajedničkoj karotidnoj arteriji (CCA), unutarnjoj karotidnoj arteriji (ICA) i vanjskoj karotidnoj arteriji (ECA) obostrano te stupnjevi stenozе. Ispitanici su bili podijeljeni u dvije kategorije – prvu skupinu činili su pacijenti sa stenozom < 50 %, a drugu oni sa stenozom > 50 % (smatra se klinički značajnom). Kriteriji za > 50 % stenozu bili su PSV > 25 cm/s, uz dodatne kriterije ICA/CCA PSV omjer između 2 i 4 i ICA EDV > 40 cm/s, na temelju konsenzusa Društva radiologa u ultrazvuku (SRU) (25).

U protokolu za MR mozga korištene su pulsne *spin-echo* sekvence (sagitalne T1-mjerene snimke, aksijalne T2-mjerene snimke), sekvenca FLAIR (*fluid attenuated inversion recovery*) posebno osjetljiva za periventrikularne i periferno smještene lezije mozga i gradijentna sekvenca T2*GRE za otkrivanje hemosiderinskih depozita. Analizirale su se promjene u morfologiji i intenzitetu signala moždanoga parenhima koje radiomorfološki odgovaraju preboljelim lakunarnim, malim ili velikim teritorijalnim infarktima mozga.

Prikupljeni su i anamnestički podatci o dobi, spolu, tjelesnoj masi i visini, pušenju, tjelesnoj aktivnosti, postojećoj hipertenziji, šećernoj bolesti, hiperlipidemiji, kardiovaskularnim i cerebrovaskularnim bolestima, odnosno o sociodemografskim značajkama, funkcijama i navikama te prethodnim bolestima i liječenjima relevantnima za cerebrovaskularne bolesti.

Statistička analiza

Interkorelacija varijabli rađena je pointbiserijalnim koeficijentima korelacije za dihotomne varijable te Phi-koeficijentima asocijacije za dvije dihotomne varijable. Fisherov i Mann-Whitneyjev U test korišteni su za određivanje korelacije stupnja stenozе na CD-UZV-u za ACC, ACI i ACE bilateralno i kalcifikacija na ortopantomogramima s obje strane. Korelacija dobi i tjelesne mase s moždanim udarom provedena je s pomoću Welchova t-testa, a korelacija moždanoga udara i ostalih čimbenika rizika Fisherovim testom. Statistički značajna razina postavljena je na $p = 0,05$. Za statističku analizu korišten je softver IBM-a SPSS Statistics 26.

Rezultati

U istraživanju je sudjelovao četrdeset i jedan ispitanik, od kojih dvadeset i osam žena (68,3 %) i trinaest muškaraca (31,7 %). Prosječna dob bila je 66 godina (raspon godina 52 – 80). Svi sudionici imali su kalcifikacije u projekciji karotidnih arterija na ortopantomogramima jednostrano

Table 1 Number of calcifications in the projection of carotids detected on orthopantomographs, according to side.
Tablica 1. Broj kalcifikata u projekciji karotida na ortopantomogramima, ovisno o strani

Right • Desno		Left • Lijevo		Bilateral • Obostrano	
n	%	n	%	n	%
32	78.0	30	73.2	20	48.8

Table 2 Variable intercorrelations
Tablica 2 Interkorelacije varijabli

	1.	2.	3.	4.	5.	6.	7.	8.	9.	10.	11.	12.	13.	14.	15.	16.	17.	18.	19.
1. Sex (0-F, 1-M) • Spol (0-Ž, 1-M)	1																		
2. Age • Dob	-.047	1																	
3. Weight (kg) • Tjelesna masa (kg)	.474**	-.267	1																
4. BMI	.114	-.239	.874**	1															
5. Hypertension (0-no, 1-yes) • Hipertenzija (0-ne, 1-da)	.361*	.102	.339*	.238	1														
6. Diabetes (0-no, 1-yes) • Dijabetes (0-ne, 1-da)	-.254	-.089	.154	.283	.314*	1													
7. Hyperlipidemia (0-no, 1-yes) • Hipertipidemija (0-ne, 1-da)	-.462**	.048	-.015	.201	.183	.283	1												
8. Cardiovascular diseases (0-no, 1-yes) • Kardiovaskularne bolesti (0-ne, 1-da)	-.176	.443**	-.252	-.102	.174	.111	.346*	1											
9. Cerebrovascular diseases (0-no, 1-yes) • Cerebrovaskularne bolesti (0-ne, 1-da)	.022	.066	-.13	-.13	-.111	-.076	.043	-.027	1										
10. Smoking (0-no, 1-yes) • Pušenje (0-ne, 1-da)	-.003	-.276	.247	.303	.087	.102	-.208	-.011	.047	1									
11. Physical activity (0-no, 1-yes) • Tjelesna aktivnost (0-ne, 1-da)	.203	.062	-.031	-.078	-.04	-.005	.009	-.119	.181	-.16	1								
12. CD-US stenosis ACC dex • CD-UZV stenozna ACC dex ^a	b	b	b	b	b	b	b	b	b	b	b	1							
13. CD-US stenosis ACE dex • CD-UZV stenozna ACE dex ^a	-.154	.097	.127	.173	-.039	.262	.172	-.137	.352*	.017	.111	b	1						
14. CD-US stenosis ACI dex • CD-UZV stenozna ACI dex ^a	.089	-.154	.112	.097	-.039	.262	-.063	-.137	.352*	.244	.111	b	.474**	1					
15. CD-US stenosis ACC sin • CD-UZV stenozna ACC sin ^a	b	b	b	b	b	b	b	b	b	b	b	b	b	b	1				
16. CD-US stenosis ACE sin • CD-UZV stenozna ACE sin ^a	.01	-.094	.12	.121	-.144	.182	.019	-.17	.437**	.115	.138	b	.806**	.806**	b	1			
17. CD-US stenosis ACI sin • CD-UZV stenozna ACI sin ^a	.066	-.011	.031	-.008	.011	.089	-.026	.111	.252	.252	-.005	b	.262	.608**	b	.468**	1		
18. Calcification on OPG on the right (0-no, 1-yes) • Kalcifikati na ortopantomogramu desno (0-ne, 1-da)	-.145	.108	-.066	-.008	.271	.018	.209	.055	-.047	.138	-.112	b	.12	-.153	b	-.077	-.163	1	
19. Calcification on OPG on the left (0-no, 1-yes) • Kalcifikati na ortopantomogramu lijevo (0-ne, 1-da)	.294	-.213	.263	.115	.384*	.226	-.003	.118	.027	.011	-.159	b	-.118	.137	b	-.041	.226	-.321*	1
20. Stroke on MRI (0-no, 1-yes) • Ishemija na MR-u (0-ne, 1-da)	.163	.232	-.015	-.145	.208	.057	-.115	.061	.492**	.307	-.144	b	.227	.227	b	.149	.267	.053	.251

For dichotomous variables point-biserial correlation coefficients are shown for quantitative variables, and Phi-coefficients of association for two dichotomous variables. • Za dichotomne varijable koeficijenti point-biserialne korelacije prikazani su za kvantitativne varijable, a Phi- koeficijenti asocijacije za dvije dichotomne varijable.

* p<0,05; ** p<0,01

^a(<50%=1, >50%=2)

^bNot possible to calculate the correlation because the variable is constant (it has only one value) • Nije moguće izračunati korelaciju jer je varijabla konstantna (ima samo jednu vrijednost)

Calcifications were seen on the right side in 32 patients (78%), and on the left side in 30 patients (73.2%) (Table 1). There was no statistically relevant correlation between the calcifications on either side and the risk factors for stroke, except for the hypertension and the calcifications on the left side ($p < 0.05$). Negative correlation has been found between the calcifications on the left and on the right side ($p < 0.05$) (Table 2).

Stenosis of $>50\%$ on CD-US was found in 6 patients (14.63%), overall in 12 arteries. All other patients had stenosis of $<50\%$ seen on CD-US (Table 3). No statistically relevant correlation between the significant stenosis on CD-US and the calcification on the OPG was found.

We have collected our subjects' sociodemographic and anamnestic data relevant to stroke risk. Hyperlipidemia was found in almost two-thirds (63.4%) of our examinees, hypertension was present in more than half (58.5%), diabetes in 12.2%, cardiovascular diseases were found in 26.8%, and cerebrovascular diseases in 29.3% of our patients. Nineteen (46.3%) patients were smokers, with another 12.2% being former smokers, and 33 (80.5%) were physically active (Table 4). Statistically significant intercorrelations were found between the male sex and weight ($p < 0.01$), as well as with male sex and hypertension ($p < 0.05$), between female

($N = 20$; 48,8 %) ili obostrano ($N = 21$; 51,2 %). Kalcifikacije su uočene desno kod 32 bolesnika (78 %), a lijevo kod njih 30 (73,2 %) (tablica 1.). Nije bilo statistički značajne korelacije između kalcifikacija na bilo kojoj strani i čimbenika rizika za moždani udar, osim za hipertenziju i kalcifikacije na lijevoj strani ($p < 0,05$). Utvrđena je negativna korelacija između kalcifikacija na lijevoj i desnoj strani ($p < 0,05$) (tablica 2.).

Stenoza $>50\%$ na CD-UZV-u pronađena je kod 6 pacijenata (14,63 %), ukupno u 12 arterija. Svi ostali imali su stenozu $<50\%$ na CD-UZV-u (tablica 3.). Nije pronađena statistički relevantna korelacija između signifikantne stenoze na CD-UZV-u i kalcifikacija na ortopantomogramima.

Prikupljeni su sociodemografski i anamnestički podatci ispitanika relevantni za rizik od moždanoga udara. Hiperlipidemiju je imalo gotovo dvije trećine (63,4 %) pacijenata, hipertenziju više od polovine (58,5 %), dijabetes 12,2 %, kardiovaskularne bolesti 26,8 %, a cerebrovaskularne bolesti njih 29,3 %. Devetnaest (46,3%) ispitanika puši, još 12,2 % bivši su pušači, a 33 (80,5 %) tjelesno su aktivni (tablica 4.). Utvrđene su statistički značajne interkorelacije između muškoga spola i tjelesne težine ($p < 0,01$), muškoga spola i hipertenzije ($p < 0,05$), ženskoga spola i hiperlipidemije ($p < 0,01$),

Table 3 Number of patients with $<50\%$ and $>50\%$ stenosis on Color Doppler ultrasound (CD-US) for each artery

Tablica 3. Broj pacijenata sa stenozom $<50\%$ i $>50\%$ na obojnom doplerskom ultrazvuku (CD-UZV) za svaku arteriju

CD-US stenosis • CD-UZV stenoza	ACC dex		ACE dex		ACI dex		ACC sin		ACE sin		ACI sin	
	n	%	n	%	n	%	n	%	n	%	n	%
$<50\%$	41	100	39	95.1	39	95.1	41	100	38	92.7	36	87.8
$>50\%$	0	0	2	4.9	2	4.9	0	0	3	7.3	5	12.2

Table 4 Stroke risk factors distribution

Tablica 4. Distribucija čimbenika rizika za moždani udar

Hypertension • Hipertenzija		Diabetes • Dijabetes		Hyperlipidemia • Hiperlipidemija		Cardiovasc. diseases • Kardiovask. bolesti		Cerebrovasc. diseases • Cerebrovask. bolesti		Smoking • Pušenje		Physical activity • Tjelesna aktivnost	
n	%	n	%	n	%	n	%	n	%	n	%	n	%
24	58.5	5	12.2	26	63.4	11	26.8	12	29.3	19	46.3	33	80.5

Table 5 Stroke correlation with age

Tablica 5. Korelacija moždanoga udara s dobi

	Stroke on MRI • Ishemija na MR-u		Average age • Prosječna dob	t; df; p
	n	%		
No • Ne	35	85.4	65.49	-2.476, 15.117; ,026 ^a
Yes • Da	6	14.6	70.50	

* $p < 0.05$; ** $p < 0.01$

^a Welch test • Welchov test

Table 6 Correlation between stroke and cerebrovascular disease

Tablica 6. Korelacija moždanoga udara i cerebrovaskularnih bolesti

Stroke on MR • Moždani udar na MR-u	Cerebrovascular diseases • Cerebrovaskularna bolest				Fisher test • Fisherov test
	No • Ne		Yes • Da		
	n	%	n	%	
No • Ne	28	80	7	20	,005**
Yes • Da	1	16.7	5	83.3	

* $p < 0.05$; ** $p < 0.01$

sex and hyperlipidemia ($p < 0.01$), and also between the hypertension and weight ($p < 0.05$) and hypertension and diabetes ($p < 0.05$), and between the cardiovascular diseases and the age ($p < 0.01$) and cardiovascular diseases and hyperlipidemia ($p < 0.05$) (Table 2).

Six patients had signs of previous stroke on brain MRI (14.6%). Two patients had territorial infarcts and four patients had small cortical or lacunar infarcts in basal ganglia and brainstem. Their mean age was five years higher than of those without the previous stroke ($p < 0.05$) (Table 5). There was a positive correlation with cerebrovascular diseases in these patients ($p < 0.01$) (Table 6). No statistically significant difference in weight, hypertension, diabetes, hyperlipidemia, cardiovascular diseases, smoking or physical activities has been found between the examinees with or without stroke.

Discussion

The prevalence of calcifications with radiomorphologic characteristics suggestive of calcified atherosclerotic plaques on OPGs in our study was 8.07%. Previously reported prevalence in the general population has been 3-15% (4,8,12,15,16,26), which is in concordance with our finding.

We had a larger number of women with calcifications in the projection of carotid arteries in our study (68.3%) compared to men (31.7%). In their review article, Alves et al. confirm this finding (9), as well as Gonçalves et al. who also had a higher percentage of female patients with calcifications (26). In our study, the number of bilateral and unilateral calcifications was almost equal, with a slight advantage in favor of unilateral findings (51.2%) and with no strong predilection for right or left side. We also found a negative correlation between the calcifications on the left and the right side ($p < 0.05$), which means that patients with a calcification on one side are less likely to have another calcification on the other side. These findings agree with those of Alves et al. who reported that calcifications are usually unilateral, but that there is no predilection for either side (9).

Our subjects' sociodemographic and anamnestic data relevant to stroke risk have been collected and correlated with the calcifications on OPGs. Hypertension, diabetes and smoking have shown positive correlations with calcifications, and physical activity showed negative correlation with calcifications, but the only statistically significant correlation was with hypertension ($p < 0.05$), which was present in 58.5% of our examinees. Abecasis et al. had a hypertension prevalence of almost 62% in their study, and their results showed that patients with hypertension have more than 5 times greater probability to develop atheromatous plaques (27). A significant correlation between the number of years of smoking and carotid plaques has been mentioned by Abecasis et al. and Kumagai et al. in their previous studies (27,28), as well as the association of calcifications and diabetes by Friedlander et al. and Johansson et al. (11,24). Regular physical activity is a protective factor for vascular diseases (29), and activity is inversely associated with carotid plaque formation, especially in patients with increased vascular risk (30,31). However, the literature on correlation between calcified carotid plaques on

između hipertenzije i tjelesne težine ($p < 0,05$), hipertenzije i dijabetesa ($p < 0,05$), između kardiovaskularnih bolesti i dobi ($p < 0,01$) te kardiovaskularnih bolesti i hiperlipidemije ($p < 0,05$) (tablica 2.).

Šest pacijenata imalo je znakove preboljeloga moždanoga udara na MR-u mozga (14,6 %). Dva su imala teritorijalne infarkte, a četiri kortikalne ili lakunarne infarkte u bazalnim ganglijima i moždanome deblu. Prosječna dob tih ispitanika bila je pet godina viša od onih bez prethodnoga moždanoga udara ($p < 0,05$) (tablica 5.), uz pozitivnu korelaciju s cerebrovaskularnim bolestima ($p < 0,01$) (tablica 6.). Nije utvrđena statistički značajna razlika u tjelesnoj težini, hipertenziji, dijabetesu, hiperlipidemiji, kardiovaskularnim bolestima, pušenju ili tjelesnim aktivnostima između ispitanika s moždanim udarom i bez moždanoga udara.

Rasprava

Prevalencija kalcifikacija radiomorfoloških karakteristika kalcificiranih aterosklerotskih plakova na ortopantomogramima u našem istraživanju bila je 8,07 %. U dosad objavljenim radovima autori navode prevalenciju u općoj populaciji od 3 do 15 % (4, 8, 12, 15, 16, 26), što je u skladu s našim nalazom.

U našem istraživanju bio je veći broj žena s kalcifikacijama u projekciji karotidnih arterija (68,3 %) u odnosu prema muškarcima (31,7 %). U svojem preglednom članku Alves i suradnici potvrđuju taj nalaz (9), kao i Gonçalves i suradnici koji su također imali veći postotak pacijentica s kalcifikacijama (26). Broj pacijenata s bilateralnim i unilateralnim kalcifikacijama bio je gotovo jednak u ovom istraživanju, s blagom prednošću u korist jednostranoga nalaza (51,2 %) i bez izražene predilekcije desne ili lijeve strane. Također je pronađena negativna korelacija između kalcifikacija na lijevoj i desnoj strani ($p < 0,05$), što znači da pacijenti s kalcifikacijama na jednoj strani imaju manju vjerojatnost kalcifikacija na drugoj strani. Ti se nalazi slažu s onima Alvesa i suradnika koji su izvijestili da su kalcifikacije obično jednostrane i bez sklonosti za ijednu stranu (9).

Sociodemografski i anamnestički podatci ispitanika relevantni za rizik od moždanoga udara prikupljeni su i korelirani s kalcifikacijama na ortopantomogramima. Hipertenzija, šećerna bolest i pušenje pokazali su pozitivnu korelaciju s kalcifikacijama, a tjelesna aktivnost negativnu, no jedina statistički značajna korelacija bila je s povišenim krvnim tlakom ($p < 0,05$) od čega je patilo 58,5 % ispitanika. U studiji dr. Abecasis i suradnika prevalencija hipertenzije bila je gotovo 62 %, a njihovi rezultati pokazali su da pacijenti s hipertenzijom imaju više od 5 puta veću vjerojatnost za pojavu ateromatoznih plakova (27). Značajnu korelaciju između broja godina pušenja i karotidnih plakova naveli su u svojim studijama Abecasis i suradnici te Kumagai i suradnici (27, 28), a Friedlander i suradnici te Johansson i suradnici istaknuli su povezanost kalcifikacija i dijabetesa (11, 24). Redovita tjelesna aktivnost zaštitni je čimbenik za vaskularne bolesti (29) te je obrnuto proporcionalna stvaranju karotidnoga plaka, osobito ako je pacijent u povećanom vaskularnom riziku (30, 31). Ipak, nema mnogo radova o korelaciji kalcificiranih karotidnih pla-

OPGs and physical activity seems to be scarce. The study of Helmi et al. showed a positive correlation between the plaque formation and irregular exercise, but with no statistical significance (32).

In this study, clinically significant stenosis of >50% on CD-US was found in 6 patients (14.63%), in 12 arteries respectively. Constantine et al. obtained similar results with 15.4% patients with calcifications having a carotid stenosis of over 50%, and showing a threefold higher risk of significant stenosis compared to those without calcifications (33). Several studies have shown higher percentage of significant carotid stenosis. Friedlander et al. have found >50% carotid stenosis on CD-US in 23% asymptomatic patients with calcified carotid plaques (15), and Almog et al. in 50% of sonographically examined arteries in their study (4). On the other hand, Johansson and al. found a significant stenosis in only 7% of the patients with positive OPG calcifications (24). Studies that performed the OPGs after the significant carotid stenosis had already been proven and before the carotid endarterectomy was been carried out showed high percentages of visible calcifications on OPGs. Griantsos et al. had positive calcification findings on 70% orthopantomographs of such patients (22) and Garoff et al. in 84% of examinees (23).

Our study showed no statistically relevant correlation between the significant stenosis on CD-US and the calcifications on the OPG. These results are coherent with the study of Johansson et al. (24) and Constantine et al. (33), but in disagreement with the results of Almog et al. (4) and Abecais et al. (27). For instance, the latter study found fifteen times greater risk of stenosis >70% on CD-US in the group of patients with calcified plaques (27).

The connection between stroke and calcified carotid artery calcifications seen on OPGs has been discussed by several authors (12,22,27,33,35-37). In a retrospective study, Cohen et al. have shown that 34% of the patients with calcifications in the projection of carotids on orthopantomographs have subsequently developed a myocardial infarction or stroke in the period of 3.5 years (12). Friedlander et al. have claimed that individuals with calcified carotid atheromas have a higher risk of experiencing similar major vascular events in the future (37). In our sample, nearly 15% of patients have had a stroke. Cerebrovascular disease and older age are known risk factors for stroke (3,34), which was confirmed by our results. There was a significant correlation ($p < 0.01$) between existing cerebrovascular disease and stroke, and our patients with stroke were approximately 5 years older than those with no previous stroke ($p < 0.05$).

The study findings are preliminary, based on the first 41 patients participating in a larger, ongoing study. More comprehensive evaluation with a larger sample is needed to investigate the significance of calcified carotid plaques on OPGs for detection of carotid artery stenosis in general population, and to determine their correlation with stroke.

kova na ortopantomogramima i tjelesne aktivnosti. Studija Helmija i suradnika pokazala je pozitivnu korelaciju između stvaranja plaka i neredovite tjelovježbe, no bez statističke značajnosti (32).

U ovom istraživanju klinički je značajna stenoza od > 50 % na CD-UZV-u pronađena kod 6 pacijenata (14,63 %), odnosno u 12 arterija. Constantine i suradnici dobili su slične rezultate, s 15,4 % pacijenata s kalcifikacijama koji su imali karotidnu stenožu veću od 50 % i pokazivali trostruko veći rizik za signifikantnu stenožu u usporedbi s onima bez kalcifikacija (33). Nekoliko istraživača objavilo je više postotke pacijenata sa značajnom karotidnom stenozom u svojim uzorcima. Friedlander i suradnici imali su karotidne stenozе >50 % na CD-UZV-u za 23 % asimptomatskih pacijenata s kalcificiranim karotidnim plakovima (15), a Almog i suradnici u 50 % sonografski pregledanih arterija (4). S druge strane, Johansson i suradnici pronašli su značajnu stenožu samo kod 7 % pacijenata s pozitivnim kalcifikacijama na ortopantomogramu (24). U studijama u kojima su se ortopantomogramima snimali ako je pacijentu bila dokazana značajna karotidna stenoza i prije karotidne endarterektomije, postotci vidljivih kalcifikacija na ortopantomogramima bili su visoki. Griantsos i suradnici imali su pozitivne nalaze kalcifikacija na 70 % ortopantomograma (22), a Garoff i suradnici kod 84 % ispitanika (23).

Naše istraživanje nije pokazalo statistički značajnu korelaciju signifikantne stenozе na CD-UZV-u i kalcifikacija na ortopantomogramima. Ti su rezultati koherentni sa studijom Johanssona i suradnika (24) i Constantinea i suradnika (33), no u suprotnosti su s rezultatima Almoga i suradnika (4) i Abecais i suradnika (26). Primjerice, u posljednjoj spomenutoj studiji istaknut je petnaest puta veći rizik za karotidnu stenožu >70 % na CD-UZV-u u skupini pacijenata s kalcificiranim plakovima (27).

O povezanosti moždanoga udara i kalcifikacija karotidnih arterija vidljivih na ortopantomogramima raspravljalo je više autora (12, 22, 27, 33, 35 – 37). U retrospektivnoj studiji su Cohen i suradnici pokazali da je 34 % pacijenata s kalcifikacijama u projekciji karotidnih arterija na ortopantomogramima razvilo infarkt miokarda ili moždani udar u razdoblju od 3,5 godine nakon snimanja (12). Friedlander i suradnici navode da osobe s kalcificiranim karotidnim ateromima imaju u budućnosti veći rizik od ozbiljnijih vaskularnih događaja (37). U našem uzorku gotovo 15 % pacijenata imalo je moždani udar. Cerebrovaskularna bolest i starija dob poznati su čimbenici rizika za moždani udar (3, 34), što potvrđuju i naši rezultati. Postojala je značajna korelacija ($p < 0,01$) između postojeće cerebrovaskularne bolesti i moždanoga udara, a ispitanici s moždanim udarom bili su prosječno 5 godina stariji od onih bez prethodnoga moždanoga udara ($p < 0,05$).

Rezultati istraživanja su preliminarni, dobiveni su od prvih ispitanika – od četrdeset i jednoga iz veće studije koja je u tijeku. Potrebna je sveobuhvatnija analiza s većim uzorkom da bi se detaljnije istražilo značenje kalcificiranih karotidnih plakova na ortopantomogramima za otkrivanje stenozе karotidne arterije u općoj populaciji i njihova korelacija s moždanim udarom.

Conclusion

Our study aimed to determine a correlation between the calcifications in the projection of carotids on OPGs and the carotid stenosis on CD-US and to analyze the relationship between stroke risk factors, calcifications in the projection of carotids on OPGs and the degree of carotid stenosis. Significant stenosis of over 50% was found in almost 15% of our patients, but no statistically significant correlation between calcifications on OPGs and significant stenosis on CD-US was found. Therefore, our hypothesis has not been confirmed by our preliminary results. Positive correlations with calcifications were shown for hypertension, diabetes and smoking, and negative correlation for physical activity, although the only statistically significant correlation was with hypertension. Nearly 15% of our examinees have had a stroke, and they were approximately 5 years older than those with no previous stroke. Further investigation and a larger sample is needed to determine the importance of calcifications in the projection of carotids on OPGs and their relationship with the significant stenosis and stroke.

Conflict of interest

Authors declare no conflicts of interest.

Author contribution: M.S.B. - data collection and analysis, analysis of MR images, figure and table preparation, writing of Abstract, Introduction, Materials and Methods, Results, Discussion, Conclusion and References, literature search; M.M. - statistical analysis, table preparation, writing of Material and Methods; T.B. - consultations on study design, writing, data analysis help in data collection; I.Š. - data collection and analysis, consultations on study writing; B.L.B. - help in data collection and analysis; A.K. - CD-US examinations and image analysis, data collection and analysis, literature search; M.F.B. - CD-US examinations and image analysis, data collection, literature search; M.P. - data collection and analysis, figure and table preparation, literature search; D.Z. - hypothesis setting, study design, data analysis, analysis of MR images, writing of Results, Discussion and Literature

Zaključak

Cilj našeg istraživanja bio je odrediti povezanost kalcifikacija u projekciji karotidnih arterija na ortopantomogramima i karotidne stenozе na CD-UZV-u te analizirati odnos između čimbenika rizika za moždani udar, kalcifikata u projekciji karotidnih arterija na ortopantomogramima i stupnja karotidne stenozе. Signifikantna stenozа veća od 50 % pronađena je kod gotovo 15 % ispitanika, no statistički značajna korelacija kalcifikacija na ortopantomogramima i signifikantne stenozе na CD-UZV-u nije pronađena. Naši preliminarni rezultati nisu potvrdili hipotezu. Pozitivna korelacija s kalcifikacijama postojala je za hipertenziju, dijabetes i pušenje, a negativna za tjelesnu aktivnost, iako je jedina statistički značajna korelacija bila s hipertenzijom. Gotovo 15 % naših ispitanika imalo je moždani udar, a bili su prosječno 5 godina stariji od onih koji ga nisu imali. Potrebno je daljnje istraživanje i veći uzorak da bi se utvrdila važnost kalcifikacija u projekciji karotidnih arterija na ortopantomogramima i njihov odnos sa signifikantnom stenozom karotidne arterije i moždanim udarom.

Sukob interesa

Autori nisu bili u sukobu interesa.

Doprinos autora: M. S. B. – prikupljanje i analiza podataka, analiza MR snimki, priprema slika i tablica, pisanje sažetka, uvoda, materijala i metoda, rezultata, rasprave, zaključka i literature, pretraživanje literature; M. M. – statistička analiza, priprema tablica, pisanje materijala i metoda; T. B. – konzultacija o izradi i pisanju studije, pomoć u prikupljanju i analizi podataka; I. Š. – prikupljanje i analiza podataka, konzultacija o pisanju rada; B. L. B. – pomoć u prikupljanju i analizi podataka; A. K. – CD-UZV pregled i analiza snimki, prikupljanje i analiza podataka, pregled literature; M. F. B. – CD-UZV pregled i analiza snimki, prikupljanje i analiza podataka, pregled literature; M. P. – prikupljanje i analiza podataka, izrada slika i tablica, pretraživanje literature; D. Z. – postavljanje hipoteze, dizajn studije, analiza podataka i MR snimki, pisanje rezultata, rasprave i zaključka

Sažetak

Uvod: Ortopantomografija jedna je od najčešće korištenih slikovnih metoda u dentalnoj medicini. Kalcifikacije u projekciji karotidnih arterija na ortopantomogramima nalaze se kod 3 do 15 % opće populacije i diferencijalnodijagnostički su kalcificirani aterosklerotski plakovi. Aterosklerotske promjene karotidnih arterija među najčešćim su uzrocima moždanoga udara pa je ta bolest diljem svijeta drugi najčešći uzrok smrti i vodeći uzrok invalidnosti. Cilj ovoga rada bio je utvrditi odnos između kalcifikacija u projekciji karotidnih arterija na ortopantomogramima, zatim između karotidne stenozе i moždanoga udara te korelaciju između čimbenika rizika za moždani udar, kalcifikacija na ortopantomogramima i stupnja karotidne stenozе. **Materijal i metode:** Doplerski ultrazvuk karotidnih arterija i MR mozga učinjeni su četrdeset i jednomu pacijentu s jednostranim ili obostranim kalcifikacijama na ortopantomogramima. Prikupljeni su anamnestički podatci o rizičnim čimbenicima za moždani udar. **Rezultati:** Signifikantna stenozа > 50 % nađena je kod gotovo 15 % pacijenata. Uočena je značajna korelacija između hipertenzije i karotidnih kalcifikacija. Između kalcifikacija i signifikantne stenozе nije pronađena statistički značajna korelacija. Pacijenti s prethodnim moždanim udarom bili su prosječno 5 godina stariji od onih koji nisu doživjeli taj moždanožilni incident. **Zaključak:** Preliminarni rezultati nisu pokazali statistički značajnu korelaciju između kalcifikacija na ortopantomogramima i signifikantne stenozе karotidnih arterija, no potrebna su daljnja istraživanja.

Zaprimljen: 14. srpnja 2022.

Prihvaćen: 11. kolovoza 2022.

Adresa za dopisivanje

Dijana Zdravec
Sveučilište u Zagrebu
Stomatološki fakultet
Katedra za opću i dentalnu radiologiju
10 000 Zagreb, Hrvatska
e-adresa: zdravec@sfzg.hr

MeSH pojmovi: kalcifikacija krvnih žila; stenozа karotidnih arterija; panoramska radiografija
Autorske ključne riječi: kalcifikacije; ortopantomografija

References

1. GBD 2019 Stroke Collaborators. Global, regional, and national burden of stroke 1990–2019: a systematic analysis for the Global Burden of Disease Study 2019. *Lancet Neurol.* 2021;20(10):795-820.
2. GBD 2016 Stroke Collaborators. Global, regional, and national burden of stroke 1990–2016: a systematic analysis for the Global Burden of Disease Study 2016. *Lancet Neurol.* 2019;18(5):439-458.
3. Wafa HA, Wolfe CDA, Emmett E, Roth GA, Johnson CO, Wang Y. Burden of Stroke in Europe Thirty-Year Projections of Incidence, Prevalence, Deaths, and Disability-Adjusted Life Years. *Stroke.* 2020 Aug;51(8):2418-2427.
4. Almog DM, Horev T, Illig KA, Green RM, Carter. Correlating LC. Carotid artery stenosis detected by panoramic radiography with clinically relevant carotid artery stenosis determined by duplex

- ultrasound. *Oral Surg Oral Med Oral Pathol Oral Radiol Endod.* 2002 Dec;94(6):768-73.
5. Guimaraes Henriques JC, Kreich EM, Baldani MH, Luciano M, Cezar de Melo Castilho J, de Moraes LC. Panoramic Radiography in the diagnosis of carotid artery atheromas and the associated risk factors. *Open Dent J.* 2011;5:79-83.
 6. Dossabhoy S, Arya S. Epidemiology of atherosclerotic carotid artery disease. *Semin Vasc Surg.* 2021 Mar;34(1):3-9.
 7. Bentzon JF, Otsuka F, Virmani R, Falk E. Mechanisms of plaque formation and rupture. *Circ Res.* 2014 Jun 6;114(12):1852-66.
 8. Garoff M, Ahlqvist J, Jaghagen EL, Johansson E, Wester P. Carotid calcification in panoramic radiographs: radiographic appearance and the degree of carotid stenosis. *Dentomaxillofac Radiol.* 2016; 45.
 9. Alves N, Deana NF, Garay I. Detection of common carotid artery calcifications on panoramic radiographs: prevalence and reliability. *Int J Clin Exp Med.* 2014 Aug 15;7(8):1931-9.
 10. Friedlander AH, Liebeskind DS, Tran HQ, Mallya SM. What are the potential implications of identifying intracranial internal carotid artery atherosclerotic lesions on cone-beam computed tomographs? A systematic review and illustrative case studies. *J Oral Maxillofac Surg.* 2014 Nov;72(11):2167-77. Friedlander AH, Maeder LA.
 11. The prevalence of calcified carotid artery atheromas on the panoramic radiographs of patients with type 2 diabetes mellitus. *Oral Surg Oral Med Oral Pathol Oral Radiol Endod.* 2000 Apr;89(4):420-4.
 12. Cohen SN, Friedlander AH, Jolly DA, Date L. Carotid calcification on panoramic radiographs: An important marker for vascular risk. *Oral Surg Oral Med Oral Pathol Oral Radiol Endod.* 2002 Oct;94(4):510-4.
 13. Carter LC. Discrimination between calcified triticeous cartilage and calcified carotid atheroma on panoramic radiography. *Oral Surg Oral Med Oral Pathol Oral Radiol Endod.* 2000 Jul;90(1):108-10.
 14. Alkhabuli J, Zakaria H, Muayad A. Prevalence of Stylohyoid Complex Elongation among Patients Attending RAK College of Dental Sciences Clinic. *Acta Stomatol Croat.* 2020 Mar;54(1):60-68.
 15. Friedlander AH, Garret NR, Chin EE, Baker JD. Ultrasonographic confirmation of carotid artery atheromas diagnosed via panoramic radiography. *J Am Dent Assoc.* 2005 May;136(5):635-40; quiz 682-3.
 16. Constantine S, Roach D, Liberali S, Kiermeier A, Sarkar P, Jannes J, Sambrook P, Anderson P, Beltrame J. Carotid Artery Calcification on Orthopantomograms (CACO Study) - is it indicative of carotid stenosis? *Aust Dent J.* 2019 Mar;64(1):4-10.
 17. Pornprasertsuk-Damrongsri S, Virazavanich W, Thanakun S, Siriwongpairat P, Amaekchock P, Khovidhunkit W. The prevalence of carotid artery calcifications detected on panoramic radiographs in patients with metabolic syndrome. *Oral Surg Oral Med Oral Pathol Oral Radiol Endod.* 2009;108:57-62.
 18. Veiga Abecasis P, Chimenos-Küstner E. Can Orthopantomography be used as a tool for screening of carotid atheromatous pathology and thus be used to help reduce the prevalence of ischemic stroke within the population? *J Clin Exp Dent.* 2012 Feb 1;4(1):e19-22.
 19. Barona-Dorado C, Gutierrez-Bonet C, Leco-Berrocal I, Fernández-Cáiz F, Martínez-González JM. Relation between diagnosis of atheromatous plaque from orthopantomographs and cardiovascular risk factors. A study of cases and control subjects. *Med Oral Patol Oral Cir Bucal.* 2016 Jan 1;21(1):e66-71.
 20. Jahromi AS, Cinà CS, Liu Y, Clase CM. Sensitivity and specificity of color duplex ultrasound measurement in the estimation of internal carotid artery stenosis: a systematic review and meta-analysis. *J Vasc Surg.* 2005;41(6):962-72.
 21. Christou P, Leemann B, Schimmel M, Kiliaridis S, Müller F. Carotid artery calcification in ischemic stroke patients detected in standard dental panoramic radiographs – a preliminary study. *Adv Med Sci.* 2010;55(1):26-31.
 22. Griniatsos J, Damaskos S, Tsekouras N, Klonaris C, Georgopoulos S. Correlation of calcified carotid plaques detected by panoramic radiograph with risk factors for stroke development. *Oral Surg Oral Med Oral Pathol Oral Radiol Endod.* 2009 Oct;108(4):600-3.
 23. Garoff M, Johansson E, Ahlqvist J, Jaghagen EL, Arnerlöv C, Wester P. Detection of calcifications in panoramic radiographs in patients with carotid stenoses $\geq 50\%$. *Oral Surg Oral Med Oral Pathol Oral Radiol.* 2014 Mar;117(3):385-91.
 24. Johansson EO, Ahlqvist J, Garoff M, Karp K, Levring Jaghagen E, Wester P. Ultrasound screening for asymptomatic carotid stenosis in subjects with calcifications in the area or the carotid arteries on panoramic radiographs: a cross-sectional study. *BMC Cardiovasc Disor.* 2011;11:44.
 25. Grant EG, Benson CB, Moneta GL, Alexandrov AV, Baker JD, Bluth EI, Carroll BA, Eliasziw M, Gocke J, Hertzberg BS, Katanick S, Needleman L, Pellerito J, Polak JF, Rholl KS, Wooster DL, Zierler RE. Carotid artery stenosis: gray-scale and Doppler US diagnosis—Society of Radiologists in Ultrasound Consensus Conference. *Radiology.* 2003 Nov; 229(2):340-6.
 26. Gonçalves JR, Yamada JL, Berrocal C, Westphalen FH, Franco A, Fernandes Â. Prevalence of Pathologic Findings in Panoramic Radiographs: Calcified Carotid Artery Atheroma. *Acta Stomatol Croat.* 2016 Sep; 50(3):230-234.
 27. Abecasis P, Chimenos-Küstner E, López-López O. Orthopantomography contribution to prevent isquemic stroke. *J Clin Exp Dent.* 2014 Apr 1;6(2):e127-31.
 28. Kumagai M, Yamagishi T, Fukui N, Chiba M. Long-term cigarette smoking increases the prevalence of carotid artery calcification seen on panoramic dental radiographs in male patients. *Tohoku J Exp Med.* 2007 May;212(1):21-5.
 29. Warburton DE, Nicol CW, Bredin SS. Health benefits of physical activity: the evidence. *CMAJ.* 2006 Mar 14;174(6):801-9.
 30. Chen L, Bi Y, Su J. Physical activity and carotid atherosclerosis risk reduction in population with high risk for cardiovascular diseases: a cross-sectional study. *BMC Public Health.* 2022 Feb 7;22(1):250.
 31. Boss HM, van der Graaf Y, Visseren FLJ, Van den Berg-Vos RM, Bots ML, de Borst GJ, Cramer MJ, Kappelle LJ, Geerlings MJ; SMART Study Group. Physical Activity and Characteristics of the Carotid Artery Wall in High-Risk Patients-The SMART (Second Manifestations of Arterial Disease) Study. *J Am Heart Assoc.* 2017 Jul 23;6(7):e005143.
 32. Helmi J, Zakria Alhariri Z, AL-Jawfi K, Shamala A. Prevalence of carotid artery calcification detected by digital panoramic radiographs in a sample of Yemeni dental patients. *J Dent Res.* 2019 May;98(5):510-516.
 33. Constantine S, Roach D, Liberali S, Kiermeier A, Sarkar P, Jannes J, Sambrook P, Anderson P, Beltrame J. Carotid artery calcification on orthopantomograms (CACO Study) – is it indicative of carotid stenosis? *Aust Dent J.* 2019 Mar;64(1):4-10.
 34. Boehme AK, Esenwa C, Elkind MS. Stroke Risk Factors, Genetics, and Prevention. *Circ Res.* 2017 Feb 3;120(3):472-495.
 35. Friedlander AH, Manesh F, Wasterlain CG. Prevalence of detectable carotid artery calcifications on panoramic radiographs of recent stroke victims. *Oral Surg Oral Med Oral Pathol.* 1994 Jun; 77(6):669-73.
 36. Tamura T, Inui M, Nakase M, Nakamura S, Okumura K, Tagawa T. Clinicostatistical study of carotid calcification on panoramic radiographs. *Oral Dis.* 2005 Sep;11(5):314-7.
 37. Friedlander AH, Cohen SN. Panoramic radiographic atheromas portend adverse vascular events. *Oral Surg Oral Med Oral Pathol Oral Radiol Endod.* 2007 Jun;103(6):830-5.