



# SCROTAL THERMOGRAPHY IN THE EVALUATION OF SURGICAL OUTCOME AFTER VARICOCELE REPAIR: A CASE REPORT

Krešimir Karlović<sup>1</sup>, Tomislav Kuliš<sup>2</sup>, Ivana Lukić<sup>3</sup>, Darko Kolarić<sup>4</sup>, Ivan Milas<sup>2</sup>, Blaženka Miškić<sup>5</sup>, Svetlana Antonini<sup>6</sup> and Željko Kaštelan<sup>2</sup>

<sup>1</sup>Department of Urology, Dr. Josip Benčević General Hospital, Slavonski Brod, Croatia;

<sup>2</sup>Department of Urology, Zagreb University Hospital Center, School of Medicine, University of Zagreb, Zagreb, Croatia;

<sup>3</sup>Division of Cardiology, Department of Internal Medicine, Osijek University Hospital Center, Osijek, Croatia;

<sup>4</sup>Ruder Bošković Institute, Center for Informatics and Computing, Zagreb, Croatia;

<sup>5</sup>Department of Internal Medicine, Dr. Josip Benčević General Hospital, Slavonski Brod, Croatia;

<sup>6</sup>Department of Radiology, Zagreb-Centar Health Center, Zagreb, Croatia

**SUMMARY** – Scrotal thermography is a diagnostic method for varicocele. In short, there are five diagnostic thermographic criteria for varicocele, i.e., pattern of scrotal thermographic image indicative of varicocele, temperature at pampiniform plexus  $\geq 34$  C°, temperature difference between left and right pampiniform plexus  $\geq 0.5$  C°, enhancement of image during Valsalva maneuver, and temperature at pampiniform plexus  $\geq$  temperature at ipsilateral thigh. Three or more positive signs are indicative of varicocele. The aim of this report is to present the use of digital thermography as a diagnostic method to evaluate the outcome of varicocele repair. We present a case of a student diagnosed with varicocele grade III, and assessed preoperatively and followed up postoperatively by scrotal thermography. According to thermographic indicators, our patient was positive for varicocele diagnosis before surgical treatment. Three months after varicocele repair, the patient did not show positive thermographic indicators of varicocele while physical examination and color Doppler ultrasound were equivocal. This case report suggests that infrared digital thermography of scrotum could be very valuable for monitoring patients in the period after surgery for varicocele, however, it should be confirmed in a larger number of patients.

**Key words:** *Varicocele; Infertility; Infrared thermography; Scrotal temperature; Varicocele repair*

## Introduction

Varicocele is a dilatation of pampiniform venous plexus within the funiculus. It can be found in about 15% of males<sup>1</sup>. It could be associated with male infertility, as it is found in more than 40% of male part-

ners in infertile couples<sup>2</sup>. The main pathophysiological mechanism for afflicted spermatogenesis is considered to be increased scrotal temperature<sup>3</sup>. Varicocele is a common, but also a correctable cause of male infertility<sup>4</sup>. Surgical treatment of varicocele has a relatively high recurrence rate<sup>5</sup>. Diagnosis and monitoring of varicocele are based on physical examination, scrotal color Doppler ultrasound, and infrared digital thermography. Scrotal thermography objectively shows temperature of the scrotum associated with varicocele. The aim of this paper is to present scrotal thermogra-

Correspondence to: *Tomislav Kuliš, MD, PhD, FEBU*, Department of Urology, Zagreb University Hospital Center, Kišpatićeva 12, HR-10000 Zagreb, Croatia  
E-mail: tkulis@kbc-zagreb.hr

Received September 24, 2019, accepted October 24, 2019

phy as a diagnostic method that can also be used to evaluate outcome of varicocele repair.

### Case Report

The patient was a 20-year-old student who was diagnosed with varicocele during his regular physical examination. Prior to our study, the hospital Institutional Review Board approved the study, which followed the principles outlined by the World Medical Assembly Declaration of Helsinki, and the patient signed the informed consent form before undergoing the procedure.

For our measurements, we used the Thermo Tracer TH7012WL infrared camera (NEC Sanei Instruments, Ltd., Japan). The process of thermographic imaging and image analyses was conducted as previously reported<sup>3</sup>. In short, there are five diagnostic criteria, as follows: 1) a pattern of scrotal thermographic image indicative of varicocele; 2) temperature at pampiniform plexus  $\geq 34$  °C; 3) temperature difference between left and right pampiniform plexus  $\geq 0.5$  °C; 4) enhancement of image during Valsalva maneuver; and 5) temperature at pampiniform plexus  $\geq$  temperature

at ipsilateral thigh. Three or more positive signs are indicative of varicocele.

In our patient, scrotal thermography was performed with thermographic parameters being in favor of varicocele grade III. After thermography, physical examination was performed in upright position with and without Valsalva maneuver. We perceived visible varicocele typical of varicocele grade III<sup>2</sup>. This was followed by color Doppler ultrasound, which showed pampiniform vein diameter larger than 2 mm and positive reflux for more than 1 s on Valsalva maneuver.

Semen analysis prior to operation showed asthenozoospermia. Surgery was proposed to the patient, to which he agreed. We performed varicocele repair with the Palomo technique.

Three months after surgery, diagnostic procedures were repeated in an exact manner. After varicocele repair, physical examination revealed that the patient might have varicocele grade I. Color Doppler ultrasound examination showed pampiniform vein diameter larger than 2 mm, however, without reflux during Valsalva maneuver. Thermographic results are shown in Figures 1 and 2 and Table 1.

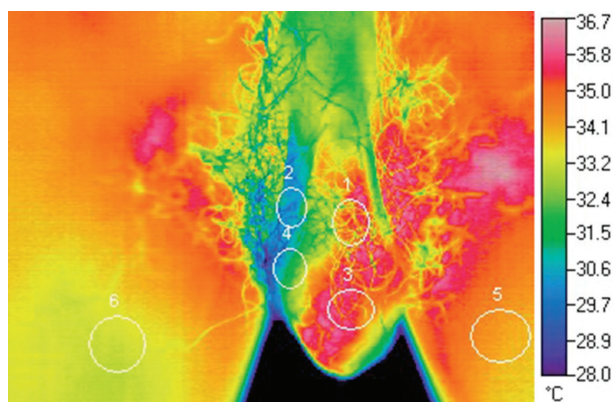


Fig. 1. Scrotal infrared digital thermography image of the patient before surgical treatment. Measured areas of interest are visible on the image.

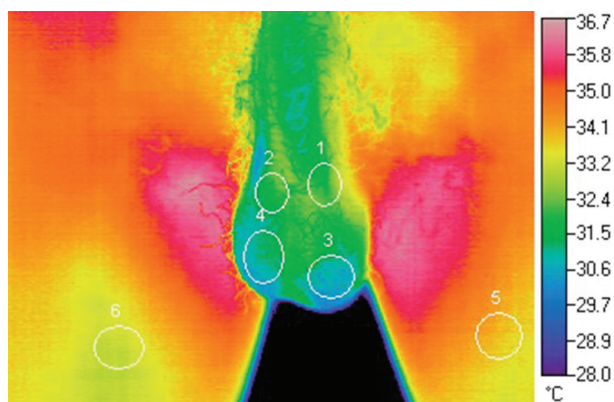


Fig. 2. Scrotal infrared digital thermography image of the patient after surgical treatment. Measured areas of interest are visible on the image.

Table 1. Mean temperature values in the areas of interest in thermographic image before and after varicocelectomy

	LP	RP	LT	RT	LTH	RTH	$\Delta$ LPRP	$\Delta$ LPLTH
Mean temperature before operation	34.3	30.6	35.1	31.6	34.1	33.2	3.7	0.2
Mean temperature after operation	32.1	31.7	30.8	31.0	33.8	33.1	0.4	-1.7

All values are expressed in °C; L = left; R = right; P = pampiniform plexus; T = testicle; TH = thigh;  $\Delta$  = temperature difference

It is important to note that semen analysis six months after operation showed normozoospermia.

#### ***Thermography of scrotum before surgical treatment***

According to thermographic diagnostic criteria, the pattern of scrotal temperature was indicative of high-grade left-sided varicocele. Temperature of the left pampiniform plexus was  $>34$  °C, which is the main thermographic indicator of varicocele, while temperature of the right pampiniform plexus was  $<34$  °C. Temperature difference between the left and right pampiniform plexus was higher or equal to  $0.5$  °C, which represents another thermographic indicator of varicocele. There were no differences in thermographic image during and after Valsalva maneuver. Temperature of the left pampiniform plexus was higher than the left thigh temperature, which is the last thermographic indicator. According to thermographic indicators, our patient was positive for varicocele diagnosis before surgical treatment.

#### ***Thermography of scrotum after surgical treatment***

In the left pampiniform plexus, temperature was  $<34$  °C. Temperature difference between the left and right pampiniform plexus was less than  $0.5$  °C. There were no differences in thermographic image during and after Valsalva maneuver. Temperature of the left pampiniform plexus was lower than the left thigh temperature. The patient did not show positive thermographic indicators of varicocele diagnosis after surgical treatment.

## **Discussion**

Preoperative thermographic image of our patient showed increased temperature in the left hemiscrotum. After the treatment, thermography showed significant temperature reduction in the testicles and pampiniform plexus, as well as in the entire scrotum.

Recurrence of varicocele is quite common in routine work. Recurrence rates vary from  $2.07\%$  to  $15.65\%$ , depending on surgical technique<sup>5</sup>. Recurrence may also be dependent on the population being studied, indications for initial intervention, degree of initial varicocele, definition of recurrence, and follow up period<sup>6</sup>. Furthermore, it has proven hard to diagnose recurrent varicocele.

Physical examination, as a usual initial diagnostic method, is limited by its subjective nature. In detecting recurrent varicocele, it has shown large interobserver variation between doctors with different levels

of training compared with color Doppler ultrasound<sup>7</sup>. Low sensitivity and specificity of physical examination compared to the ultrasound in diagnosing varicocele has also been reported in several studies<sup>8-12</sup>. Furthermore, a study involving experienced andrologists and clinicians identified a significant inter- and intra-observer variability in grading of varicoceles<sup>13</sup>. After surgery, during physical examination local status can be found to be quite unchanged compared to preoperative status, however, the patient has subjective and objective signs of recovery.

Venography is considered a reference standard as it has highest sensitivity for detecting varicocele<sup>14</sup>. However, considering its invasive nature, it is rarely used today. In a setting of recurrent varicocele, it has proved useful for detecting collateral venous flow and as a concomitant therapeutic method with embolization<sup>15,16</sup>.

In addition to physical examination and owing to its wide availability and noninvasive nature, scrotal ultrasound is today the most widely used diagnostic method. However, this widespread use of scrotal ultrasound has resulted in increased detection of subclinical varicoceles<sup>17</sup>. In postoperative setting, ultrasound yields conflicting data. Cvitanic *et al.* have reported palpable resolution of varicocele after surgery in  $91\%$  of patients, while only  $23\%$  of patients were found to have postoperative reductions on color Doppler ultrasound<sup>18</sup>. They conclude that this marked disparity in the light of the improving sperm parameters and conception rates raises question on ultrasound use in postoperative setting<sup>18</sup>. Ultrasound color Doppler is subjective and the diameter of pampiniform vessels is insufficient to confirm the right success of the operation, given that the vessels after surgery occasionally remain dilated<sup>18</sup>. Therefore, physical examination and color Doppler ultrasound sometimes are not enough to show us the true state.

Thanks to its high sensitivity and relative objectivity, scrotal infrared digital thermography could greatly help in monitoring the success of varicocele repair and can be an additional step in detecting recurrences of varicocele when physical examination is not sufficient and ultrasound color Doppler is not objective. To date, thermography has been little used with this aim and literature published on it is scarce.

A result similar to ours was described in 1992 by Iwata *et al.*<sup>19</sup>. The case describes a 12-year-old boy with left-sided varicocele (grade III) who was assessed pre-

operatively and followed up postoperatively by computer-assisted infrared thermography. Temperature in the left scrotum was 35.4 °C before surgery, which was by 4 °C higher than temperature in the right scrotum. After ligation of the left internal spermatic vein and removal of the varicocele, scrotal thermograms done 39 days and 12 months after the operation were normal<sup>19</sup>.

Scrotal thermography objectively shows preoperative temperature elevation in the scrotum caused by varicocele, as well as postoperative temperature reduction. It could be very valuable for monitoring patients in the period after surgical treatment and this should be confirmed in a larger number of patients.

## References

- Romeo C, Santoro G. Varicocele and infertility: why a prevention? *J Endocrinol Invest.* 2009;32(6):559-61. doi: 10.3275/633010.1007/BF03346507.
- Dubin L, Amelar RD. Varicolectomy as therapy in male infertility: a study of 504 cases. *Fertil Steril.* 1975;26(3):217-20.
- Kulis T, Kolaric D, Karlovic K, Knezevic M, Antonini S, Kastelan Z. Scrotal infrared digital thermography in assessment of varicocele – pilot study to assess diagnostic criteria. *Andrologia.* 2012;44 Suppl 1:780-5. doi: 10.1111/j.1439-0272.2011.01265.x.
- Baazeem A, Belzile E, Ciampi A, Dohle G, Jarvi K, Salonia A, *et al.* Varicocele and male factor infertility treatment: a new meta-analysis and review of the role of varicocele repair. *Eur Urol.* 2011;60(4):796-808. doi: 10.1016/j.eururo.2011.06.018.
- Diegidio P, Jhaveri JK, Ghannam S, Pinkhasov R, Shabsigh R, Fisch H. Review of current varicolectomy techniques and their outcomes. *BJU Int.* 2011;108(7):1157-72. doi: 10.1111/j.1464-410X.2010.09959.x.
- Rotker K, Sigman M. Recurrent varicocele. *Asian J Androl.* 2016;18(2):229-33. doi: 10.4103/1008-682X.171578.
- Lund L, Roebuck DJ, Lee KH, Sorensen HT, Yeung CK. Clinical assessment after varicolectomy. *Scand J Urol Nephrol.* 2000;34(2):119-22.
- Behre HM, Nashan D, Nieschlag E. Objective measurement of testicular volume by ultrasonography: evaluation of the technique and comparison with orchidometer estimates. *Int J Androl.* 1989;12(6):395-403.
- Meacham RB, Townsend RR, Rademacher D, Drose JA. The incidence of varicoceles in the general population when evaluated by physical examination, gray scale sonography and color Doppler sonography. *J Urol.* 1994;151(6):1535-8.
- Petros JA, Andriole GL, Middleton WD, Picus DA. Correlation of testicular color Doppler ultrasonography, physical examination and venography in the detection of left varicoceles in men with infertility. *J Urol.* 1991;145(4):785-8.
- Preuthipan S, Nicholas OA. Comparative study between scrotal physical examination and scrotal ultrasonography in the detection of varicocele in men with infertility. *J Med Assoc Thai.* 1995;78(3):135-9.
- Trum JW, Gubler FM, Laan R, van der Veen F. The value of palpation, varicoscreen contact thermography and colour Doppler ultrasound in the diagnosis of varicocele. *Hum Reprod.* 1996;11(6):1232-5.
- Carlsen E, Andersen AG, Buchreitz L, Jorgensen N, Magnus O, Matulevicius V, *et al.* Inter-observer variation in the results of the clinical andrological examination including estimation of testicular size. *Int J Androl.* 2000;23(4):248-53.
- Ahlberg NE, Bartley O, Chidekel N, Fritjofsson A. Phlebography in varicocele scroti. *Acta Radiol Diagn (Stockh).* 1966;4(5):517-28.
- Kwak N, Siegel D. Imaging and interventional therapy for varicoceles. *Curr Urol Rep.* 2014;15(4):399. doi: 10.1007/s11934-014-0399-0.
- Rais-Bahrami S, Montag S, George AK, Rastinehad AR, Palmer LS, Siegel DN. Angiographic findings of primary *versus* salvage varicoceles treated with selective gonadal vein embolization: an explanation for surgical treatment failure. *J Endourol.* 2012;26(5):556-60. doi: 10.1089/end.2011.0387.
- Belay RE, Huang GO, Shen JK, Ko EY. Diagnosis of clinical and subclinical varicocele: how has it evolved? *Asian J Androl.* 2016;18(2):182-5. doi: 10.4103/1008-682X.169991.
- Cvitanic OA, Cronan JJ, Sigman M, Landau ST. Varicoceles: postoperative prevalence – a prospective study with color Doppler US. *Radiology.* 1993;187(3):711-4.
- Iwata G, Deguchi E, Nagashima M, Yanagihara J, Iwai N, Yamada K. Thermography in a child with varicocele. *Eur J Pediatr Surg.* 1992;2(5):308-10. doi: 10.1055/s-2008-1063468.

## Sažetak

## TERMOGRAFIJA SKROTUMA U PROCJENI ISHODA OPERACIJE VARIKOKELE: PRIKAZ SLUČAJA

*K. Karlović, T. Kuliš, I. Lukić, D. Kolaric, I. Milas, B. Miškić, S. Antonini i Ž. Kaštelan*

Termografija skrotuma je metoda dijagnostike varikokele. Postoji pet termografskih dijagnostičkih kriterija za dijagnozu varikokele: termografski prikaz karakterističan za varikokelu, temperatura pampiniformnog pleksusa  $\geq 34\text{ }^{\circ}\text{C}$ , razlika temperature između lijevog i desnog pampiniformnog pleksusa  $\geq 0,5\text{ }^{\circ}\text{C}$ , indikativna promjena slike prilikom Valsalvina manevra i temperatura pampiniformnog pleksusa koja je  $\geq$  temperaturi ipsilateralne natkoljenice. Tri ili više pozitivnih znakova predstavlja pozitivan nalaz u slučaju dijagnostike varikokele. Cilj ovoga rada je prikazati primjenu termografije skrotuma kao dijagnostičke metode u procjeni ishoda operacije varikokele. Prikazat ćemo slučaj studenta koji je imao dijagnozu varikokele III. stupnja te je prijeoperacijski dijagnosticiran, a poslijeoperacijski praćen termografijom skrotuma. Prema termografskim kriterijima ovaj bolesnik je prijeoperacijski imao varikokelu. Tri mjeseca nakon operacije bolesnik nije imao pozitivne termografske znakove za varikokelu, međutim, klinički pregled i obojeni doppler nisu bilo tako uvjerljivi. Ovaj prikaz slučaja pokazuje mogućnost primjene termografije skrotuma u praćenju bolesnika nakon operacije varikokele, no ovo svakako treba potvrditi na većem broju ispitanika.

Ključne riječi: *Varikokela; Neplodnost; Termografija; Temperatura skrotuma; Operacija varikokele*