

Tomislav Badel¹, Iva Alajbeg¹, Miljenko Marotti², Sandra Kocijan Lovko³

Terapija poremećaja čeljusnog zgloba okluzijskom udlagom: prikaz slučaja

Temporomandibular Joint Disorder Therapy by Occlusal Splint: A Case Report

¹ Zavod za stomatološku protetiku Stomatološkog fakulteta Sveučilišta u Zagrebu, Zagreb, Hrvatska
Department of Prosthodontics, School of Dental Medicine, University of Zagreb, Zagreb, Croatia

² Zavod za dijagnostičku i intervencijsku radiologiju Kliničke bolnice Sestara milosrdnica" Sveučilišta u Zagrebu, Zagreb, Hrvatska
Department of Diagnostic and Interventional Radiology, Clinical Hospital "Sestre milosrdnice", University of Zagreb, Zagreb, Croatia

³ Psihijatrijska ambulanta Opće bolnice Zabok, Zabok, Hrvatska
Psychiatric Outpatient Department, Zabok General Hospital, Zabok, Croatia

Sažetak

Temporomandibularni poremećaji obuhvaćaju sve funkcijske poremećaje čeljusnih (temporomandibularnih) zglobova i žvačnih mišića. U radu se opisuje jedan od najčešćih - pomak zglobne pločice u anteriorni položaj, tzv. dislokacija. Ona se povezuje s nekoliko čimbenika - najčešće je to makrotrauma, na primjer udarac u čeljust, ili mikrotrauma povezana s kroničnom mišićnom hiperaktivnošću ili okluzijskom nestabilnošću. Magnetskom rezonancijom, neinvazivnom metodom za analizu tkiva, koristili smo se kako bismo snimili temporomandibularni zglob te meka tkiva. Iako se u liječenju temporomandibularnih poremećaja preporučuju i ireverzibilna terapijska sredstva, najčešći stomatološki oblik liječenja reverzibilan je i neinvazivan, što znači da se izrađuje stabilizacijska okluzijska udlaga. U radu je predstavljen slučaj pacijentice s anteriornim pomakom zglobne pločice lijevog temporomandibularnog zgloba te liječenje stabilizacijskom udlagom kako bi se postigla funkcionalna učinkovitost njezina mastikatornog sustava.

Zaprimljen: 19. srpnja 2007.

Prihvaćen: 30. lipnja 2008.

Adresa za dopisivanje

Tomislav Badel
Sveučilište u Zagrebu
Stomatološki fakultet
Zavod za stomatološku
Gundulićeva 5, HR-10000 Zagreb, Croatia
Tel. ++3851 48 02 125,
Fax. ++3851 48 02 159
badel@sfzg.hr

Ključne riječi

temporomandibularni poremećaj;
bruksizam; magnetska rezonancija

Uvod

Temporomandibularni poremećaji (TMD-i) obuhvaćaju sve funkcijske poremećaje čeljusnih (temporomandibularnih) zglobova i žvačnih mišića (1). U poremećaje čeljusnog zgloba najčešće ubrajamo probleme s kondil-disk kompleksom te upalne procese. Prvu kategoriju čine poremećaji u normalnom odnosu između kompleksa zglobne pločice i kondila te oni nastali zbog poremećaja u obliku zglobne pločice. Pritom je pomak zglobne pločice u anteriorni položaj vjerojatno najčešći nalaz tijekom

Introduction

Temporomandibular disorder (TMD) is the term that includes all functional disturbances of temporomandibular joints (TMJ) and masticatory muscles (1). Disorders of TMJ most commonly include problems with condyle-disc complex and inflammatory joint disorders. Changes of a normal relationship between articular disc and condyle as well as derangements of articular disc shape fall into the first category. Thus, the anterior articular disc displacement is probably the most common finding

pregleda pacijenta s disfunkcijom čeljusnog zgloba (2,3). Kod tog poremećaja mijenja se fiziološki odnos kondila i zglobne pločice u položaju mirovanja i/ili kretnji kondila tijekom otvaranja i zatvaranja usta.

Kako je disk medijalno i lateralno povezan s kondilom pomoću ligamenata diska, on zadržava svoj položaj na kondilu tijekom svih kretnji. Osim toga, translacijska kretnja u zdravom zglobu može biti jedino između kondil-disk kompleksa i zglobne jamice (4). Najvjerojatnije zbog produljenja donje retrodiskalne lamine i kolateralnih ligamenta zglobne pločice, te zbog sve tanjega stražnjeg ruba zglobne pločice, zglobna pločica može skliznuti ili biti u cijelosti gurnuta prema naprijed. Budući da ona i kondil tada više nisu međusobno uzgobljeni, to se stanje naziva *pomakom zglobne pločice* (5).

Ako pacijent može tako manipulirati s čeljusti da repozicionira kondil na stražnji rub zglobne pločice, smatra se da je zglobna pločica *reducirana*, što prati škljocanje tijekom otvaranja usta. Tada se namješta (reponira, to jest počinje redukcija postojećeg anteriornog pomaka) zglobna pločica na glavicu kondila. Tijekom zatvaranja usta zglobna pločica ne slijedi kretnju kondila, nego ostaje anteriorno smještena, što prati recipročno škljocanje (2,3).

Etiopatogeneza pomaka zglobne pločice nije u cijelosti razjašnjena. Bilo koje stanje koje vodi prema produljenju ligamenata zglobne pločice ili promjeni morfologije njezina stražnjeg ruba, može uzrokovati takav poremećaj kondil-disk kompleksa. Najčešći čimbenik je trauma. To može biti makrotrauma - iznenadna sila koja djeluje na zglob i može prouzročiti njegove strukturne promjene, ili mikrotrauma - funkcijsko preopterećenje povezano s mišićnom hiperaktivnošću (bruksizmom) ili okluzijskom nestabilnošću. Ostali mogući čimbenici su: povećana labavost (laksitet) zglobova, degenerativne zglobne bolesti (osteoartritis), promjene morfologije i položaja kondila (tj. dorzokranijalni pomak u zglobnoj jamici), povećano unutarzglobno trenje te smanjeno podmazivanje zbog povećanog opterećenja čeljusnog zgloba (6-8).

Pacijenti s pomakom zglobne pločice većinom su žene (oko 75 posto), uglavnom u dobi između 20 i 45 godina. Ovisnost temporomandibularnih poremećaja o spolu još nije objašnjena, ali se smatra da je, kao i kod ostalih muskuloskeletnih poremećaja u tijelu, važan fiziološki mehanizam i reakcija na doživljaj boli (9).

Sve dok nije dokazana povezanost s kauzalnim čimbenicima, a imamo samo opis mnogobrojnih ri-

when examining a patient for TMJ disorder (2,3). The change of physiological relationship between the condyle and articular disc in rest position and/or condyle movements while opening and closing the mouth is typical of this disorder.

In physiological conditions, the disc is medially and laterally bound to the condyle by discal ligaments. Thus the disc keeps its position on the condyle during all the movements. Furthermore, the translatory movement in healthy joint can occur only between the condyle-disc complex and articular fossa (4). It is most probable that the articular disc may slide or be entirely protruded forward due to elongation of the inferior retrodiscal lamina and discal collateral ligaments, as well as due to thinning of the posterior border of the articular disc. Since in this case an articular disc and the condyle are not joined together anymore, this condition is known as *articular disc displacement (DD)* (5).

If a patient can still manipulate his/her jaw in such a way to reposition the condyle on the posterior border of the articular disc, the articular disc is considered to be reduced (*DD with reduction*), which is accompanied by clicking during opening of the mouth. This results in repositioning, that is reduction of the existing anterior DD of the articular disc on the condyle head. During closing of the mouth the articular disc does not follow condyle movement but remains positioned anteriorly, which is accompanied by a reciprocal clicking (2,3).

The etiopathogenesis of articular disc displacement has not been entirely clarified. Any condition that leads to elongation of the discal ligaments or alteration of the morphology of the posterior discal border can cause the derangement of the condyle-disc complex. The most common risk factor related to this disorder is trauma. This can be macrotrauma - any sudden force to the joint that can result in structural alteration, or microtrauma - functional overloading associated with muscular hyperactivity (bruxism) or occlusal instability. Other potential risk factors include: increased laxity of the joints, osteoarthritis, changes in morphology and position of the condyle (that is dorsocranial displacement in the articular fossa), increased interarticular friction as well as decreased lubrication due to increased load of the TMJ (6-8).

Patients with disc displacement are mainly between 20 and 45 years of age, a large majority of them being women (about 75%). Correlation between TMD and gender has not yet been clarified, but physiological mechanism and response to pain

zičnih čimbenika, pacijentu je važno da se ustanove odgovarajući dijagnostički i terapijski postupci kojima se mogu izliječiti temporomandibularni poremećaji i poboljšati funkcija žvačnog sustava. U liječenju takvih poremećaja preporučuju se reverzibilna i neinvazivna terapijska sredstva. Najčešći stomatološki oblik liječenja je izradba okluzijske udlage. Između nekoliko konstrukcijskih oblika udlaga i njihova biomehaničkog djelovanja, jedna od najčešće korištenih jest ona stabilizacijska (10,11).

Prikaz slučaja

Dvadesetdevetogodišnja pacijentica, nakon pregleda kod oralnog kirurga, javila se u Zavod za stomatološku protetiku Stomatološkog fakulteta Sveučilišta u Zagrebu, zbog škljocanja i bolova u lijevom čeljusnom zglobo. Bol je bila posebice jaka tijekom žvakanja.

Anamneza

U anamnezi je pacijentica istaknula da od trenutnih simptoma pati već dulje. Škljocanje u lijevom čeljusnom zglobo javilo se prije desetak godina, a bol prije šest. Nije mogla navesti ni jedan događaj koji bi povezala s početkom simptoma. U posljednje dvije godine simptomi su se postupno pogoršavali te je bol postala izrazita pri otvaranju usta i žvakanju. Zbog toga ne može dulje imati otvorena usta, na primjer tijekom stomatološkog zahvata, a željela je i ortodontsku terapiju. Tijekom posljednje godine dana pacijentica je imala obostrano osjetljivu donju čeljust. Također je zapazila da škripi zubima, uglavnom noću kada se često budi sa zgrčenim žvačnim mišićima. Danju nastoji kontrolirati škripanje i stiskanje zuba.

Okluzijska analiza

Pacijentica je imala sanirane zube (Slika 1.). Izravnom okluzijskom analizom i poslije prijenosom dijagnostičkih modela zubnih lukova u artikulatorku, utvrđena je u anteroposteriornj dimenziji: klasa II/1 prema Angleu, horizontalni preklop 8 mm te normalan preklop gornjih zuba preko donjih (Slika 2.). U transverzalnoj ravnini pomak je medijalne linije između donjih središnjih sjekutića 2,5 mm ulijevo u odnosu prema gornjim središnjim sjekutićima, zbog gubitka ekstrahiranog zuba 36. Vertikalni preklop iznosio je 3,5 mm, a vertikalna okluzijska dimenzija bila je osigurana. Gornji umnjaci otežano

sensation are considered to play an important role in this disorder as well as in other musculoskeletal disorders (9).

So far there has been only a description of a large number of risk factors and no evidence of the correlation between causal factors. Therefore, for patients' benefit it is necessary to determine adequate diagnostic and therapeutic procedures in order to improve the function of the masticatory system. Reversible and noninvasive therapeutic means are recommended for treatment. The most common dental treatment is the use of stabilization occlusal splint (10, 11).

Case report

A 29 year-old female patient, previously examined by oral surgeon, reported to the Department of Prosthodontics, School of Dental Medicine, University of Zagreb, complaining of her left TMJ clicking and pain. The pain was accentuated with chewing.

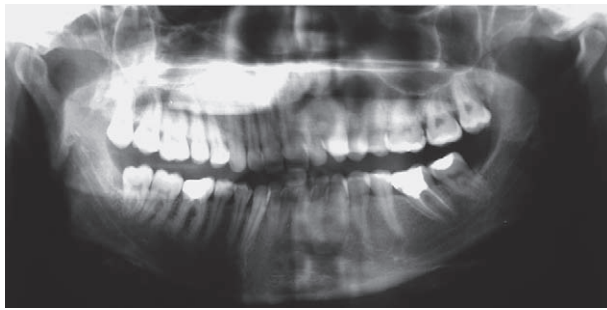Medical history

The patient stated to suffer from the described symptoms for a longer period of time. Clicking in her left TMJ had begun about 10 years ago and joint pain 6 years ago. She was unable to associate any special event that could be related to the onset of symptoms. During the last 2 years symptoms had gradually become worse with pain during mouth opening and mastication. This resulted in her inability to have her mouth open for a longer period of time, for example, during dental treatment. The patient also requested to have an orthodontic treatment. In the last year she has also suffered from tenderness of the mandible bilaterally. She was aware of teeth clenching mainly at night when she woke up with spasms in her masticatory muscles. By day she attempts to control clenching and grinding of her teeth.

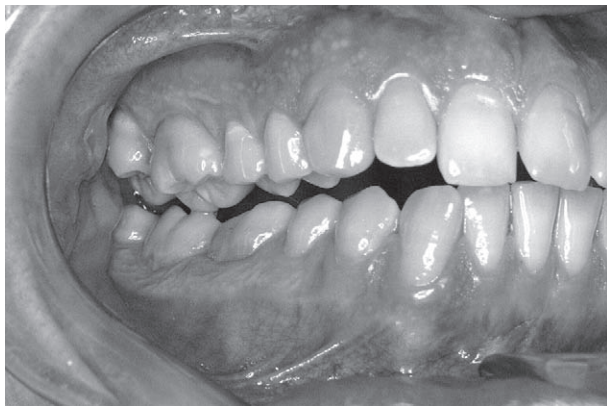Occlusal analysis

The patient's teeth were treated previously (Figure 1). By direct occlusal analysis and later by mounting diagnostic casts on an articulator, the following has been determined in the anteroposterior dimension: Angle's class II/1, an 8 mm horizontal overlap and a normal overbite of upper teeth over the lower ones (Figure 2). In the transversal plane there was a 2.5 mm displacement of the medial line between lower central incisors to the left compared with the upper central incisors due to the loss of previously extracted tooth 36. A vertical overlap amounted to 3.5 mm while the vertical occlusal dimension was

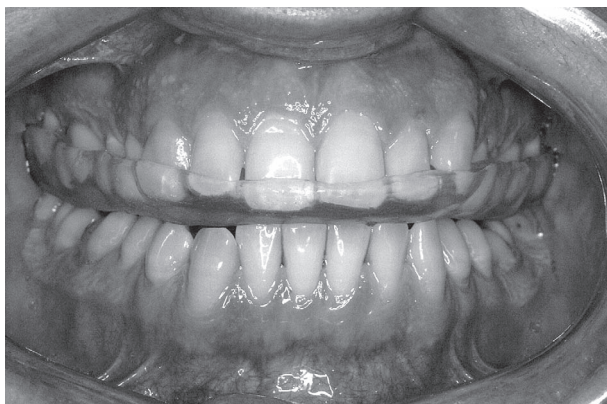
su nicali te ih je prije terapije udlagom izvadila zbog premalo mjesta u zubnom luku i tercijalne kompresije. U objema lateralnim kretnjama bilo je prisutno vođenje očnjakom, ali je tijekom lijeve lateralne kretnje uočen interferentni dodir na zubima 16 i 47 na mediotruzijskoj strani (Slika 3.).



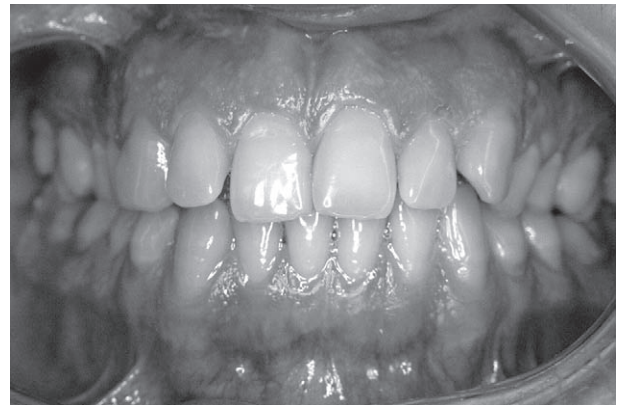Slika 1. Ortopantomogramski prikaz zubnog statusa pacijentice
Figure 1 Panoramic image of patient's dental status



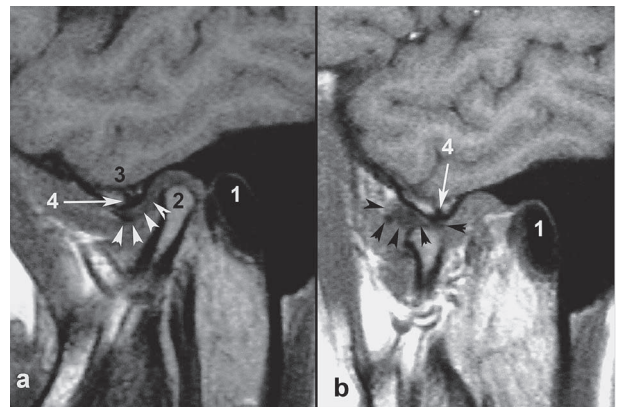
Slika 3. Ravnotežni (balansni) dodir između zuba 16 i 47 na neradnoj strani tijekom lijeve laterotruzijske kretnje vođene očnjakom
Figure 3 The balanced contact between tooth 16 and tooth 47 on the non-working side during left laterotrusion movement by canine guidance



ensured. The upper wisdom teeth erupted with difficulty so she had them extracted prior to splint treatment due to lack of space in the dental arch and due to tercial compression. In both lateral movements there was a canine guidance, but during left lateral movement the patient had mediotrusive contact with teeth 16 and 47 (Figure 3).



Slika 2. Habitualna okluzija pacijentice
Figure 2 The patient's habitual occlusion



Slika 4. Prikaz lijevog čeljusnog zgloba magnetskom rezonancijom u položaju zatvorenih (a) i otvorenih (b) usta (1-vanjski zvukovod, 2-kondil, 3-zglobna kvržica, 4-subhondralna sklerozacija zglobne kvržice, strelice-zglobna pločica)
Figure 4 A magnetic resonance image of the left temporomandibular joint in the closed (a) and open (b) mouth position (1-external auditory meatus, 2-condyle, 3-articular eminence, 4-subchondral sclerosation of the articular eminence, arrows- the articular disc)

Slika 5. Okluzijska udlaga aplicirana na gornjem zubnom nizu
Figure 5 Occlusal splint applied to the upper teeth arrangement

Iako nije imala znatnije izražene kliničke znakove zubne abrazije (stupanj 2, fasete paralelne s konturama zubnih ploha (12), na temelju anamnestičkih podataka dijagnosticiran je bruksizam - opazila je da škripi zubima, noću se budi sa zgrčenim žvačnim mišićima, a škripanje tijekom spavanja potvrđuje i njezin partner.

Psihološka testiranja

Zbog mogućeg djelovanja psiholoških čimbenika na dugotrajnije bolove u čeljusnom zglobu (kronična bol) te moguće etiopatogenetske podloge za razvoj bruksizma, pacijentica je testirana na anksioznost, što je potvrđeno psihološkim mjernim instrumentom State-Trait Anxiety Inventory (13). Rezultati u STAI 1 (odnose se na anksioznost kao subjektivno stanje, osjećaj zadnjih tjedan dana, uključujući i danas) i STAI 2 (odnosi se na anksioznost kao razmjerno stabilnu individualnu karakteristiku općenito tijekom života) pokazuju visoku razinu anksioznosti. Oboje, - STAI 1=38 i STAI 2=40 - više su vrijednosti od referentnih prosječnih vrijednosti koje iznose 36,17 za STAI 1 i 36,15 za STAI 2 za tu životnu dob i spol.

Klinički pregled

Kliničkim pregledom i ortopedskim testovima utvrđeno je recipročno škljocanje i bolovi u lijevom čeljusnom zglobu. Aktivno otvaranje usta iznosilo je 45 mm, a pasivno, tj. otvaranje uz primjenu blage pasivne sile na donje sjekutiće u smjeru prema dolje, iznosilo je 55 mm. Protruzijska kretnja iznosila je 12 mm, laterotruzija desno 9 mm, a laterotruzija lijevo 11 mm. Intenzitet boli na vizualno analagnoj ljestvici bio je 65 posto. Tijekom otvaranja usta dolazi do devijacije udesno. Temeljem kliničkog nalaza posumnjalo se na anteriorni pomak zglobne pločice s redukcijom u lijevom čeljusnom zglobu, te je pacijentica upućena na magnetsku rezonanciju kako bi se eventualno to potvrdilo te utvrdio stupanj pomaka.

Radiološka dijagnostika

Radiološkom dijagnostičkom metodom - magnetskom rezonancijom - potvrđen je anteriorni pomak zglobne pločice u lijevom čeljusnom zglobu. Izražena je fibrozacija retrodiskusnog tkiva, te se počeo stvarati pseudodiskus. Uredan je bio prikaz oblika glavice kondila, koja nije smještena centralno u zglobnoj jamici nego dorzokranijalno. Vidljiva je također blaga subhondralna sklerozacija zglobne kvržice uz održan kontinuitet kortikalne kosti. Tijekom

Although clinical signs of dental abrasion were not significantly expressed (degree 2, facets parallel with contours of tooth surfaces) (12), bruxism was diagnosed based on her medical history. She noticed clenching of her teeth and woke up at night with spasms in her masticatory muscles; the nocturnal clenching was confirmed by her partner.

Psychological testing

The patient was tested for anxiety due to interaction of psychological factors and pain which lasted for a longer period of time (chronic pain) and a possible etiopathogenetic basis for development of bruxism, which was confirmed by State-Trait Anxiety Inventory (STAI) (13), a psychological measuring instrument. STAI 1 test results (related to anxiety as a subjective condition, patient's mood in the last week including the day of testing) and STAI 2 test results (related to anxiety as a relatively permanent individual trait generally throughout a lifetime) showed higher anxiety scores (STAI 1=38 and STAI 2=40) than the mean reference scores for this age and gender amounting to 36.17 for STAI 1 and 36.15 for STAI 2, respectively.

Clinical diagnostics

A reciprocal clicking accompanied by pain in the left TMJ was diagnosed by clinical examination and orthopedic tests. Active mouth opening amounted to 45 mm whereas passive mouth opening, that is mouth opening by exerting a mild downward passive force on the lower incisors, amounted to 55 mm. Protrusive movement amounted to 12 mm, laterotrusion to the right amounted to 9 mm and laterotrusion to the left amounted to 11 mm. The pain intensity on Visual Analogue Scale (VAS) was rated 65%. On mouth opening there was a deviation to the right. Based on clinical findings, an anterior DD of articular disc with reduction in the left TMJ was suspected so that the patient was referred to magnetic resonance imaging (MRI) in order to possibly confirm a degree of the DD.

Radiological diagnostics

The anterior DD of the articular disc in the left TMJ was confirmed by MRI. There was a pronounced fibrosation of retrodiscal tissue expressed by pseudodisc. The form of the condyle head, which was not positioned centrally in the articular fossa but dorsocranially, was normal. A mild subchondral sclerosis of the articular eminence with maintained continuity of cortical bone was visible. On mouth opening there was a partial reduction, that is

kom otvaranja događa se djelomična redukcija, tj. zglobna pločica u položaju otvorenih usta ne namješta se potpuno u svoj fiziološki položaj na glavicu kondila (Slika 4.).

Postupak liječenja

Za inicijalno liječenje bolova uzrokovanih anteriornim pomakom zglobne pločice indicirana je i izrađena stabilizacijska udlaga (prema nekim autorima michiganska udlaga –(14) (Slika 5.). Ona privremeno osigurava stabilan položaj zgloba, te smanjuje abnormalnu (parafunkcijsku) mišićnu aktivnost i štiti tvrda zubna tkiva od prekomjernog i nefiziološkog trošenja (5).

Pacijentici su uzeti alginatni otisci obiju čeljusti te joj je udlaga izrađena u novom terapijskom položaju, tj. položaju centrične relacije (11). To je ujedno bio i najpovoljniji položaj za izradbu stabilizacijske udlage indiciran u tom slučaju, budući da osigurava stabilnu poziciju kondila u zglobnim jamicama te istodobno omogućuje rasterećenje retrodiskalnog tkiva od trajnog pritiska koji kondil na njega čini, jer je zglobna pločica pomaknuta trajno naprijed. Pacijentici je savjetovano da udlagu nosi noću barem tri mjeseca, a na prvu kontrolu bila je naručena za tjedan dana.

Nakon sedam dana pacijentica je još osjećala bolove. Nakon tri mjeseca škljocanje se još čulo, iako slabije, uz još znatno izražen intenzitet boli na vizualno analagnoj ljestvici ocijenjen s 22 posto. Preporučeno joj je da nosi udlagu sljedeća tri mjeseca, kako bi se poboljšalo cijeljenje retrodistalnoga tkiva. Na redovitoj kontroli, nakon što je dvanaest mjeseci nosila udlagu, pacijentica više nije imala bolove. Okluzijska udlaga bila je u dobrom stanju, tako da je i dalje nosi noću zbog bruksističke aktivnosti. Povremeno škljocanje, ali rjeđe nego u razdoblju bolnih simptoma, nije ju funkcijski ograničavalo. Pacijentici je rečeno da bi zvukovi u zglobu mogli biti trajni, no najvjerojatnije bez bolova.

Rasprava

Nije u cijelosti objašnjen patogenetski tijek anteriorno pomaknute zglobne pločice, opseg i posljedice procesa pregradnje u čeljusnom zglobu te tijekom stanja bez adekvatne terapije. Samo bezbolno škljocanje u čeljusnom zglobu, nije dovoljan klinički nalaz za terapiju. Škljocanje se javlja zbog repozicije zglobne pločice tijekom otvaranja usta i njezina vraćanja u pomaknuti položaj tijekom zatvaranja (15).

Longitudinalno istraživanje pokazalo je veliku varijabilnost u pojavi i iščezavanju pojedinih glav-

the articular disc in the open mouth position was not entirely placed into its physiological position on the condyle head (Figure 4).

Treatment

The stabilization splint (according to some authors the Michigan splint) (14) is indicated for the initial treatment of pain caused by anterior DD (Figure 5). It temporarily provides stable joint position, and in addition reduces abnormal (parafunctional) muscle activity as well as protects hard dental tissues from excessive non-physiological wear (5).

Both jaw alginate impressions were taken and the splint was fabricated in a new therapeutic position, that is in a position of centric relation (11). This was also the best position for stabilization splint fabrication since it ensures a stable position of condyle in the articular fossa. It also enables the removal of the retrodiscal tissue load exerted by the condyle since the articular disc is permanently protruded, that is displaced anteriorly. The patient was instructed to wear the appliance while sleeping for at least 3 months and was asked to come for a check up in a week.

After 1 week she reported that she still felt some pain. After 3 months the clicking had lessened but was still present, with still significant pain intensity on Visual Analogue Scale (22%). She was encouraged to continue wearing the appliance for three more months to promote complete healing of retrodiscal tissues. After twelve months recall appointment the patient did not sense any pain at all. The occlusal splint was still in a good state so that the patient could wear it at night only for nocturnal bruxism. Occasional clicking, less frequent than at time when she suffered a lot of pain, did not cause any functional limitations. The patient was told that the joint sound would likely be permanent but hopefully with no pain.

Discussion

The pathogenesis of the anterior DD, the extent and consequences of remodeling and the condition without adequate treatment have not been entirely clarified. Just the painless clicking in the TMJ is insufficient clinical finding to require the treatment. Clicking is the result of articular disc repositioning on mouth opening and its return into the displaced position on mouth closing (15).

Longitudinal studies revealed great variability in the appearance and disappearance of certain main

nih simptoma temporomandibularnih poremećaja. U ovom radu pacijentica je znatno prije pojave boli čula škljocanje. Možemo pretpostaviti da je to bio subklinički znak anteriornog pomaka zglobne pločice s repozicijom, ali je dulje postojala funkcijska kompenzacija takvog stanja (16).

S obzirom na to da je znatna prevalencija anteriornog pomaka zglobne pločice i kod asimptomatskih ispitanika, nalaz poremećaja temporomandibularnog zgloba dokazan magnetskom rezonancijom može se uvjetno smatrati patološkim. Potvrđena je povezanost kliničkih znakova te nalaza magnetske rezonancije i klinička primjena u dijagnostici boli čeljusnog zgloba (17). Neki su autori opisali povezanost dorzokranijalnog pomaka kondila u etiološkom modelu nastanka anteriornog pomaka zglobne pločice (18,19), a Kuritta i suradnici (20) ističu samo povezanost s anteriornim pomakom zglobne pločice s redukcijom.

Makroskopske promjene pomaka zglobne pločice, promjene su njezina oblika, odnosno istanjivanje ili deformacija. Zglobne se strukture pregradnjom (remodelacijom) prilagođavaju opterećenju izvan fizioloških granica. U predjelu bilaminarne zone prema stražnjem dijelu (*pars posterior*) zglobne pločice dolazi do fibrozacije, te se smanjuje udjel elastičnih vlakana, krvnih i živčanih elemenata, pa nastaje pseudodiskus, što je bilo vidljivo i na prikazu zgloba naše pacijentice (21). To se može objasniti duljim razdobljem anterionog pomaka zglobne pločice i reparacijskog mehanizma kojim se nastoji imitirati njezin fiziološki položaj.

Terapijska okluzija postignuta apliciranjem stabilizacijske udlage je neinvazivno okluzijsko liječenje morfoloških i fizioloških značajki žvačnog sustava, čime se privremeno mijenjaju okluzijski uvjeti i položaj zgloba (22). Načelo osmišljavanja terapijske okluzije najčešće je individualni pristup kako bi se poboljšala funkcija, popravila kvaliteta života i izbjegla ijatrogena šteta (11).

Terapija poremećaja temporomandibularnog zgloba okluzijskim udlagama najčešće je, ali i ne jedino, sredstvo liječenja i izbora. Kao dodatna terapijska mogućnost tu je najprije farmakoterapija (neopioidni analgetici i nesteroidni antireumatici) te fizioterapija. *Biofeedback* je djelotvorniji od bilo kojeg oblika placeba i gotovo ekvivalentan terapiji udlagama. Psihoterapija se primjenjuje u slučaju kronificiranja temporomandibularne boli (23).

Bruksizam, to jest klinička manifestacija bruksizma u obliku nefiziološke atricije zuba, potencijalni je rizični čimbenik za nastanak temporomandibu-

symptoms of TMD. In this case, the patient experienced clicking long before the pain started. It is assumed that clicking in this case was a subclinical sign of the anterior articular DD with reduction. Nevertheless, there was a functional compensation of this condition for a longer period of time (16).

Since there was also a significant prevalence of anterior DD in asymptomatic subjects, the finding of TMJ disorders confirmed by MRI can most probably be considered pathological. Correlation between clinical signs and MRI findings has been determined as well as clinical application in TMJ pain diagnostics (17). Some authors described the connection of dorsocranial condyle displacement in etiological model of anterior DD (18, 19), whereas Kuritta et al. (20) report only the connection with DD with reduction.

Macroscopic changes of DD are in fact changes in its shape that is either thinning or deformity. The articular structures adapt to the overload beyond physiological limits by remodeling. Fibrosation occurs in the bilaminar zone towards the posterior part (*pars posterior*) of the articular disc, and pseudodisc occurs with a decrease in the number of elastic fibers, vascular and nerve elements, which was evident in the image of the patient's TMJ (21). This can be explained by anterior DD for a longer period of time as well as by the repair mechanism which attempts to imitate its physiological position.

Therapeutic occlusion achieved by the application of stabilization splint is non-invasive occlusal treatment of morphological and physiological characteristics of the masticatory system which temporarily alters the occlusal condition and joint position (22). The principle of creating a therapeutic occlusion is most commonly an individual approach aiming at improving the function, quality of life as well as avoiding iatrogenic damages (11).

The treatment of TMJ disorders by occlusal splints is the most frequent, but not the only method of choice. As an additional therapeutic alternative, the first choice is pharmacotherapy (nonopioid analgesic drugs and nonsteroidal anti-inflammatory drugs) and physical therapy. *Biofeedback* is more efficient than any other type of placebo and almost identical to splint therapy. Psychotherapy is applied in the case of TMJ pain chronification (23).

Bruxism, that is a clinical manifestation of bruxism as non-physiological attrition of teeth, is a putative risk factor for TMD (8). However, Pergamalian et al. (24) did not find any correlation between

larnih poremećaja (8). No, Pergamalian i suradnici (24) nisu utvrdili povezanost atricije zuba s bruksizmom te temporomandibularnom boli čeljusnih zglobova i mišićja.

Etiopatogeneza bruksizma povezana je uglavnom s patofiziološkim i psihološkim čimbenicima, a ne s okluzijom i ostalim morfološkim čimbenicima žvačnog sustava (25). U suvremenom multidisciplinarnom pristupu treba utvrditi anksioznost, kao mogući etiološki čimbenik bruksizma i perpetualni čimbenik temporomandibularne boli. U našem istraživanju ustanovljena je znatnija razina anksioznosti kod pacijenata s diskopatijom čeljusnog zgloba ako im je dijagnosticiran i bruksizam (26).

Zaključak

U zaključku ovog rada istaknimo da je magnetska rezonancija dijagnostički standard u potvrđivanju kliničkih znakova poremećaja čeljusnog zgloba. Kako je trošenje zuba posljedica bruksizma, stabilizacijska udlaga može biti ne samo inicijalno terapijsko sredstvo liječenja poremećaja čeljusnog zgloba, nego u duljem razdoblju i djelotvorna zaštita od noćnog bruksizma.

teeth attrition and bruxism with pain in TMJs and muscles.

Etiopathogenesis of bruxism is mainly related to physiopathological and psychological factors rather than occlusion or some other morphological factors of the masticatory system (25). In the current multidisciplinary approach, anxiety as a putative etiological factor of bruxism and perpetual factor of temporomandibular pain should be diagnosed. In this research, a significant level of anxiety in patients with TMJ disorders was diagnosed provided that bruxism was diagnosed as well (26).

Conclusion

In conclusion, MRI is a diagnostic standard for confirmation of clinical signs of TMJ disorders. Since tooth wear is a result of bruxism, the stabilization splint is not only an initial therapeutic means for treating TMJ disorders, but also an efficient protection from nocturnal bruxism throughout a longer period of time.

Abstract

Temporomandibular disorder is the term that includes all functional disturbances of temporomandibular joint and masticatory muscles. This paper deals with one of the most common types of temporomandibular disorders that is articular disc displacement into an anterior position or so called articular disc dislocation. The most common risk factor related to this disorder is trauma. This can be a macrotrauma, such as an impact into the jaw, or microtrauma, which is related to chronic muscle hyperactivity or the occlusal instability. Magnetic resonance imaging is used for noninvasive evaluation of temporomandibular joints and soft tissues. Although irreversible therapeutic means are recommended for temporomandibular disorder treatment, the most common dental treatment is reversible and noninvasive which implies occlusal stabilization splint fabrication. This paper reports a case of a female patient with anterior articular disc displacement of her left temporomandibular joint and the treatment by a stabilization splint in order to obtain functional efficiency of her masticatory system.

Received: July 19, 2007

Accepted: June 30, 2008

Address for correspondence

Tomislav Badel, DMD, PhD
University of Zagreb
School of Dental Medicine
Department of Prosthodontics
Gundulićeva 5, HR-10000 Zagreb, Croatia
Tel. ++3851 48 02 125
Fax. ++3851 48 02 159
badel@sfz.hr

Key words

Temporomandibular Joint Disorders;
Bruxism; Magnetic Resonance Imaging

References

1. Griffiths RH. Report of the president's conference on the examination, diagnosis, and management of temporomandibular disorders. *J Am Dent Assoc.* 1983;106:75-7.
2. Türp JC, Hugger A, Nilges P, Hugger S, Siegert J, Busche E et al. Recommendations for the standardized evaluation and classification of painful temporomandibular disorders: an update. *Schmerz.* 2006;20(6):481-9.
3. Badel T, Pandurić J, Marotti M, Krolo I. Funkcijski poremećaji u žvačnomu sustavu. *Med Jadertina.* 2005;35(2):81-6.
4. Obrez A, Gallo LM. Anatomy and Function of the TMJ. In: Laskin DM, Green CS, Hylander WL, editors. Temporomandibular disorders. An evidence-based approach to diagnosis and treatment. Hanover Park: Quintessence; 2006. p. 35-67.
5. Okeson JP. Management of temporomandibular disorders and occlusion. St. Louis: Mosby; 1998.
6. Huddleston Slater JJ, Lobbezoo F, Onland-Moret NC, Naeije M. Anterior disc displacement with reduction and symptomatic hypermobility in the human temporomandibular joint: prevalence rates and risk factors in children and teenagers. *J Orofac Pain.* 2007;21(1):55-62.
7. Greene CS. Concepts of TMD etiology: effects on diagnosis and treatment. In: Laskin DM, Green CS, Hylander WL.

- Temporomandibular disorders. An evidence-based approach to diagnosis and treatment. Hanover Park: Quintessence; 2006. p. 219-28.
8. Mikić V, Gržić R, Kovačević Pavičić D, Antičić R, Fugošić V. Etiologija temporomandibularnih poremećaja. *Medicina*. 2006; 42(4):237-42.
 9. Türp JC. Temporomandibular Pain - Clinical Presentation and Impact. Berlin: Quintessenz-Verlag; 2000.
 10. Dylina TJ. The basics of occlusal splint therapy. *Dent Today*. 2002;21(7):82-7.
 11. Badel T, Pandurić J, Kraljević S, Dulčić N. Initial Treatment of Prosthetic Patients with a Michigan Splint. *Acta Stomatol Croat*. 2003;37(2):199-210.
 12. John MT, Frank H, Lobbezoo F, Drangsholt M, Dette KE. No association between incisal tooth wear and temporomandibular disorders. *J Prosthet Dent*. 2002;87(2):197-203.
 13. Spielberger CD. Priručnik za upitnik anksioznosti kao stanja i osobine ličnosti (STAI) (Oblik Y). Jastrebarsko: Naklada Slap; 2000.
 14. Ash MM Jr, Ramfjord SP. Reflections on the Michigan splint and other intraocclusal devices. *J Mich Dent Assoc*. 1998;80(8):32-5.
 15. Leader JK, Robert Boston J, Rudy TE, Greco CM, Zaki HS, Henteleff HB. Quantitative description of temporomandibular joint sounds: defining clicking, popping, egg shell crackling and footsteps on gravel. *J Oral Rehabil*. 2001;28(5):466-78.
 16. Magnusson T, Egermark I, Carlsson GE. A longitudinal epidemiologic study of signs and symptoms of temporomandibular disorders from 15 to 35 years of age. *J Orofac Pain*. 2000;14(4):310-9.
 17. Hugger A. Diagnostic imaging assessment of temporomandibular joint pain. *Schmerz*. 2002;16(5):355-64.
 18. Bonilla-Aragon H, Tallents RH, Katzberg RW, Kyrkanides S, Moss ME. Condyle position as a predictor of temporomandibular joint internal derangement. *J Prosthet Dent*. 1999;82(2):205-8.
 19. Gateno J, Anderson PB, Xia JJ, Horng JC, Teichgraeber JF, Liebschner MA. A comparative assessment of mandibular condylar position in patients with anterior disc displacement of the temporomandibular joint. *J Oral Maxillofac Surg*. 2004;62(1):39-43.
 20. Kurita H, Ohtsuka A, Kobayashi H, Kurashina K. A study of the relationship between the position of the condylar head and displacement of the temporomandibular joint disk. *Dentomaxillofac Radiol*. 2001;30(3):162-5.
 21. Larheim TA. Role of magnetic resonance imaging in the clinical diagnosis of the temporomandibular joint. *Cells Tissues Organs*. 2005;180(1):6-21.
 22. Alajbeg IZ, Valentić-Peruzović M, Alajbeg I, Illes D. Influence of occlusal stabilization splint on the asymmetric activity of masticatory muscles in patients with temporomandibular dysfunction. *Coll Antropol*. 2003;27(1):361-71.
 23. Palla S. Principles on therapy of myoarthropathic pain. *Schmerz*. 2002;16(5):373-80.
 24. Pergamalian A, Rudy TE, Zaki HS, Greco CM. The association between wear facets, bruxism, and severity of facial pain in patients with temporomandibular disorders. *J Prosthet Dent*. 2003;90(2):194-200.
 25. Lobbezoo F, Naeije M. Bruxism is mainly regulated centrally, not peripherally. *J Oral Rehabil*. 2001;28(12):1085-91.
 26. Badel T, Kocijan Lovko S, Pandurić J, Marotti M, Keros J, Kern J. Anxiety and bruxist behaviour in the patients with temporomandibular joint disorder. *J Eur Psychiatry* 2007; 22 Supp 1:268.