

Diagnostic Imaging of Small Amounts of Pleural Fluid: Pleural Effusion vs. Physiologic Pleural Fluid

Igor Kocijančič

Clinical Institute of Radiology, University Medical Centre, Ljubljana, Slovenia

ABSTRACT

The aim of this article is to present an overview of our 10 years clinical research work and early clinical experience with small pleural effusions. Small amounts of pleural fluid are severely difficult to identify with imaging methods (chest x-rays and ultrasound). Nevertheless, it may be an important finding, sometimes leading to a definitive diagnosis of pleural carcinomatosis, infection or other pathologic condition. Chest x-rays were used for many years for the diagnosis of small pleural effusions. Lateral decubitus chest radiographs represented a gold standard for imaging of small amounts of pleural fluid for more than 80 years. In the last two decades, ultrasonography of pleural space became a leading real-time method for demonstrating small pleural effusions. Furthermore, the advent of sonographic technology actually enables detection of physiologic pleural fluid in some otherwise healthy individuals. In conclusion, new definitions of the key terms in the field of diagnostic imaging of small amounts of pleural fluid seem to be justified. We suggest that the term pleural fluid should determine physiologic pleural space condition while the term pleural effusion should only be used in the cases of pleural involvement or pleural illness.

Key words: pleura, pleural effusion, pleural fluid, ultrasonography, radiography, thoracic, physiology

Introduction

The pleural space is only potential space between the parietal and visceral pleura. The pleural surface is covered by a thin (5 to 10 μm) fluid layer¹. Limited studies in healthy volunteers suggested that the amount of fluid is generally no more than 5 ml, but could be up to 15 mL². Noppen et al.³ recently showed that the amount of fluid is 4 to 18 mL in a single pleural space of healthy individual.

The data on the smallest amount of pleural fluid detectable by imaging methods vary considerably. Lateral decubitus chest radiography was used for many years for detecting small pleural effusions⁴⁻⁷. There are only two articles^{4,6} over 50 years old, reporting on the possibility to demonstrate normal pleural fluid with lateral decubitus chest radiography. The advent of sonographic technology enables to detect very small amounts of pleural fluid this way⁸⁻¹⁰.

In the literature there are only few articles compared the thickness of the pleural effusion as seen on sono-

graphy with X-ray and the amount of aspirated fluid^{11,12}. In addition there is no clear consensus definition of small pleural effusion on chest radiography and on sonography. Furthermore there are no fixed boundaries between the amount of pleural fluid detected by imaging methods in physiologic and pathologic (i.e. pleural effusions) conditions.

Chest Radiography

If the pleural space contains an effusion in upright position the fluid will tend to obey the law of gravity and accumulate in the infrapulmonary space if pleural space is free of adhesions and the lung is healthy, so forming »sub-pulmonary« effusion. If the patient is examined in upright position only, the image will give the impression that the fluid is situated between the lung and the diaphragm. The reason for this so called »infra or sub-pulmonary« localisation is its anatomy. Dorsal pleural si-

nuses are the deepest and more fluid accumulates in this localisation.

Nearly simultaneous with »infra or sub-pulmonal« accumulation, the pleural fluid come in site in the costophrenic recesses and can be seen as medial displacement of costophrenic angle first and with blunting of the diaphragm afterwards¹². It is agreed that gravity is probably the main factor of location of fluid, although some authors believe that elasticity of the lung, basal atelectasis and surface tensions could contribute as factors of fluid accumulation^{12,13}. Davis et al.¹⁴ has shown that the upper limit of a free pleural effusion is horizontal and is located about the level of the apex of the meniscus shaped density. The x-ray beam traverses a greater depth of the fluid in the periphery of the thorax where the fluid is tangential to the beam¹⁵.

Radiological imaging methods detect free pleural fluid with erect poster-anterior (PA) chest radiographs, by erect lateral views and more precisely by lateral decubitus chest radiograph with horizontal X-ray beams.

The amounts of 175 to 500 mL could be hidden in pleural space on erect PA views radiographs¹¹. The term small pleural effusion should not be used for the pleural fluid clearly visible on PA chest films. We disagree with

the authors who claiming that meniscus sign with blunting of one half of the hemi diaphragm is a sign of small pleural effusion^{18,19}. We proposed that a small meniscus sign (Figure 1) and medial displacement of costophrenic angle (Figure 2) are the only subtle signs of small accumulations of fluid on PA as well as lateral erect views. In these cases 200–300 mL of fluid can be evacuated from the pleural space^{14,20}.

In a study on a roentgen pathology models Collins¹⁷ showed that as little as 25 mL of pleural fluid (injected saline) on lateral erect chest radiograms could be detected as a subpulmonic accumulation of fluid in posterior costophrenic sulcus, but only with the presence of coexisting pneumo-peritoneum. This is less reliable in practice, so we proposed a finding of small meniscus sign in posterior costophrenic angle as a sign of small pleural effusion on lateral views. Some authors^{4,14} also suggested that the junction of the major fissure with the diaphragm may commonly be the site of small pleural effusions on lateral erect chest radiograms. The sign is described as a straight triangular shadow at the anterior diaphragmatic contour. We claim that it is difficult to interpret the sign without previous lateral chest x-rays and in the cases of superimposing fat in anterior mediastinum.

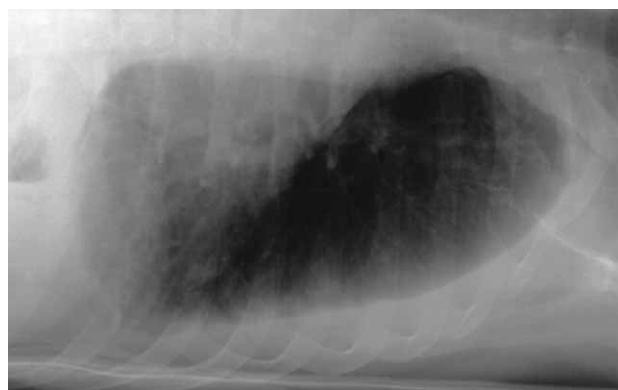
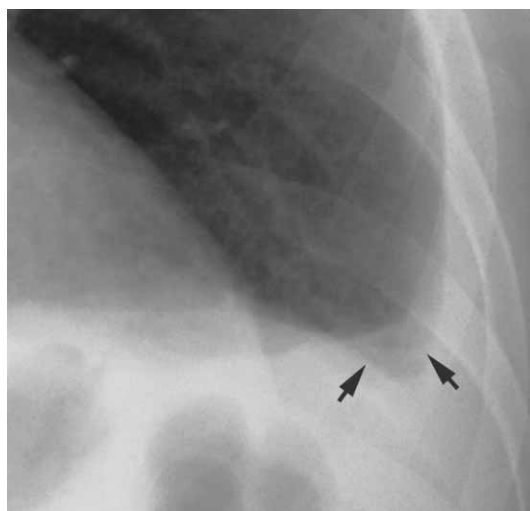

Fig. 1. a) Erect chest x-ray: a small meniscus sign in the left phrenicocostal sinus (arrows) b) left lateral decubitus view: more than 1,5 cm thick fluid layer – approximately 300 mL of pleural fluid (from Radiol Oncol 2005, 39(4): 237–42 with permission).

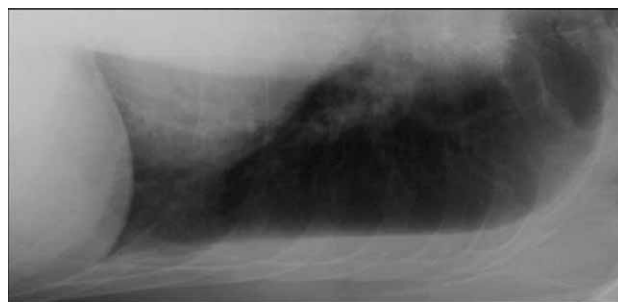
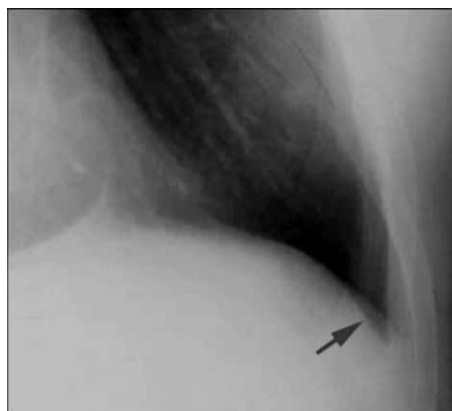
Fig. 2. a) only medial displacement of costophrenic angle on erect chest X-ray (arrows). b) about one cm thick fluid layer (approximately 200 mm of fluid) on the the left lateral decubitus view (with permission from Radiol Oncol 2005; 39(4): 237–42).

For many years chest radiographs in lateral decubitus position were used for the diagnosis of small pleural effusions. Rigler⁵ was the first one who described this examination. Few other investigators^{4,6} tried to improve the technique with exposure in expiration and with elevation of the patient's hip. Additionally they used central beam aimed at the lateral chest wall parallel to the expected fluid level. Müller and Löfstedt⁶ used the exposure in expiration, but although proofed efficient the technique apparently did not gain wider acceptance in the past. The study of Kocijančić et al.⁷ demonstrated that lateral decubitus views taken in expiration contributed significantly to the diagnostic sensitivity of radiological examination as the fluid layer thickness changed during inspiration-expiration in 80% of cases. This minimal improvement of the well-known technique facilitates the diagnosis of small pleural effusions and facilitates distinction between small pleural effusion and artefacts such as skin folds, sheets and subcutaneous fat. According to the data from cadaveric experiments²¹ the amount of pleural fluid detectable with this technique was as little as 5 mL. Since the results of thoracocentesis are not very exact²², this is less reliable in practice.

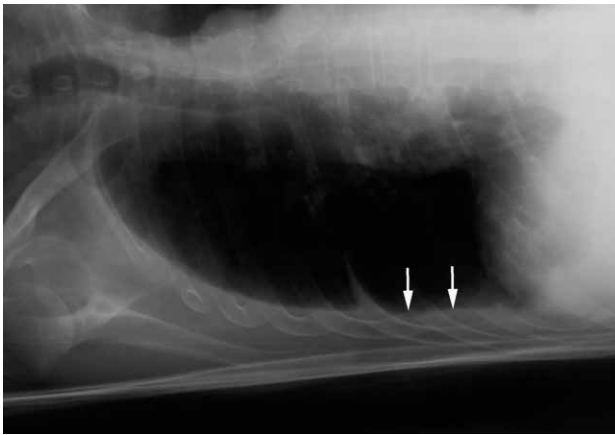


Fig. 3. One cm thick fluid layer of pleural fluid (arrows) in the right lateral decubitus position in a patient with cardiac failure.

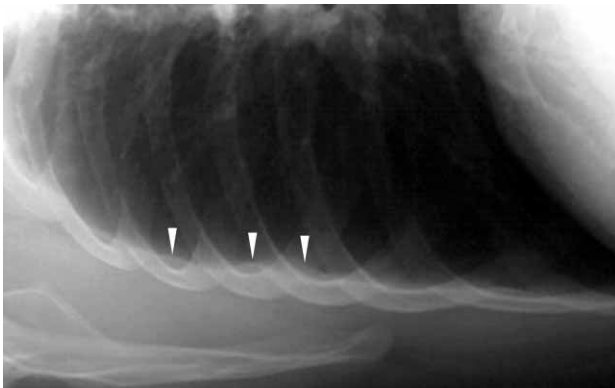

Fig. 4. Right lateral decubitus chest x-ray radiograph – in obese patient subpleural fat layer of at least 3mm can mimic free pleural fluid. Note typical »undulation« appearance of fat (arrowheads).

We are proposing new criteria for small pleural effusion in the lateral decubitus position. This includes fluid density from 3 mm to 15 mm in thickness, with horizontal air-fluid level at lateral dependent chest wall (Figure 3). The skin folds, sheets and subpleural fat can mimic thin fluid layer (Figure 4). Thinner densities are difficult to interpret.

Chest Ultrasonography

Ultrasonography (US) of pleural space became a leading real-time method for demonstrating small pleural effusions in last decades²³⁻²⁶. During examination US probe should be perpendicular to the thoracic wall. To identify the pleural effusion on sonography the fluid collection must be at least 3 mm thick anechogenic zone between the parietal and the visceral pleura. The fluid layer thickness is changing between expiration and inspiration and with different positions of the patient²³⁻²⁶.

In the comparative study Kocijančić et al.²⁶ tested chest US versus expiratory lateral decubitus radiography and showed both to be efficient methods for demonstrating small pleural effusions. However, US appear to assess the thickness of fluid layer more accurately than radiography does. Last but not least, this study showed the main sign, allowing the demonstration of the smallest effusions, was similar in both modalities: the fluid layer thickness changes during inspiration – expiration (Figure 5). The thickness of the fluid layer was between 3–15 mm with both examination modalities. The most frequent signs on erect chest radiograms were medial displacement of costophrenic angle and small meniscus sign – detected in 40% of the patients.

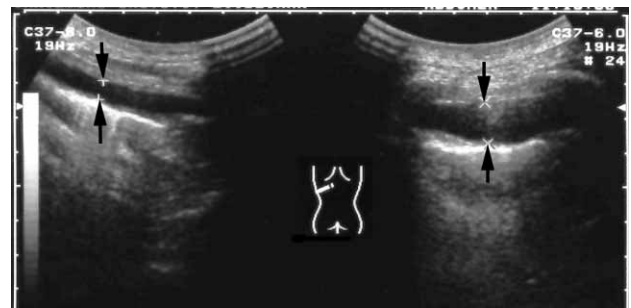

Fig. 5. Sonograms in a patient with right upper lobe lung cancer. Images show a thin (5 mm, arrows) fluid collection during inspiration (left image) that was more conspicuous (10 mm, arrows) during expiration (right image).

The sonographic examination of pleural spaces from behind, with the patient in sitting position is common. Kocijančić et al.²⁶ have introduced improved method of US examination in « elbow position ». This examination begins with a patient placed in lateral decubitus position for 5 minutes first (similar to lateral decubitus chest radiography), followed by US examination of the patient, while he/she is leaning on the elbow (Figure 6). The advantage of this technique is, that also small subpulmonic

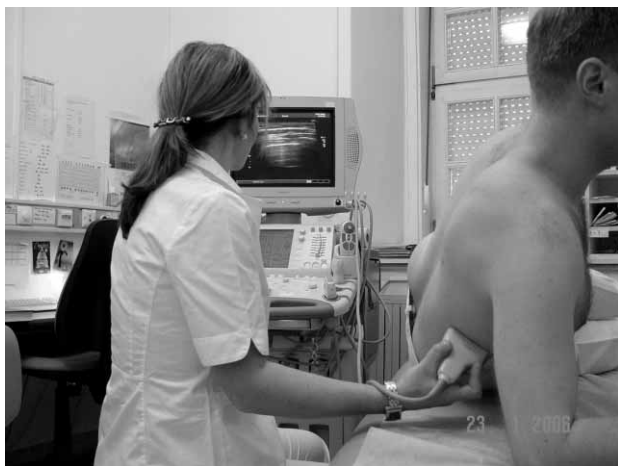

Fig. 6. Figure shows the »elbow position« with the placement of the transducer during examination of the right pleural space (courtesy of Ksenija Kocijančić).

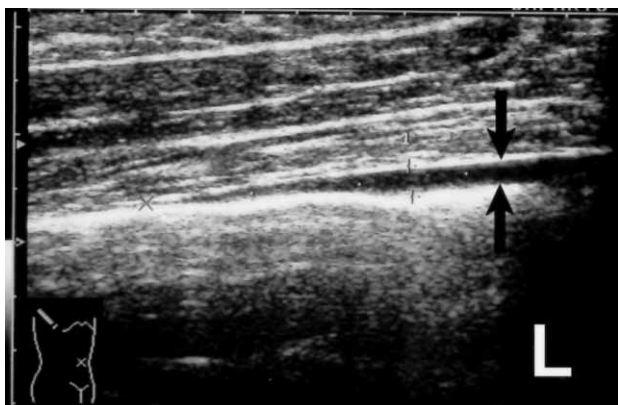

Fig. 7. Typical »wedge-shaped« appearance of physiologic pleural fluid in a person with »wet pleural space« (between arrows), L – liver.

effusions come in site by described manoeuvre as lateral fluid accumulation.

Wu and co-authors²⁷ described so-called »fluid colour« sign as a useful indicator for discrimination between pleural thickenings and pleural effusion and a diagnostic aid to grey scale US for minimal or loculated pleural effusions²⁸. According to our experience this sign is not a

reliable diagnostic marker when the amount of fluid is very small.

Imaging Physiologic Pleural Fluid

There are two articles^{4,6}, more than 50 years old, reporting the possibility detecting normal pleural fluid with lateral decubitus chest radiography. In 1951 Hesen⁴ reported that four percents of physiologic pleural fluid was detected by lateral decubitus chest radiography in 300 healthy persons and in 22% of healthy women after childbirth. In 1999 our study⁷ did not confirm Hesen's findings – in more than 100 health individuals. Using the same technique as Hesen, no signs of physiologic pleural fluid were found on lateral decubitus chest radiographs.

Four recent studies^{29–31} showed that physiologic pleural fluid is easy to detect by chest sonography in about of 25 to 30 percents of healthy individuals using the »elbow position« as previously described²⁶. In a small group of healthy pregnant women the percentage of positive findings raised up to 60%³². Furthermore these studies showed that the amount of pleural fluid is an individual characteristic and is stable³⁰. In some healthy persons with more physiologic pleural fluid, it becomes visible with chest sonography in phrenico-costal recesses.

This visible fluid layer measured from two to five millimeters (Figure 7). In these cases of so-called »wet pleural space«³⁰ chest sonography could be an important source of error in the diagnosis of pleural effusion, especially in healthy pregnant women. US is more accurate than chest radiography in demonstration of physiologic pleural fluid³³.

Conclusions

Recent studies lead us to redefine the nomenclature in the field of diagnostic imaging of small amounts of pleural fluid. We are suggesting that the term pleural fluid should determine physiologic pleural space condition. There is a »dry pleural space« and there is a »wet pleural space« in a healthy individual. The term pleural effusion should only be used in the cases of pleural involvement or pleural illness. In spite of all those investigations clear border between physiologic pleural fluid and pleural effusion remains still indeterminate.

REFERENCES

1. HENSCHKE CI, DAVIS SD, ROMANO P, YANKELEVITZ DF, Radiol Clin North Am, 27 (1989) 1241. — 2. BROADDUS C, STAUB NC, Semin Respir Med, 9 (1987) 7. — 3. NOPPEN M, DE WAELE M, LI R, GUCHT KV, D'HAESE J, GERLO E, VINCKEN W, Am J Crit Care Med, 162 (2000) 1023. — 4. HESSEN I, Acta Radiol, 86 suppl (1951) 1. — 5. RIGLER LG, JAMA, 104 (1931) 104. — 6. MÜLLER R, LÖFSTEDT S, Acta Med Scand, 122 (1945) 105. — 7. KOCIJANČIĆ I, TERELJ M, VIDMAR K, JEREB M, Clin Radiol, 54 (1999) 595. — 8. MATHIS G, Berlin-Springer-Verlag, (1992) 11. — 9. Mc Loud TC, Flower CDR, AJR, 156 (1991) 1145. — 10. MIKLOWEIT P, ZACHGO W, LÖRCHER U, MEIERSYDOW J, [in German] Bildgebung 58 (1991) 127. — 11. BÖRNER N,

KELBEL C, LORENZ J, WEILEMANN LS, MEYER J, [in German] Ultraschall Klin Prax, 2 (1987) 148. — 12. LORENZ J, BÖRNER N, NIKOLAUS HP, [in German] Ultraschall, 9 (1988) 212. — 13. RUDIKOFF JC, Chest, 77 (1980) 1092. — 14. PETERSEN JA, Radiology, 74 (1960) 34. — 15. DAVIS S, GARDNER F, QVIST G, Brit Med J, 1 (1963) 436. — 16. RAASCH BN, CARSKY EW, LANE J, AJR, 139 (1982) 899. — 17. COLLINS JD, BURWELL D, FURMANSKI S, LORBER P, STECKEL RJ, Radiology, 105 (1972) 51. — 18. KOHAN JM, POE RH, ISRAEL RH, Am Rev Respir Dis, 133 (1986) 1124. — 19. PETROVIC P, OSTOJIC L, PERIC I, MISE K, OSTOJIC Z, BRADARIC A, BOTA B, JANKOVIC S, TOCILJ J, Coll Antropol, 28 (2004) 711. — 20. ANZBOCK W, STELLAMOR

- K, BRAUN U, HRUBY W, [in German] Fortschr Rontgenstr, 153 (1990) 278. — 21. MOSKOWITZ H, PLATT RT, SCHACHAR R, MELLUS H, Radiology, 109 (1973) 33. — 22. KOCLJANCIC I, Radiol Oncol, 39 (2005), 237. — 23. MATHIS G, Ultrasound Med Biol, 23 (1997) 1131. — 24. KOCLJANCIC I, Radiol Oncol, 37 (2003) 13. — 25. RADIC R, NIKOLIC V, KARNER I, KURBEL S, SELTHOFER R, Coll Antrpol, 26 (2002) suppl. 59. — 26. KOCLJANCIC I, VIDMAR K, IVANOVIC-HERCEG Z, J Clin Ultrasound, 31 (2003) 69. — 27. WU RG, YUAN A, LIW YS, Am. J Respir Crit Care Med, 150 (1994) 510. — 28. SAVKOVIC A, NIKOLIC V, DELIC J, ISAKOVIC E, Coll Antrpol, 28 (2004) 701. — 29. KOCLJANČIĆ I, KOCLJANČIĆ K, ČUFER T, Clin Radiol, 59 (2004) 826. — 30. KOCLJANČIĆ K, KOCLJANČIĆ I, VIDMAR G, J Clin Ultrasound, 33 (2005) 386. — 31. KOCLJANČIĆ K, Coll Antropol, 31 (2007) in press. — 32. KOCLJANČIĆ I, KOCLJANČIĆ K, PUŠENJAK S, VIDMAR G, J Clin Ultrasound 33 (2005) 63. — 33. KOCLJANČIĆ I, Radiol Oncol 40 (2006) 1.

I. Kocijančić

*Clinical Institute of Radiology, University Medical Centre, Zaloška 7, SI – 1000 Ljubljana, Slovenia
e-mail: igor.koc@kclj.si*

DIJAGNOZA SLIKOVNIM METODAMA MALIH KOLIČINA PLEURALNE TEKUĆINE: PLEURALNI IZLJEV ILI FIZIOLOŠKA PLEURALNA TEKUĆINA

S A Ž E T A K

Male količine pleuralne tekućine izvanredno se teško pronalaze slikovnim metodama (rentgenskim slikanjem prsnog koša i ultrazvukom). Unatoč tome, one mogu biti od velikog značenja, jer se pomoću njih ponekad postavlja konačna dijagnoza pleuralne karcinomatize, upale ili drugih patoloških stanja. Dugo se u diagnostici malih pleuralnih izljeva koristio rentgenogram prsnih organa, pa se kroz više od 80 godina snimaka u bočnom položaju smatrao zlatnim standardom u pronalaženju malih nakupina pleuralne tekućine. U posljednjih 20 godina ultrazvuk pleuralnog prostora postao je vodeća slikovna dijagnostička metoda u pronalaženju malih nakupina pleuralne tekućine. Što više, suvremenom ultrazvučnom tehnologijom može se prikazati čak fiziološki prisutna pleuralna tekućina kod inače zdravih osoba. U zaključku pokazuje se potreba, da se u slikovnoj diagnostici malih količina tekućine u pleuralnom prostoru uvedu novi ključni pojmovi. Predlažemo, da se pojmom pleuralna tekućina obuhvati fiziološki prisutna tekućina u pleuralnom prostoru, a pojmom pleuralni izjev tekućina, koja je posljedica oboljenja pleure ili njene zahvaćenosti patološkim procesom.