



TRANSVENOUS APPROACH FOR INDIRECT CAROTID-CAVERNOUS FISTULA USING DETACHABLE COILS: A CASE REPORT AND REVIEW OF TREATMENT OPTIONS

Ante Rotim^{1,2,3}, Vladimir Kalousek⁴, Marina Raguž^{5,6,7}, Darko Orešković⁵, Filip Vrban¹, Ivan Brumini⁸ and Krešimir Rotim^{1,3,6}

¹Department of Neurosurgery, Sestre milosrdnice University Hospital Centre, Zagreb, Croatia;

²University of Applied Sciences Velika Gorica, Zagreb, Croatia;

³Josip Juraj Strossmayer University of Osijek, Faculty of Medicine, Osijek, Croatia;

⁴Department of Radiology, Sestre milosrdnice University Hospital Centre, Zagreb, Croatia;

⁵Department of Neurosurgery, Dubrava University Hospital, Zagreb, Croatia;

⁶University of Applied Health Sciences, Zagreb, Croatia;

⁷Catholic University of Croatia, School of Medicine, Zagreb, Croatia;

⁸Department of Radiology, Rijeka University Hospital Centre, Rijeka, Croatia

SUMMARY – Carotid-cavernous fistula (CCF) is a relatively rare pathology with a low incidence compared with other vascular pathologies. They can be classified based on hemodynamics as low- or high-flow fistulas, and anatomically as direct or indirect fistulas. Anatomy of the shunt somewhat dictates the selection of endovascular treatment, meaning the venous or arterial approach and selection of embolizing materials. Although there is general agreement as to when to access CCF transvenously or transarterially, which depends on the shunt being direct or indirect, there is no uniform agreement on which occlusion method should be used. Herein, we report a case of an 80-year-old woman treated for indirect CCF using detachable coils. We also provide a brief review of the literature, including recent advances in treatment of said entities. In conclusion, selection of both the approach and material used depends on the operator's experience and preference.

Keywords: *Carotid cavernous fistula; proptosis; endovascular treatment; neurosurgery; neurointerventions*

Introduction

Carotid-cavernous fistula (CCF) is a pathological vascular shunt between the internal or external carotid artery and the cavernous sinus. CCF was one of the earliest recognized intracranial vascular lesions¹. At first, it was proposed that the symptoms, including

proptosis, bruit and chemosis, were caused by intra-orbital aneurysms². It was not until years later that the correct etiology of the disease was determined, after performing a postmortem examination on patient with said symptoms³. Up to 75% of CCFs are traumatic, the rest being spontaneous, usually caused by cavernous carotid aneurysms⁴ or sinus thrombosis⁵. There are several treatment options depending on the patient's symptoms, characteristics of the fistula itself (high- or low-flow CCFs) and the success of possible previous treatment modalities. These modalities include conservative therapy, endovascular treatment if these fail, and surgery. Some variations of CCF, such

Correspondence to:

Ante Rotim, MD

Department of Neurosurgery, Sestre milosrdnice University Hospital Centre, Vinogradska cesta 29, Zagreb HR-10000, Croatia

E-mail: ante.rotim92@gmail.com

Received April 6, 2022, accepted August 16, 2022

as dural carotid cavernous fistulas, can be effectively treated with stereotactic radiosurgery⁶.

In this paper, we report a case of an 80-year-old woman with left-sided carotid-cavernous fistula. We also provide a brief review of the literature concerning endovascular treatment options for CCFs.

Case report

An 80-year-old female patient was admitted to the hospital following an ophthalmologic examina-

tion. The patient was referred to the examination due to periorbital pain, chemosis and proptosis of the left eye that had lasted for two months prior to the ophthalmologic examination. The patient also stated that she was also experiencing diplopia for the past month. She is also a diabetic (insulin treated) for the past 15 years and suffered from arterial hypertension. 20 years ago, she underwent CVI and was treated for left and right eye cataracts one year ago. Following admission, it was noted that the patient's left eye was not able to

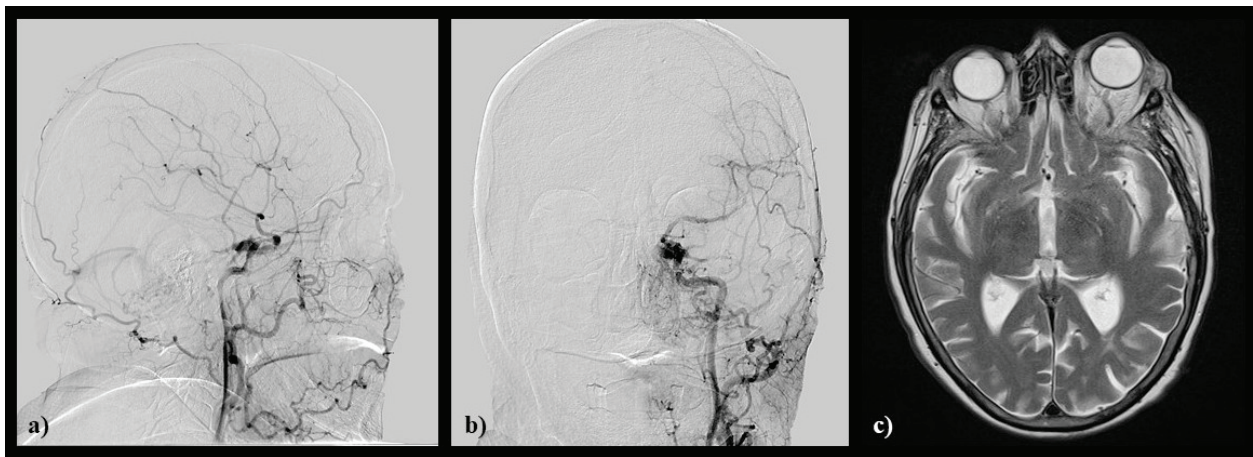


Fig. 1. Preoperative images: a) preprocedural DSA showing CCF with dilatated and retrogradely filled SOV, along with outflow from CCF to dilatated cortical cerebellar veins (LL projection), b) preprocedural DSA showing CCF with dilatated and retrogradely filled SOV, along with outflow from CCF to dilatated cortical cerebellar veins (AP projection), and c) MRI T2-sequence showing dilatated SOV on the left side with proptosis of the eye.

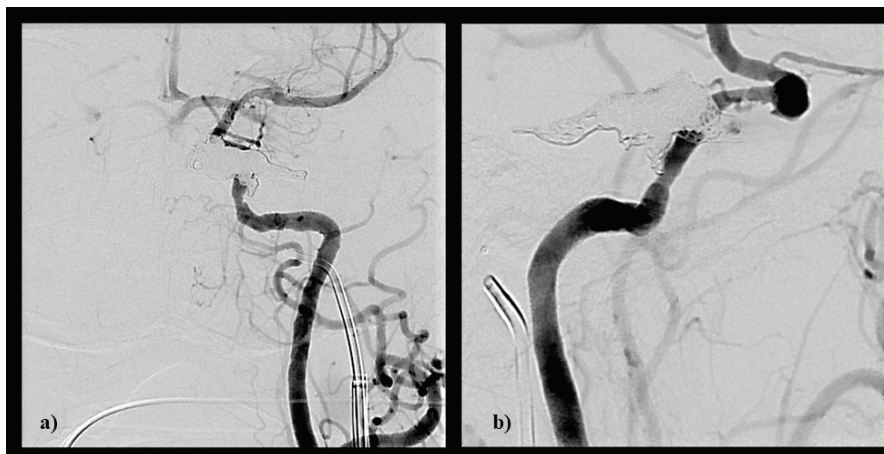

Fig. 2. Intraoperative imaging: a) intraprocedural DSA showing transvenous approach where the tip of 5F diagnostic catheter is in IPS and the microcatheter is in the cavernous sinus, which is in turn filled with coils (AP projection), and b) intraprocedural DSA showing transvenous approach where the tip of 5F diagnostic catheter is in IPS and the microcatheter is in the cavernous sinus which is in turn filled with coils (LL projection).

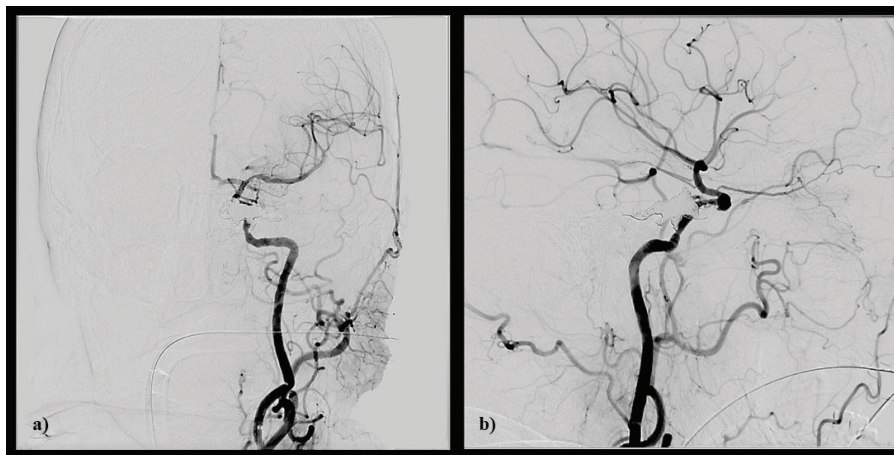


Fig. 3. Postoperative imaging: a) postprocedural DSA showing obliteration of CCF without SOV and cerebellar outflow veins presence (AP projection), and b) postprocedural DSA showing obliteration of CCF without SOV and cerebellar outflow veins presence (LL projection).

deviate the gaze to the left. DSA was conducted and revealed left-sided CCF with reflux into the cortical veins. A neurovascular board consisting of a neurosurgeon, neuroradiologist and neurologist decided the patient was eligible for neuroradiological intervention. The procedure was performed using the venous transfemoral approach, and femoral artery was used for guiding catheter placement for flow control. The guiding system was inserted into the femoral vein and was used to reach the jugular vein, and then a diagnostic 5F catheter was hooked to the foot of the inferior petrosal sinus (IPS) and the microcatheter was placed (Fig. 1); a microcatheter was then navigated into the cavernous sinus, which was obliterated using coils, along with the foot of the outflow superior ophthalmic vein (SOV), (Fig. 2). Heparin (3000 IU) was administered as a bolus after the procedure was completed. Control angiograms showed no active CCF (Fig. 3). The patient recovered well, with residual though milder proptosis and with no sign of chemosis. She was discharged 3 days after the procedure with a still persisting inability of directing the gaze leftwards. Likewise, diplopia remained, with the patients confirming it being milder in nature. Control magnetic resonance imaging (MRI) has been scheduled in 6 months, along with MR angiography.

Discussion

Currently, the first line treatment modality for most CCFs (all high and most low-flow fistulas) is endovascular intervention⁷. The obliteration of these

entities is done with either detachable balloons⁸, detachable coils⁹ or liquid embolics¹⁰ or a combination of both¹¹. Recently, endovascular covered stents and flow diverters have also been used to safely and effectively treat CCFs¹². Selection of the approach (transarterial or transvenous) method depends on vessel anatomy (patency of inferior petrosal sinus¹³) and the use of each of the techniques on the microanatomy and extent of the arterial defect. Detachable balloon occlusion has been a mainstay of endovascular CCF treatment for decades. The main advantage is occlusion of the fistula with preservation of ICA patency and relative ease of the transarterial approach. Drawbacks include the potential migration of the detached balloon into ICA due to postponed deflation or rupture¹⁴. The next technique to be developed was embolization with solid and liquid materials, and the combination of the two. Both can be performed using the arterial and/or venous approach. Given the various sizes of detachable coils and available catheters and wires, it is now easier to approach and occlude the varying sizes of carotid wall defects responsible for communication. However, this procedure is more expensive and lengthier in comparison with detachable balloon technique. The arterial approach carries a greater risk of coil migration and prevents denser packing, as opposed to the venous approach, because of greater distance to the siphon. This technique offers high occlusion rates, but there have been reports of persistent neurological deficits, both oculomotor and visual¹⁵, said to be due to coil mass effect. Other

possible complications include, as in detachable balloon occlusion, loss of ICA patency due to coil migration and ICA dissection. Liquid embolization is one of viable options for treating CCFs. Although reported rates of occlusion are high, there are possible complications including postembolization cavernous sinus thrombosis resulting in cranial nerve palsies and postprocedural penetration of arterial collaterals causing CVI¹⁰. Combination of liquid agents (Onyx) and solid materials (detachable coils) is also an option, especially for patients with large cavernous sinus and fistula ostium¹¹. There are also several other recent methods of occluding CCFs such as covered stents¹² and the Woven EndoBridge System¹⁶.

The transvenous approach is preferred for indirect CCFs and also serves as an alternative approach for direct CCFs. It has also been reported that selecting detachable coils over liquid embolics in the transvenous approach, as in our case, is the superior technique in comparison with any other⁶. The most common route of transvenous approach is through IPS, though alternative routes may be used if the one through IPS is not feasible. Such instances occur rarely, usually due to venous hypertension. Alternative routes include SOV, inferior ophthalmic vein, superior petrosal sinus, lateral pterygoid plexus and contralateral SOV or IPS. Some difficult cases require a combined surgical and endovascular approach¹⁷. We would also like to note that endovascular treatment is a legitimate treatment modality following complications of intracranial surgery causing iatrogenic carotid injury and subsequent CCF¹⁸.

In conclusion, the transvenous approach to the cavernous sinus via IPS and coil embolization of indirect CCFs is, in experienced hands, a safe and effective treatment option, with perhaps the least amount of possible complications in comparison with other methods of occlusion of the cavernous sinus, and should be first treatment option.

References

- Lang M, Habboub G, Mullin JP, Rasmussen PA. A brief history of carotid-cavernous fistula. *J Neurosurg.* 2017 Jun;126(6):1995-2001. doi: 10.3171/2016.5.JNS152372.
- Travers B. A case of Aneurism by Anastomosis in the Orbit, cured by the Ligature of the common Carotid Artery. *Med Chir Trans.* 1811;2:1-420.1. doi: 10.1177/095952871100200101.
- Dandy WE. Intracranial aneurysm of the internal carotid artery: cured by operation. *Ann Surg.* 1938 May;107(5):654-9. doi: 10.1097/00000658-193805000-00003.
- Ellis JA, Goldstein H, Connolly ES Jr, Meyers PM. Carotid-cavernous fistulas. *Neurosurg Focus.* 2012 May;32(5):E9. doi: 10.3171/2012.2.FOCUS1223.
- Kim CK, Shin JY, Chang JY, Lee SH. Spontaneous Carotid Cavernous Fistula in a Case with Protein S Deficiency that Newly Developed Ophthalmoplegia after Embolization. *J Clin Neurol.* 2011 Sep;7(3):164-7. doi: 10.3988/jcn.2011.7.3.164.
- Park SH, Park KS, Kang DH, Hwang JH, Hwang SK. Stereotactic Radiosurgery for Dural Carotid Cavernous Sinus Fistulas. *World Neurosurg.* 2017 Oct;106:836-843. doi: 10.1016/j.wneu.2017.04.143.
- Alexander MD, Halbach VV, Hallam DK, Cooke DL, Ghodke BV, Dowd CF, Amans MR, Hettis SW, Higashida RT, Meyers PM. Long-Term Outcomes of Endovascular Treatment of Indirect Carotid Cavernous Fistulae: Superior Efficacy, Safety, and Durability of Transvenous Coiling Over Other Techniques. *Neurosurgery.* 2019 Jul 1;85(1):E94-E100. doi: 10.1093/neuros/nyy486.
- Lewis AI, Tomsick TA, Tew JM Jr. Management of 100 consecutive direct carotid-cavernous fistulas: results of treatment with detachable balloons. *Neurosurgery.* 1995 Feb;36(2):239-44; discussion 244-5. doi: 10.1227/00006123-199502000-00001.
- Nishizawa T, Terada K, Matsuyama N. Transvenous detachable coil embolization of direct & high-flow carotid-cavernous fistula. Alternative of transarterial detachable balloon embolization. *Interv Neuroradiol.* 2000 Nov 30;6 Suppl 1(Suppl 1):117-24. doi: 10.1177/1591019900060S117.
- Elhammady MS, Wolfe SQ, Farhat H, Moftakhar R, Aziz-Sultan MA. Onyx embolization of carotid-cavernous fistulas. *J Neurosurg.* 2010 Mar;112(3):589-94. doi: 10.3171/2009.6.JNS09132.
- Yu Y, Li Q, Huang Q, Zhang Y, Fang Y, Xu Y, Hong B, Zhao W, Liu J. Embolization of direct carotid cavernous fistula with Onyx and coils under transarterial balloon protection. *Cardiovasc Intervent Radiol.* 2014 Jun;37(3):679-85. doi: 10.1007/s00270-013-0732-x.
- Li K, Cho YD, Kim KM, Kang HS, Kim JE, Han MH. Covered stents for the endovascular treatment of a direct carotid cavernous fistula: single center experiences with 10 cases. *J Korean Neurosurg Soc.* 2015 Jan;57(1):12-8. doi: 10.3340/jkns.2015.57.1.12.
- De Renzis A, Nappini S, Consoli A, Renieri L, Limbucci N, Rosi A, Vignoli C, Pellicanò G, Mangiafico S. Balloon-assisted coiling of the cavernous sinus to treat direct carotid cavernous fistula. A single center experience of 13 consecutive patients. *Interv Neuroradiol.* 2013 Sep;19(3):344-52. doi: 10.1177/159101991301900312.
- Korkmazer B, Kocak B, Tureci E, Islak C, Kocer N, Kizilkilik O. Endovascular treatment of carotid cavernous sinus fistula: A systematic review. *World J Radiol.* 2013 Apr 28;5(4):143-55. doi: 10.4329/wjr.v5.i4.143.
- Bink A, Goller K, Luchtenberg M, Neumann-Haefelin T, Dützmann S, Zanella F, Berkefeld J, du Mesnil de Rochemont R. Long-term outcome after coil embolization of cavernous sinus arteriovenous fistulas. *AJNR Am J Neuroradiol.* 2010 Aug;31(7):1216-21. doi: 10.3174/ajnr.A2040.

16. Tropine A, Moussa-Pacha A, Tritt S. Endovascular Treatment of a Direct Carotid Cavernous Sinus Fistula with the Woven EndoBridge Aneurysm Embolization System. *Clin Neuroradiol.* 2020 Dec;30(4):865-67. doi: 10.1007/s00062-020-00914-1.
17. Muram S, Khader Eliyas J, Eesa M, Mitha AP. Combined surgical and endovascular approach to treat a carotid cavernous fistula with associated brainstem venous congestion. *BMJ Case Rep.* 2017 Aug 28;2017:bcr2017013248. doi: 10.1136/bcr-2017-013248.
18. Iancu D, Lum C, Ahmed ME, Glikstein R, Dos Santos MP, Lesiuk H, Labib M, Kassam AB. Flow diversion in the treatment of carotid injury and carotid-cavernous fistula after transsphenoidal surgery. *Interv Neuroradiol.* 2015 Jun;21(3):346-50. doi: 10.1177/1591019915582367.

Sažetak

TRANSVENOZNI PRISTUP ZA INDIREKTNU KAROTIDNO KAVERNOZNU FISTULU KORISTEĆI ODVOJIVE ZAVOJNICE: PRIKAZ SLUČAJA I PREGLED METODA LIJEČENJA

A. Rotim, V. Kalousek, M. Raguz, D. Orešković, F. Vrban, I. Brumini i K. Rotim

Karotidno kavernoza fistula je relativno rijetka patologija s niskom incidencijom u odnosu na ostale vaskularne abnormalnosti. Hemodinamski se dijele na niskoprotokne i visokoprotokne, a anatomski na direktne i indirektne. Anatomija fistule određuje vrstu endovaskularnog tretmana, dakle arterijski ili venski pristup, kao i vrstu materijala kojom se vrši embolizacija. Iako postoji opći konsenzus oko primjene arterijskog ili venskog pristupa, ovisno o tome je li fistula direktna ili indirektna, ne postoji uniformni dogovor koja bi se metoda trebala koristiti u pojedinačnim slučajevima. Ovim radom smo prikazali slučaj osamdesetogodišnje bolesnice koja je liječena radi indirektno karotidno kavernoze fistule koristeći zavojnice. Također, prikazan je pregled literature i recentnog napretka u liječenju spomenutih entiteta. Zaključno, kako izbor pristup tako i izbor materijala ovise o iskustvu te preference operatera.

Ključne riječi: Karotidno kavernoza fistula, proptoza, endovaskularno liječenje, neurokirurgija, neurointervencija