

UNRECOGNIZED OCHRONOSIS – A CASE REPORT

Lucija Murgić, Frane Grubišić and Zrinka Jajić

University Department of Rheumatology, Physical Medicine and Rehabilitation, Sestre milosrdnice University Hospital, Zagreb, Croatia

SUMMARY – Alkaptonuria is a rare metabolic disorder characterized by a deficiency of the homogentisic acid oxidase enzyme. The result is accumulation of homogentisic acid in collagenous structures throughout the body, especially in fibrous and cartilaginous tissue. This leads to gradual development of a phenomenon known as ochronosis. Characteristic features of ochronosis are urine darkening, progressive scleral pigmentation, subcutaneous cartilage pigmentation (for example, ear cartilage and nails) and degenerative ochronotic arthropathy resembling osteoarthritis. In addition, cardiovascular and genitourinary systems are also affected. Alkaptonuric ochronosis is particularly interesting because it can be detected based only on clinical signs and medical history. Herein we present a patient with typical signs and symptoms such as darkening of urine, pigmented sclerae, nails and ear cartilage, manifesting arthritis in his fifth decade. Additional clinical examination indicated alkaptonuria, which was unrecognized in childhood.

Key words: *Alkaptonuria – diagnosis; Alkaptonuria – complications; Ochronosis – diagnosis; Ochronosis – complications; Pigmentation disorders – etiology; Arthritis – diagnosis; Case report*

Introduction

Alkaptonuria is a rare metabolic disease which is caused by a deficiency of the homogentisic acid oxidase enzyme¹. It affects collagenous structures resulting in progressive damaging of different body systems². There are few, but often neglected, characteristic clinical signs for alkaptonuria. The patient is usually asymptomatic until the third or fourth decade. After a long asymptomatic stage, the dominant and most troublesome symptom is severe arthropathy, which has detrimental influence on the patient's quality of life³. Currently, there is no specific and effective etiologic treatment, but essential is dealing with the symptoms and the patient's quality of life. Therefore, symptomatic and supportive therapy including physical therapy, nonsteroidal anti-inflammatory drugs, dietary restriction and appropriate anti-osteoporotic therapy are necessary to prevent further disability. In advanced cases, surgical replacement of

joints and aortic valves results in significant improvement.

Case Report

A 60-year-old male patient presented to our department complaining of a sudden onset of left knee inflammation. His medical history included the following data: at age 43, he had right heel aseptic necrosis and Achilles tendon rupture as the result of sudden foot movement, requiring surgical repair during which blue pigmented heel bone and tendon were found. The operation consisted of ablation of the necrotic bone, reconstruction (sec. Vulpius) and Achilles tendon fixation with a metal screw. At that time, no further diagnostic work-up was undertaken and no definitive diagnosis was made. From that time until his sixties, the patient did not contact physician regarding this issue although he sometimes suffered moderate heel pain. Scleral pigmentation on the left eye appeared at age 45, 13 years later also on the right eye, and in the meantime blue pigment on thumb nails and ear cartilage became visible (Figs. 1 and 2). He also reported that, since childhood,

Correspondence to: *Lucija Murgić, MD*, Iločka 3, HR-10000 Zagreb, Croatia

E-mail: *lucija.fabijanic@zg.t-com.hr*

Received May 5, 2008, accepted June 4, 2008

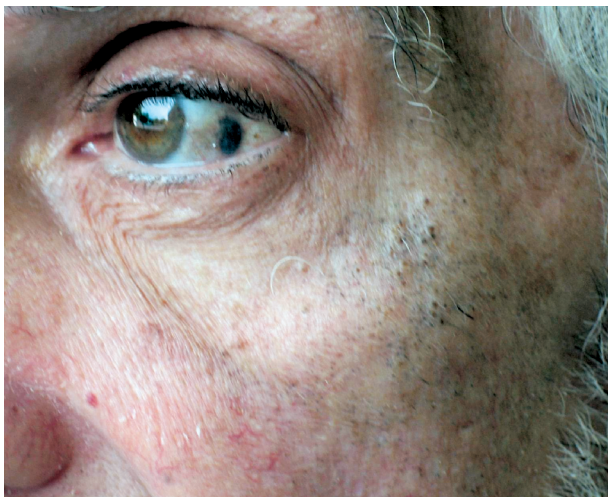


Fig. 1. Pigmented sclera.

his urine and sometimes his sweat left stains impossible to wash. He confirmed that his urine turned dark on staying on air. From age 57 he suffered chronic pain in his knees, low back and shoulders, especially during the night. His body height had decreased by 10 cm. On physical examination, obvious bluish black discoloration of his sclerae, thumb nails and ear skin was confirmed. Other findings included reduced cervical and lumbar lordosis, painful and increased spinal muscle tonus, kyphosis and muscle atrophy. Chest expansion index was 5 cm and modified Schober test 3 cm. Radiological evaluation of sacroiliac joints revealed bilateral sacroileitis, while spine x-ray showed diffuse advanced axial osteoarthritic degenerative changes and severe osteoporosis

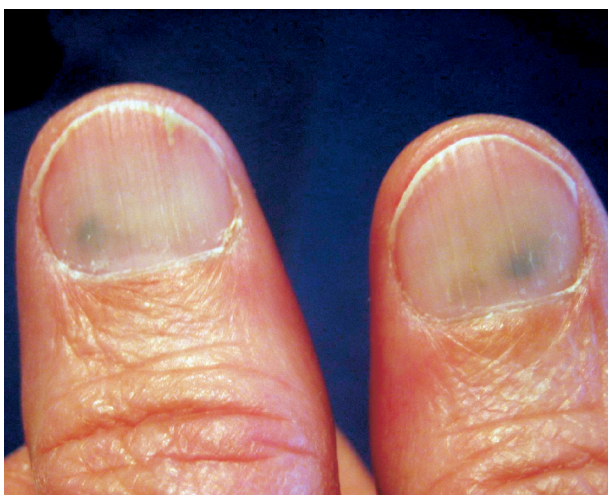

Figure 2. Pigmented thumb nails.

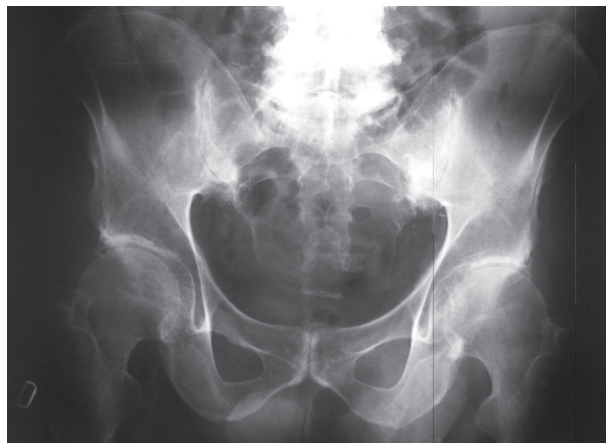

Fig. 3. Pelvis x-ray: mild bilateral hip osteoarthritis, bilateral asymmetric sacroileitis with narrowed intra-articular gap and reactive subchondral symphyseal osteosclerosis.

of the spine (Fig. 3). Magnetic resonance imaging (MRI) of the spine indicated severe deforming spondylosis and de-

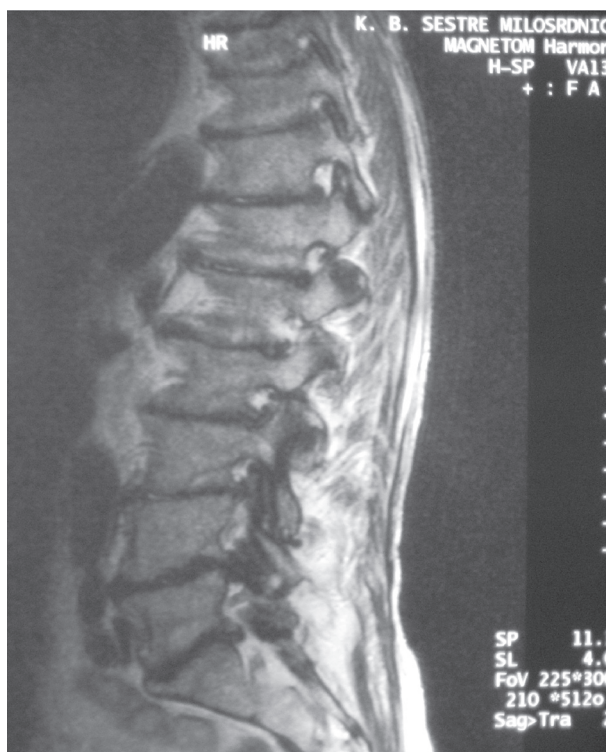

Fig. 4. Spine MRI indicated severe deforming spondylosis, degenerative changes of small joints, intervertebral disks with narrowed spinal canal and extrusion of osteophyte disk complex with reduction of intervertebral foramina in all segments of lumbar spine, especially L5-S1 segment.

generative changes of small joints and intervertebral disks with narrowed spinal canal. In all segments of lumbar spine, extrusion of the osteophyte disk complex was observed, with reduction of intervertebral foramina, most pronounced in L5-S1 segment (Fig. 4). Arthritic changes were also found in both knees and shoulders. Heart ultrasound showed mild degenerative changes of both aortic and mitral valves with mild mitral regurgitation. Routine laboratory analyses including complete blood count, erythrocyte sedimentation rate, C-reactive protein, urea, creatinine, uric acid, liver function tests, calcium, phosphate as well as urinalysis were within the normal ranges. Rheumatoid factor and HLA-B27 were negative. Urine chromatography confirmed the presence of large amounts of homogentisic acid. Finally, the diagnosis of ochronosis was made.

Discussion

Alkaptonuria is a rare metabolic disease (about 1:250,000)¹⁻³, although in some areas such as Slovakia and the Dominican Republic, the incidence is much higher⁴. One of the first symptoms is darkening of the urine upon standing because homogentisic acid excreted in urine turns dark brown or black upon oxygenation and alkalization⁴. Apart from the above phenomenon, the patient is usually asymptomatic until the third or fourth decade of life¹. Deposition of oxidized and polymerized homogentisic acid occurs throughout the body, especially in fibrous and cartilaginous tissue⁴. This leads to gradual development of a phenomenon known as ochronosis (a brownish black melanin-like pigmentation of the nails, sclerae, cartilages, joints, etc.) after 20 to 30 years of age². Degenerative ochronotic arthropathy resembling osteoarthritis, a particularly troublesome feature, appears insidiously usually in the fourth decade of life^{1,4}. There is involvement of spinal and weight-bearing joints like hips and knees as well as shoulders. Findings often include joint effusions, synovitis and ligament tears^{2,4}. Joint inflammation could be attributed to inflammatory reaction of the ochronotic fragment in the synovial membrane⁵. There are also many extra-articular manifestations of alkaptonuria, such as alkaptonuric depositions throughout the cardiovascular system, resulting in valvular dystrophic calcification, aortic stenosis and coronary disease⁴. In the genitourinary system the main manifestations are calculus formation and urine discoloration. But most obvious is widespread dusky discoloration of the skin of the cheeks, forehead, axillae

and genitalia⁶. One life-table analysis showed that joint replacement due to severe arthropathy was performed at a mean age of 55 years and that renal stones developed at 64 years, cardiac valve involvement at 54 years, and coronary artery calcification at 59 years of age².

*Clinical features in alkaptonuria*⁷

- Dark urine
- Scleral pigmentation
- Subcutaneous cartilage pigmentation
- Arthritis, kyphosis, osteoporosis
- Rupture of tendons and ligaments
- Renal, urinary bladder and prostatic calculi
- Inflammation, fibrosis, calcification of cardiac valves

The diagnosis of alkaptonuria is made by documenting homogentisic aciduria. Previously, the diagnosis was often made early in life as nappies turned black⁷. Although diagnostic confirmation of alkaptonuria is easily made by quantitative determination of homogentisic acid in urine, only 21% of patients are diagnosed before 1 year of age^{2,4}. In one survey, out of 755 respondents, only 43% correctly diagnosed alkaptonuric ochronosis, while 23% thought of melanoma and 23% of porphyria or porphyria cutanea tarda⁸.

Currently, there is no specific and effective etiologic treatment, but the physician's holistic approach is essential in dealing with the symptoms and patient's quality of life. Supportive therapy like nonsteroidal anti-inflammatory drugs and physical therapy is used for arthropathy. However, the average life span of patients remains unchanged and they die of the causes comparable with the general population^{1,2,4}. Nitisinone, a potent inhibitor of 4-hydroxyphenylpyruvate dioxygenase, dramatically reduces the production and urinary excretion of homogentisic acid; however, the long-term efficacy and side effects of such therapy are unknown. Identifying the gene for alkaptonuria offers the potential for a new therapeutic approach, replacement therapy with a recombinant enzyme⁴.

In advanced cases, surgical replacement of joints and aortic valves results in significant improvement. Regarding surgical intervention in ochronosis patients, almost all patients need orthopedic surgery, and the mean age at joint replacement is 55 years⁹. There are some reports such as one series of 58 ochronosis patients where 8 (13.8%) had three or more joints replaced. In the same series, 3 (5.2%) had aortic valve replacement, while 50% had computed tomography evidence of coronary artery calcification by 59 years of age². There are two other

reports on four total joint replacement arthroplasties in an ochronosis patient and one report on even seven joint replacements in a single patient¹⁰⁻¹². Besides surgery, physiotherapy, analgesia and appropriate anti-osteoporotic therapy are essential to prevent further disability.

Patient management plan

- Discuss with patients their needs, worries, thoughts and hopes
- Consider future disability issues (joint and heart valve surgery)
- Pain management
- Dealing with risk factors (osteoporosis, progressive atherosclerosis)
- Genetic counseling
- Dietary advice
- Exercise (passive – transcutaneous electrical nerve stimulation, active-swimming, cycling, walking)
- Coordination of different specialist recommendations

Conclusion

Patients with alkaptonuria are often treated under wrong diagnosis and they undergo unnecessary and expensive diagnostic procedures. The diagnosis and management of patients with alkaptonuric ochronosis is complex because it is a rare disease with multiple system involvement. Even though there is no specific and effective etiologic treatment or prevention, ochronotic patients can benefit from an early diagnosis since early recognition and appropriate symptomatic treatment may significantly improve the quality of life in these patients. Advances in orthopedic and cardiac surgery have enabled many patients to overcome progressive disability.

References

1. VERMA SB. Early detection of alkaptonuria. *Indian J Dermatol Venereol Leprol* 2005;71:189-91.
2. PHORNPHUTKUL C, INTRONE WJ, PERRY MB, BERNARDINI I, MURPHEY MD, FITZPATRICK DL, ANDERSON PD, HUIZING M, ANIKSTER Y, GERBER LH, GAHL WA. Natural history of alkaptonuria. *N Engl J Med* 2002;347:2111-21.
3. KOTTINEN YT, HOIKKA V, LANDTMAN M, SAARI H, SANTAVIRTA S, METSARINNE K, SEEGMILLER JE. Ochronosis: a report of a case and a review of literature. *Clin Exp Rheumatol* 1989;7:435-44.
4. FISHER AA, DAVIS MW. Alkaptonuric ochronosis with aortic valve and joint replacements and femoral fracture: a case report and literature review. *Clin Med Res* 2004;2:209-15.
5. MANNONI A, *et al.* Alkaptonuria, ochronosis and ochronotic arthropathy. *Semin Arthritis Rheum* 2004;33:239-48.
6. LUBICS A, SCHNEIDER I, SEBOK B, HAVASS Z. Extensive bluish gray skin pigmentation and severe arthropathy. Endogenous ochronosis (alkaptonuria). *Arch Dermatol* 2000;136:548-52.
7. MISHRA V, RANGANATH LR. Pigmented sclera: a diagnostic challenge? *Postgrad Med J* 2004;80:491.
8. NIKKELS AF, PIERARD GE. Medical mystery: the answer. *N Engl J Med* 2001;344:1642-3.
9. Van OFFEL JF, De CLERCK LS, FRANCX LM, STEVENS WJ. The clinical manifestations of ochronosis: a review. *Acta Clin Belg* 1995;50:358-62.
10. CARRIER DA, HARRIS CM. Bilateral hip and bilateral knee arthroplasties in a patient with ochronotic arthropathy. *Orthop Rev* 1990;19:1005-9.
11. DEMIR S. Alkaptonuric ochronosis: a case with multiple joint replacement arthroplasties. *Clin Rheumatol* 2003;22:437-9.
12. JAGOSE JT, BAILEY RR, ROTHWELL AG. Alkaptonuria with ochronotic nephropathy and multiple joint replacements for ochronotic arthropathy. *N Z Med J* 1997;110:235-6.

Sažetak

NEPREPOZNATA OHRONOZA – PRIKAZ SLUČAJA

L. Murgić, F. Grubišić i Z. Jajić

Alkaptonurija je rijedak poremećaj metabolizma koji nastaje zbog manjka oksidaze homogentizinske kiseline. Posljedica toga je nakupljanje homogentizinske kiseline u kolagenskim strukturama cijelog tijela, osobito u fibroznim i hrskavičnim tkivima. To postupno uzrokuje nastajanje pojave nazvane ohronoza. Ona podrazumijeva znakovite promjene poput tamnjenja boje mokraće, progresivne pigmentacije bjeloočnice, pigmentacije potkožne hrskavice (na primjer, hrskavice na uškama i noktima) te degenerativne ohronotske artropatije nalik osteoartritisu. Uz to, zahvaćeni su i kardiovaskularni i genitourinarni sustavi. Bolesnik je obično bez simptoma do trećeg ili četvrtog desetljeća života. Zasad ne postoji specifično i djelotvorno etiološko liječenje, ali je važno primjereno zbrinjavati simptome i brinuti se o bolesnikovoj kvaliteti života. U težim slučajevima moguća je kirurška zamjena zglobova i aortnih zalistaka. Fizioterapija, analgezija i primjerena antiosteoporotska terapija su neophodni za sprječavanje invalidnosti. Navedeni poremećaj je zanimljiv, jer se može jednostavno otkriti samo na osnovi pojedinosti iz povijesti bolesti i kliničkih znakova.

Ključne riječi: *Alkaptonurija – dijagnostika; Alkaptonurija – komplikacije; Ohronoza – dijagnostika; Poremećaji pigmentacije – etiologija; Artritis – dijagnostika*

