

Virtual Bronchoscopy and 3D Spiral CT Reconstructions in the Management of Patient with Bronchial Cancer – Our Experience with Syngo 3D Postprocessing Software

Višeslav Ćuk¹, Stanko Belina², Rajko Fureš³, Damir Buković⁴, Daniel Lovrić⁵ and Ivana Šešo⁴

¹ Department of Otorhinolaryngology, General Hospital Zabok, Zabok, Croatia

² Department of Radiology, Special Hospital Krapinske Toplice, Krapinske Toplice, Croatia

³ Department of Obstetrics and Gynaecology, General Hospital Zabok, Zabok, Croatia

⁴ Department of Obstetrics and Gynaecology, University Hospital Center »Zagreb«, Zagreb, Croatia

⁵ Department of Cardiovascular Diseases, University Hospital Center »Zagreb«, Zagreb, Croatia

ABSTRACT

Multislice helical CT generated virtual bronchoscopy (VB) represents one of the most recent developments in three-dimensional computer aided visualisation techniques. VB allows non-invasive and relatively accurate 3D evaluation of tracheobronchial tree. We performed virtual bronchoscopy and in-space 3D volume analysis on CT-data set acquired from sixty-four-year old male with bronchial cancer in order to demonstrate advantages and disadvantages of these methods in diagnostics and preoperative management of metastatic bronchial cancer. Siemens Somatom Emotion 16 helical CT scanner was used for data acquisition. Data post-processing was done with 3D Syngo 2006G software package from Siemens medical systems. CT scanning of the thorax was performed in heavy smoker with an expansive T4N1M1 malignant process in a superior lobe of the right lung accompanied with large metastatic lesion attached on the right lateral chest wall. Metastatic lesions were also found in vertebral column. In-space 3D analysis followed with virtual bronchoscopy had revealed obstruction of apical branch of superior lobe segmental bronchus. External compression done by tumor to the superior segmental and right main bronchus was found. We concluded that multi-slice CT in connection with VB became a possible non-invasive alternative to bronchoscopy, if tissue samples are not required.

Key words: virtual bronchoscopy, high resolution computer tomography, bronchial cancer, CT image postprocessing

Introduction

Classical endoscopic procedures performed with rigid or flexible endoscopes are invasive and often uncomfortable for patients. Some of them may have serious side effects such as perforation, infection and hemorrhage. Virtual endoscopy (VE) is a new method of diagnosis using computer processing of 3D image datasets (such as CT or MRI scans) to provide simulated visualizations of patient specific organs similar or equivalent to those produced by standard endoscopic procedures^{1,2}. Virtual endoscopy visualization avoids the risks associated with real endoscopy, and when used prior to performing an actual endoscopic exam can minimize procedural difficulties and decrease the rate of morbidity, especially for endoscopists in training¹. The history of VE is a relatively brief one. It

is a new technology in diagnostic medical imaging. VE derives principally from digital medical imaging, and in particular from visualization of 3D CT and MRI datasets.

A number of investigators have been working in this field. Some of the earliest work was published by Vining³ on virtual colonoscopy, Robb⁴ who began with patient specific 3D organ visualizations and progressed to interactive organ fly-throughs and Hara and Johnson⁵ who have published early clinical observations in the colon.

Virtual bronchoscopy is the descriptive term given to representations of the bronchial tree and surrounding structures created from spatial information derived from imaging sources other than the bronchoscope itself⁶. The

accuracy of virtual bronchoscopy techniques with real bronchoscopy findings is high^{7,8} and this will improve further as CT scanning protocols improve. In comparison with fiberoptic bronchoscopy, virtual bronchoscopy offers the advantage of being able to visualize areas beyond even high-grade stenoses. In addition to the limited view of fiberoptic bronchoscopy, extraluminal causes of lumen compressions can be analyzed in the cross-sectional images and evaluated together with the virtual representation. However, it was not possible to detect small infiltrations with virtual bronchoscopy⁹, therefore the usage of virtual bronchoscopy as a diagnostic tool is limited, since detailed information on the mucosa is not available, thus tumors limited to that areas cannot be detected easily¹⁰.

CT of the lung produces two-dimensional images (a cross-section of the thorax at the slice point) with the minimal x,y resolution in this image referred to as a »pixel« and the depth of the slice adding a z direction to that pixel; this volumetric minimal resolution image is referred to as a »voxel.«. Current CT scanners (64 multi-row detector CT devices [MDCT]) now produce x,y and z resolutions of the order of 0.6 mm. If these two-dimensional x,y slices are stacked one on top of the other, maintaining their alignment, then it becomes very clear that a high-resolution three-dimensional image of the thorax can be obtained. This three-dimensional image contains all of the structures within the thorax, including the airways (where there is natural contrast between tissue and air), the mediastinal blood vessels (where, with contrast injection, there is discrimination between blood vessels and other soft tissue¹¹.

Subject and Methods

Axial helical CT scans of the thorax from the level of the proximal trachea in the lower neck through the lung bases were obtained at end-inspiration in 64-year-old male who suffered from bronchial cancer of the right superior lobe. Several metastatic lesions were also found in right lateral thoracic wall, vertebral column and liver. Siemens Somatom Emotion 16 CT scanner was used for image acquisition. CT images were stored in DICOM format and transferred to Xeon-based workstation running standard postprocessing software 3D Syngo CT 2006G from Siemens Medical Systems. Initial postprocessing was performed by one radiologist and one ENT specialist working together on In-space and Fly-through software. Working area during fly-through was divided in four windows showing CT image reconstruction in three major planes and resulting 3D rendered virtual endoscopic view for current position of virtual endocamera. Fly-through path planning was performed by moving mouse pointing device. Recordings of virtual bronchoscopic images together with appropriate CT images in three major planes during fly-through was performed with Camtasia recorder in real-time.

3D Syngo CT 2006G is the new overall platform for the imaging workstation of Siemens Medical Systems. The volume rendering functionality is based on Tera-

Recon's VolumePro technology (originally developed by Mitsubishi Electric Research Labs). On the Virtuoso, an earlier version of the Siemens imaging workstation, volume rendering was done using 2D texture mapping. Virtual endoscopy on the Syngo platform is performed using ray casting method with space leaping as major acceleration technique. It also provides an automatic navigation mode.

Results

Helical CT images were acquired from sixty-four-year old heavy smoker who was referred to our hospital with history of intensive low back pain during last two months. Pain was also present at the right side of the chest where he noticed a swelling attached to one rib. He also suffered occasional dyspnea and cough attacks. Standard chest X-rays were performed during initial management. Consolidation due to expansive malignancy was found in the projection of superior lobe of the right lung. Lymph nodes in right hilus were also enlarged.

3D In space volume rendering was performed in order to show fine structure of lung parenchyma (red), trachea, right main bronchus and smaller segmental bronchi (light red), primary cancer obstructing and compressing superior lobar and apical segmental bronchus (grey). Large metastasis 40x70 mm was also shown on the lateral chest wall subpleurally. It was attached to one rib and rib destruction was shown (Figure 1). Dislocation of bronchi due to extraluminal compression in the projection of primary cancer, as well as compression of the right inferior lobe with large metastasis within thoracic wall was shown on Figure 2. In space 3D presentation of ventilation of small alveolar spaces was demonstrated on

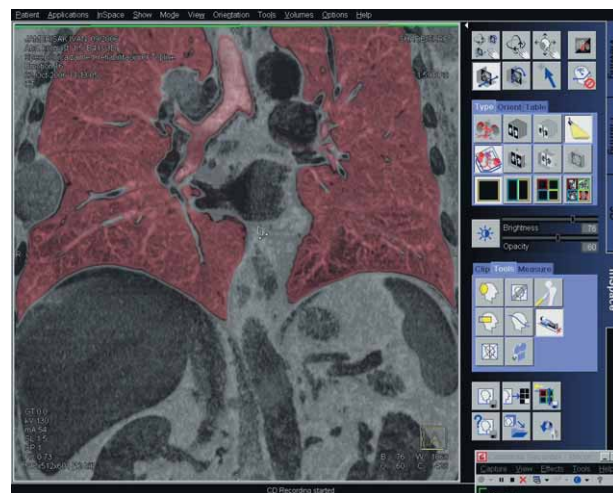


Fig. 1. 3D In space volume rendering was performed in order to show fine structure of lung parenchyma (red), trachea, right main bronchus and smaller segmental bronchi (light red), primary cancer obstructing and compressing superior lobar and apical segmental bronchus (grey). Large metastasis 40x70 mm was also shown on the lateral chest wall subpleurally. It was attached to one rib and rib destruction.

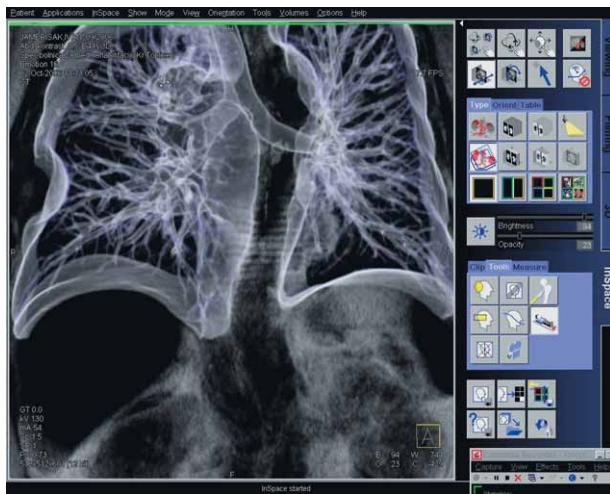


Fig. 2. Figure presents 3D In space volume rendering semitransparent reconstruction of tracheobronchial tree. Dislocation of bronchi due to extraluminal compression in the projection of primary cancer, as well as compression of the right inferior lobe with large metastasis within thoracic wall was shown.

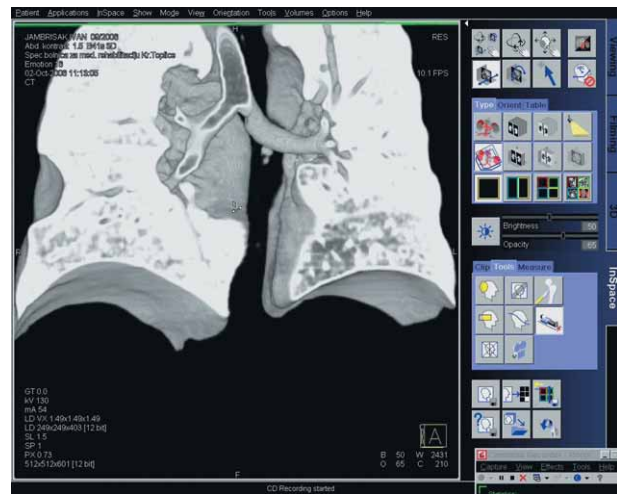

Fig. 4. In space 3D reconstruction of pulmonary parenchyma (white). Primary tumor and large metastasis were shown as defect in parenchyma volume caused by compression.

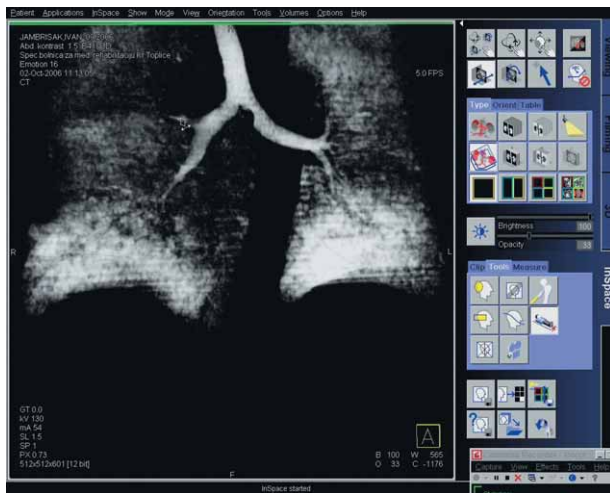

Fig. 3. In space 3D presentation of ventilation of small alveolar spaces. Good ventilation was presented as white. Almost whole upper third of right lung was poor ventilated due to compression and obstruction caused by primary cancer.

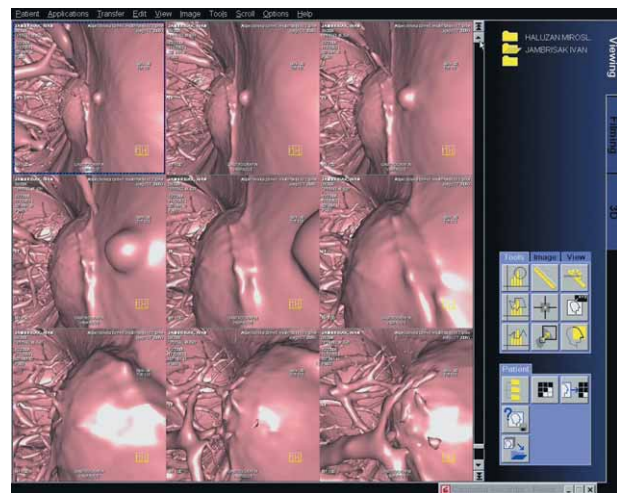


Fig. 5. Fly-through within the right pleural space near the lateral chest wall (lung tissue eliminated). Position of large metastasis and one small satellite subpleural metastasis was shown as well as blood vessels irrigating large metastasis.

Figure 3. Good ventilation was presented as white. Almost whole upper third of right lung was poor ventilated due to compression and obstruction caused by primary cancer. Figure 4 presents in space 3D reconstruction of pulmonary parenchyma (white). Primary tumor and large metastasis were shown as defect in parenchyma volume caused by compression. Fly-through within the right pleural space near the lateral chest wall (lung tissue eliminated) was presented on Figure 5. Position of large metastasis and one small satellite subpleural metastasis was shown as well as blood vessels irrigating large metastasis.

Figure 6. Virtual endoscopy reconstruction. View directed towards superior lobar bronchus and three segmental bronchi. External compression with tumor. After stenosis, openings of apical, posterior and anterior segmental bronchus were shown.

Position of virtual camera within all three major planes inside the superior lobar bronchus and 3D reconstruction of view to three segmental bronchus was shown of Figure 7. Fly-through 3D reconstruction was presented on Figure 8. Virtual camera is situated outside the bronchi within pulmonary parenchyma and parenchyma was eliminated by program. The surface of primary tu-

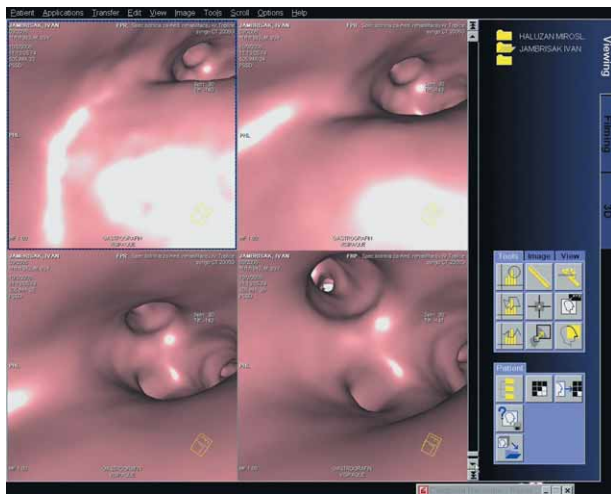


Fig. 6. Virtual endoscopy reconstruction. View directed towards superior lobar bronchus and three segmental bronchi. External compression with tumor. After stenosis, openings of apical, posterior and anterior segmental bronchus were shown.

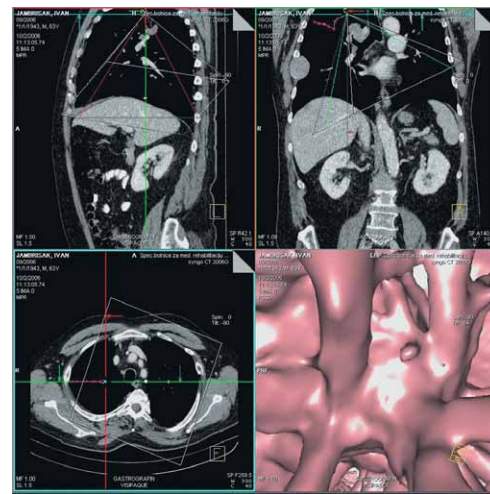


Fig. 8. Fly-thru 3D reconstruction. Virtual camera is situated outside the bronchi within pulmonary parenchyma and parenchyma was eliminated by program. The surface of primary tumor was revealed as well as blood vessels.

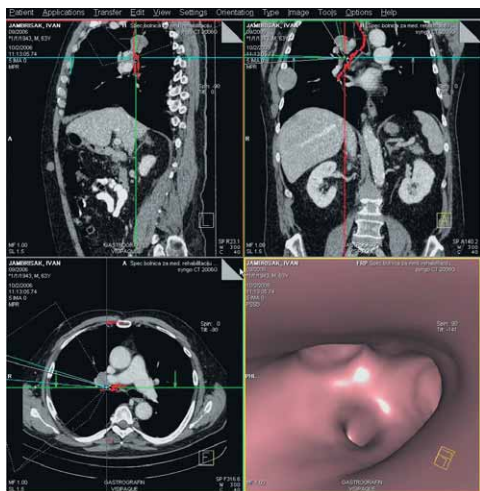


Fig. 7. Position of virtual camera within all three major planes inside the superior lobar bronchus and 3D reconstruction of view to three segmental bronchi.

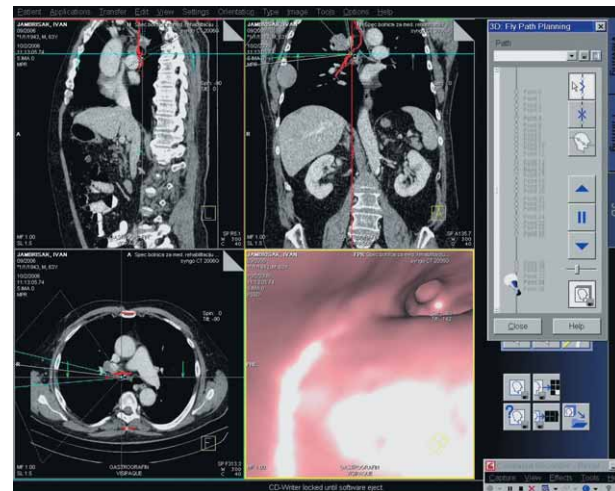


Fig. 9. Virtual camera was located within the right main bronchus and looking forward through superior lobar bronchus to opening of one segmental bronchus.

mor was revealed as well as blood vessels. At the Figure 9 virtual camera was located within the right main bronchus and looking forward through superior lobar bronchus to opening of one segmental bronchus.

Fly-through view to metastases on lateral chest wall and virtual camera position within the main three planes was shown of Figure 10.

Discussion

Advances in computer technology have permitted development of virtual reality images of the tracheobronchial tree using data sets derived from helical CT of the chest. The current gold-standard to identify the respective

lung parenchyma and airways is computed tomography (CT) that is performed prior to a bronchoscopy. Classical fiberoptic bronchoscopy remains tool for inspections of the trachea and central bronchi and deriving tissue samples.

Several studies^{12,13} have shown that VB can accurately show the lumen and diameter of the trachea, the left and right mainstem bronchi, and the bronchial tree down to the fourth order of bronchial orifices and branches.

VB is being increasingly used to evaluate central airway disease and especially to detect benign and malignant airway stenosis^{14,15}. VB estimates of the grade of tracheobronchial stenosis resulting from either endobronchial pathology or external compression were found to be correlated with findings on flexible bronchoscopy¹⁶

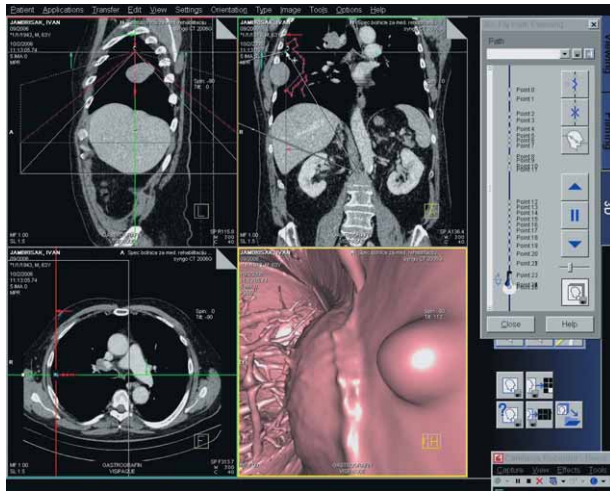


Fig. 10. Fly-through view to metastases on lateral chest wall and virtual camera position within the main three planes.

Another potential role for VB is evaluation of bronchogenic carcinoma. Finkelstein et al¹⁷ found that VB had a sensitivity of 100% for the detection of obstructive lesions and of 83% for detection of endoluminal non-obstructive lesions; however, its sensitivity for mucosal abnormalities was 0% and specificity was 100%.

Using VB, clinicians can appreciate not only the intraluminal proliferation of the tumor but also the extraluminal extension of the mass and its relation to the bronchial tree. However, because VB is unsuitable for the detection of subtle mucosal lesions, it cannot be used to identify premalignant lesions in the respiratory tract¹⁷

Nevertheless, VB may provide important diagnostic and potentially therapeutic information before classical bronchoscopy or before surgery.

Thanks to recent technological advances in medical imaging, physicians can now use volumetric chest CT for tridimensional exploration of the bronchial tree¹⁸, what we also demonstrated on Figure 1, 2, 3 and 4.

REFERENCES

1. ROBB RA, Comput Med Imaging Graph, 24 (2000) 133. — 2. WICKHAM JE, BMJ, 308 (1994) 193. — 3. VINNING DJ, Gastrointest Endosc Clin N Am, 7 (1997) 285. — 4. ROBB RA, HANSON DP, Australas Phys Eng Sci Med, 14 (1991) 9. — 5. HARA AK, JOHNSON CD, REED JE, AHLQUIST DA, NELSON H, MACCARTY RL, HARMSSEN WS, ILSTRUP DM, Radiology 205 (1997) 59. — 6. FERGUSON JS, MCLENNAN G, Proc Am Thorac Soc 2 (2005) 488. — 7. LIEWALD F, LANG G, FLEITER T, SOKIRANSKI R, HALTER G, OREND KH, Thorac Cardiovasc Surg, 46 (1998) 361. — 8. FINKELSTEIN SE, SUMMERS RM, NGUYEN DM, STEWART JHT, TRETTLER JA, SCHRUMP DS, J Thorac Cardiovasc Surg, 123 (2002) 967. — 9. FLEITER T, MERKLE EM, ASCHOFF AJ, LANG G, STEIN M, GOERICH J, LIEWALD F, RILINGER N, SOKIRANSKI R, AJR, 169(1997) 1591. — 10. ROGALLA P, RUCKERT JC, SCHMIDT B, WITT C, MEIRI N, HAMM B, Radiologe, 41 (2001) 261. — 11. FERGUSON JS, MCLENNAN G, Proc Am Thorac Soc 2 (2005) 488. — 12. POLVEROSI R, VIGO M, BARON S, ROSSI G, Radiol Med, 102 (2001) 313. — 13. AQUINO SL, VINING DJ, Clin Chest Med, 20 (1999) 725. — 14. ROGALLA P, MEIRI N, Virtual endoscopy of the trachea and bronchi. In: ROGALLA P (Ed), Virtual endoscopy and related 3D techniques. (Springer, Berlin, 2001). — 15. HOPPER KD, IYRIBOZ AT, WISE SW, NEUMAN JD, MAUGER DT, KASALES CJ, Radiology, 214 (2000) 517. — 16. HOPPE HR, WALDER B, SONNENSCHNEIN M, VOCK P, DINKEL HP, AJR Am J Roentgenol, 178 (2002) 1195. — 17. FINKELSTEIN, SE, SUMMERS, RM, NGUYEN DM, STEWARTH JH 4th TRETTLER JA, SCHRUMP DS, J Thorac Cardiovasc Surg, 123 (2002) 967. — 18. HIGGINS WE, RAMASWAMY K, SWIFT RD, MCLENNAN G, HOFFMAN EA, Radiographics 18 (1998)761.

Using virtual endoscopy different goals can be achieved. These goals range from teaching, diagnosis, intervention planning: providing insight into the potentially complicated and non-standard anatomy of the patients intra-operative navigation etc.

We found Syngo 3D platform for postprocessing CT data easy to use and our generated images and fly through were of good quality with acceptable frame rate therefore our results were comparable or even better than other platforms like VirEn or EasyVision Endo3D – Philips Medical Systems. Virtual bronchoscopy is relatively simple to carry out as a special representation of a helical CT scan of the thorax. Compared with fiberoptic bronchoscopy, it has several advantages: it is noninvasive; it can pass even high-grade stenoses due to tumors; and for every position of the virtual endoscope in the bronchial tree, it is possible to refer to the corresponding cross-sectional image or to other multiplanar reconstructions to evaluate structures outside the bronchial lumen. A major disadvantage is its inability to evaluate the mucosal surface. Furthermore, biopsy as well as cytologic and microbiologic specimens cannot, be obtained with this method.

Distal portions of the bronchial tree can be evaluated with virtual bronchoscopy only if they are not filled with viscous secretions or, for example, coagulated blood. However, because the corresponding cross-sectional images are always available, apparent occlusions due to secretions can be identified. Furthermore, data obtained using this method can simplify decision making regarding suitable operative techniques when both the cause of an impression and its relation to important mediastinal structures, such as the great vessels are known. Finally, follow-up examinations after interventions such as stent placement are feasible without additional risk for the patient. The main advantage of virtual bronchoscopy in a clinical setting was to provide a diagnostic tool for airway evaluation in patients who were not suitable for fiberoptic bronchoscopy on presentation to hospital.

V. Ćuk

*Department of Otorhinolaryngology, General Hospital Zabok, Trg Dragutina Domjanića 6, 49210 Zabok, Croatia
e-mail vcuk@net.hr*

VIRTUALNA BRONHOSKOPIJA I TRODIMENZIONALNE CT REKONSTRUKCIJE U OBRADI BOLESNIKA S KARCINOMOM BRONHA – NAŠE ISKUSTVO SA SYNGO 3D PROGRAMSKOM PODRŠKOM ZA POSTPROCESIRANJE CT SLIKA

S A Ž E T A K

Virtualna bronhoskopija (VB) na temelju podataka dobivenih višeslojnom spiralnom kompjutoriziranom tomografijom predstavlja jedno od najnovijih dostignuća vizualizacijskih tehnika potpomognutih računalom. VB pruža mogućnost neinvazivne i relativno pouzdane trodimenzionalne evaluacije traheobronhalnog stabla. Virtualnu bronhoskopiju i »in-space« trodimenzionalnu volumnu analizu izveli smo na skupu CT snimaka šezdesetčetverogodišnjeg muškarca sa karcinomom bronha, kako bismo demonstrirali prednosti i nedostatke ove metode u dijagnostici i prijeoperacijskoj obradi metastatskog karcinoma bronha. Siemensov Somatom Emotion 16 spiralni CT skener je primjenjen za prikupljanje podataka. CT snimanje prsnog koša je učinjeno u pušača sa ekspanzivnim T4N1M1 malignim procesom u gornjem režnju desnog pluća, popraćenog sa velikom metastatskom lezijom na desnoj lateralnoj torakalnoj stijenci. Metastatske lezije su također pronađene u kralješnici. In-space trodimenzionalna analiza popraćena s virtualnom bronhoskopijom prikazala je opstrukciju apikalnog ogranka segmentalnog bronha gornjeg plućnog režnja. Prikazana je vanjska kompresija tumora na gornji segmentalni i desni glavni bronh. Zaključujemo da višeslojna kompjuterizirana tomografija sa VB može biti neinvazivna alternativa bronhoskopiji, ukoliko nije potrebno uzimanje uzoraka ili obrisaka tkiva.