

Effect of Pesticides on Wound Contraction

Željko Glavić¹, Ljubo Begić¹, Ilija Bagarić², Srećko Sabalić¹, Marijana Šimunović¹ and Marta Gotovac³

¹ Department of Surgery, County General Hospital, Požega, Croatia

² Department of Pathology, County General Hospital, Požega, Croatia

³ Department of Ophthalmology, County General Hospital, Požega, Croatia

ABSTRACT

Agricultural injuries are a complex surgical problem, especially because of frequently extensive skin lesions prone to infection and delayed healing. The aim of the study was to assess the local effect of pesticides, chemical substances widely used in agriculture, on wound healing, especially on wound contraction. Local effects of the combined herbicide composed of atrazine and dual (Primextra) and insecticide alphamethrin (Fastac 10% SC) on primary wound healing were assessed in a bioassay performed in 18 New Zealand white rabbits. Relative size of the wound, measured on days 0, 1, 3, 6, 9 and 12 of wounding was analyzed by two-factor analysis of variance with repeat measurements. The activity of the process of restoration was assessed on histopathologic preparations obtained after the last measurement. Results of the study showed the final wound contraction to be smaller and the process of healing slower in the experimental groups of animals. Histopathology revealed defects of epithelialization, phasic delay in healing, infiltration with eosinophilic granulocytes, and decreased density of newly formed collagen. Pesticides were concluded to have adverse local effects on the wound, causing impairment of the mechanisms of healing.

Key words: pesticides, wound contraction, wound healing

Introduction

Agricultural injuries present a considerable surgical problem, especially in terms of skin lesion management. In agricultural traumatism, the prevalence of extensive, concussion injuries to the skin^{1–3} associated with lesions to other anatomical structures has increased, primarily due to the rapid development of farm machinery, almost exclusively serving the goal of productivity increase^{4–6}. The large-scale use of pesticides, natural or synthetic chemical and other substances to protect cultivated plants from various animal and plant organisms destroying them or interfering with their growth began between the 1940s and 1950s. Over the past 50 years, more than 100,000 compounds with pesticidal activity have been synthesized in the world. However, the occurrence of undesired effects of pesticides on human health, at first in the form of acute poisoning, has pointed to the need of caution in their use^{7–13}. Experimental studies have shown some groups of pesticides to exert embryotoxic, mutagenic and teratogenic effects, whereas clinical trials have pointed to a relationship between pesticides and cancer^{14–40}.

The characteristics of pesticides and their effects on the live cell, plants, and animal and human body are generally known, however, their effect on the wound, process of wound healing and results of treatment has not yet been defined. In view of the large-scale use of pesticides and their presence in the soil contaminating the wounds in farmers, the aim of this study was to determine their effect on the wound and mechanisms of healing, especially wound contraction.

Material and Methods

Two pesticides used in this study were chosen from an abundance of widely used pesticidal agents listed in the Kutjevo Agroindustry 1988 Calendar of Pesticide Utilization (Table 1). The agents were first ranked according to the size of agricultural areas on which they were used, then two agents belonging to different pesticide groups were chosen among the five most widely used agents: the

TABLE 1
KUTJEVO AGROINDUSTRY 1988 CALENDAR
OF PESTICIDE UTILIZATION

Pesticide	Culture	ha	kg/ha	Total
Fastac 10%	Rape	177	0.12	21.24
Ronilan FL		177	1.5	265.5
Ridomil MZ 72	Seed-rape	98	2.5	245.0
Fastac 10%		98	0.175	17.15
BI-58 EC		98	2.0	196.0
Dicofluid MP	Rye	10	4.0	40.0
Fastac 10%	Wheat	4635	0.12	556.2
Dicofluid MP		4635	4.0	18540.0
Dicuran FW 500		4635	2.5	11587.5
Tilt 250 EC		4635	0.5	2317.5
Dicofluid MP	Oats	184	4.0	736.0
Fastac 10%		184	0.12	22.08
Dual 500	Sugar beet	175	3.0	525.0
Piramin FL		175	6.0	1050.0
Brestan con		175	0.4	70.0
BI-58 EC		175	1.5	262.5
Fastac 10%		175	0.12	21.0
Racer 25	Sunflower	531	3.0	1593.0
Dual 500		531	3.0	1593.0
Dithane M-45		531	4.5	2389.5
Dual 500	Soya	970	1.0	970.0
Galex 500 EC		970	4.0	3880.0
Primextra	Corn	3193	3.0	19158.0
Devrinol	Tobacco	428	3.0	1284.0
Ridomil MZ 72		428	2.5	1070.0

insecticide alphasmethrin (Fastac 10% SC) and combined herbicide composed of atrazine and dual (Primextra). On 10,431 hectares (ha), 68,410.17 kilograms (kg) pesticide were used, distributed as follows: 637.67 kg of Fastac 10% SC insecticide on 5,269 ha, and 9,579 kg of Primextra herbicide on 3,193 ha.

Fastac 10% SC, discovered and developed at the Shell Research Centre in Sittingbourne, England, and manufactured by Pliva Co., Zagreb, American Cyanamide Co. license (trade-name Cyanamide), is a well-known, broad-spectrum insecticide from the group of pyrethroids with a generic name of alphasmethrin, used for the protection of cereals, cotton, rape, soya, corn, vine, fruit-tree, coffee-tree, hop-vine and woods. The insecticide is available as an emulsion and suspension concentrate containing 100 grams (g) of active substance alphasmethrin *per* liter (L). The agent is applied by 0.01%–0.25% solution spraying. Fastac 10% SC is a fast-acting insecticide. The symptoms of poisoning in insects include excitation, convulsions, paralysis and death, in this order of occurrence. According to the

manufacturer's commercial information leaflet, the agent is toxic in laboratory conditions, whereas its toxic effect on useful organisms and humans when used outdoors is negligible. Its mean *per os* lethal dosis (LD₅₀) for the rat is 1,805 milligrams per kg body weight (mg/kg).

Primextra, manufactured by Ciba-Geigy, is a combined triazine herbicide containing atrazine and metholachlorine as active ingredients, and is used to destroy annual wide-leaf weeds and weed grass in cornfields. It contains 200 g/L atrazine and 300 g/L metholachlorine. Primextra acts as a systemic poison, and optimal herbicidal action is achieved if incorporated into the upper layer of the soil. According to the manufacturer's information leaflet, the agent is poisonous if inhaled, swallowed and in skin contact. Its mean *per os* LD₅₀ for the rat is 3,080 mg/kg.

In the study, the herbicide and insecticide described were used in the form and concentration regularly applied onto the agricultural soil.

New Zealand white rabbits, from the Brezovac farm near Bjelovar, mean body weight 1,900–2,300 g, were used in the study. A total of 18 rabbits, 10 male and 8 female, were used. All animals were clinically healthy, as confirmed by veterinary examination. The rabbits were housed in separate wire cages, in a closed room, at room temperature, and were fed concentrated chow with the addition of water. In all rabbits, an oval wound was made at the same site, on a depilated area of the skin, paravertebrally, always along the long axis of the rabbit body, across full skin thickness, i.e. to the muscular fascia (Figure 1).

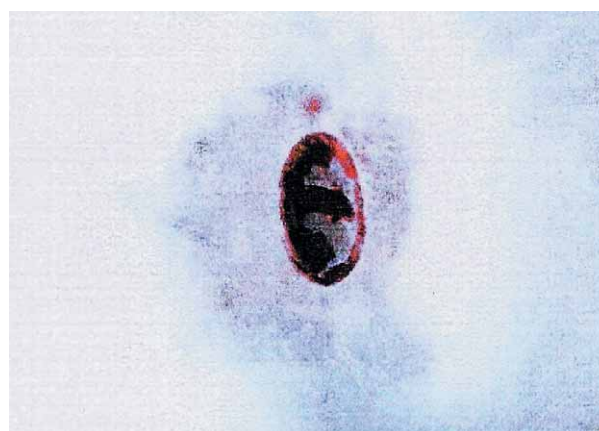

Fig. 1. Macroscopic appearance of the wound before application of the tested agent.

In six control group rabbits, the wound was immediately covered with saline-soaked gauze for 4 hours. The remaining 12 rabbits were divided into two groups of six rabbits each. Their wounds were covered for the first 4 hours with gauze soaked in the herbicide and insecticide tested, respectively, and secondary wound healing, i.e. primary wound contraction, was observed. The surface of each wound was calculated from the mutually vertical wound diameters measured on days 0, 1, 3, 6, 9 and 12, according to the formula for ellipse surface.




Fig. 2. Macroscopic appearance and size of the third wound in control group (K3) on days 1, 6 and 12 of wound induction.

Upon the last measurement on day 12, the scars were ovally excised and pinned onto cork-plates to prevent bending, and placed into bottles containing 10% formalin. Histopathologic preparations were made from the fixed scars by taking 2-millimetres (mm) wide scar centers, which were paraffin-embedded and cut into 5-microns (μ) microsections. The section plane was vertical upon the skin surface. Preparations obtained from each individual scar were stained with hematoxylin-eosin by trichrome method according to Mallory and periodic acid schiff (PAS) method, and analyzed by light microscopy technique.

Scar examination to evaluate epithelialization defects, the presence of granulation blood vessels, cellular granulomas and eosinophilic granulocytes, and density of the newly formed collagen, was performed on five preparations from each wound using the three staining methods mentioned above. The parameters were evaluated as YES and



Fig. 3. Macroscopic appearance and size of the sixth wound treated with herbicide (H6) on days 1, 6 and 12 of wound induction.

NO, with autoreproducibility taken as the criterion of evaluation. Density of the newly formed collagen was assessed by mutual comparison of the three groups of preparations.

Results

The size of each individual wound on the day of wounding (day 0) was taken as baseline, and all other measurements (days 1, 3, 6, 9 and 12) were calculated as percent of the baseline, thus obtaining the relative wound size dynamics (Figures 2, 3 and 4). Examination of arithmetical means of the relative size of the wounds revealed the highest rate of wound contraction in the control group, followed by the herbicide-contaminated group of wounds, whereas the lowest rate of wound contraction was recorded in the group of insecticide-contaminated wounds (Figure 5).




Fig. 4. Macroscopic appearance and size of the fourth wound treated with insecticide (I4) on days 1, 6 and 12 of wound induction.

Difference was determined by two-factor analysis of variance with repeat measurements. There was a statistically significant difference among the three groups of animals according to the final wound contraction ($F=14.28$; $df=2:15$; $p<0.05$) and rate of wound contraction ($F=4.92$; $df=8:60$; $p<0.01$). The highest density of newly formed collagen was found in the control group and lowest in the insecticide-treated group of wounds. The elements of early stages of healing, i.e. cellular granulomas and granulation capillaries, were most pronounced in the group of insecticide-contaminated wounds and were present in all preparations from this group, whereas in the control preparations they were only sporadically observed. Epithelialization defects were found in one control wound, four herbicide-treated wounds and all six insecticide-treated wounds. Histological examination revealed eosinophilic granulocytes to be present in all preparations of the two experimental groups of wounds, and in none of the control preparations.

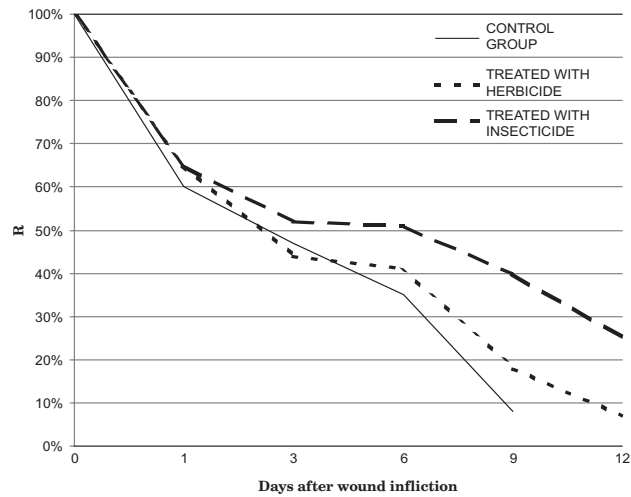


Fig. 5. Graphic presentation of the relative wound size (R) dynamics. Measurement results are presented as mean \pm SD. The three groups differed significantly according to the final wound contraction ($F=14.28$; $df=2:15$; $p<0.05$) and rate of wound contraction ($F=4.92$; $df=8:60$; $p<0.01$).

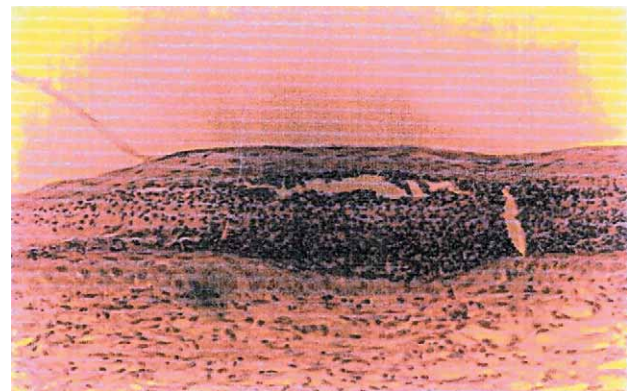


Fig. 6. Epithelialization defect in an insecticide-treated preparation.

Considerable differences were recorded in the macroscopic appearance of the wounds between individual groups of wounds. In the control group, the wounds were regularly rounded throughout the study period, the tissue was red, finely granulated, with no crust on the surface of the wound. None of these wounds showed signs of infection. In the group of herbicide-treated wounds, some wounds showed more or less irregular edges, slightly elevated from the adjacent skin level, while the granulation tissue was pale and below the skin level. Some of these wounds formed a fine crust on the surface, which fell off after day 9. The edges of insecticide-contaminated wounds were extremely irregularly shaped, serrated and markedly elevated above the adjacent skin level. The bed of the wound at first appeared bacon-white and dry, and was subsequently covered with a solid crust which persisted until the end of the study period.

Discussion

Primary contraction, i.e. a tendency of wound reduction by its edges approaching the center of the wound, is one of the main characteristics of the wound^{40–43}. It occurs as early as during the early inflammatory stage, probably consequentially to the chemotactic action of kinins and prostaglandins on myofibroblasts in the wound surrounding^{44,45}. The phenomenon was described in 1973 by Gabbiani, who observed many fibroblasts to contain myofibrils and to be characterized by extreme contractility⁴⁶. Any agent suppressing the formation or intralesional action of chemotactic substances, or exerting an unfavorable effect on myofibroblasts, actually reduces or prevents the mechanism of primary wound contraction^{47–49}.

Wound epithelialization is also controlled by chemotactic substances released in the wound and interfering with the mitotic activity of epidermal cells and their migration^{50–55}. In the present study, the most rapid and complete epithelialization of experimentally induced wounds was recorded in the control group. In the experimental groups of wounds, both macroscopic and histopathologic defects of epithelialization were observed (Figure 6), which manifested by the epithelium overgrowing the crust, growing into the depth of the wound, or growing over the lower surface of the crust, with a space filled with exudate between the epithelium and granulation tissue of the wound, indicating that the effect of pesticides destroyed favorable conditions or created unfavorable conditions for wound healing⁵⁶.

As eosinophilic granulocytes were found in all preparations of the two experimental groups, allergic reaction to

the pesticides tested was suspected^{57–61}. The control group scars contained the highest amount of newly formed collagen, followed by the scars of herbicide-treated wounds. The scars of insecticide-treated wounds contained the lowest amount of newly formed collagen, i.e. it was found in traces only. Collagen is formed by the activity of macrophages from fibroblasts which also depend on the action of regulatory mechanisms of wound healing, primarily of the above mentioned chemotactic substances, and on physicochemical characteristics of the wound *milieu*. Therefore, poorer collagenization in the experimental than in the control wounds pointed to the pesticide-induced impairment of the process of new collagen formation^{62–66}.

In conclusion, the results obtained demonstrated that secondary healing of pesticide-contaminated wounds was retarded as compared to control wounds according to all the parameters observed, i.e. final wound contraction, rate of wound contraction, wound epithelialization, presence of elements of early stages of healing, presence of eosinophilic granulocytes, and amount of newly formed collagen. Comparison of the two experimental groups indicated all the elements of retarded wound healing and healing impairment to be present in both groups, however, they were more pronounced in the group of insecticide-treated wounds than in the herbicide-treated wounds. This observation could by no means be equally extrapolated to all pesticides, yet it should be emphasized that the pesticides tested in the study are characterized by a relatively low oral and dermal toxicity as compared to most other pesticides widely used in agriculture^{67–69}.

REFERENCES

1. COLE DC, CARPIO F, MATH JJ, LEON N, Contact Dermatitis, 37 (1997) 8. — 2. SPIEWAK R, Ann Agric Environ Med, 8 (2001)1. — 3. WESSELING C, HOGSTEDT C, FERNANDEZ P, AHLBOM A, Int J Occup Environ Health, 7 (2001)1. — 4. SIMPSON SG. Farm machinery injuries, J Trauma, 24 (1984) 150. — 5. NIELSEN CT, Ugeskr Laeger, 148 (1986) 1705. — 6. ŠANJEK V, KOMANOV I, Opsežne povrede mekih dijelova šake u poljoprivrednika. In Croat. In: Proceedings. (IV simpozij o bolestima i ozljedama šake, Opatija, 1974). — 7. AMOATENG-ADJEPONG Y, SATHIAKUMAR N, DELZELL E, COLE P J Occup Environ Med, 37 (1995) 471. — 8. LESSENGER JE, ESTOCK MD, YUNGLOVE T, J Am Board Fam Pract, 8 (1995) 278. — 9. CASEY P, VAALE JA, Hum Exp Toxicol, 13 (1994) 95. — 10. THOMPSON JP, CASEY PB, VALE JA, Hum Exp Toxicol, 14 (1995) 437. — 11. DAS R, STEEGE A, BARON S, BECKMAN J, HARRISON R, Int J Occup Environ Health, 7 (2001) 303. — 12. SPERATI A, RAPITI E, SETTIMI L, QUERCIA A, TEREZONI B, FORASTIERE F, Am J Ind Med, 36 (1999) 142. — 13. FLEMING LE, BEAN JA, RUDOLPH M, HAMILTON K, Occup Environ Med, 56 (1999) 14. — 14. COLTON T, JAMA, 256 (1986) 1176. — 15. HOAR SK, BLAIR A, HOLMES FF, BOYSEN CD, ROBEL RJ, HOOVER R, JAMA, 256 (1986) 1141. — 16. EL-SADEK WY, HASSAN MH, East Mediterr Health J, 5 (1999) 960. — 17. ERIKSSON M, Br J Ind Med, 38 (1981) 27. — 18. BLAIR A, ZAHM SH, Environ Health Perspect, 103 (1995) 205. — 19. SAFI JM, NAHHAL YZ, SOLIMAN SA, SEBAE AH, Sci Total Environ, 132 (1993) 371. — 20. MORRISO H, SAVITZ D, SEMENCIW R, HULKA B, MAO Y, MORISON D, Am J Epidemiol, 137 (1993) 270. — 21. DICH J, WIKLUND K, Prostate, 34 (1998) 100. — 22. YAMANO T, MORITA S, Arch Environ Contam Toxicol, 25 (1993) 271. — 23. LEISS JK, SAVITZ DA, Am J Public Health, 85 (1995) 249. — 24. ARBUCKLE TE, SEVER LE, Crit Rev Toxicol, 28 (1998) 229. — 25. ARBUCKLE TE, LIN Z, MERRY LS, Environ Health Perspect, 109 (2001) 851. — 26. TIELEMANS E,

- VAN KOOLIJ R, TE VELDE ER, BURDORF A, HEEDERIK D, Lancet, 354 (1999) 484. — 27. KAUPPINEN T, PARTANEN T, DEGERETH R, OJAJARVI A, Epidemiology, 6 (1995) 498. — 28. DOLAPSAKIS G, VLACHONIKOLIS IG, VARVERIS C, TSATSAKIS AM, Eur J Cancer, 37 (2001) 1531. — 29. TAUBES G, Science, 264 (1994) 499. — 30. BOHNEN NI, Int J Epidemiol, 23 (1994) 867. — 31. TUCHSEN F, JENSEN AA, SCAND J Work Environ Health, 26 (2000) 359. — 32. BALDI I, FILLEUL L, MOHAMED-BRAHIM B, FABRIGOULE C, DARTIGUES JF, Environ Health Perspect, 109 (2001) 839. — 33. GORELL JM, JOHNSON CC, RYBICKI BA, PETERSON EL, RICHARDSON RJ, Neurology, 50 (1998) 1346. — 34. BUZIO L, TONDEL M, DE PALMA G, BUZIO C, FRANCHINI I, MUTTI A, AXELSON O, Med Lav, 93 (2002) 303. — 35. ZAVON MR, J Occup Med, 36 (1994) 598. — 36. VIEL JF, CHALLIER B, Occup Environ Med, 52 (1995) 587. — 37. PARRON T, HERNANDEZ AF, VILLANUEVA E, Forensic Sci Int, 79 (1996) 53. — 38. KAMEL F, BOYES WK, GLADEN BC, ROWLAND AS, ALAVANJA MC, BLAIR A, SANDLER DP, Am J Ind Med, 37 (2000) 618. — 39. DOWLING KC, SEIBER JN, Int J Toxicol, 21 (2002) 371. — 40. RUNDOLPH R, World J Surg, 4 (1980) 279. — 41. DUNPHY JE, Can J Surg, 10 (1967) 281. — 42. HOFSTADTER F, Chirurg, 66 (1995) 174. — 43. BOYKIN JV Jr, Wound Repair Regen, 9 (2001) 391. — 44. SCHWEMMLE K, LINDER R, Chirurg, 66 (1995) 182. — 45. VANDE BERG JS, RUDOLPH R, Ann Plast Surg, 14 (1985) 111. — 46. SILEVER IA, Schweiz Rundsch Med Prax, 73 (1984) 942. — 47. PULANIĆ D, RUDAN I, Coll Antropol, 29 (2005) 341. — 48. MODOLIN M, BEVILACQUA RG, MARGARIDO NF, GONCALVES EL, Ann Plast Surg, 12 (1984) 428. — 49. CROSS SE, NAYLOR IL, COLEMAN RA, TEO TC, Br J Plast Surg, 48 (1995) 189. — 50. BOLLOUGH WS, LAURENCE EB, Exp Cell Res, 43 (1996) 343. — 51. BHORA FY, DUNKIN BJ, BATZRI S, ALY HM, BASS BL, SIDAWY AN, HARMON JW, J Surg Res, 59 (1995) 236. — 52. GUDEHITHLU KP, AHMED N, WU

H, LITBARG NO, GARBER SL, ARRUDA JA, DUNEA G, SINGH AK, J Lab Clin Med, 145 (2005) 194. — 53. KUNIMOTO BT, Ostomy Wound Manag, 45 (1999) 56. — 54. HART J, SILCOCK D, GUNNIGLE S, CULLEN B, LIGHT ND, WATT PW, Int J Biochem Cell Biol, 34 (2002) 1557. — 55. HARRIES RH, ROGERS BG, LEITCH IO, ROBSON MC, Aust N Z J Surg, 65 (1995) 600. — 56. SHAMRAI PF, PRISHCHAK AF, Vrach Delo, 12 (1979) 92. — 57. GASSNER M, Schweiz Rundsch Med Prax, 85 (1996) 950. — 58. KANERVA L, ESTLANDER T, JOLANKI R, Contact Dermatitis, 31 (1994) 242. — 59. ASSINI R, FEACCHIOLLA F, RAVALLI C, NAVA C, Med Lav, 85 (1994) 321. — 60. BENER A, LESTRINGANT GG, BESHWARI MM, PASHA MA, Allerg Immunol, 31 (1999) 52. — 61. NAMBA T, HONMA K, HORIUCHI K, TSUJISAWA I, MIYATA M, ISHI-

KAWA S, Nippon Ganka Gakkai Zasshi, 97 (1993) 297. — 62. HUNT TK, KNIGHTON DR, THAKRAL KK, GOODSON WH III, ANDREWS WS, Surgery, 96 (1984) 48. — 63. KNIGHTON DR, HUNT TK, THAKRAL KK, GOODSON WH III, Ann Surg, 196 (1982) 379. — 64. GROTDORST G, J Trauma, 24 (1984) 49. — 65. STRUCH H, MMWR, 125 (1983) 1111. — 66. ŠVAJGER A, Kolagen. In: Medicinska enciklopedija. In Croat. (Dopunski svezak, Zagreb, 1976). — 67. BAINOVA A, Toxicity of selected groups of pesticides. Herbicides. In: Proceedings. (Toxicology of pesticides, Sofia, 1981). — 68. MATSUMURA F, Toxicology of insecticides (Plenum Press, New York, London, 1984). — 69. SCOTT RC, CARMICHAEL NG, HUCKLER KR, NEEDHAM D, SAVAGE T, Food Chem Toxicol, 31 (1993) 523.

Ž. Glavić

Department of Surgery, County General Hospital, Osječka 107, 34000 Požega, Croatia
e-mail: zeljko.glavic@pozeska-bolnica.hr

UTJECAJ PESTICIDA NA KONTRAKCIJU RANE

SAŽETAK

Ozljede u poljodjelstvu predstavljaju složeni kirurški problem, posebno zbog učestalosti opsežnih ozljeda kože sklonih infekciji i produljenom cijeljenju. Cilj ove studije bio je ispitati lokalno djelovanje pesticida, kemijskih pripravaka koji se uglavnom upotrebljavaju u poljodjelstvu, na cijeljenje rane, posebno na njenu kontrakciju. Lokalno djelovanje herbicida Primextra i insekticida Fastac 10% SC na primarno cijeljenje rane ispitano je biološkim pokusom na 18 bijelih novozelandskih kunića. Relativna veličina rane, mjerena 0., 1., 3., 6., 9. i 12. dana nakon ranjavanja, statistički je uspoređena dvofaktorskom analizom varijance s ponavljanim mjerenjima. Tijek procesa cijeljenja praćen je i na patohistološkom materijalu uzetom nakon posljednjeg mjerenja. Rezultati ispitivanja pokazali su da je konačna kontrakcija rane manja, a proces cijeljenja sporiji u ispitivanim skupinama životinja. Patohistološki su prikazani defekti epitelizacije, zaostajanje u fazi cijeljenja, infiltracija eozinofilnim granulocitima i smanjena gustoća novostvorenog kolagena. Pesticidi, zaključno, imaju nepovoljni lokalni utjecaj na ranu zbog oštećenja mehanizama njenog cijeljenja.