

The Study of Enteses: Proposal of a Standardised Scoring Method for Twenty-Three Enteses of the Postcranial Skeleton

Valentina Mariotti, Fiorenzo Facchini and Maria Giovanna Belcastro

Department of Experimental Evolutionary Biology, Anthropology Unit, University of Bologna, Bologna, Italy

ABSTRACT

Enteses are always visible on the bone, although with variable forms and degrees of expression. The term »robusticity« indicates the »normal« osseous markings at enteses, while »enthesopathy«, indicates the presence of enthesophytes or osteolytic areas^{1–3}. A scoring method for enthesopathy development has already been proposed³. In this paper, a standardised descriptive and photographic scoring method is proposed for the robusticity of 23 postcranial skeleton enteses. For each entesis, 3 levels of development are described, corresponding, in general, to a weak-moderate expression (degree 1), strong development (degree 2) and very strong development (degree 3). The interobserver error of about 20% seems acceptable given the great morphological variability of these traits.

Key words: entesis, robusticity, enthesopathy, postcranial skeleton, standardised scoring method

Introduction

The term »entesis« derives from the Greek word »ενθεσις«, meaning »insertion«⁴. This term is normally used to identify the sites of attachment of muscles, ligaments and capsules on bones^{3–7}, although some authors make a distinction between »entesis« (site of muscle attachment) and »syndesmosis« (site of ligament attachment)^{8–11}.

The study of enteses in human skeletal remains to reconstruct habitual physical activities of past populations has received much attention since the 1980s^{1,5,12–21}. However, these studies have only rarely employed standardised scoring methods; this makes comparison of the results of studies performed by different authors on different populations rather unreliable, and this fact, in turn, limits the interpretative possibilities. In particular, two standardised scoring methods have been proposed by Hawkey²² (see also Hawkey and Merbs¹) and Robb^{23,24} respectively. The main problem with these methods is that none of them provides reference photographs of each entesis. Moreover, the first method regards only the upper limb enteses. The objective of the present paper is to propose a descriptive and photographic standard for the scoring of 23 enteses of the postcranial skeleton and to illustrate the various operational phases involved in its definition.

It is useful to record the type of expression of enteses (simple surface irregularity or osteoproliferative or erosive formations) and their levels of development. These traits are essentially qualitative, with continuous variation, and they are usually scored via macroscopic observation. Indeed, quantification of the degrees of development is often impossible due to the great number of variables that need to be considered: ideally it would be necessary to clearly delimit the attachment surface, whose borders, however, are not always evident, and then evaluate its extension, but more properly its volume since an entesis has a complex three-dimensional development because of its irregular surface (rugosity, sulci, ridges, etc.); the latter information should then be evaluated in relation to the size of the bone. It should also be noted that most anthropological research on the skeleton (attribution of age and sex, palaeopathology, study of activity indicators, study of discrete traits, etc.) routinely employs inexpensive, non-destructive macroscopic observation, which is often no less informative than more sophisticated methods (microscopic, radiographic, biomolecular, histological, etc.). The latter methods are usually used to complement macroscopic observations or for more detailed study of doubtful situations.

The main problem with the macroscopic scoring of qualitative traits is the difficulty of their codification, which gives the observations a large degree of subjectivity. To reduce the subjectivity of the observations, it is necessary to use standardised scoring methods. The problem of standardisation of scoring methods for skeletal morphological markers of activity was tackled by our research group long ago², particularly regarding the development and alterations of entheses and the possible presence of extensions of articular surfaces or the formation of accessory articular facets.

In previous works^{2,3}, we proposed that 3 aspects of each enthesis be scored:

1. robusticity (cf. Hawkey and Merbs¹), representing the »normal« osseous markings at the site of attachment of a muscle or ligament;
2. proliferative, »osteophytic« enthesopathies (OF), characterised by the presence of enthesophytes (we will call them, most properly, EF);
3. erosive, osteolytic enthesopathies (OL), characterised by pitting or eroded areas.

Entheses are always recognizable on the bone by the presence of surface irregularities (rough or remodelled surface, ridges, grooves, etc.). In fact, being involved in the transmission of forces to generate movement, they are subjected to mechanical loading, which induces a response by the bone. The type and magnitude of the response can vary, probably depending on several factors (e.g. the type and magnitude of stress, the age and sex of the individual, etc.), giving rise to different degrees of development and also to different morphologies. Therefore, robusticity markers are always observable, although with variable degrees of expression, while enthesopathies (enthesophytes or eroded areas) can be absent or present. Thus, the distinction between robusticity and enthesopathies is justified by their different meaning, the first representing the physiological bone response to the muscle or ligament solicitations, the latter being the effect of some kind of »anomalous« condition (excessive mechanical loading, pathological conditions of various origin, etc.). A scoring standard for the two forms of enthesopathies has already been published³.

The aim of this paper, the continuation and completion of the preceding one on enthesopathies³, is to propose a standardised method to score the robusticity of entheses, discussing in a critical way the problems that have aroused in the course of its definition and the choices that have been made. In fact, the definition of a scoring methodology for qualitative characteristics implies some initial decisions (e.g. to decide the entheses to be scored, the number of developmental classes, etc.). Their effectiveness have to be evaluated in relation to the objectives of the study (e.g. to study the individual skeletal response to limb amputation, the biological effects of different life styles in prehistoric populations with different subsistence patterns, etc.), considering also the type of data analysis or statistical elaborations required. Various attempts have to be done before reaching the desired

result, that represents in any case a compromise between the need for a sensitive instrument, capable of giving detailed data, and an effective instrument, providing reproducible observations.

Thus, in the present paper, the main aspects of the procedure that led to the production of the standard proposed will be illustrated. This procedure can be divided in three phases:

1st phase: preparation of a preliminary standard with 5 degrees of development for each enthesis and verification of its validity by calculation of the intraobserver error;

2nd phase: evaluation of the interpretative possibilities offered by the 5-degrees-standard through its application to study a sample of 113 individuals of known age, sex and occupation, in order to verify if this subdivision into 5 degrees was effectively useful to find possible relationships between the enthesal development and these variables;

3rd phase: preparation of the definitive standard, on the basis of observations in the first two phases, and verification of the new methodology by calculation of the intra- and interobserver errors.

TABLE 1
LIST OF THE ENTHESES (NAMED AFTER THE MUSCLE OR LIGAMENT ATTACHING TO IT) CONSIDERED IN THE PRESENT STUDY (IN BRACKETS THE BONE ON WHICH THE ENTHESIS OCCURS), DIVIDED ACCORDING TO THE FUNCTIONAL COMPLEX TO WHICH THE MUSCLE/LIGAMENT BELONGS

Enthesis	Functional Complex
Costoclavicular lig. (clavicle)	Shoulder
Conoid lig. (clavicle)	
Trapezoid lig. (clavicle)	
M. pectoralis major (clavicle)	
M. deltoideus (clavicle)	
M. pectoralis major (humerus)	
M. lat. dorsii/teres major (humerus)	
M. deltoideus (humerus)	Elbow (flexion/ extension)
M. triceps brachii (scapula)	
M. brachioradialis (humerus)	
M. biceps brachii (radius)	
M. triceps brachii (ulna)	Forearm (pronation/ supination)
M. brachialis (ulna)	
M. pronator teres (radius)	
Interosseous membrane (radius)	Hip
M. supinator (ulna)	
M. gluteus maximus (femur)	Knee
M. iliopsoas (femur)	
M. vastus medialis (femur)	
Quadriceps tendon (tibia)	Foot
Quadriceps tendon (patella)	
M. soleus (tibia)	Foot
Achilles tendon (calcaneus)	

The 1st and 2nd phases will thus constitute the materials and methods section, while the 3rd phase represents the results and discussion section. We also propose a standardised data collection form that allows the scoring of the above-mentioned aspects for each enthesis: robusticity, enthesophytic (EF) and osteolytic enthesopathies (OL).

Materials and Methods

The standardised scoring method for robusticity was developed for 23 entheses of the postcranial skeleton (Table 1). These entheses were chosen on the basis of three characteristics: they should be often preserved on osteoarchaeological material; they should be easily identifiable on bones, so we selected those ones where only one (e.g. *m. deltoideus* on the humerus) or at most two attachment sites are present in the same area of the bone (e.g. *mm. latissimus dorsi/teres major* on the humerus); they should show appreciable variability to be divided in different classes of development.

The skeletal materials utilized for the study come from the Sardinian (Italy) collection (part of the Frassetto collections²⁵, early XX century) of the Museum of Anthropology, University of Bologna and from the Sperino Collection (late XIX century) housed in the Institute of Anatomy of the Modena Hospital (Italy). Information about the age, sex and occupation of the individuals is available for both skeletal collections. The Sardinian collection include also bones from ossuaries. The pathological specimens were discarded.

First phase

As suggested by Robb^{23,24}, we identified 5 levels of development for each enthesis (degrees 0 to 4) by setting up a series of bones (around 30) in increasing order of degree of development of the enthesis considered and dividing the observed variability into classes. The bones came from ossuaries of several Sardinian cemeteries (XX century). We then described the characteristics of each class of development for each enthesis. As an example, we report the standard for the attachment of the costoclavicular ligament on the costal tuberosity of the clavicle:

Costoclavicular ligament

0. the impression is practically absent; the surface of the attachment site is smooth
1. the impression is barely appreciable, the attachment area presents only slight rugosity
2. the attachment area is well delimited, although the edges are discontinuous. The surface is barely raised or depressed, smooth or slightly rugose
3. the area is delimited by well-defined margins, raised or depressed, with irregular or rugose surface
4. the impression is strongly developed and extensive; different morphologies are possible: »fingerprint in plasticine« or raised platform with irregular or rugose surface. The edges are generally sharp or »lipped«, in any case well-defined, usually with the dorsal margin more developed than the ventral.

NB: if an osteolytic enthesopathy of degree 3 (presence of several small areas of erosion – ca. 4 mm in length or diameter – or at least one extensive and deep osteolytic area – >4 mm in length or diameter) is present, robusticity should be scored as NR (not recordable).

To test the validity of this method of scoring entheses, we calculated the intraobserver error: the percentage of errors committed by the same observer in attributing the various entheses to the defined levels of development in two independent scoring sessions a few months apart. A sample of 60 complete skeletons (43 males and 17 females) from the Sardinian (Sassari) collection was used for this test³. We could not refer to the literature for the definition of errors associated to standardized scoring methods for entheses development. In fact, Robb^{23,24} did not associate any error to his method, while Hawkey and Merbs¹ state the interobserver error of their method has proven negligible, but they did not specify the method used for its calculation. The error presented here was calculated with a program in Visual Basic For Applications (1998) that compares the contents of cells of two Excel spreadsheets containing the data of the first and second scoring sessions. The program computes the total number of cells, the number of cells with different content and the percentage error (no. cells with different content*100/total no. cells). The overall intraobserver error was 28.1%. Various revisions were made to try to give a better definition of the different classes of development, but the error was not noticeably reduced.

In this regard, it must be noted that the procedure to define the developmental classes has an objective limitation: the need to divide continuous variation into discrete categories, and even to apply the concepts of 'previous-subsequent' or 'greater-lesser' to different morphologies (for example, the radial tuberosity, insertion of *m. biceps brachii*, can be very prominent, but with a smooth surface, or not prominent, but with a rough surface; the ulnar insertion of *m. supinator* can be in the form of a crest or a tubercle). In fact, we found that, during attempts to order the bones according to the increasing development of a certain enthesis, various series were possible and we could not reasonably choose one or another. Therefore, the choice is largely arbitrary and, with the current state of knowledge, this error probably cannot be eliminated. Hawkey²² also recognised the difficulty of defining discrete classes of development for these traits characterised by continuous variation. In fact, despite her methodology provides 3 degrees of development (1=faint, 2=moderate and 3=strong expression), she states that intermediate scores (i.e. 2.5) can also be used. In the present work, the use of intermediate scores has been avoided. In doubtful cases, you must decide which category best fits with the specimen under examination.

Intraobserver errors were occasionally due to attribution of a certain degree of development in one of the two scoring sessions versus a »not recordable« verdict in the other session when the area was incomplete or damaged. However, the errors were most often due to confusion between two adjacent developmental classes. This type of

error can be attributed to several causes. First of all, the attribution of a degree is influenced by the unconscious comparison with the previously analysed bone, so that the observer will tend to attribute a more or less high degree depending on whether the enthesis of the previous bone was poorly or well developed. In addition, the right and left bones of one individual were scored contemporaneously; this led, in the case of asymmetry, to attribution of the same degree to both sides in one of the two scoring sessions (with a note indicating the side that presented the greater development) but attribution of a higher degree to the bone with greater development in the other session. Finally, the observer may also be influenced by the greater absolute extension of the entheses on large bones than on smaller bones.

Second phase

The above observations on the origin of the scoring error made us think that the most reasonable way to try to lower it was to reduce the number of degrees of development, for example from 5 to 3. In particular, the major part of the variability (from very low to medium development) could be included in the first degree, while the high and very high development, less subject to scoring errors, could be included in the second and third degrees respectively. However, before accepting this modification, it was necessary to obtain information about the interpretative possibilities offered both by the finer subdivision in 5 degrees of development and a grosser one. Thus, despite the high intraobserver error, the preliminary standard with 5 classes of development was used to study the variation of the traits according to age, sex and occupation of the individuals. In fact, the intraobserver errors mainly concerned adjacent classes of development; thus, we concluded that the attributions within a single scoring session would reflect the level of relative development of the entheses of the different individuals.

Therefore, we used this standard to study a sample of 113 individuals deriving partly from the Sperino Collection (52 males, late XIX century) and partly from the Sardinian (Sassari) collection (44 males and 17 females, early XX century). As already said, information about the age, sex and occupation of the individuals is available for both skeletal collections. The males worked at various jobs, although most were farmers (Table 2), while the females were all housewives.

For each enthesis of each individual, we recorded the robusticity and the possible presence and degree of development of enthesophytic (EF) and osteolytic (OL) enthesopathies³. To investigate age-related differences, we considered only the 96 males (Table 2) divided into three classes: 54 »young« adults (YA, 20–29 years), 27 »mature« adults (MA, 30–39 years) and 15 »old« adults (OA, >40 years). For sampling reasons (few individuals over 40 years), we did not use the classic subdivision of Buikstra and Ubelaker²⁶ (YA: 20–35 years; MA: 36–50; OA: >50).

To test for possible sex differences, we selected individuals between 30 and 39 years to avoid any effects of too young or too advanced age. The sample consisted of 17 females and 27 males.

TABLE 2
COMPOSITION OF THE MALE SAMPLE BY AGE
AND OCCUPATION

	20–29		30–39		>40		total
	SS	Sp	SS	Sp	SS	Sp	
Farmer	10	8	8	3	1		30
Mason	5	4	1	1	1		12
Merchant	4	1	2	2	3		12
Cobbler		5		1	1		7
Miner	2	1	1		1		5
Baker		2		1			3
Butcher		1			2		3
Carpenter	2	1					3
Employee	1		1		1		3
Weight carrier		1		2			3
Driver	1		1				2
Shepherd	1			1			2
Smith					2		2
Other	3	1	1	1	3		9
Total	29	25	15	12	0	15	96

SS – Sardinian collection, Sp – Sperino collection

For each grouping based on age or sex, we calculated the absolute frequencies and percentages of each degree of development for each enthesis, taking account of the side. However, in view of the small subsample sizes, it was necessary to reduce the developmental classes to two (low-medium development, degrees 0+1+2, and high development, degrees 3+4) in order to carry out valid statistical analyses. The significance of the differences among age classes, or between sexes, was evaluated by χ^2 test and when possible (2*2 table) by Fisher's exact test^{27–29}. These statistical analyses were not applied to investigate differences among occupations because of the limited number of individuals performing each job (Table 2).

The original division into 5 classes of development was also used to calculate a »score« for each individual, i.e. a »mean degree of development« calculated as the mean of the degrees of development of the single entheses. This operation, attributing a number to each individual, allowed us to apply other statistical methods. The score was calculated for each »functional complex« (Table 1), as suggested by Dutour (personal communication). In fact, movements of the human body require the contemporary and coordinated intervention of several muscles, and they often involve more than one joint. Thus, the entheses were grouped, on the basis of the functions they are associated with, into six 'functional complexes': shoulder, elbow (flexion/extension), forearm (pronation/supination), hip, knee and foot (Table 1). For each functional complex, we calculated the mean score (X), standard deviation (SD) and coefficient of variation (CV=SD*100/mean) according to sex, age class and, when possible, occupation. In addition to the functional complexes, we also considered the entire upper and lower limbs.

TABLE 3
 MEAN SCORE, STANDARD DEVIATION, COEFFICIENT OF VARIATION AND p VALUE OF THE ANOVA TEST FOR EACH FUNCTIONAL COMPLEX AND UPPER AND LOWER LIMBS, OF LEFT AND RIGHT SIDES, IN THE THREE AGE CLASSES, FOLLOWED BY THE SPEARMAN CORRELATION COEFFICIENT AND RELATIVE p VALUE BETWEEN THE SCORE OF EACH INDIVIDUAL AND HIS AGE

	20–29				30–39				>40				p (ano- va)	N	rS	p	
	N	X	SD	CV	N	X	SD	CV	N	X	SD	CV					
Left	Shoulder	49	2.27	0.38	16.96	26	2.29	0.37	16.22	13	2.75	0.46	16.58	0.001	88	0.24	0.025
	Elbow	50	2.07	0.39	18.78	27	2.25	0.34	15.10	15	2.43	0.26	10.73	0.002	92	0.38	0.000
	Forearm	50	1.61	0.57	35.49	27	1.95	0.54	27.92	15	2.16	0.71	32.99	0.003	92	0.43	0.000
	Hip	50	2.59	0.61	23.62	26	2.81	0.58	20.81	14	3.14	0.57	18.12	0.009	90	0.37	0.000
	Knee	48	1.50	0.46	30.52	26	1.96	0.57	28.97	15	2.11	0.69	32.51	0.000	89	0.51	0.000
	Foot	48	2.18	0.51	23.45	26	2.67	0.66	24.78	15	2.97	0.64	21.57	0.000	89	0.50	0.000
	Upper limb	49	2.10	0.35	16.67	26	2.22	0.31	13.92	13	2.53	0.33	13.11	0.000	88	0.39	0.000
	Lower limb	47	2.00	0.39	19.67	26	2.41	0.45	18.89	15	2.62	0.44	16.63	0.000	88	0.59	0.000
	Up+low limb	46	2.09	0.28	13.61	25	2.27	0.30	13.19	13	2.57	0.33	12.83	0.000	84	0.53	0.000
Right	Shoulder	47	2.30	0.36	15.51	26	2.33	0.40	17.12	14	2.83	0.42	14.73	0.000	87	0.33	0.002
	Elbow	48	2.13	0.39	18.13	27	2.29	0.38	16.65	15	2.51	0.24	9.47	0.002	90	0.41	0.000
	Forearm	51	1.57	0.62	39.23	27	2.00	0.51	25.74	15	2.27	0.62	27.34	0.000	93	0.48	0.000
	Hip	48	2.50	0.62	24.75	27	2.78	0.61	21.95	14	3.11	0.59	19.12	0.004	89	0.37	0.000
	Knee	48	1.55	0.50	32.26	27	1.95	0.58	29.49	15	2.11	0.45	21.45	0.000	90	0.56	0.000
	Foot	51	2.15	0.50	23.42	27	2.63	0.63	23.93	15	3.03	0.69	22.86	0.000	93	0.53	0.000
	Upper limb	46	2.11	0.34	15.97	26	2.27	0.35	15.49	14	2.63	0.33	12.48	0.000	86	0.47	0.000
	Lower limb	47	2.01	0.38	18.78	27	2.39	0.38	16.03	15	2.65	0.38	14.30	0.000	89	0.67	0.000
	Up+low limb	43	2.12	0.29	13.80	27	2.30	0.31	13.31	14	2.63	0.32	12.18	0.000	84	0.57	0.000

rS – Spearman correlation coefficient

For the males, the possible correlation between the individual scores of each functional complex and age was evaluated by calculation of the non-parametric Spearman correlation coefficient and the respective level of significance (STATISTIC 4.0 for Windows, Statsoft, Inc. 1993), while the possible significance of the differences observed in the mean score of each functional complex for each age class was evaluated by the ANOVA single factor test (Ms Excel 2000).

The significance of the differences between the mean scores of males and females and of some occupational classes was assessed by Student's t test.

The analysis of scores allowed testing the interpretative possibilities offered by the 5-grades-standard, while the analysis of the frequencies allowed testing the interpretative possibilities offered by a standard with a lesser number of degrees, in this case only 2 degrees (low to medium and high to very high development). As the purpose of our work is to define a useful new scoring method, the results of the application of the preliminary methodology to the study of the sample of known age, sex and occupation will be only briefly discussed, focusing in particular on the comparison, for age and sex grouping, between the results obtained calculating the »scores« and the frequencies respectively.

Relation between degree of development and age

The individual scores provide a basic outline of the relationship between the general degree of development and age. Table 3 shows that the mean score for each functional complex and for the upper and lower limbs increases significantly in the three age classes. Moreover, the Spearman correlation coefficient shows a significant positive correlation between the score of each individual and age, for all the skeletal regions examined. In general, the correlation is higher for the lower limb (Table 3).

The frequencies of the »low-medium« (degrees 0+1+2) and »high« (degrees 3+4) developmental classes for each entheses also show an increase of development with age (Table 4). This increase is statistically significant in many cases, in particular for all the entheses of the lower limb but the *m. iliopsoas* entheses.

Increased robusticity with age is evident in spite of the small number of »old« adults, both considering the scores and the frequencies. This trend has been observed by various Authors^{2,19,23,24}. Indeed, it is expected for traits influenced by mechanical loading, since even slight but prolonged mechanical stresses can cause high enthesal development. The effect of age is more evident for the entheses of the lower limbs, maybe in relation to the carrying function of these limbs. For the upper limbs, the

TABLE 4
 FREQUENCY DISTRIBUTION (%) OF »HIGH« DEVELOPMENT (DEGREES 3+4) FOR EACH ENTESIS BY AGE CLASS, ALONG WITH THE p VALUE OF χ^2 TEST AMONG THE AGE CLASSES

Enthesis	Left						p	Right						p	
	20–29		30–39		>40			20–29		30–39		>40			
	N	%	N	%	N	%		N	%	N	%	N	%		
Shoulder	Costoclavicular lig. (clav.)	49	46.94	24	33.33	13	69.23	0.112	47	44.68	25	40.00	14	71.43	0.140
	Conoid lig. (clav.)	54	33.33	26	42.31	13	46.15	0.586	52	30.77	26	38.46	14	50.00	0.391
	Trapezoid lig. (clav.)	54	20.37	26	15.38	13	23.08	0.813	52	25.00	26	26.92	14	14.29	0.645
	M. pectoralis major (clav.)	52	21.15	26	23.08	13	61.54	0.012	52	36.54	26	42.31	14	78.57	0.019
	M. deltoideus (clav.)	53	37.74	26	50.00	13	61.54	0.243	52	42.31	26	46.15	14	64.29	0.342
	M. pectoralis major (huM.)	51	76.47	27	51.85	15	93.33	0.009	49	77.55	27	51.85	15	93.33	0.008
	M. lat.dorsii/teres M. (huM.)	50	50.00	27	59.26	15	73.33	0.263	48	45.83	26	50.00	15	60.00	0.631
	M. deltoideus (huM.)	52	42.31	27	51.85	15	93.33	0.002	50	46.00	27	44.44	15	93.33	0.003
Elbow	M. triceps brachii (scap.)	53	15.09	27	18.52	15	40.00	0.101	53	18.87	27	37.04	15	40.00	0.111
	M. brachioradialis (huM.)	49	36.73	27	59.26	15	53.33	0.140	49	40.82	27	62.96	15	60.00	0.132
	M. biceps brachii (radius)	51	9.80	27	18.52	15	0.00	0.169	51	9.80	27	18.52	15	6.67	0.418
	M. triceps brachii (ulna)	49	12.24	27	37.04	15	46.67	0.007	48	14.58	24	41.67	15	53.33	0.004
	M. brachialis (ulna)	52	32.69	27	25.93	15	53.33	0.190	50	42.00	27	25.93	15	53.33	0.181
Fore-arm	M. pronator teres (radius)	50	2.00	27	3.70	15	13.33	0.165	50	2.00	27	3.70	15	26.67	0.002
	Interosseous membr. (radius)	49	6.12	27	11.11	15	20.00	0.280	50	4.00	26	15.38	15	13.33	0.199
	M. supinator (ulna)	53	43.40	27	55.56	15	80.00	0.041	51	29.41	27	51.85	15	80.00	0.002
Hip	M. gluteus maximus (femur)	53	26.42	26	53.85	14	78.57	0.001	51	25.49	27	51.85	14	78.57	0.001
	M. iliopsoas (femur)	51	78.43	27	81.48	13	76.92	0.931	49	65.31	27	66.67	13	76.92	0.726
Knee	M. vastus medialis (femur)	53	18.87	26	38.46	15	46.67	0.048	51	13.73	27	33.33	15	46.67	0.016
	Quadriceps tendon (tibia)	46	32.61	26	73.08	15	73.33	0.001	47	31.91	26	65.38	14	78.57	0.001
	Quadriceps tendon (patella)	49	14.29	24	25.00	12	50.00	0.027	45	20.00	24	25.00	13	46.15	0.163
Foot	M. soleus (tibia)	48	29.17	26	53.85	15	73.33	0.005	51	23.53	27	51.85	15	66.67	0.003
	Achilles tendon (calcaneus)	46	28.26	24	66.67	13	76.92	0.001	48	33.33	27	55.56	13	76.92	0.011

extra mechanical loading due to occupation, influencing especially the young and mature adults, could be responsible for the »mitigation« of the age effect on enthesal development.

Relation between degree of development and sex

Student’s t test applied to the scores of males and females between 30 and 39 years shows that the sex differences are not significant (Table 5).

The frequencies reveal that sex differences are only significant in a few cases (*m. supinator*, *m. iliopsoas* and quadriceps tendon), with higher development in males (Table 6). The greater development of two enteses of the lower limbs of men could be in relation to the fact that they were involved in activities that likely required greater use of these limbs (farmers, miners, weight carriers, etc.) respect to the women that were all housewives.

The results obtained could be influenced by the small sample size. In any case, it should be noted that both the

scores and the frequencies show that some functional complexes and some enteses present higher development in one sex while others are more developed in the other. Thus, the differences between the sexes could reflect functional differences, since an inhomogeneous pattern of higher or lower development in one of the two sexes makes the influence of intrinsically sex-related factors less likely.

Observations regarding the occupations

Because of sampling problems, Tables 7 and 8 only report the mean scores and respective t test results of farmers, masons, cobblers and merchants between 20 and 39 years old. Individuals over 40 years of age were not considered, because of the marked influence of age on the entesis development. In general, merchants present lower mean development and lower CV than other occupations (Table 7). The higher mean score of cobblers, especially for the lower limb, could be in relation to the very small sample size. Significant differences among oc-

TABLE 5
MEAN SCORE, STANDARD DEVIATION AND COEFFICIENT OF VARIATION FOR EACH FUNCTIONAL COMPLEX AND UPPER AND LOWER LIMBS, OF LEFT AND RIGHT SIDES, IN MALES AND FEMALES (30–39 Y.), AND THE p VALUE OF STUDENT'S t TEST

	Males				Females				p	
	N	X	SD	CV	N	X	SD	CV		
Left	Shoulder	26	2.29	0.37	16.22	17	2.37	0.28	11.83	0.492
	Elbow	27	2.25	0.34	15.10	17	2.26	0.36	16.05	0.906
	Forearm	27	1.95	0.54	27.92	16	1.98	0.51	25.70	0.866
	Hip	26	2.81	0.58	20.81	16	2.53	0.50	19.71	0.124
	Knee	26	1.96	0.57	28.97	17	1.73	0.53	30.72	0.179
	Foot	26	2.67	0.66	24.78	17	2.35	0.55	23.48	0.106
	Upper limb	26	2.22	0.31	13.92	16	2.30	0.24	10.58	0.399
	Lower limb	26	2.41	0.45	18.89	16	2.15	0.43	19.75	0.078
	Up+low limb	25	2.27	0.30	13.19	17	2.23	0.27	12.07	0.665
Right	Shoulder	26	2.33	0.40	17.12	17	2.37	0.28	11.71	0.707
	Elbow	27	2.29	0.38	16.65	17	2.31	0.41	17.68	0.844
	Forearm	27	2.00	0.51	25.74	16	1.98	0.52	26.43	0.899
	Hip	27	2.78	0.61	21.95	16	2.53	0.46	18.34	0.171
	Knee	27	1.95	0.58	29.49	17	1.75	0.58	33.26	0.281
	Foot	27	2.63	0.63	23.93	17	2.26	0.64	28.27	0.070
	Upper limb	26	2.27	0.35	15.49	16	2.30	0.28	12.18	0.749
	Lower limb	27	2.39	0.38	16.03	16	2.15	0.47	21.70	0.069
	Up+low limb	27	2.30	0.31	13.31	17	2.24	0.28	12.54	0.497

cupations have been found between farmers and merchants for the entire lower limbs and the right foot (Table 8). In this case, an influence of mechanical loading is very likely.

The small sample sizes of the occupational classes, with the exception of farmers, make it useless to analyse the frequencies of the degrees of development.

Results and Discussion

Third phase

For the final definition of the scoring standard, we considered the results and observations obtained in the first two phases of the study, which showed that:

- the intraobserver error using the standard with 5 degrees of development is high (around 28%), even if it must be pointed out that most of the errors concern adjacent classes of development.
- age is the main factor influencing the degree of enthesal development.
- the subdivision into 5 developmental classes, implying a great fragmentation of the sample (already subdivided by sex and age), could not be used for calculation of frequencies, even if it has been useful for the calculation of the individual »score«.
- the study of the relationship of robusticity with age and sex using the »score« (that implies the use of the 5-degrees-standard) provided results in general consis-

tent with those obtained using the frequencies derived by pooling the first three degrees (0+1+2) of development and the last two (3+4). It is worth noting that the »score« emphasizes especially the effect of age on enthesal development.

Therefore, for the definitive version of the scoring standard, we decided to reduce the degrees of development of robusticity to three: degree 1 includes weak to medium enthesal development; degree 2 corresponds to strong development, and degree 3 is reserved for very strong development of the enthesis, albeit not in an enthesopathic form. In this way, both the intraobserver and interobserver error were around 20%. In view of the qualitative nature of the observed traits, their great variability and the fact that the scoring was performed by well-trained personnel, these values were considered acceptable and the standard was judged to be suitable for use. Nevertheless, subcategories (1a, 1b and 1c) have been maintained for degree 1, corresponding to the »very slight«, »low« and »medium« degrees of development; these subcategories can be used as indicative values or when one is able to examine a fairly large skeletal series.

In general, if one wants to consider the frequencies of the different degrees of development, it is advisable to use only the 3 main degrees of development, or even only degree 1 and 2+3: the use of more degrees would lead to fragmentation of the sample, making interpretation of the results difficult. When the subcategories of degree 1 are considered, one effectively obtains a scale with 5 de-

TABLE 6
 FREQUENCY DISTRIBUTION (%) OF »HIGH« DEVELOPMENT (DEGREES 3+4) FOR EACH ENTESIS BY SEX (30–39 Y.) AND
 THE p VALUE OF FISHER'S TEST

Enthesis	Left					Right					
	M		F		p	M		F		p	
	N	%	N	%		N	%	N	%		
Shoulder	Costoclavicular lig. (clav.)	24	33.33	17	23.53	0.7289	25	40.00	17	35.29	1.0000
	Conoid lig. (clav.)	26	42.31	17	29.41	0.5230	26	38.46	17	29.41	0.7478
	Trapezoid lig.(clav.)	26	15.38	17	29.41	0.4448	26	26.92	17	29.41	1.0000
	M. pectoralis major (clav.)	26	23.08	17	11.76	0.4462	26	42.31	17	17.65	0.1107
	M. deltoideus (clav.)	26	50.00	17	70.59	0.2194	26	46.15	17	64.71	0.3495
	M. pectoralis major (huM.)	27	51.85	17	64.71	0.5351	27	51.85	17	70.59	0.3455
	M. lat.dorsii/teres M. (huM.)	27	59.26	16	75.00	0.3415	26	50.00	16	75.00	0.1949
	M. deltoideus (huM.)	27	51.85	17	70.59	0.3455	27	44.44	17	76.47	0.0605
Elbow	M. triceps brachii (scap.)	27	18.52	17	11.76	0.6886	27	37.04	16	12.50	0.1580
	M. brachioradialis (huM.)	27	59.26	17	41.18	0.3539	27	62.96	16	37.50	0.1267
	M. biceps brachii (radius)	27	18.52	16	31.25	0.4596	27	18.52	16	31.25	0.4596
	M. triceps brachii (ulna)	27	37.04	16	18.75	0.3072	24	41.67	16	18.75	0.1770
	M. brachialis (ulna)	27	25.93	17	41.18	0.3340	27	25.93	17	52.94	0.1083
Forearm	M. pronator teres (radius)	27	3.70	16	6.25	1.0000	27	3.70	16	12.50	0.5449
	Interosseous membrane (radius)	27	11.11	16	31.25	0.1250	26	15.38	15	33.33	0.2476
	M. supinator (ulna)	27	55.56	16	6.25	0.0012	27	51.85	16	6.25	0.0028
Hip	M. gluteus maximus (femur)	26	53.85	16	43.75	0.7513	27	51.85	16	43.75	0.7546
	M. iliopsoas (femur)	27	81.48	16	43.75	0.0181	27	66.67	16	43.75	0.2035
Knee	M. vastus medialis (femur)	26	38.46	16	43.75	0.7570	27	33.33	16	37.50	1.0000
	Quadriceps tendon (tibia)	26	73.08	17	29.41	0.0109	26	65.38	17	41.18	0.2086
	Quadriceps tendon (patella)	24	4.17	17	5.88	1.0000	24	8.33	16	6.25	1.0000
Foot	M. soleus (tibia)	26	53.85	17	35.29	0.3495	27	51.85	17	29.41	0.2133
	Achilles tendon (calcaneus)	24	66.67	16	50.00	0.3387	27	55.56	15	46.67	0.7488

degrees of development, which can be used to calculate the score (to obtain score values comparable with those presented in this study, you should attribute the value 0 to degree 1a, 1 to degree 1b, 2 to degree 1c, 3 to degree 2 and 4 to degree 3). However, the attribution errors will be greater in this case; therefore, it is advisable to use this more detailed scale only when it is possible to sort the bones to be scored into a series reflecting the graded development of the individuals, at least in relative terms.

With regard to interpretation of the resulting data, the characteristics of enteses have a multifactorial etiology, and the single factors and their relative contribution to the expression of the traits are very difficult (sometimes impossible) to assess^{2,3}. Thus, a functional interpretation of enteses robusticity requires the subdivision of the sample by age and sex. Our studies show that age is the main factor responsible for the degree of development of robusticity and of the type and degree of development of enthesopathies. A high, generalised enthesal development in one individual seems to be a rather good »old« age indicator! Hence, only high degrees

of development involving only some enteses, or an evident asymmetry of development in skeletons of young or mature adults can provide reliable indications about mechanical loading. Pathological conditions or the results of traumas which could interfere with the development of particular characteristics of the enteses, should also be taken into account.

The definitive standardised scoring method, consisting of the description of the possible developmental classes of each entesis and their photographic documentation, is fully reported in Appendix 1. The complete standardised data collection form, also allowing the scoring of enthesopathies (whose standard has already been published³), is reported in Appendix 2. The form allows one to put in the first line the identification label for the specimen to be studied (for example: Tomb 1). In the second line one should mark the corresponding sex (M= male, F=female, NI=sex not identified) and age class (YA, MA, OA, NI). Then, one can fill in the form by marking the degree of robusticity development (NR when the trait is not recordable), EF and OL for the bones of the two

TABLE 7
MEAN SCORE, STANDARD DEVIATION AND COEFFICIENT OF VARIATION FOR EACH FUNCTIONAL COMPLEX AND UPPER AND LOWER LIMBS, OF LEFT AND RIGHT SIDES, IN FARMERS, MASONS, COBBLERS AND MERCHANTS (20–39 Y.)

		Farmers				Masons				Cobblers				Merchants			
		N	X	SD	CV	N	X	SD	CV	N	X	SD	CV	N	X	SD	CV
Left	Shoulder	29	2.24	0.44	19.48	9	2.30	0.53	22.95	5	2.49	0.42	16.88	8	2.29	0.20	8.88
	Elbow	29	2.09	0.40	19.29	10	2.12	0.46	21.67	5	2.00	0.49	24.49	9	1.95	0.24	12.56
	Forearm	29	1.64	0.56	33.82	10	1.63	0.71	43.51	5	1.93	0.95	49.37	9	1.63	0.48	29.72
	Hip	28	2.71	0.60	22.10	10	2.40	0.81	33.74	5	3.00	0.71	23.57	9	2.33	0.61	26.24
	Knee	27	1.73	0.50	28.98	9	1.37	0.63	46.22	5	1.80	0.80	44.60	9	1.46	0.33	22.63
	Foot	27	2.33	0.60	25.91	9	2.17	0.66	30.53	5	2.40	0.42	17.43	9	2.00	0.43	21.65
	Upper limb	29	2.09	0.36	17.19	9	2.16	0.49	22.52	5	2.24	0.51	22.66	8	2.07	0.14	6.65
	Lower limb	27	2.18	0.37	17.12	8	1.87	0.66	35.12	5	2.31	0.57	24.85	9	1.87	0.33	17.86
	Up+low limb	27	2.16	0.25	11.35	8	2.07	0.52	24.95	5	2.27	0.51	22.44	8	1.99	0.14	6.84
Right	Shoulder	29	2.31	0.44	19.23	8	2.35	0.39	16.81	5	2.56	0.37	14.42	8	2.32	0.17	7.43
	Elbow	29	2.17	0.40	18.20	10	2.12	0.49	23.19	4	1.95	0.50	25.64	9	2.02	0.12	5.94
	Forearm	29	1.66	0.56	33.82	10	1.47	0.74	50.48	5	1.83	1.12	60.98	9	1.52	0.41	27.13
	Hip	27	2.57	0.58	22.67	10	2.55	0.76	29.88	5	3.00	0.71	23.57	9	2.39	0.60	25.16
	Knee	27	1.74	0.49	27.89	9	1.41	0.64	45.52	5	1.80	0.90	50.03	9	1.54	0.37	24.11
	Foot	29	2.33	0.50	21.69	9	2.22	0.62	27.81	6	2.25	0.52	23.31	9	1.94	0.39	20.10
	Upper limb	29	2.16	0.38	17.74	8	2.13	0.45	21.15	4	2.18	0.53	24.27	8	2.08	0.13	6.25
	Lower limb	27	2.16	0.35	16.06	9	1.98	0.60	30.24	5	2.29	0.65	28.30	9	1.91	0.26	13.61
	Up+low limb	26	2.21	0.25	11.46	7	2.06	0.51	25.04	5	2.30	0.55	24.10	9	2.04	0.13	6.49

TABLE 8
THE p VALUE OF STUDENT'S t TEST BETWEEN COMPARED PAIRS OF OCCUPATIONS

		Farm./mas.	Farm./merch.	Farm./cobbl.	Mas./merch.	Mas./cobbl.	Merch./cobbl.
		Left	Shoulder	0.751	0.629	0.246	0.988
Elbow	0.860		0.340	0.664	0.350	0.661	0.800
Forearm	0.963		0.946	0.342	0.990	0.502	0.438
Hip	0.203		0.108	0.346	0.843	0.183	0.089
Knee	0.087		0.141	0.809	0.703	0.289	0.413
Foot	0.489		0.137	0.816	0.536	0.493	0.120
Upper limb	0.619		0.783	0.406	0.578	0.775	0.483
Lower limb	0.233		0.032	0.515	0.993	0.242	0.088
Up+low limb	0.671		0.067	0.665	0.650	0.529	0.290
Right	Shoulder	0.831	0.926	0.256	0.859	0.367	0.144
	Elbow	0.728	0.078	0.310	0.556	0.571	0.793
	Forearm	0.404	0.504	0.743	0.855	0.457	0.572
	Hip	0.919	0.419	0.156	0.618	0.290	0.112
	Knee	0.109	0.259	0.892	0.607	0.359	0.561
	Foot	0.607	0.044	0.736	0.271	0.929	0.217
	Upper limb	0.870	0.396	0.926	0.785	0.878	0.751
	Lower limb	0.396	0.053	0.698	0.763	0.384	0.270
	Up+low limb	0.458	0.060	0.754	0.942	0.454	0.361

sides. In the case of asymmetry with no difference of degree (e.g. degree 2 on both the left and right side, but with the left more developed), one should mark a »+« near the degree of the most developed side.

Conclusion

With the present study and the preceding one³, we provide a standardised method to score the robusticity of entheses and the possible presence and degree of development of enthesopathies. The scoring standard for robusticity is specific for each of the 23 considered entheses, while that for the enthesophytic (EF) and osteolytic (OL) enthesopathies is applicable to any of them. The standard consists of the description of the different degrees of development for each enthesis and the corresponding photographic representation. The proposed method is a useful tool for reducing subjectivity in the scoring of these traits, thus allowing a more reliable comparison of the results of different studies. However, it should be underlined that use of the standard requires adequate training, including experience in observing the entheses, which is necessary to familiarize the observer with their extreme variability. Photographic documentation of the variability of the different degrees of development is useful, but no substitute for the experience of the scorer. The interobserver error of 20% is considered acceptable for these continuously variable qualitative traits.

The standard for enthesal robusticity includes three degrees of development: low-medium (degree 1), high (degree 2) and very high (degree 3). The first degree is further divided into three subcategories: slight impression (or an extremely low development – degree 1a), low

(1b) and medium development (1c). This makes the standard a flexible working tool, adaptable to the experience and requirements of the scorer.

The proposed scoring method has proved to be a useful tool for the study of past populations. Its application to various osteoarchaeological series has allowed us to formulate interesting functional hypotheses that have been confirmed by archaeological and historical evidence^{30–36}.

Our research group has also worked on the standardisation of the scoring of several cranial entheses (masticatory muscles and ligaments of the temporomandibular joint)^{37–39}, and similar work is in progress for other postcranial insertion sites and for the extension of articular surfaces and accessory articular areas. The next step in the study of the so-called »activity markers« should be to better understand their interpretative possibilities, in particular through a deep investigation of their relationship with age, sex and occupation. For this purpose, the complete investigation of the identified collections of the Museum of Anthropology of the University of Bologna (Frassetto collections²⁵, about 1000 skeletons of adult individuals of known sex, age and occupation) has been undertaken, and we hope the results of this study will soon be available.

Acknowledgements

The authors wish to thank Prof. Olivier Dutour, Prof. Patricia Brasili and Dr. Benedetta Bonfiglioli for useful discussions. The authors wish also to thank the anonymous Reviewers for useful suggestions to improve this paper.

REFERENCES

- HAWKEY DE, MERBS CF, *Int J Osteoarchaeol*, 5 (1995) 324. — 2. MARIOTTI V, *Ricerche metodologiche sugli indicatori scheletrici morfologici di attività*, PhD Thesis, In Italian, (University of Bologna, Bologna, 1998). — 3. MARIOTTI V, FACCHINI F, BELCASTRO MG, *Coll Antropol*, 28 (2004) 145. — 4. PAOLAGGI JB, *Presse Med*, 16 (1987) 285. — 5. DUTOUR O, *Am J Phys Anthropol*, 71 (1986) 221. — 6. FOURNIÉ B, FOURNIÉ A, *La Lettre du Rhumatologue*, 92 (1987) 15. — 7. LAGIER R, *Enthèse normale et enthesopathies*. In: SIMON L, HÉRISSON C, RODINEAU J (Eds), *Pathologie des insertions et enthesopathies* (Masson, Paris, 1991). — 8. STIRLAND A, *Diagnosis of occupationally related paleopathology: can it be done?* In: ORTNER DJ, AUFDERHEIDE AC (Eds), *Human paleopathology: current synthesis and future options* (Smithsonian Institution Press, Washington, 1991). — 9. STIRLAND AJ, *Int J Osteoarchaeol*, 8 (1998) 354. — 10. WILCZAK CA, KENNEDY KAR, *Mostly MOS: technical aspects of identification of skeletal markers of occupational stress*. In: REICHS KJ (Ed), *Forensic Osteology. Advances in the identification of human remains* (Charles C. Thomas publisher, Springfield, 1998). — 11. CAPASSO L, KENNEDY KAR, WILCZAK CA, *Atlas of occupational markers on human remains* (Edigrafital, Teramo, 1999). — 12. KENNEDY KAR, *J Forensic Sci*, 28 (1983) 871. — 13. BORGOGNINI TARLI SM, REPETTO E, *Human Evolution*, 1 (1986) 331. — 14. KELLEY JO, ANGEL JL, *Am J Phys Anthropol*, 74 (1987) 199. — 15. MOLLESON T, *Antiquity*, 63 (1989) 356. — 16. MOLLESON T, *Le Scienze*, 314 (1994) 82. — 17. ROBB J, *Human Evolution*, 9 (1994) 215. — 18. GALERA V, GARRALDA MD, *Int J Anthropol*, 8 (1993) 247. — 19. CUNHA E, UMBELINO C, *Antrop Port*, 13 (1995) 49. — 20. PETERSON J, *Int J Osteoarchaeol*, 8 (1998) 378. — 21. WEISS E, *Am J Phys Anthropol*, 125 (2004) 232. — 22. HAWKEY DE, *Use of upper extremity entheso-*

- pathies to indicate habitual activity patterns*, [MA Thesis], (Arizona State University, Tempe, 1988). — 23. ROBB J, *Issues in the skeletal interpretation of muscle attachments*, [not published], (Paper presented at the Annual Meeting of the Paleoanthropology Society, Anaheim, California, 1994). — 24. ROBB JE, *Int J Osteoarchaeol*, 8 (1998) 363. — 25. FACCHINI F, MARIOTTI V, BONFIGLIOLI B, BELCASTRO MG, *Supplément au Bulletin Archéologique de Provence*, 4 (2006) 67. — 26. BUIKSTRA JE, UBELAKER DH, *Standards for data collection from human skeletal remains* (Arkansas Archeological Survey Research Series No. 44, Fayetteville, 1994). — 27. CAVALLI SFORZA L, *Analisi statistica per medici e biologi* [in Italian] (Bollati Boringhieri, Torino, 1965). — 28. COLTON T, *Statistica in medicina* [in Italian] (Piccin, Padova, 1979). — 29. HAMILTON LC, *Modern data analysis: a first course in applied statistics* (Belmont, Wadsworth, 1990). — 30. BELCASTRO MG, FACCHINI F, MARIOTTI V, *Skeletal evidence in the shoulder of the weapon use in osteoarchaeological materials*. In: *Abstracts. XII Congreso de la Sociedad Española de Antropología Biológica*, Bellaterra-Cerdanyola del Vallès, 2000). — 31. BELCASTRO MG, FACCHINI F, NERI R, MARIOTTI V, *J of Paleopathology*, 13 (2001) 9. — 32. BELCASTRO MG, GALLETTI L, BOSI A, GUALDI RUSSO E, *Before the Advent of Ergonomy. The Skeletal Markers of Activity*. In: *Proceedings. (3rd International Congress on »Science and Technology for the Safeguard of Cultural Heritage in the Mediterranean Basin«*, Alcalá de Henares, Litoflash srl, Roma, 2001). — 33. MARIOTTI V, *Skeletal markers of activity in the warriors from the Celtic necropolis of Casalecchio di Reno (Bologna, Italy) (IV-III c. BC)*. In: *Proceedings. XIII Congresso degli Antropologi italiani*, CESI, Roma, 2001). — 34. MARIOTTI V, CONDEMI S, BELCASTRO MG, FACCHINI F, *The Mesolithic necropolis of Taforal: the skeletal markers of activity* (prelim-

inary results). In: Pre-prints. (XIV UISPP Congress, University of Liège, 2001). — 35. MARIOTTI V, BONFIGLIOLI B, BELCASTRO MG, FACCHINI F, CONDEMI S. The contribution of the anthropological study to the reconstruction of the life style of the Epipaleolithic population of Taforalt (Morocco). Preliminary report. In: Proceedings. (Section 7. The Mesolithic. XIVth UISPP Congress, University of Liège, BAR International Series 1302, Oxford, 2004). — 36. BELCASTRO MG, MARIOTTI V, FACCHINI F, BONFIGLIOLI B, Period Biol, 108, (2006) 319. — 37. MARIOTTI V, BONFIGLIOLI B, BELCASTRO MG, FACCHINI F, CONDEMI

S, Alterations of the temporomandibular joint (TMJ) in the Epipaleolithic population from Taforalt (Morocco). In: Abstracts. (14th European Meeting of the Paleopathology Association, Coimbra, 2002). — 38. MARIOTTI V, BONFIGLIOLI B, BELCASTRO MG, FACCHINI F, CONDEMI S, Bull Mem Soc Anthropol Paris, 14 (2002) 219. — 39. MARIOTTI V, BONFIGLIOLI B, FACCHINI F, BELCASTRO MG, Il complesso funzionale oro-masticatorio: proposta di un metodo di studio sul cranio dei caratteri muscolari, articolari e dento-alveolari [in Italian] In: Riassunti. (XV Congresso degli Antropologi Italiani, Chieti 2003).

V. Mariotti

Department of Experimental Evolutionary Biology, Anthropology Unit, University of Bologna, via Selmi 3,
40126 Bologna, Italy
e-mail: valemari@alma.unibo.it

ISTRAŽIVANJE HVATIŠTA MIŠIĆA – PRIJEDLOG STANDARDIZIRANE METODE OCJENJIVANJA 23 HVATIŠTA NA POSTKRANIJALNOM KOSTURU

SAŽETAK

Enteze su uvijek vidljive na kostima, ali u različitim formama i s različitom izraženošću. Termin »robucitet« označava »normalnu« koštanu razvijenost na entezama, dok »entezopatija« ukazuje na prisutnost entezopatija ili osteolitičkih područja. Metoda ocjenjivanja razvoja entezopatija već postoji od ranije. U ovom radu se predlaže standardizirana deskriptivna i fotografska metoda ocjenjivanja robuciteta 23 enteze postkranijalnog kostura. Za svaku entezu opisane su 3 razvojne razine, koje uglavnom odgovaraju slaboj do umjerenoj izraženosti (stupanj 1), jakoj izraženosti (stupanj 2) i vrlo jakoj izraženosti (stupanj 3). Odstupanje u procjeni različitih promatrača od oko 20% čini se prihvatljivim, uzmu li se u obzir velike morfološke varijacije ovih svojstava.

APPENDIX 1 – p.p. 302–312

APPENDIX 2 – p. 313

Appendix 1: Standard for the Scoring of Developmental Degrees of Some Entheses of The Postcranial Skeleton

The entheses are indicated by the names of the muscles or ligaments inserted on them.

NB: When the enthesis is affected by a degree 3 osteolytic enthesopathy (presence of several small areas of erosion – ca. 4 mm in length or diameter – or at least one extensive and deep osteolytic area – >4 mm in length or diameter)³, the robusticity is usually not recordable (NR). This occurs most often at the attachment sites of the costoclavicular ligament on the clavicle, *mm. pectoralis major* and *latissimus dorsi/teres major* on the humerus and *m. soleus* on the tibia.

Enthesophytes³ can be present in association to every degree of robusticity (Figure 1), but in some cases (*m. triceps brachii* on the ulna, quadriceps tendon on the patella and tibia, Achilles tendon on the calcaneus) they are usually associated to degree 3 of robusticity.

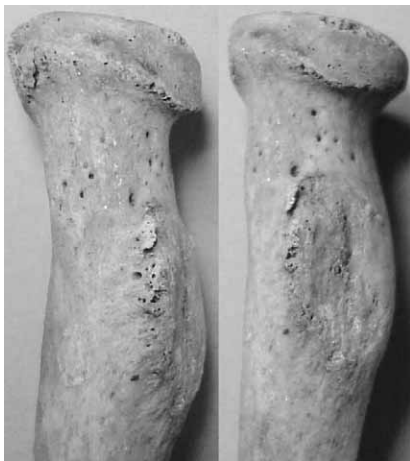

Fig. 1. *M. biceps brachii* enthesis on a right radius, with degree 1c robusticity and a degree 2 (1–4 mm) enthesophyte.

Scapula

M. triceps brachii (Figure 2)

1. a – slight impression: the profile of the infraglenoid tubercle does not interrupt the profile of the axillary border of the scapula; the surface is smooth. b – low development: the infraglenoid tubercle interrupts the profile of the axillary border, assuming an oblong crest-like or roughly triangular shape in frontal view; the surface is smooth or moderately rugose. c – medium development: the same as degree 1b, but the surface is rugose.
2. high development: the infraglenoid tubercle emerges as a distinct formation of the axillary border, assuming the form of a real tubercle or crest. The surface is irregular or rugose.
3. very high development: the infraglenoid tubercle, in the form of a tubercle or crest, is very prominent and rugose.

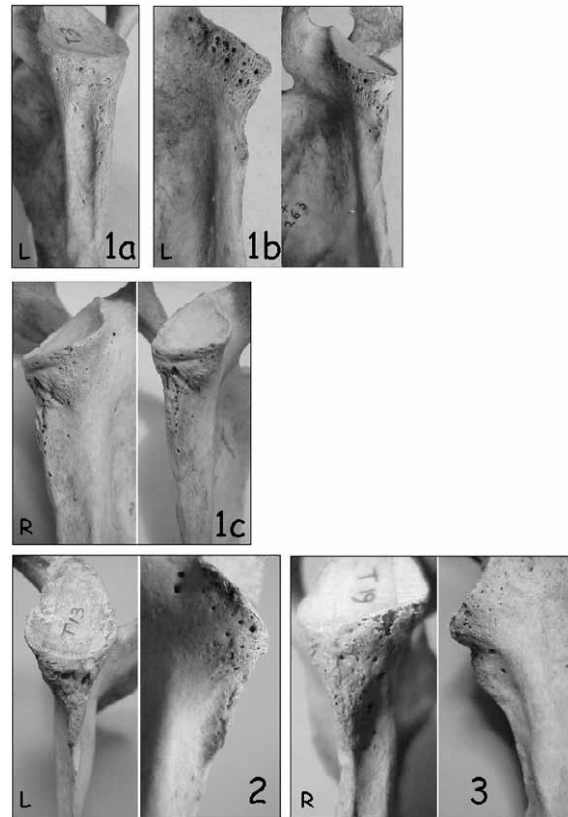


Fig. 2. Photographic standard for the developmental degrees of robusticity (1a, 1b, 1c, 2, 3) of the scapular enthesis of *m. triceps brachii*. Photos in the same frame show the same bone from different points of view. R – right bone, L – left bone.

Clavicle

Costoclavicular ligament (Figure 3)

1. a – slight impression: the area of insertion is identifiable only by slight irregularity of the surface; b – low development: the impression presents an irregular surface and is delimited by discontinuous margins; it can be slightly depressed or raised; c – medium development: the impression, slightly raised or depressed, is delimited by well-defined margins and the surface is irregular or rugose.
2. high development: impression strongly developed, raised or depressed, with an irregular or rugose surface. The margins are generally well-defined; the posterior margin is often more developed than the anterior.
3. very high development: as above, but with a »lipped« margin (usually the posterior).

Conoid ligament (Figure 4)

1. a – slight impression: the postero-inferior angle of the acromial extremity is rounded and may present only a slightly irregular surface; b – low development: there is only thickening of the postero-inferior angle of the bone or a small tubercle; the borders of the area of insertion are not clearly identifiable; the surface is more or less irregular; c – medium development: there is a small tubercle or a raised elongated area with rough surface.

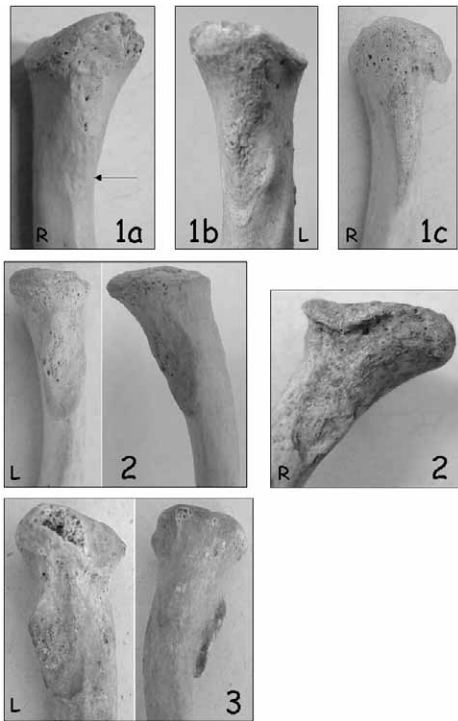


Fig. 3. Photographic standard for the developmental degrees of robusticity (1a, 1b, 1c, 2, 3) of the clavicular entheses of costoclavicular ligament. Photos in the same frame show the same bone from different points of view. R – right bone, L – left bone.

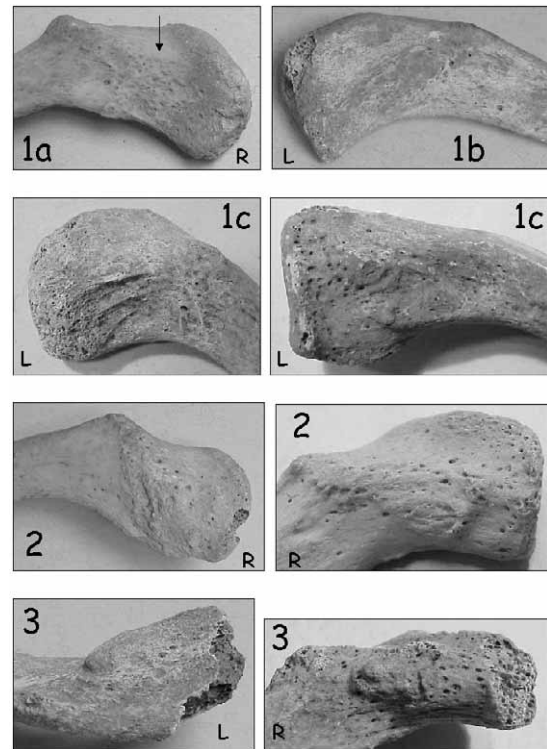


Fig. 5. Photographic standard for the developmental degrees of robusticity (1a, 1b, 1c, 2, 3) of the clavicular entheses of trapezoid ligament. R – right bone, L – left bone.

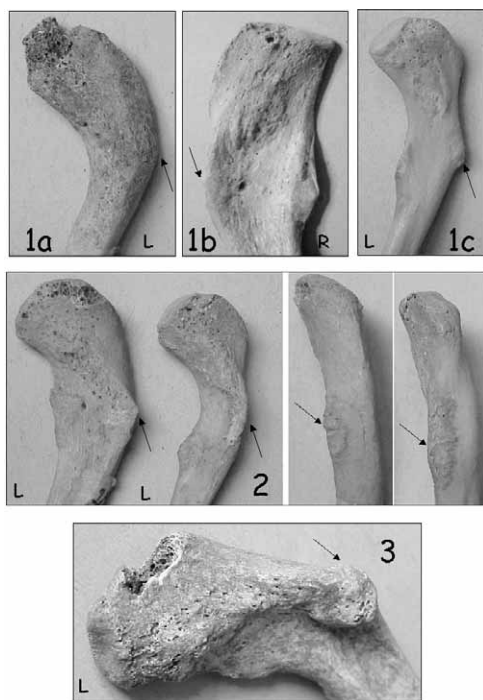


Fig. 4. Photographic standard for the developmental degrees of robusticity (1a, 1b, 1c, 2, 3) of the clavicular entheses of conoid ligament. Photos in the same frame show the same bone from different points of view. R – right bone, L – left bone.

2. high development: the tubercle or «crest» is well developed and presents a rough surface.
3. very high development: the tubercle or «crest» is very protruding.

Trapezoid ligament (Figure 5)

1. a – slight impression: the area of insertion is barely distinguishable; b – low development: the area of insertion is indicated only by slight surface irregularity and is on the same plane as the surface of the clavicle; c – medium development: the area of insertion is rugose, but on the same plane as the surface of the clavicle.
2. high development: the area of insertion is rugose and usually raised; in some cases, it may be depressed; however, it is not on the same plane as the surrounding zone.
3. very high development: the attachment area is rugose and very raised or depressed.

M. pectoralis major (Figure 6)

1. the anterior surface of the sternal half of the «shaft» is: a – slight impression: rounded with smooth or slightly irregular surface; b – low development: slightly flattened and the surface is smooth or slightly irregular; c – medium development: flattened and the surface is smooth or slightly irregular.
2. high development: marked flattening, possibly extending to more than half the length of the bone and/or with irregular surface.

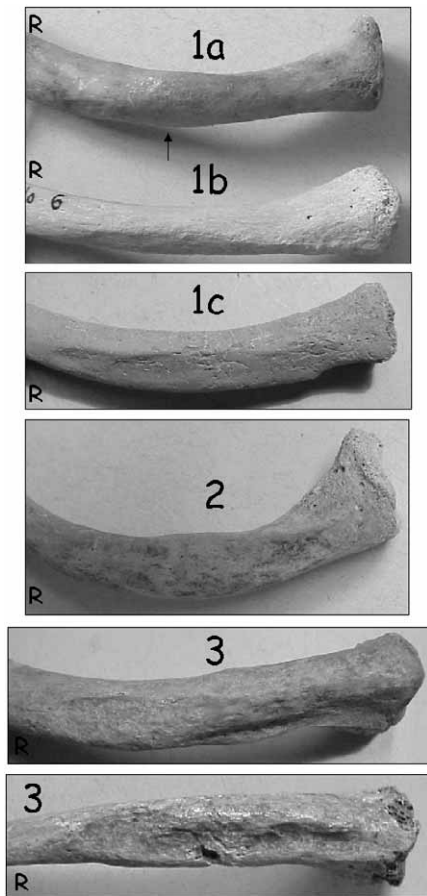


Fig. 6. Photographic standard for the developmental degrees of robusticity (1a, 1b, 1c, 2, 3) of the clavicular enthesis of *m. pectoralis major*. R – right bone, L – left bone.

3. very high development: marked flattening and rough surface, sometimes with crests and *sulci*.

M. deltoideus (Figure 7)

1. a – slight impression: the anterior margin of the acromial half is rounded and the surface is smooth; b – low development: the anterior margin of the acromial half is rounded and its surface is irregular; c – medium development: the margin is rounded, but the surface is rugose, or the margin is interrupted by a slight prominence with a rugose surface.
2. high development: the profile of the anterior margin is no longer regularly curved (viewed from above or below), but is interrupted by a prominence (at times sharp, at times thicker), or there is a very accentuated rugosity.
3. very high development: as above, but the prominence is very evident and/or the rugosity extends onto a relatively large area of the superior surface of the clavicle.

Humerus

M. pectoralis major (Figure 8)

1. the crest of the greater tubercle is: a – slight impression: only slightly raised and its surface is smooth; b –

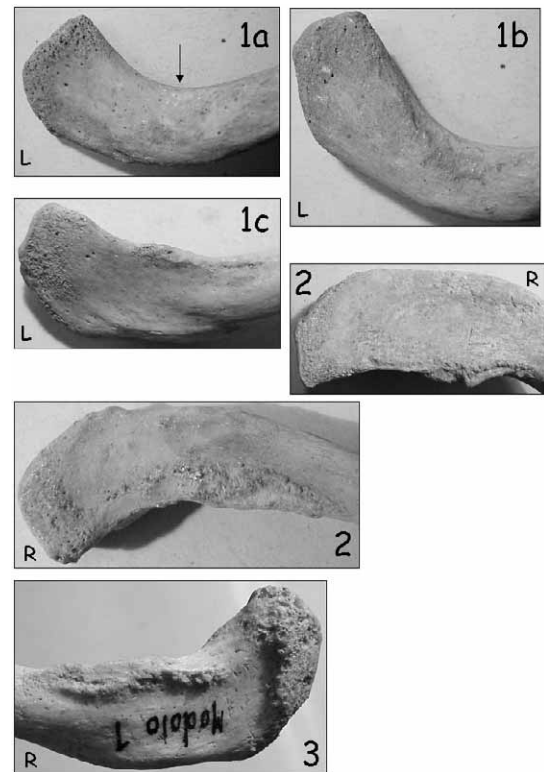


Fig. 7. Photographic standard for the developmental degrees of robusticity (1a, 1b, 1c, 2, 3) of the clavicular enthesis of *m. deltoideus*. R – right bone, L – left bone.

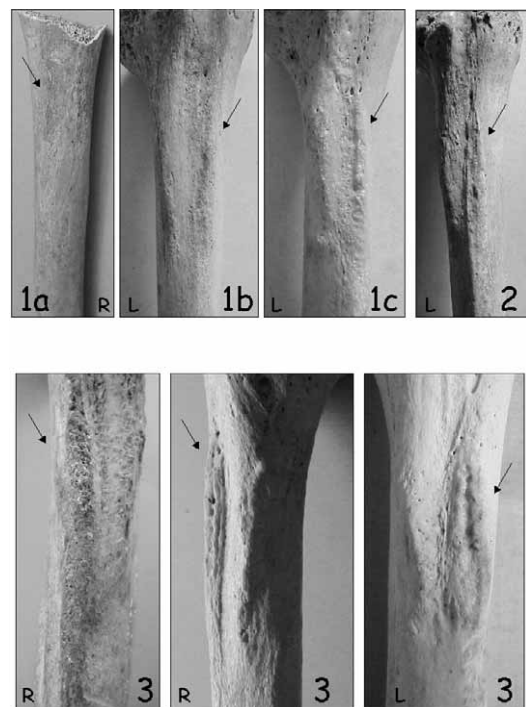


Fig. 8. Photographic standard for the developmental degrees of robusticity (1a, 1b, 1c, 2, 3) of the humeral enthesis of *m. pectoralis major*. R – right bone, L – left bone.

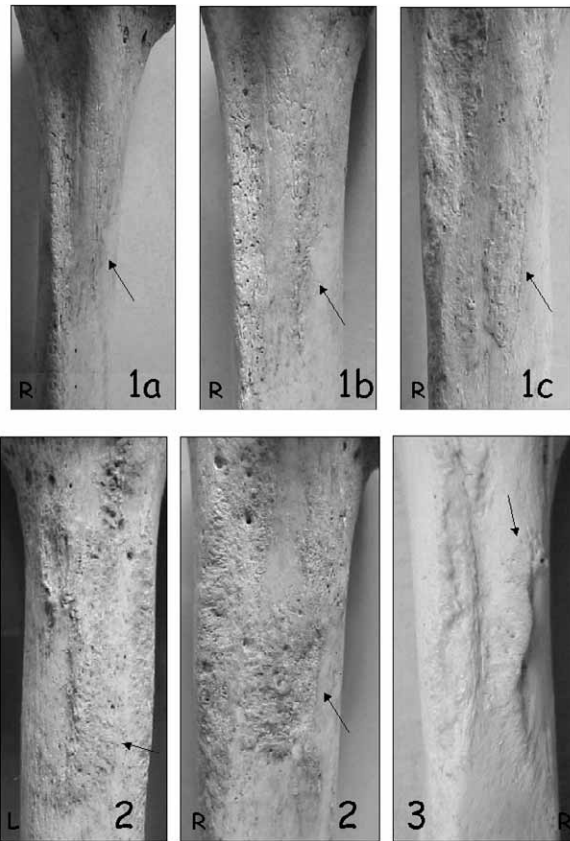


Fig. 9. Photographic standard for the developmental degrees of robusticity (1a, 1b, 1c, 2, 3) of the humeral enthesis of *m. latissimus dorsi/teres major*. R – right bone, L – left bone.




Fig. 10. Photographic standard for the developmental degrees of robusticity (1a, 1b, 1c, 2, 3) of the humeral enthesis of *m. deltoideus*. R – right bone, L – left bone.

low development: only slightly raised and its surface is slightly irregular; c – medium development: raised and with irregular surface.

2. high development: the crest is raised and its surface is rugose.
3. very high development: the crest is very raised and rugose, often in the form of a lanceolate, olive leaf-shaped area, with well-defined margins and often grooved by a longitudinal fossa.

M. latissimus dorsi/teres major (Figure 9)

1. the area of insertion on the crest of the lesser tubercle is: a – slight impression: barely perceptible to the touch; b – low development: marked by some rugosity; c – medium development: slightly raised and with an irregular surface.
2. high development: the area of insertion is raised and can present a longitudinal sulcus.
3. very high development: the area of insertion is raised and rugose and can form a true crest, sometimes with a longitudinal groove.

M. deltoideus (Figure 10)

1. a – slight impression: the anterior and lateral crests of the deltoid tuberosity are only barely appreciable and the surface is smooth; b – low development: the anterior and lateral crests are not very marked and the surface may be rugose; c – medium development:

the crests are well visible and the lateral one protrudes, slightly altering the profile of the bone; the surface may be rugose.

2. high development: the anterior and lateral crests are raised and rugose. The lateral crest protrudes, altering the profile of the bone.
3. very high development: the anterior and lateral crests are very raised and/or rugose, and the lateral crest is very protruding.

M. brachioradialis (Figure 11)

1. a – slight impression: the latero-inferior margin is smooth; b – low development: the latero-inferior margin presents, anteriorly, a barely appreciable crest; c – medium development: the margin can present a flattened and rugose inverted »v« anterior zone, or a little crest curved or »lipped« anteriorly.
2. high development: the latero-inferior margin presents a crest curved anteriorly.
3. very high development: the lateral part of the inferior quarter of the bone is »sail-like« and presents a very developed crest curved anteriorly.

Radius

M. biceps brachii (Figure 12)

1. a – slight impression: there is only a slight swelling at the bicipital tuberosity, with smooth surface; b – low de-

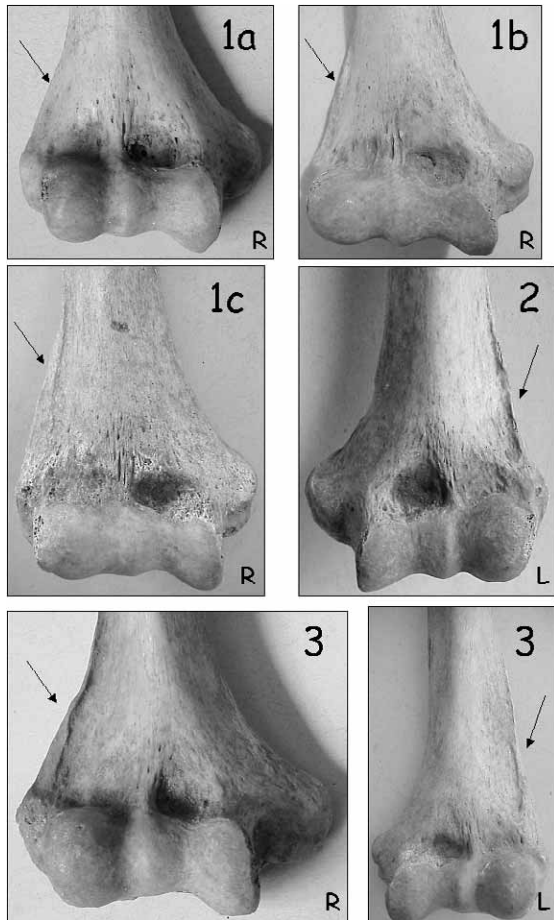


Fig. 11. Photographic standard for the developmental degrees of robusticity (1a, 1b, 1c, 2, 3) of the humeral enthesis of *m. brachioradialis*. R – right bone, L – left bone.

velopment: the bicipital tuberosity appears as an oval swelling with rounded margins; the muscle markings, in the form of surface irregularities, are weak and they are usually more evident on the medial margin; c – medium development: the lateral margin of the tuberosity is rounded, but the medial margin is more developed; the surface of the tuberosity is irregular and often grooved by a little longitudinal fossa or sulcus.

2. high development: the tuberosity, especially the medial margin, is very prominent. The surface can be more or less rugose and may be grooved by a longitudinal fossa or sulcus.
3. very high development: the tuberosity is very prominent and its margins, especially the medial, are very well developed and may form a raised border.

M. pronator teres (Figure 13)

1. a – slight impression: the area of insertion is practically smooth, or presents very slight surface irregularities; b – low development: the surface of the insertion area is irregular. c – medium development: the area presents obvious rugosity, but is not markedly raised with respect to the surface of the bone. In all cases (1a, 1b, 1c), there may be a slight longitudinal sulcus.

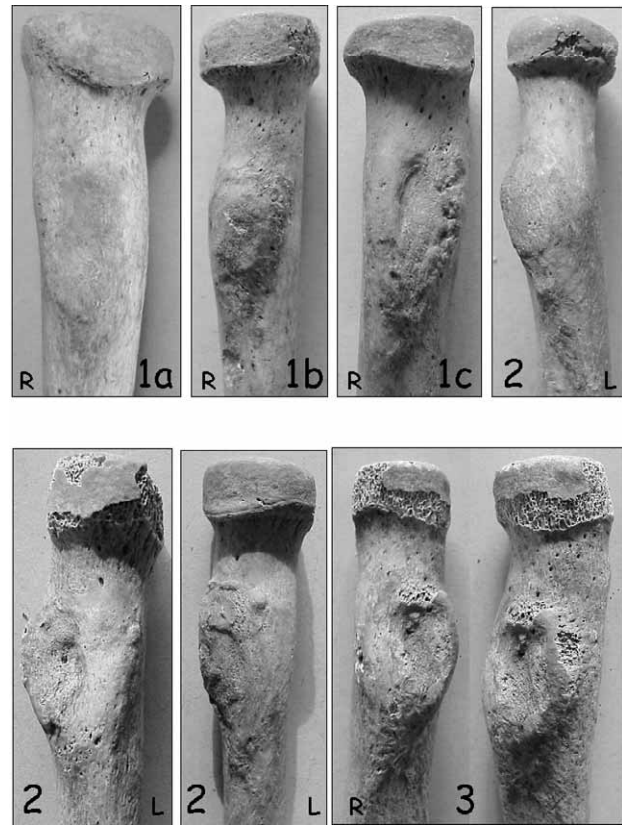


Fig. 12. Photographic standard for the developmental degrees of robusticity (1a, 1b, 1c, 2, 3) of the radial enthesis of *m. biceps brachii*. Photos in the same frame show the same bone from different points of view. R – right bone, L – left bone.

2. high development: the area presents »herring-bone« rugosity and is slightly raised or even flattened, but with well-defined borders.
3. very high development: the »herring-bone« rugosity is very well developed and forms a raised crest, possibly marked by a longitudinal sulcus.

Interosseous membrane (Figure 14)

The insertion of the interosseous membrane is scored superior to the mid-point of the shaft where one observes a prominence called the »interosseous tubercle«. Often visible are the areas corresponding to the insertions of Weitbrecht's ligament (»tail« or line of rugosity or raised areas that extend superior to the interosseous crest toward the bicipital tuberosity, sometimes even reaching it) and the oblique ligament (obvious rugosity, or even a longitudinal ridge, posterior to the interosseous crest). The standard refers only to the development of the interosseous tubercle.

1. a – slight impression: the interosseous tubercle cannot be distinguished as an autonomous formation; the surface is smooth or slightly irregular; b – low development: the interosseous tubercle is slightly raised and the surface is smooth or slightly irregular; c – medium development: the interosseous tubercle is easily distinguished and the surface is irregular.

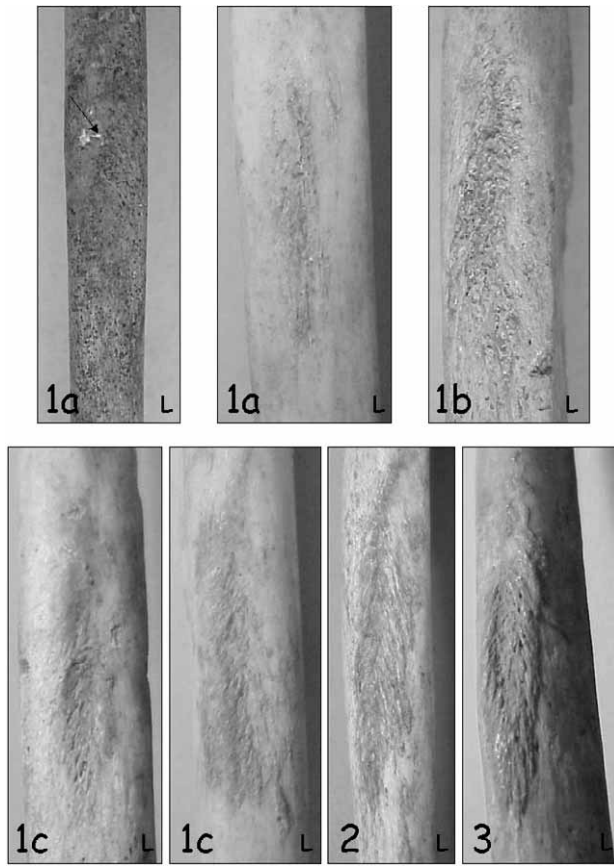


Fig. 13. Photographic standard for the developmental degrees of robusticity (1a, 1b, 1c, 2, 3) of the radial entheses of *m. pronator teres*. R – right bone, L – left bone.

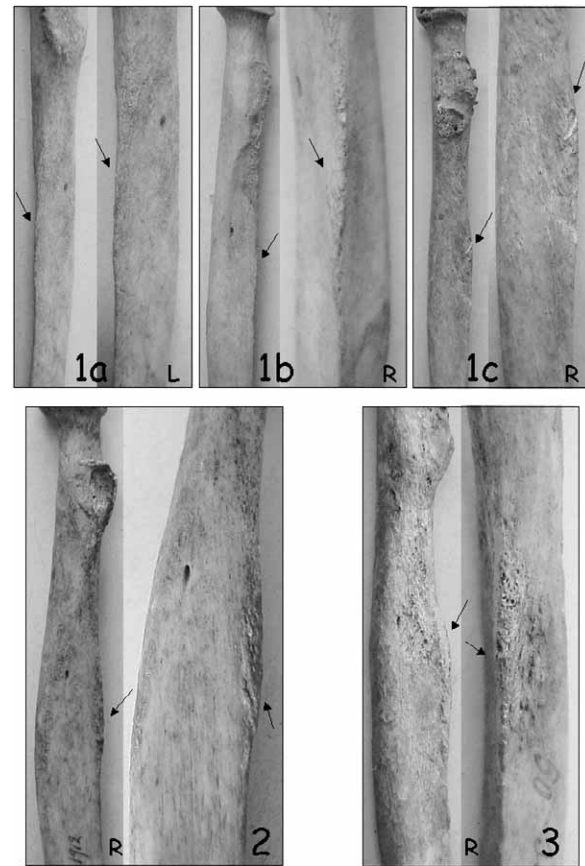


Fig. 14. Photographic standard for the developmental degrees of robusticity (1a, 1b, 1c, 2, 3) of the radial entheses of interosseous crest (superior part). Photos in the same frame show the same bone from different points of view. R – right bone, L – left bone.

2. high development: the interosseous tubercle is quite evident and presents obvious markings (rugosity).
3. very high development: the interosseous tubercle is very well developed; the margin can be swollen or, at times, flattened. Strong rugosity may be present.

Ulna

M. triceps brachii (Figure 15)

1. a – slight impression: the posterior surface of the olecranon is rounded and presents only a few markings, generally in the form of longitudinal striae. b – low development: in lateral view, the angle between the posterior and superior surfaces of the olecranon tends toward a right angle, and vertical striae are usually present on the crest. c – medium development: the posterior and superior surfaces of the olecranon form a right angle, with evident muscle markings, generally in the form of longitudinal striae.
2. high development: the posterior and superior surfaces of the olecranon meet to form a crest that is slightly raised with respect to the superior surface of the olecranon. Markings are visible on the crest, usually in the form of longitudinal striae or small ridges.
3. very high development: the crest is raised and its surface is rough, usually with small ridges or incipient digitations. Often, true enthesophytes are present.

M. supinator (Figure 16)

The insertion site can be in the form of a crest or of a tubercle, in both cases with a »tail« of rugosity or a little crest directed in the posterior-inferior direction.

1. a – slight impression: the lateral margin of the ulna, inferior to the radial notch, is only a little raised, but has a smooth surface; b – low development: one can identify a raised ridge inferior to the radial notch, whose proximal part can present a small tubercle; the surface is smooth; c – medium development: there is a rugose ridge that, inferiorly, can meet the interosseous crest or run posterior to it. The proximal part of the ridge can present a tubercle with obvious markings (rugosity).
2. high development: raised and rugose crest, often markedly prolonged inferiorly in the form of a »tail« that runs posterior to the interosseous crest, with obvious markings (rugosity). At times, the superior part of the insertion forms a tubercle with strong rugosity.
3. very high development: a: rugose crest with a marked tail of ridges inferiorly which can meet the interosseous crest or run parallel and posterior to it; b: very well developed tubercle, with strong muscle markings (rugosity) and possibly a »facet« on the apex; usually

a tail of muscle markings (small ridges, rugosity) extends downwards, posterior to the interosseous crest.

M. brachialis (Figure 17)

1. a – slight impression: the ulnar tuberosity is only barely appreciable and its surface is only slightly irregular; b – low development: the tuberosity is in the form of an oval area, often slightly depressed at the centre; c – medium development: idem, but a bit more raised and rugose.
2. high development: the tuberosity presents well-defined margins and is very rugose.
3. very high development: the tuberosity is very raised and rugose, possibly with very elevated margins.

Femur

M. gluteus maximus (Figure 18)

The 3rd trochanter may be present in the form of a round or oval tubercle, easily identifiable as an autonomous formation, whose surface can be smooth or rugose (see figure of degree 1a); the present standard does not take account of this trait, that can thus be present or absent in each degree of development of the *m. gluteus maximus*.

The enthesis of *m. gluteus maximus* can also be accompanied by a hypotrochanteric fossa, that can be more or less developed and whose surface can be more or less rugose, depending on the degree of development of the enthesis.

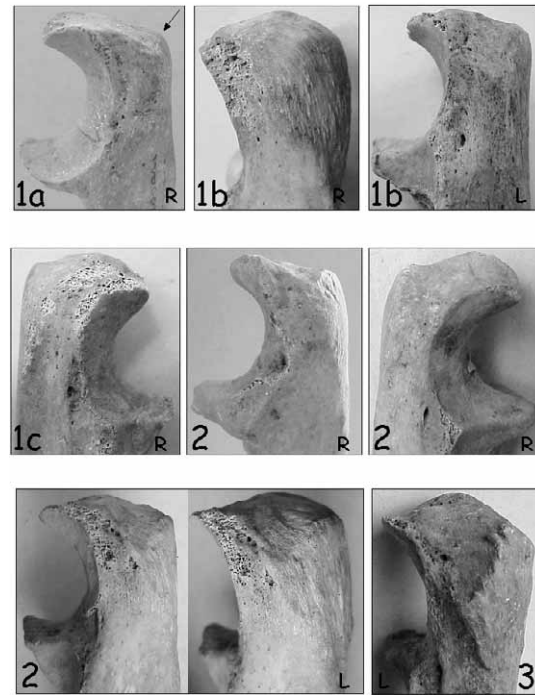


Fig. 15. Photographic standard for the developmental degrees of robusticity (1a, 1b, 1c, 2, 3) of the ulnar enthesis of *m. triceps brachii*. Photos in the same frame show the same bone from different points of view. R – right bone, L – left bone.

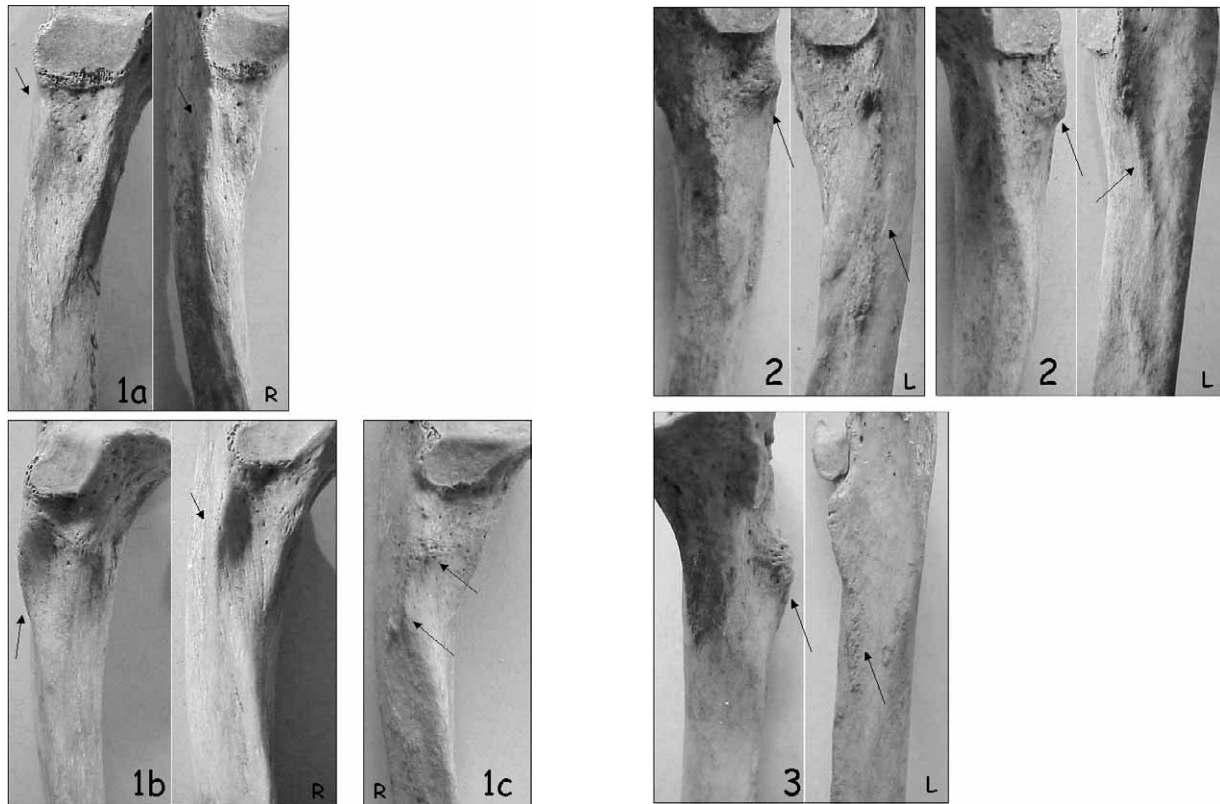


Fig. 16. Photographic standard for the developmental degrees of robusticity (1a, 1b, 1c, 2, 3) of the ulnar enthesis of *m. supinator*. Photos in the same frame show the same bone from different points of view. R – right bone, L – left bone.

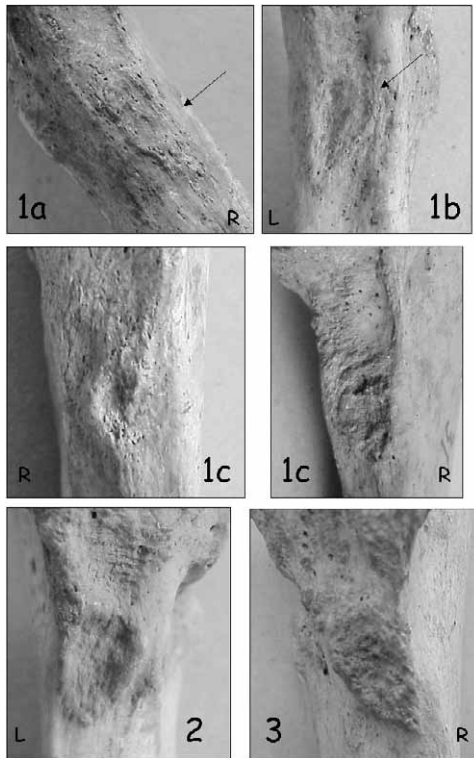


Fig. 17. Photographic standard for the developmental degrees of robusticity (1a, 1b, 1c, 2, 3) of the ulnar enthesis of *m. brachialis*. R – right bone, L – left bone.

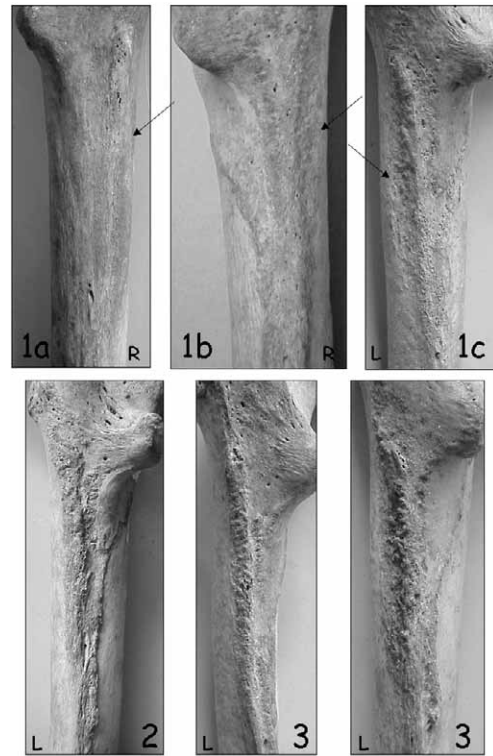


Fig. 18. Photographic standard for the developmental degrees of robusticity (1a, 1b, 1c, 2, 3) of the femoral enthesis of *m. gluteus maximus*. R – right bone, L – left bone.

1. a – slight impression: the insertion area is barely perceptible to the touch and presents a smooth surface; b – low development: the insertion area is easily distinguished and the surface is generally rather smooth; c – medium development: the gluteal ridge is evident and its surface is irregular or rugose.
2. high development: raised ridge with rough surface.
3. very high development: well-defined and very raised ridge; there may be a deep and rugose fossa, with its medial border forming a crest.

M. vastus medialis (superior part) (Figure 19)

1. a – slight impression: the surface is practically smooth, even though an oblique line is perceptible to the touch; b – low development: the insertion is marked by a rugose, oblique line; c – medium development: the line of insertion forms a continuous or discontinuous ridge, not very raised.
2. high development: the line of insertion forms a raised and/or rugose crest.
3. very high development: very raised and/or rugose crest.

M. iliopsoas (Figure 20)

1. a – slight impression: the lesser trochanter presents rounded margins and the surface is smooth; b – low development: the lesser trochanter presents rounded margins (the medial one more sharply angled) and the surface has weak markings, generally in the form of transverse striae; c – medium development: the medial margin of the lesser trochanter is sharply angled and the markings (striae or rugosity) are evident.

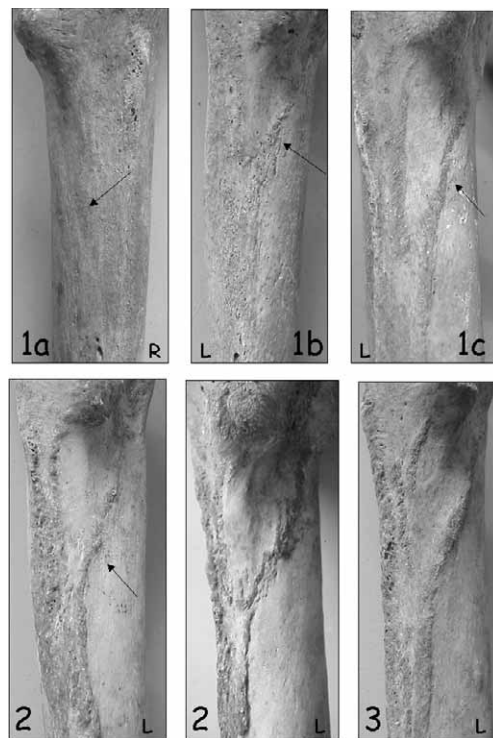


Fig. 19. Photographic standard for the developmental degrees of robusticity (1a, 1b, 1c, 2, 3) of the femoral enthesis of *m. vastus medialis* (superior part). R – right bone, L – left bone.

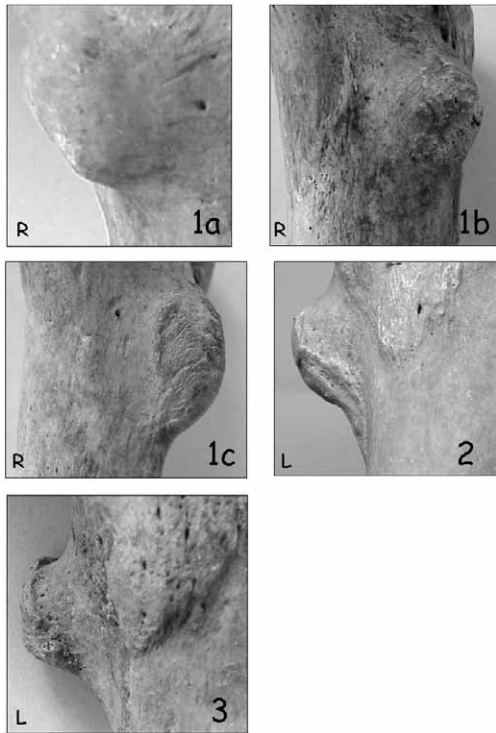


Fig. 20. Photographic standard for the developmental degrees of robusticity (1a, 1b, 1c, 2, 3) of the femoral enthesis of *m. iliopsoas* (the medial part of the lesser trochanter is shown). R - right bone, L - left bone.

2. high development: the apex of the lesser trochanter may be flattened and the surface presents transverse striations; the medial margin is sharply angled, and the muscle markings (rugosity) may extend downward on the side of the lesser trochanter.
3. very high development: the medial margin is »lipped« and the muscle markings (rugosity) can present an inferior extension on the side of the trochanter towards the femoral shaft. At times, the lesser trochanter may be flattened or have a very flattened and rugose superior facet.

Patella

Quadriceps tendon (Figure 21)

1. a - slight impression: the anterior superior part of the patella (in lateral view) is rounded and presents only a few markings, generally in the form of longitudinal striae. b - low development: the anterior superior part of the patella presents more evident ligament markings, in the form of rugosity or small ridges; c - medium development: the same as 1b, but the anterior superior margin of the patella is more sharply angled.
2. high development: the anterior superior margin of the patella is sharply angled and presents many markings in the form of rugosity or small ridges.
3. very high development: the antero-superior margin of the bone forms a crest whose surface is rough, usually with small ridges or incipient digitations. Often, true enthesophytes are present. Sometimes there are




Fig. 21. Photographic standard for the developmental degrees of robusticity (1a, 1b, 1c, 2, 3) of the patellar enthesis of quadriceps tendon. Photos in the same frame show the same bone from different points of view. R - right bone, L - left bone.

also enthesophytes directed downward on the inferior part of the bone, or, more rarely, the last occur alone.

In degrees 2 and 3, there may be a strong development of the entire anterior surface of the patella, as a kind of raised bony apposition.

Tibia

Quadriceps tendon (Figure 22)

1. a – slight impression: the tuberosity, consisting in a smooth superior part and an inferior part usually marked by longitudinal striae, does not interrupt the continuity of the shaft; b – low development: the superior part (smooth) of the tuberosity and the inferior part (with the longitudinal striae) are separated by a sulcus; c – medium development: the inferior part has a rough surface and there may be a lateral swelling.
2. high development: a true crest is present at the proximal end of the inferior part of the tuberosity.
3. very high development: the tuberosity presents a true crest, often running diagonally from the infero-lateral to supero-medial part of the bone, with incipient digitations. Often true enthesophytes are present.

M. soleus (Figure 23)

1. a – slight impression: the surface is practically smooth, even though an oblique line is perceptible to the touch. b – low development: the insertion is marked by a line of rugosity; c – medium development: the line of insertion is marked by obvious rugosity, or there is a slight crest with smooth surface.

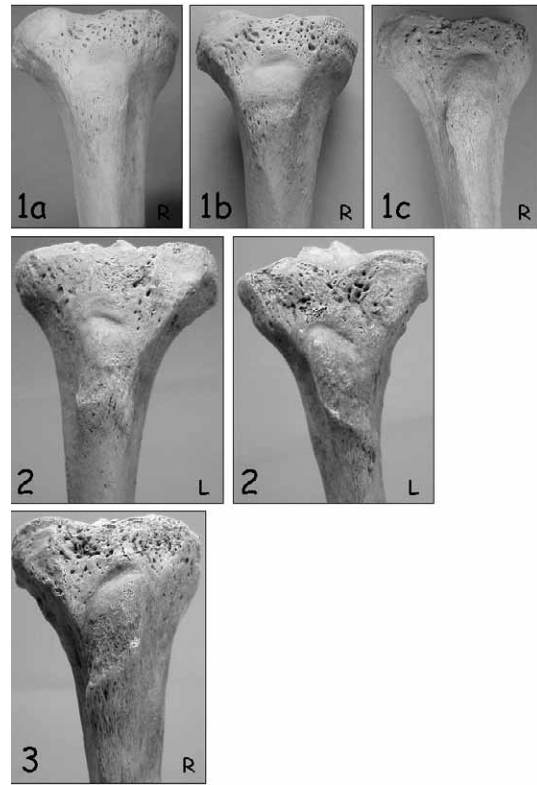


Fig. 22. Photographic standard for the developmental degrees of robusticity (1a, 1b, 1c, 2, 3) of the tibial enthesis of quadriceps tendon. R – right bone, L – left bone.




Fig. 23. Photographic standard for the developmental degrees of robusticity (1a, 1b, 1c, 2, 3) of the tibial enthesis of *m. soleus*. R – right bone, L – left bone.

2. high development: definite crest, possibly discontinuous, but with obvious rugosity.
3. very high development: very raised and rugose crest.
Sometimes, the enthesis of *m. soleus* is in the form of a »fossa« (Figure 23, degree 2), that can be more or less developed and whose surface can be more or less rugose, depending on the degree of development of the enthesis.

Calcaneus

Achilles tendon (Figure 24)

1. a – slight impression: the inferior half of the posterior surface of the calcaneus protrudes only slightly with respect to the superior half, and the resulting crest is rounded, with only a few markings, generally in the form of longitudinal striae. b – low development: idem, but the longitudinal striae are more evident; c – medium development: the crest is more developed and some vertical ridges are present.
2. high development: the crest (in lateral view) is very protruding and its surface presents vertical ridges.
3. very high development: very protruding crest, with ridges or incipient digitations. Often true enthesophytes are present.

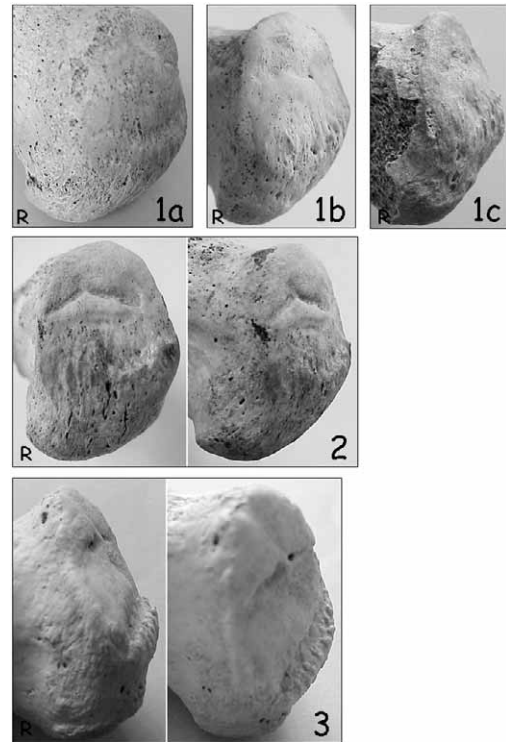


Fig. 24. Photographic standard for the developmental degrees of robusticity (1a, 1b, 1c, 2, 3) of the calcaneal enthesis of Achilles tendon. Photos in the same frame show the same bone from different points of view. R – right bone, L – left bone.

APPENDIX 2
STANDARDISED DATA COLLECTION FORM FOR ENTESIS ROBUSTICITY AND ENTHESOPATHIES

Specimen																		
Sex / age	M / F / NI			YA/MA/OA/NI			M / F / NI			YA/MA/OA/NI			M / F / NI			YA/MA/OA/NI		
	Left			Right			Left			Right			Left			Right		
	Rob	EF	OL	Rob	EF	OL	Rob	EF	OL	Rob	EF	OL	Rob	EF	OL	Rob	EF	OL
SCAPULA																		
M. triceps brachii																		
CLAVICLE																		
Costoclavicular lig.																		
Conoid lig.																		
Trapezoid lig.																		
M. pectoralis major																		
M. deltoideus																		
HUMERUS																		
M. pectoralis major																		
M. lat.dorsii/teres major																		
M. deltoideus																		
M. brachioradialis																		
RADIUS																		
M. biceps brachii																		
M. pronator teres																		
Interosseous membrane																		
ULNA																		
M. triceps brachii																		
M. brachialis																		
M. supinator																		
FEMUR																		
M. gluteus maximus																		
M. iliopsoas																		
M. vastus medialis																		
PATELLA																		
Quadriceps tendon																		
TIBIA																		
Quadriceps tendon																		
M. soleus																		
CALCANEUS																		
Achilles tendon																		