

# Paleobiology, Palaeopathology and Necrophobic Practices in Early Iron Age Burials (IX–VII Century BC) in Capo Colonna, Trani, Apulia, Southern Italy – The State of Health of a Small Sample from Iron Age

Sandro Sublimi Saponetti<sup>1</sup>, Fabio Scattarella<sup>2</sup>, Amelia De Lucia<sup>3</sup> and Vito Scattarella<sup>1</sup>

<sup>1</sup> Department of Zoology, Anthropology Unit, University of Bari, Italy

<sup>2</sup> Department of Clinic of Orthopedic Surgery, University of Bari, Italy

<sup>3</sup> Department of Statistics, University of Bari, Italy

## ABSTRACT

*In this palaeobiological and palaeopathological study of skeletal remains, we attempt to define the physical characteristics, living conditions and the state of health of a small sample from two early Iron Age (IX–VIII century BC) graves at Capo Colonna, Trani (Bari, Apulia, southern Italy). In the thoraco-lumbar segment (T11–L1) of the vertebral column of an adult male 35 years old, we found wedge-shaped deformation of the anterior part of T12 with kyphosis of the affected tract. Digital radiography and volumetric reconstruction by 3D CT indicated that the alteration did not result from an infectious process (Pott's disease). Instead, it was a traumatic lesion probably caused by falling from a height. The archaeological investigation revealed extraordinary arrangements of the bodies in the graves: they were buried with a boulder placed on the coffin. This practice has been seen in similar graves in the Balkan area, particularly in Greece, from the Neolithic to the Early Middle Ages. The most likely explanation is a funeral ritual characterized by necrophobia, the purpose of which was to prevent the deceased from returning to terrorize the living.*

**Key words:** palaeobiology, palaeopathology, necrophobia, vampirism

## Historical and Archaeological Context

In archaeo-anthropological research, we occasionally encounter disturbing elements in our investigations, like those we infer from unusual, probably necrophobic, actions toward deceased individuals buried in two graves discovered in 2001 in Capo Colonna, Trani (Bari, Apulia, southern Italy).

Archaeological excavations in the Capo Colonna peninsula in 1960 revealed a human-occupied level rich in pottery fragments dating back to the Bronze Age. A more systematic investigation in the same area by the Archaeological Supervising office of Apulia in 1972 documented a stratigraphic succession spanning six centuries, from the early to late Bronze Age, with traces of Mycenaean frequentation of the site<sup>1</sup>.

In 2001, the Archaeological Supervising office resumed excavations in a neighboring zone, where structures of a building with a paved courtyard appeared. The building exhibited a peculiar construction technique, in which the external walls were made with stone slabs stuck vertically into the ground; in addition, a circular pit, containing stones, was dug next to the wall (Figure 1). The pottery fragments found in the ground were from Daunian geometric pots, which date the site to between the IX and VIII century BC. The archaeologists believe that it was a religious site with two graves, one inside the building and the other in the courtyard<sup>2</sup>.

## Taphonomy and Myth

Grave no. 1 (Figure 2), inside the building, was oriented in an east/west direction and contained three individuals with their heads facing eastward. The three bodies were supine and partially overlapping, suggesting that they were buried at the same time.



Fig. 1. Building with paved internal courtyard. Grave no. 2 can be seen in the upper right, grave no. 1 in the upper left.



Fig. 2. Grave no. 1 with the three burials in situ.

All three individuals were buried with a boulder placed on the coffin. The boulder in burial I covered the individual's abdominal area. In burial II this covered the thorax, abdomen and forearms, while the smaller boulder in burial III covered the left hemithorax and shoulder.

Grave no. 2, situated outside the building and oriented in an east-west direction, contained a single individual buried with the head facing eastward, in a prone position and huddled up, with the forearms flexed under the abdomen and the heels touching the hip bones. This suggests a burial in a confined space, with the body sealed in by a slab placed on the back (Figure 3).

All the individuals present peri-mortem loss of an upper medial incisor, the right in grave no. 1 and the left in



Fig. 3. Grave no. 2 with the single burial in situ. The body is sealed in the grave by a large stone slab placed on the back.

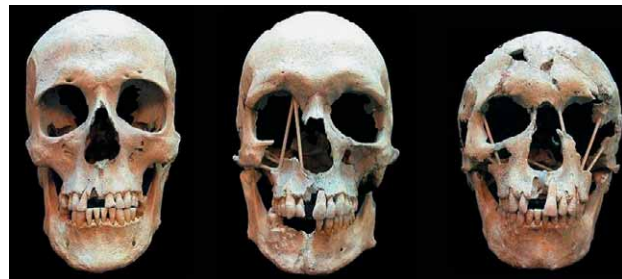


Fig. 4. Peri-mortem loss of the right upper medial incisor in the burials of grave no. 1. From left to right, the skulls of burials I, II and III.

grave no. 2. The openness of the alveolus indicates that these were lost immediately pre- or post-mortem. However, we cannot say with certainty if they were deliberate extractions, even though there was no trace of the teeth in the excavated soil (Figure 4).

The ritual extraction of teeth is mentioned in the myth of the Argonauts: to conquer the Golden Fleece, Jason killed the dragon and, during the ploughing of a field sacred to Ares, sowed its teeth, from which sprang armed warriors<sup>3</sup>.

The sowing of human teeth is documented in the megalithic area of Saint Martin de Corleans (Aosta). Around 2900 BC, a human group forming part of the Bell-shaped Vase community constructed a necropolis marked by numerous poles that acted as totems. An ancient rite was practiced next to the poles, i.e. a consecrating ploughing of the area and the sowing of human teeth, while anthropomorphic decorated stelae and menhirs were subsequently erected at a place characterized by wells. The trapezoidal stelae, representing gods or ancient heroes, resemble those of the Petit Chasseur site at Sion<sup>4</sup>.

Similarly, the elements cited for the Calcolithic site of Saint Martin all fall within the Daunian cultural context and are also found at the Capo Colonna site, i.e. a temple, wells and dental extractions as a prelude to the sowing of teeth.



Fig. 5. Khirokitia, Cyprus, Eneolithic burial (III millennium BC)

Such funeral practices are associated with burials involving extraordinary arrangements of the bodies, as documented in the Balkan and Aegean areas and at Cyprus in particular, from the Neolithic to the Early Middle Ages<sup>5</sup> (Figure 5). This practice is conditioned by necrophobia (Necros + Phobos), i.e. fear that the deceased will return to terrorize the living.

Vampirism is a form of necrophobia that appears in European popular beliefs, especially in the Balkans, since the Neolithic age<sup>6</sup>. Possible explanations for the belief in vampires (reanimated, non-dead bodies that rise from the grave, wander at night and suck the blood of the living to satisfy their hunger and perpetuate their existence) could come from Clinical and Forensic Pathology. The following pathologies may be related to this myth:

- TUBERCULOSIS, because of the persistent cough, with bloody sputum;
- PORPHYRIA, in which sunlight makes the porphyrin deposited in the skin toxic;
- RABIES and PHOTOFOBIA, because of the fits of violence, aggression and insomnia;
- PHOTOSENSITIVITY, because of the cutaneous rash and intolerance of the sun;
- MENTAL DISORDERS, sometimes leading to cannibalism or necrophilia.

Some methods used to prevent transformation of the deceased into a vampire are mutilation of the corpse, the driving of stakes, decapitation, placing boulders or chains on the body<sup>6</sup>.

### Palaeobiological Data

The bones of burial I in grave no. 1 belong to a male with a biological age of around 35 years<sup>7,8</sup>. The remains present several dental and skeletal markers of stress. Semilunar extra-masticatory wear on the anterior maxillary teeth is related to use of the teeth in handicraft activities, such as making baskets or ropes with plant fibres<sup>9,10</sup>. The posterior margin of the glenoid cavity of the right scapula presents a posterior extension of the ar-

ticular surface. Combined with the cortical alteration of the greater tuberosity of the ipsilateral humerus (osteorefaction), it indicates functional impingement syndrome, related to repeated strenuous activities with the arm raised<sup>11</sup>. The entheses of the adductor and rotatory muscles of the humerus are rather strong, and there are marked Poirier facets on the left femoral neck<sup>12</sup>.

The bones of burial II in the same grave belong to a male with an age at death of around 35 years<sup>7,8</sup>. There is enamel hypoplasia on the anterior teeth<sup>13</sup> and ante-mortem loss of the two central incisors of the mandible. Again there is semilunar extra-masticatory wear on the occlusal surface of the anterior maxillary teeth. Markers of stress indicating impingement syndrome are also present in this subject, but this time on the left scapula and humerus; in addition, there is a strong osteophytic lamina on the dens of the axis, which can be attributed to the habitual transport of loads using a band passing over the forehead<sup>14</sup>. The inflammation of the medial surface of the left metatarsal I is related to irritation caused by tight shoes, while the extension of the distal articular area onto the superior surface indicates »executive foot« syndrome<sup>12</sup>. This is associated with alterations of the articular surfaces of the proximal epiphyses of the proximal phalanges of the halluces. The malar tubercle on the right zygomatic process and the third trochanteric eminence on the femora are morphological characters shared with the individual of burial III.

The bones of burial III in grave no. 1 are of a 15–17-year-old female<sup>7,8</sup>. This subject presents persistence of the right deciduous second molar of the mandible and early eruption of the mandibular left third molar. Indicators of occupational stress include a hypertrophic left superior mental spine (4 mm long) and hypertrophy of the humeral insertions of pectoralis major.

The single burial in grave no. 2 is of a young adult male around 20–25 years old. The individual had a robust skeleton, height of over 180 cm<sup>15</sup> and body mass of around 80 kg<sup>16</sup>. As in the other adult individuals examined, the stress indicators include extension of the dorsal border of the right scapular glenoid cavity. In addition,

there is a notch and fossa of vastus lateralis on the patellae. The distal epiphyses of the tibiae exhibit accessory lateral facets. Pathological features include localized areas of inflammation on the pleural surfaces of some ribs and on the left nasal bone; the orbital roofs present cribrotic *cribra orbitalia*<sup>17</sup>.

### Traumas

On the skeletal remains of burial II in grave no. 1, we observed alterations of the thoraco-lumbar segment (T11 to L1) of the vertebral column that suggested a serious inflammatory infectious process (Pott's disease). In T11, the cortex of the anterior body wall is well preserved and the impressions of the *annulus fibrosus* of the intervertebral disc are recognizable on the inferior surface of the body. T12 presents an anteriorly wedge-shaped body, the superior and inferior surfaces of the body with the impressions of the *annulus fibrosus*, the left twelfth rib, the costo-transverse joint, the left pedicle, the left superior and inferior articular processes and part of the lamina. In the first lumbar vertebra (L1), the cortex of the anterior body wall is well preserved and the impressions of the *annulus fibrosus* are recognizable on the inferior surface of the body. The residual spongy bone appears regular (Figure 6).

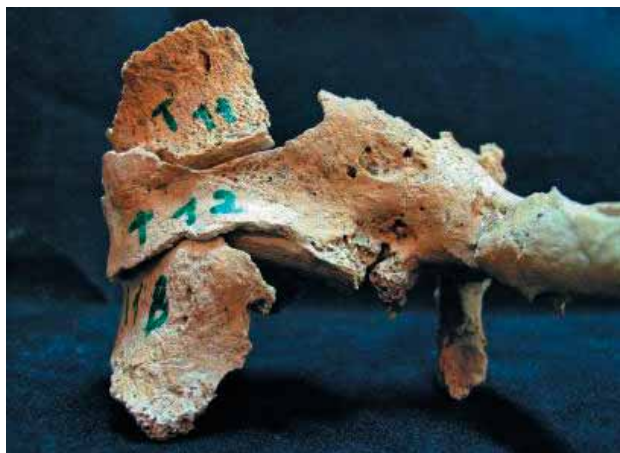

Fig. 6. Thoraco-lumbar segment (T11-L1) of the vertebral column of burial II in grave no. 1 in left antero-lateral view.

To verify the reliability of our diagnosis (Pott's disease), we conducted a digital radiological analysis of the T11-L1 sample. In this pathology, the most affected vertebra is T11: there is progressive destruction of its trabecular component leading to collapse of the vertebral body and subsequent kyphosis of the vertebral segment. The radiological characteristics of this infectious process are: absence of the intervertebral space; voluminous paraspinal abscesses with strong margins; calcifications inside the abscessual fluid; osteolysis and destruction of the margin of the body.

The digital radiographic examination of the vertebrae revealed wedge-shaped deformation of the anterior part of the body of T12. The compact bone of the vertebral body surfaces is well preserved and there is no evident osteolysis of the spongy bone (Figure 7). This tends to exclude the infectious-inflammatory nature (typical of Pott's disease) of the collapse of the vertebral body. Instead, we can hypothesize a traumatic lesion occurring in this adult individual (around 35 years old); this is shown by the absence of osteoporotic trabecular rarefaction of the spongy bone. This hypothesis is supported by the relatively good preservation of the spongy bone of the vertebral body despite the evident anterior collapse of T12. The latter radiological datum best fits a post-traumatic deformity of the vertebra. In experimental models, it has been calculated that the vertebral bodies of adults resist compressive forces of around 400 Kg. Therefore, it is plausible that the lesion was caused by a fall from a certain height (high-energy trauma).

CT (both in axial sections and three-dimensional reconstructions) was less efficacious than digital radiography (Figure 8) because of the fragmentary nature of the sample (especially of T11). Nevertheless, it tended to confirm the traumatic aetiology of the collapsed body of T12 and to refute the idea of an infectious-inflammatory origin.

### Conclusions

The data reported here are an attempt to define the physical characteristics, living conditions and the state of health of a small sample from early Iron Age graves (IX–VIII century BC). Unfortunately, the poor state of preservation of the skeletal remains from grave no. 1

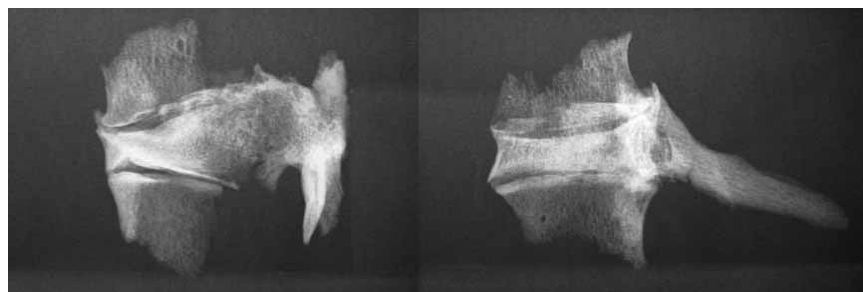

Fig. 7. Burial II in grave no. 1. Digital radiography of the three assembled fragments (T11-L1). Note the wedge-shaped deformation of the body of T12 and the absence of osteolysis of the spongy bone.

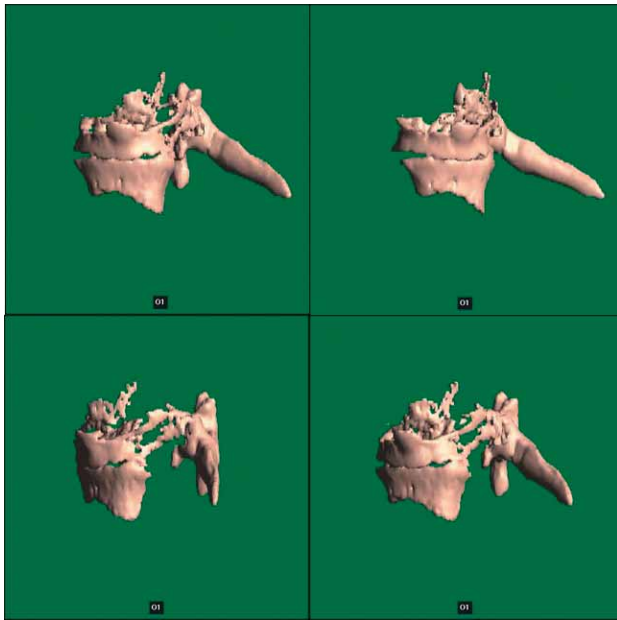


Fig. 8. Burial II in grave no. 1. Volumetric reconstruction by 3D CT. Upper left and right, frontal view; lower left, lateral view; lower right, lateral oblique view.

(three individuals) and the lack of data on the skeletal biology of Iron Age Apulian populations prevented an in-depth study.

The two graves at Capo Colonna, Trani (Bari, Italy) contained 4 individuals. The three individuals of grave no. 1 (two adult males around 35 years old and a female 15–17 years old) were all placed in a supine position and were partially overlapped.

Grave no. 2 contained a single individual (adult male 20–25 years old) placed in a prone position and strongly huddled up, with forearms flexed under the abdomen and the heels contacting the hip bones. This subject had a robust physique, height of 180 cm and body mass of around 80 kg.

All four individuals present peri-mortem loss of an upper medial incisor, the right in grave no. 1 and the left in grave no. 2. Skeletal and dental markers of stress include: semilunar extra-masticatory wear on the maxillary incisors; extension of the articular surface of the glenoid cavity of the right scapula; enthesopathies of the

adductor and rotatory muscles of the humerus; Poirier facets on the femur; enamel hypoplasia on the anterior teeth; a large osteophytic lamina on the dens of the axis; notch and fossa of vastus lateralis on the patellae; tibiae with accessory lateral facets; orbital roofs with *cribra*. Regarding traumas, the most interesting feature concerns the thoraco-lumbar segment (T11 to L1) of the vertebral column of burial II in grave no. 1, which shows wedging of vertebra T12, probably caused by a fall from a certain height.

In addition to the palaeobiological and palaeopathological data, the peculiar feature of these two early Iron Age graves is that all four individuals were buried with a boulder placed on the coffin. Particularly significant is the type of burial in grave no. 2: the deceased was sealed in the grave by a large stone slab set on his back.

What is the relationship among dental extractions, the sowing of teeth in fields, the belief in vampires and necrophobic practices? A connection, albeit a weak and uncertain one, appears from the abysses of European protohistory, in the form of a unitary symbolic system which then dispersed in the thousand rivulets of time and of human lineages. Myths may be of help in this regard, for instance the story of the Argonauts or the Odyssey in which all these elements forcefully appear. The sowing of teeth in a sacred field, containing anthropomorphic stelae and wells, is documented archaeologically as a magic-religious practice in the Eneolithic communities of Valle d'Aosta. In this regard, the practice of dental extraction seems to be a prelude to the sacred sowing.

A common denominator of all these rituals, apparently unrelated but probably closely linked, is necrophobia, manifested by recourse to all the remedies used to prevent the return after death of sacrificial victims.

Indeed, these remedies emerge from our analysis of the archaic graves of Capo Colonna, Trani.

## Acknowledgements

The authors thank Dr. Ada Riccardi of the Archaeological Supervising office of Apulia for entrusting us with the study of the material and Dr. Maurizio Resta, head of the Radiology Unit of »S.S Annunziata« Hospital, Taranto, for interpretation of the digital radiography and volumetric reconstruction by 3D CT.

## REFERENCES

1. DE JULIIS E, Gli Iapigi. Storia e civiltà della Puglia preromana. (Longanesi, Milano 1988).
2. RICCARDI A, Trani (Bari), Capo Colonna, Taras Rivista di Archeologia, 12 (2002) 34.
3. IACOVELLI G, Miti e culti di interesse sanitario nella Daunia antica. In: Atti XII Conv. Naz. sulla Preistoria, Protostoria, Storia della Daunia, (1990) 131.
4. COCCHI GENICK D, Manuale di Preistoria III. L'età del Rame. (Firenze, 1996).
5. TSALIKI A, Vampires beyond legend: a bioarchaeological approach (Proceedings of XIIIth European Meeting of the Paleopathology Association, Chieti, 2000) 295.
6. CANDELIERI L, Il carnevale a Trani nel XVIII secolo (Lares Leo S. Olschki, Firenze, 1999).
7. FEREMBACH D, SCHWIDETZY I, SLOUKAL M, Riv. Antrop. 60 (1979) 5.
8. LOVEJOY CO, Am Jour Phys Anthrop, 68 (1985) 47.
9. LARSEN CS, Am Jour Phys Anthrop, 67 (1985) 393.
10. MOLLESON T, Antiquity, 63 (1989) 356.
11. CAPASSO L, I fuggiaschi di Ercolano. (L'Erma di Bretschneider, Roma, 2001).
12. KENNEDY KAR, Reconstruction of life from the skeleton. (Alan Liss, New York, 1989).
13. GOODMAN AH, ARMELAGOS GS, ROSE JC, Human Biology, 52 (1980) 515.
14. CAPASSO L, KENNEDY KAR, WILCZAC A, Atlas of occupational markers of human remains. (Edigrafital s.p.a, Teramo, 1999).
15. TROTTER M, GLESER GC, Am Jour Phys Anthrop, 47 (1997) 355.
16. RUFF CR, TRINKAUS E, HOLLIDAY TW, Nature 387 (1997) 8.
17. HENGEL OP, Homo, 22 (1971) 57.

*S. Sublimi Saponetti*

*Department of Zoology, Anthropology Unit, University of Bari, via Orabona 4, 70125, Italy  
e-mail: s.sublimi@biologia.uniba.it*

**PALEOBIOLOGIJA, PALEOPATOLOGIJA I NEKROFOBNI POGREBNI OBIČAJI U  
RANOM ŽELJEZNOJ DOBI (IX-VII STOLJEĆE PRIJE KRISTA) U CAPO COLONNI,  
TRANI, APULIA, JUŽNA ITALIJA – ZDRAVSTVENO STANJE NA MALOM UZORKU  
POPULACIJE IZ ŽELJEZNOG DOBA**

**S A Ž E T A K**

U ovoj paleobiološkoj i paleoantropološkoj studiji na skeletnim ostacima, pokušali smo utvrditi fizičke karakteristike, životne uvjete i zdravstveno stanje na malom uzorku populacije iz Capo Colonne sa početka željeznog doba. U torakalno-lumbarnom dijelu kralježnice 35-godišnjaka pronađeno je klinasto oblikovana deformacija anteriornog dijela T12. Digitalnom radiografijom i volumetrijskom rekonstrukcijom na 3D CT-u, ustanovljeno je da deformacija nije bila uzrokovana infekcijom, već da je to bila traumatska posljedica pada sa neke visine. Arheološka iskopavanja potvrdila su odličnu očuvanost tijela u grobovima. Takav način ukopa bio je sličan na Balkanu, posebice u Grčkoj u Neolitiku i ranijem srednjem vijeku. Najprikladnije objašnjenje nekrofnog pogrebnog običaja, je ono koje kazuje da se na taj način pokušalo zaštititi žive od teroriziranja pokojnika.