

Erdheim-Chester Disease and Concomitant Tuberculosis Successfully Treated with Chemotherapy and Long-Term Steroids

Saša Badžek^{1,2}, Ana Mišir-Krpan^{1,2}, Zdenko Krajina^{1,2}, Ivo Radman³, Ranka Štern-Padovan⁴ and Snježana Dotlić⁵

¹ Department of Oncology, University Hospital Center »Zagreb«, Zagreb, Croatia

² School of Medicine, University »J. J. Strossmayer«, Osijek, Croatia

³ Department of Hematology, University Hospital Center »Zagreb«, Zagreb, Croatia

⁴ Department of Radiology, University Hospital Center »Zagreb«, University of Zagreb School of Medicine, Zagreb, Croatia

⁵ Department of Pathology, University Hospital Center »Zagreb«, Zagreb, Croatia

ABSTRACT

Erdheim-Chester disease (ECD) is a rare histiocytosis usually affecting the skeletal system, but visceral organs and central nervous system involvement are common as well. Probability exists that immunomodulatory therapies and disorders can play a role in clinical course of the disease. Because of rarity of the disorder, it is hard to classify it and standardize the treatment options, but, according to published material and our experience, cytotoxic chemotherapy and long-term steroids have therapeutic benefit. Although this approach can probably be accepted as standard of care management, novel therapeutic modalities should be explored, and pathogenesis and disorder classification should be cleared out as well. The case of ECD affecting skeletal system and lungs and concomitant laryngeal tuberculosis successfully treated with chemotherapy and long-term steroid therapy is presented.

Key words: Erdheim-Chester disease, steroids, therapy, tuberculosis.

Case Report

A 62-year-old white male presented in April 2004 with progressive pain in both femoral regions and right inguinum that started two weeks before admission to the hospital. Initial radiological imaging and bone scintigraphy revealed pathologic fracture of neck of right femoral bone and diaphyseal infiltrations in both femoral bones and right humerus (Figure 1). Biopsy samples have been taken from right femur, and revealed Erdheim-Chester disease (ECD), a rare form of histiocytosis. Past medical history revealed non-insulin dependent diabetes mellitus successfully treated with repaglinide since 2000, when episode of acute pancreatitis occurred. Physical examination revealed mild exophthalmus and palpatory pain in right inguinum. Computed tomography scan of the chest, abdomen and brain revealed infiltration of left lung parenchyma, and no other abnormalities were found (Figure 2). Laboratory tests revealed high serum calcium and elevated blood glucose level; no other abnormalities

were present, including hormone analysis. Pathology of the lesion demonstrated CD1a negative, S-100 partially positive and vimentin and CD68 positive histiocytes, all suggestive for ECD diagnosis (Figure 3).

After implantation of partial right hip endoprosthesis, external-beam radiotherapy of right femoral region was performed, and consequently 7 cycles of cyclophosphamide (Endoxan) chemotherapy with concomitant PO methylprednisolone (Solu-Medrol) and IV pamidronate (Aredia) have been administered. Initial follow-up after 6 months of chemotherapy revealed remission of the disease in the lungs and humerus, and only right femoral bone infiltration was present. Long-term corticosteroid use was complicated by worsening of diabetes mellitus and consequent lipid metabolic disorder development, which are currently controlled by insulin, methylprednisolone dose reduction and atorvastatin (Sortis). In August 2005, pa-

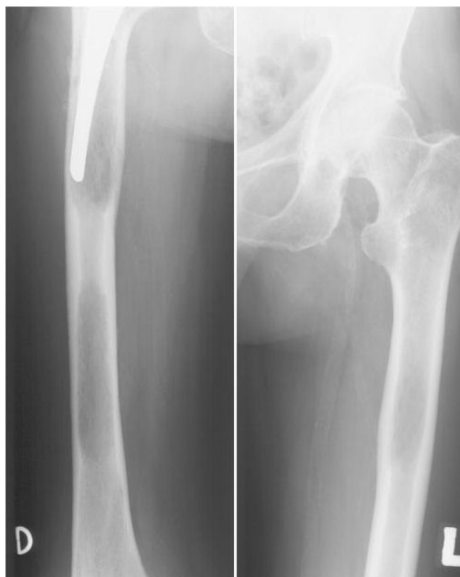

Fig. 1. Initial radiological imaging and bone scintigraphy revealed pathologic fracture of neck of right femoral bone and diaphyseal infiltrations in both femoral bones and right humerus.

tient presented with sore throat and pain in right side of the neck. Physical examination and radiological imaging revealed exophytic tumor of the epiglottis. Laryngomicroscopy and biopsy have been performed and revealed tuberculosis infiltration of the epiglottis and constrictor pharyngis muscle, and one month later pulmonary tuberculosis developed, which has been successfully eradicated till February 2006, by rifampicin (Rimactan), etambutol (Etambutol), pirazynamide (Pyrazinamid) and isoniazide (Eutizon) course. Currently, the patient is well, participating normally in daily activities, and with only detectable infiltration in the right femoral bone.

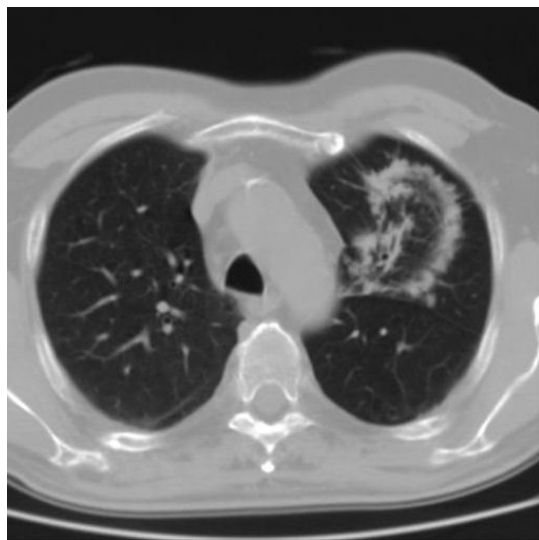


Fig. 2. Computed tomography scan of the chest, abdomen and brain revealed infiltration of left lung parenchyma.

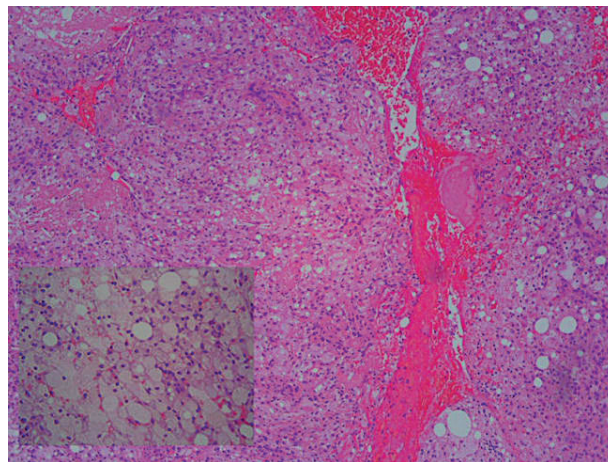


Fig. 3. Pathology of the lesion demonstrated CD1a negative, S-100 partially positive and vimentin and CD68 positive histiocytes, all suggestive for ECD diagnosis.

Discussion

ECD is a rare form of histiocytosis, first time described as distinctive form of lipoid granulomatosis by William Chester and Jacob Erdheim in 1930¹. Jaffe reported a similar case in 1972, and named it Erdheim-Chester disease. Less than 100 cases have been described in literature so far. ECD usually strikes the skeletal system, but involvement of visceral organs, lungs and central nervous system is also well recognized. Depending of extraskeletal involvement, it can vary from focal indolent process to life-threatening condition. It affects both sexes equally, in age range 21–77, with average of 54 years. Bone lesions are usually sclerotic or mixed and distributed symmetrically through the skeleton, commonly in diaphyses and metaphyses of long bones, but can be found in other parts of skeleton as well^{1,2}. Central nervous system infiltration usually can be found in posterior lobe of pituitary gland, with consequent hypothalamic-pituitary dysfunction, i.e. central diabetes insipidus, hyperprolactinemia, gonadotropin insufficiency and decreased insulin-like growth factor I levels. Pericardial infiltration can lead to heart failure, and retroperitoneal infiltration can result in renal insufficiency with or without urethral obstruction. Eyelid xanthomas and exophthalmus due to retrobulbar involvement are also common^{1,2}. In patients with advanced lesions pulmonary involvement is accompanied with pulmonary fibrosis, which can lead to cardiorespiratory failure^{3–5}.

ECD has been recognized as a separate entity from other Langerhans cell histiocytosis since its different clinical presentation. Although it is histologically similar to a subgroup of Langerhans cell histiocytosis, e.g. Hand-Schuller-Christian disease, modern immunohistochemistry techniques have revealed important differences between these two entities⁶. Several cases have been described of patients with both diseases, as well as a case of ECD with eosinophilic granuloma^{7–9}. Although connection be-

tween these diseases probably exists, the pathogenesis of ECD remains unknown. Ongoing debate persists whether it is reactive or malignant in origin, since conflicting reports about its clonality have been published in recent literature^{10,11}. Having in mind common multisystem involvement and poor prognosis of the disease, as well as good efficacy of anti-cancer treatment modalities, this rare disorder is probably neoplastic in origin, but additional clonality analyses are yet to clarify this issue. There is no standard of care treatment for ECD. At-

tempts have been made with radiotherapy (including half-body irradiation), chemotherapy (vincristine, vinblastine, doxorubicin, cyclophosphamide), immunotherapy (interferon alpha-2a)¹² and corticosteroids, with limited response. The prognosis is poor; about two thirds of patients die of the disease, and almost 1/3 of them die within 6 months of diagnosis¹¹.

Further clarification of pathogenesis, standardizing of treatment, as well as novel therapeutic approaches are needed.

S. Badžek

Kralja Zvonimira 73, 10000 Zagreb, Croatia
e-mail: sbadzek@kbc-zagreb.hr

REFERENCES

1. VAN DER LEE I, SLEE PH, ELBERS JR, *Neth J Med*, 55 (1999) 76. — 2. SIKIC J, VUKOJEVIC N, POPOVIC-SUIC S, KATUSIC D, *Coll Antropol*, 29 Suppl 1 (2005) 119. — 3. EGAN AJ, BOARDMAN LA, TAZELAAR HD, SWENSEN SJ, JETT JR, YOUSEM SA, *Am J Surg Pathol*, 23 (1999) 17. — 4. RUSH WL, ANDRIKO JA, GALATEAU-SALLE F, BRAMBILLA E, BRAMBILLA C, ZIANY-BEY I, *Mod Pathol*, 13 (2000) 747. — 5. VEYSSIER-BELOU C, CACOUB P, CAPARROS-LEFEBVRE D, *Medicine*, 75 (1996) 157. — 6. KENN W, ECK M, ALLOLIO B, *Hum Pathol*, 31 (2000) 734. — 7. BORALEVI F, LEAUTE-LABREZE C, TISON F, BIOULAC-SAGE P, VITAL C, DELBREL X, *Ann Dermatol Venereol*, 125 (1998) 335. — 8. VITAL C, BIOULAC-SAGE P, TISON F, RIVEL J, BEGUERET H, GOMEZ C, *Clin Exp Pathol*, 47 (1999) 71. — 9. STROUSE PJ, ELLIS BI, SHIFRIN LZ, SHAH AR, *Skeletal Radiol*, 21 (1992) 64. — 10. AL-QUARAN S, REITH J, BRADLEY J, RIMSZA L, *Mod Pathol*, 15 (2002) 666. — 11. CHETRITT J, PARADIS V, DARGERIE D, ADLE-BIASSETTE H, MAURAGE CA, MUSSINI JM, *Hum Pathol*, 30 (1999) 1093. — 12. M.D. Anderson Cancer Center: Interferon-alpha Successfully Treats Complications of Rare Disease. Accessed: 12.2006. Available from: <http://www.mdanderson.org/diseases/eyecancer/display.cfm?id=5423a04c-459e-4e12-a737309ef2e1e299&method=displayfull>.

ERDHEIM-CHESTEROVA BOLEST S PRATEĆOM TUBERKULOZOM LIJEČENA USPJEŠNO KEMOTERAPIJOM I DUGOTRAJNOM TERAPIJOM

SAŽETAK

Erdheim-Chesterova bolest (ECD) je rijetka histiocitoza koja obično zahvaća koštani sustav, ali i unutarnje organe i središnji živčani sustav. Postoji vjerojatnost da imunomodulacijske terapije i poremećaji mogu utjecati na klinički tijek bolesti. Budući da je bolest rijetka, teško ju je klasificirati i standardizirati terapiju. No, prema objavljenom materijalu i našem iskustvu, citotoksična kemoterapija i dugotrajno liječenje steroidima imaju terapijski učinak. Premda se ovaj pristup može prihvatiti kao standard, novi modaliteti liječenja trebali bi biti istraženi, a trebala bi biti razjašnjena patogeneza i klasifikacija bolesti.