

Ovarian Cancer: PCD and Brain Metastases

Vesna Stepanić, Višnja Matković, Ante Ćorušić, Dubravko Barišić,
Damir Buković, and Jadranka Ilić-Forko¹

¹ Department of Gynecology and Obstetrics, University Hospital »Zagreb«, Zagreb, Croatia

ABSTRACT

Paraneoplastic cerebellar degeneration (PCD), the one of the most common paraneoplastic syndromes, refer to clinical disorders associated mostly with lung, ovarian and breast cancer, but not directly caused by the cancer or its metastases. Pathologic finding is an extensive loss of Purkinje cells in the cerebellum. Immunohistochemically, the auto-antibodies on the Purkinje cells had been detected. Clinically, PCD is characterized by sub-acutely evolving pancerebellar symptoms. Neurological dysfunction may appear before the detection of the underlying cancer. Therefore, the surgical exploration is necessary for the final diagnosis. The patient undergoes specific therapy. Soon, neurological status of the patient gets irreparable worse. Death come usually 2–3 years after the first symptoms of the PCD occurs. Case of a 63-years old woman with PCD as the first evidence of her cancer is reported. The patient developed brain metastases and died almost 3 years after the first symptoms of PCD occur.

Key words: auto-antibodies, brain metastases, gynecologic malignancies, paraneoplastic syndromes

Case Report

A 63-years-old woman, doctor in retirement, married, mother of two children was admitted to hospital for evaluation of an unsteady gait, slurred speech and some others, mostly cerebellar symptoms that had appeared a few weeks before.

The first of her four hospitalizations followed in the Department of Neurology, University Hospital Zagreb. During the time she had spent in the hospital, June, 18th – July, 11th, 2002, the detailed diagnostic procedure was made.

In the blood analysis, a mild leukocytosis was revealed (L=11.4, normal 4–10x10⁹/L). The urine and the biochemical analysis were nonspecific.

Multi-slice computed tomography of the abdomen and the pelvis and gynecological ultrasound showed mostly solid tumor mass in the left ovary, approximately 3.5x2.3 cm in the diameter with the venous type of a neo-vascularization. No enlarged lymph-node and no ascites were showed.

Serum cancer antigen levels were normal, except CA 125 level, an ovarian tumor marker which was 66.78 (normal 0.00–35.00 kIU/L).

Clinically, gynecological examination was normal, according to the years of the patient. Other physical examinations, including breast examination were also negative, except neurological status.

Neurological examination showed mild dysarthria, vertical diplopia on the left gaze with evoked horizontal nistagmus, slight ataxia on finger-to-nose and heel-to-shin testing; truncal ataxia, dysmetria mainly of the lower limbs. Her gait was broad-based and unsteady. The deep tendon reflexes were brisk and the toes were down going, she was unable to do tandem walking.

The suspicion on the gynecologic malignant was made and a laparoscopy in the Gynecologic Cancer Center, University Hospital Zagreb, was performed. A mass in the left ovary and the small, white nodule on the right fallopian tube were found. The uterus, the right ovary and the left fallopian tube appeared normal. No enlarged lymph-node and no ascites were found. She underwent bilateral salpingo-oophorectomy and the samplings of peritoneal washings for cytology were performed.

Cytology of the peritoneal irrigation fluid was negative for malignant cells. The pathological analysis re-

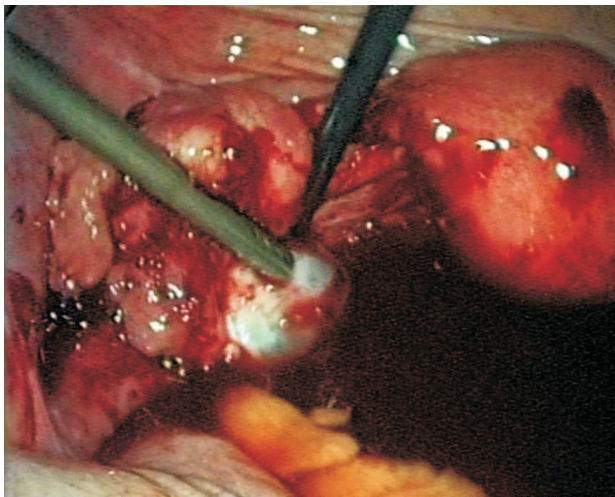


Fig. 1. Endoscopic view of the left ovary tumor.

vealed stage II A ovarian serous adenocarcinoma and serous adenocarcinoma of the part fimbriatic of the right fallopian tube.

Postoperatively, the patient started intravenous immunoglobulin (35 mg) treatment with corticosteroids.

At 2002 year no immunoassay for detection of anti-Purkinje cells in Croatia was performed. In this case, we had good reasons for suspicion on PCD. That is why our patient was the first one that the immunoassay for detection of anti-Purkinje cells was performed.

The Western blot immuno-analysis of the serum was positive for anti-Yo antibodies and diagnose of PCD with the ovarian cancer was completed.

The patient started treatment with paclitaxel, 175 mg/m² and carboplatin, AUC 5.5, 6 cycles.

After such therapy, CA 125 levels normalized (CA 125=16.10 kIU/L in October 2002, in contrast to those in August, 2002, which was 334.00 kIU/L) and gynecological examination was adequate.

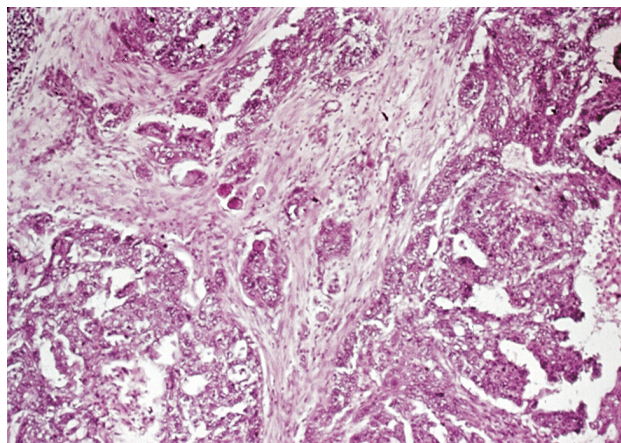


Fig. 2. a) Photomicrograph – histopathological findings of the left ovary tumor.

When she was discharged from the acute care hospital, the patient was under the therapy that oncologist, neurologist, internist and psychiatrist suggested – one year more she was taken cyclophosphamid, 100 mg/per os, corticosteroids (Decortin, 60 mg), antiepileptic (Depakine, 300 mg, Rivotril, 1 mg), antihypertensiv (Atenolol, 12.5 mg, Kalinor 2 tbl) and psychiatric drugs (Fluzepam, 15–30 mg).

She made modest improvement in her balance during transfers and ambulation at the end of the acute hospital stay. Functionally, the patient required minimal assistance for feeding and grooming, but needed moderate assistance for all the other activities of daily living. Above all, her functional status was minimally improved compared with that at admission. Her laboratory tests were almost normal, except mild leukocytosis.

In May of 2005 her neurological symptoms rapidly getting worse. Physical examination showed worsening of her ataxia, dysarthria, she became impassive and incontinent. Head MR images showed multiple metastases particularly in the left hemisphere of the brain. The irradiation therapy on the whole CNS was performed – 30 Gy/10 fractions.

For the next few weeks her condition was well. After that period, in July 2005 she became irreparable worse. She needed constantly assistance for all the activities of daily living. In blood analysis the mild leukocytosis (L=10.1) and thrombocytopenia (T=83, normal 100–400 × 10⁹/L) were detected. CA 125 levels were elevated (CA 125=63.20). Her serum chemistry and liver function showed higher levels of AST (AST=39, normal under 30 U/L), ALT (ALT=70, normal under 36 U/L), γ GT (γ GT=102, normal under 35 U/L), glucose (glucose=8.2, normal 3.75–6.0 mmol/L) and lower levels of potassium (K=3.7, normal 3.8–5.5 mmol/L).

It was clearly understood that she had to have another chemotherapy, carboplatin and cyclophosphamid, but because of the thrombocytopenia, the chemotherapy was delayed.

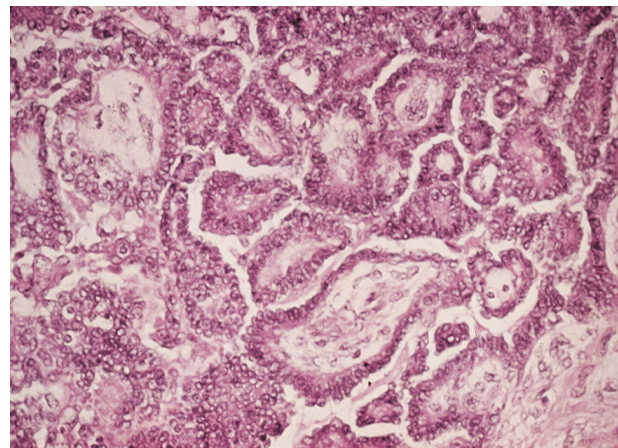


Fig 2. b) Photomicrograph – histopathological findings of the left ovary tumor (higher resolution).

The patient died in July, 2005, with hepatorenal insufficient and lack of the consciousness.

Discussion

Paraneoplastic neurological disorders are manifestations of an antitumor immune response. It consist of a variety of neurological disorders like paraneoplastic encephalomyelitis, PE, paraneoplastic sensory neuropathy, PSN, paraneoplastic cerebellar degeneration, PCD, paraneoplastic opsoclonus-myoclonus ataxia, POMA and Stiffmann syndrome¹⁻⁴.

Paraneoplastic disorders are characterized by the presence of neuronal auto-antibodies in patient serum. The detection of these auto-antibodies is useful for the clinicians as it represents the presence of an underlying tumor¹⁻⁴.

Clinical presentation includes sensory and memory loss, cerebellar, brainstem, motor or autonomic dysfunction, involuntary saccadic eye movements, truncal and limbic myoclonus and ataxia⁴⁻⁶.

In laboratory tests, usually a mild leukocytosis is revealed and higher levels of some of the serum tumor markers with normal blood chemistry and urine analysis¹⁻³.

Tumors that have been known to initiate paraneoplastic disorders are lung cancer, neuroblastoma, breast, ovarian and testicular cancers^{1,2}.

There is a strong association among paraneoplastic syndromes, anti-neuronal antibody specificities and the associated tumor types. Anti-Hu antibodies have patients with lung cancer and neuroblastomas. Anti-Ri antibodies have patients with breast and lung cancer. Anti-Yo antibodies have patients with ovarian or breast cancer or some others gynecologic cancers^{1,2}.

The paraneoplastic syndromes are estimated to occur with a frequency of no more than 1% of all cancer patients, but it always indicated further investigations². False-positive results of presenting an auto-antibody is not yet been reported.

The Western Blot immunoassay provides a sensitive method for simultaneous screening and confirmation of auto-antibodies against various neuronal antigens present in the nucleus as well as the cytoplasm of granular cells². This method is in use in the Department of Immunology of the University Hospital Zagreb.

The Immuno-Blot anti-neuronal antibody strips contain 125, 70 and 77 kD molecular weight markers. Anti-Hu and anti-Ri reactions can be easily observed at 35–40 and 55 kD region respectively, anti-Yo reactions at 24–62 kD. If the specimen yields no immuno-reactivity on the blot strip, the result should be reported as negative^{2,3,7}.

In our patient, 2–3 weeks passed between the first symptoms appeared and the first hospitalization in Department of Neurology, University Hospital Zagreb. Another 7–8 weeks passed until the neurological illnesses were excluded. From the appearance of the first neurological signs and death passed about 3 years. The patient

gets worse constantly with a period of stagnation, but no regression of the symptoms.

The patient underwent surgical procedure, intravenous immunoglobulin and corticosteroid treatment and chemotherapy. All the time she received bedside physical therapy and psychiatric consultation.

At 2002 year no immunoassay for detection of anti-Purkinje cells in Croatia was performed. In this case, we had good reasons for suspicion on PCD. That is why our patient was the first one that the immunoassay for detection of anti-Purkinje cells was performed.

By the western blot immunoassay, the reaction appeared at 24–65 kD and the anti-Yo antibody was recognized as positive. In according to the pathologic findings of the stage II A ovarian serous adenocarcinoma and serous adenocarcinoma of the part fimbriatic of the right fallopian tube and neurological disorders, the diagnosis of the paraneoplastic cerebellar degeneration with the ovarian cancer was made.

It is known that in neurologically normal patient with above mentioned cancers no anti-neuronal antibodies were found⁵.

This evidence leads to questions about the factors that cause the appearance of the anti-neuronal antibodies and paraneoplastic syndromes in general.

When these mechanisms will be understood completely, the further investigations about the appropriate treatment of the neurological symptoms will be observed. It is necessary because the present procedure, such as surgical, immunoglobulin and chemotherapy have no influences on the neurological symptoms. The patient has some period of getting better, but soon the neurological symptoms getting worse and led to death in a no-consciousness state of mind⁶. Further investigation into the pathogenesis of paraneoplastic cerebellar degeneration combined with earlier detection and therapy of the malignancy may offer an improved neurological prognosis in the future.

In this case, there is another thing that has to be emphasized. To our best knowledge, brain metastases from ovarian cancer are uncommon. The incidence of cerebral metastases from epithelial ovarian cancer is 0.29%–1.3% according to different authors⁸⁻¹⁴. Diagnosis of brain metastases is readily made on high-resolution imaging technology such as CT scan or MRI. There is no standard treatment for brain metastases from ovarian cancer. The choice of therapy is based on the location of metastases, the presence of disease at other sites, and history of previous treatment. The array of therapies includes surgery, radiotherapy and chemotherapy⁸⁻¹⁰. The outcomes of different modalities of therapy, showed by median survival are very uncommon.

In our patient head MR images showed multiple metastases particularly in the left hemisphere of the brain. The irradiation therapy on the whole CNS was performed – 30 Gy/10 fractions. For the next few weeks her condition was well. After that period, in July 2005 she became irreparable worse. She needed constantly assis-

tance for all the activities of daily living. It was clearly understood that she had to have another chemotherapy, carboplatin and cyclophosphamid, but because of the thrombocytopenia, the chemotherapy was delayed.

The patient died in July, 2005, with hepatorenal insufficiency and lack of the consciousness.

The median follow-up period for brain metastases was 8.5 months, range 5–19 months⁸. Because of the general condition of our patient and according to her years, we decided our patient treated by irradiation on whole CNS. After such therapy, she lived for next 3 months. It has to be emphasized that she was in bed general condition because of what neurosurgeon and oncologist were against any radical treatments on brain metastases. She was also un-

able to receive any other chemotherapy, so irradiation was the only acceptable palliative therapy.

In conclusion, this case of laboratory and histopathologically confirmed paraneoplastic cerebellar degeneration and brain metastases in a patient with epithelial ovarian cancer are uncommon in medical literature. According to all today's medical knowledge, first she underwent surgical treatment, than chemotherapy and irradiation therapy on the whole CNS and physical therapy. From the appearance of the first neurological signs and death, treated her by all the procedure mentioned above, passed about 3 years, and that is data that other authors mention talking about the disease-free interval for ovarian cancer^{8,9}.

REFERENCES

1. DALMAU JO, POSNER JB, Arch Neurol, 56 (1999) 405. — 2. ROJAS-MARCOS I, ROUSSEAU A, KEIME-GUIBER F, RENE R, CARTALAT-CAREL S, J. Y. DELATTRE JY, F. GRAUS F, Medicine, 82 (2003) 216. — 3. ROJAS I, GRAUS F, KEIME-GUIBERT F, RENE R, DELATTRE JY, RAMON JM, DALMAU J, POSNER JB, Neurology, 55 (2000) 713. — 4. CARDOSI RJ, DECESARE SL, ROBERTS WS, Int J Gynecol Cancer, 7 (1997) 279. — 5. GEOMINI PM, DELLEMIJN PL, BREMER GL, Gynecol Obstet Inves, 52 (2001) 145. — 6. SUTTON I, Curr Opin Neurol, 15 (2002) 685. — 7. AGUIRRE-CRUZ L, CHARUEL JL, CARPENTIER AF, BENYAHIA B, DELATTRE JY, MUSSET L, J

Neurooncol, 71 (2005) 39. — 8. TAY SK, RAJESH H, Int J Gynecol Cancer, 15 (2005) 824. — 9. CHI DS, LIAO JB, LEON LF, Gynecol Oncol, 82 (2001) 532. — 10. GEISLER JP, GEISLER HE, Gynecol Oncol, 57 (1995) 246. — 11. D'ANDREA G, ROPERTO R, DINIA L, CAROLI E, SALVATI M., FERRANTE L, Neurosurg Rev, 28 (2005) 120. — 12. KOUL A, LOMAN N, MALANDER S, BORG A, RIDDERHEIM M, Gynecol Oncol, 41 (2001) 67. — 13. MELICHAR B, URMINSKA H, KOHLOVA T, NOVA M, ČESAK T, Gynecol Oncol, 94 (2004) 267. — 14. POTHURI B, CHI DS, REID T, AGHAJANIAN C, VENKATRAMAN E, ALEKTIAR K, Gynecol Oncol, 87 (2002) 133.

V. Stepanić

Department of Gynecology and Obstetrics, University Hospital Zagreb, Petrova 13, 10000 Zagreb, Croatia
e-mail: vstepi@yahoo.com

RAK JAJNIKA: PCD I METASTAZE U MOZGU

SAŽETAK

Paraneoplastična cerebelarna degeneracija (PCD) najčešća je manifestacija paraneoplastičnog sindroma, koji se može se javiti uz mnoge malignome, no najčešće ide uz rak pluća, jajnika i dojke. Sindrom je povezan s rakom, ali nije uzrokovan samim rakom ni njegovim presadnicama. Patohistološki, nalazi se gubitak Purkinjeovih stanica u malom mozgu. Imunološkim metodama registrira se postojanje autoantitijela na Purkinjeove stanice. Klinički, dolazi do subakutnog razvoja neurološke simptomatologije. Neurološki simptomi nerijetko se mogu javiti uz ostale uredne kliničke pokazatelje, pa se tek dijagnostičkom laparoskopijom, odnosno eksplorativnom laparotomijom, potom i patohistološkom obradom materijala, može dokazati postojanje raka. Nakon liječenja kemoterapeutičima i imunoglobulinima, neurološki se status bolesnika stabilizira, međutim ubrzo nastupi daljnje pogoršanje. Letalni ishod bolesti obično nastupi 3-5 godina nakon pojave prvih znakova paraneoplastičnog sindroma. Opisan je slučaj 63-godišnje bolesnice s PCD-om kao prvom manifestacijom bolesti. U bolesnice su se razvile metastaze u mozgu i letalni je ishod nastupio gotovo 3 godine nakon pojave prvih simptoma PCD-a.