

A Rare Case of Multiple Aneurysms in a Young Patient

Tomislav Trajbar¹, Predrag Pavić¹, Ante Ivkošić¹, Elvira Grizelj Stojčić² and Višnja Neseck Adam²

¹ Department of Vascular Surgery, General Hospital »Sveti Duh«, Zagreb, Croatia

² Department of Anesthesiology, General Hospital »Sveti Duh«, Zagreb, Croatia

ABSTRACT

Multiple aneurysms are clinically common in population aged over sixty and are caused mainly by atherosclerosis. When occurring in young population other etiologies such as trauma, infections, Bechet's disease, Marfan syndrome, neurofibromatosis or inflammatory disease are responsible for the development of arterial aneurysms. A rare case of multiple aneurysms in a 40-year-old man, affecting the infrarenal part of abdominal aorta, both iliac arteries, common femoral arteries, left femoral superficial and popliteal arteries on both legs, is reported. The underlying pathology was progressive atherosclerosis, favored by familial hyperlipidemia and excessive cigarette smoking.

Key words: multiple aneurysms, popliteal artery, hyperlipidemia

Introduction

Multiple aneurysms can be defined as one or more concomitant aneurysms in different arterial segments, clinically frequent in the population over 60, the origin of the disease is mainly atherosclerosis^{1–3}. Some authors use term »aneurysmosis«, which clinically implies these multiple aneurysms presented at different or the same level of the vascular tree separated by normal, occluded or arteriomegalic arteries³. Predominant locations are abdominal aorta, femoral arteries and popliteal arteries, whereas tibial and fibular arteries are rarely affected¹.

Usual diagnostic procedures employed in the detection of multiple aneurysms include physical examination along with Doppler ultrasonography, angiography and computed tomography (CT).

Aneurysms of femoral and popliteal arteries are defined as focal arterial dilatation of at least 1.5 times the adjacent normal arterial segment, while abdominal aortic aneurysm (AAA) is defined as having anterior posterior diameter of aorta of at least 3 cm. The leading symptoms of AAA are pulsatile mass in abdomen, low or loss of arterial pulses on lower extremities, nausea, and back-pain, whereas aneurysms of popliteal and femoral arteries are often presented with intermittent claudication and symptoms of distal embolism, or without symptoms^{1–9}.

Current recommendations for the management of the disease depend on many factors such as the size and location of aneurysm, the risk of complications such as embolism, rupture and thrombosis but the general issue is that the best therapeutic approach for femoral and popliteal aneurysms is elective surgery including exclusion of the aneurysm with proximal and distal ligation combined with reverse great saphenous vein bypass grafting around the affected segment of the artery, and in patients with AAA bypass with prosthesis or endovascular repair^{1–9}.

A rare case of multiple aneurysms of progressive atherosclerotic origin in a young man aged 40 is presented.

Case Report

A 40-year-old man was referred to the hospital for the clinical condition of embolism of peripheral arteries of the right leg with severe ischemia. On admission he complained of severe pain in the entire right leg, which was pale, cold, with unpalpable pulses in the right popliteal artery and arteries of the right foot. Even ultrasonographic measurement of arterial flow distally of the right common femoral artery failed to show any flow. The pa-

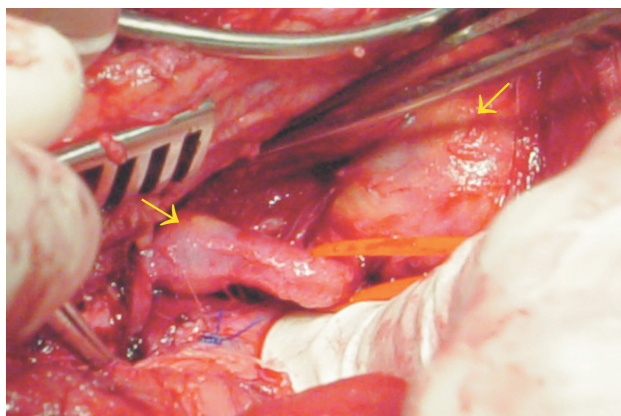


Fig. 1a. Aneurysms of popliteal arteries, the second and third (the smallest) aneurysm labeled by yellow arrows.

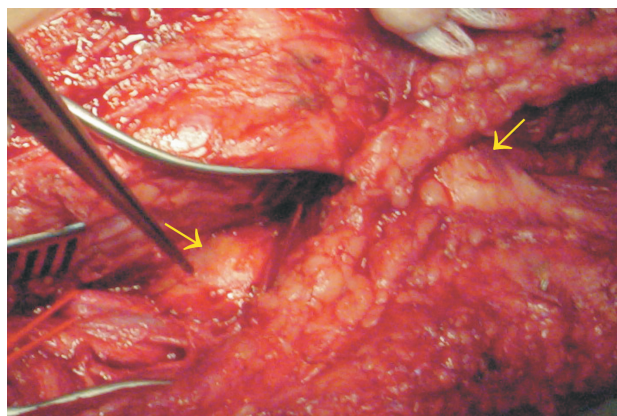


Fig. 1b. Aneurysms of popliteal artery, the proximal and second one (pointed by forceps) labeled by yellow arrows.

tient underwent urgent surgery, embolectomy using Fogarty catheter through the femoral artery. It was unable to reach popliteal artery because of obvious obstruction at the level of popliteal fossa. Distal segment of the popliteal artery was explored and operative treatment in the form of femoropopliteal bypass was indicated as an appropriate therapeutic option. The exploration revealed three giant, thrombosed aneurysms of the popliteal artery: the first one under the adductor canal at the level of the proximal part of popliteal artery, the second one at the distal part of popliteal artery, both egg-like and of up to 5 cm in diameter, and the third, smallest one, up to 2 cm in diameter, situated a few millimeters over popliteal artery trifurcation (Figure 1a–b). Medial approach using bypass graft with autologous great saphenous vein and exclusion of the aneurysms by ligation was done, followed by crural fasciotomy. After the surgery, pulses in the dorsal artery of the foot and posterior tibial artery remained palpable, and the leg color and temperature turned normal. Laboratory findings were as follows: leukocytes $7.40 \times 10^9/L$, erythrocytes $4.13 \times 10^{12}/L$, hemoglobin 125g/L, hematocrit 0.365 L/L, platelets $231 \times 10^9/L$, blood glucose 6.4mmol/L, sodium 138 mmol/L, and potassium 4.1 mmol/L. Lipidogram showed hypertriglyceridemia 9.12 mmol/L, hypercholesterolemia 9.54 mmol/L, HDL cholesterol 0.83 mmol/L and LDL cholesterol 5.19 mmol/L confirming the diagnosis of hyperlipidaemia. According to the patient's medical history, hyperlipidaemia had been diagnosed several years before, since when he had been treated with statins and low cholesterol diet.

Postoperatively, thorough diagnostic follow up was performed. CT scans were revealed aneurysm of abdominal aorta of up to 5.5 cm in diameter, located infrarenally; aneurysms of both common iliac arteries (left 4 cm and right 3 cm) extending to the right internal iliac artery; aneurysms of common femoral arteries and left femoral superficial artery; multiple aneurysms of the right popliteal artery; and an aneurysm of left popliteal artery. Digital subtraction angiography (DSA) showed identical findings, along with normal flow through the venous bypass graft (Figure 2a–c). Coronarography indi-

cated occlusion of the right coronary artery. Electrocardiography pointed to a previous myocardial infarction, although the patient denied any heart problems in the past. Medical family history was negative, however, the patient had a history of cigarette smoking of more than 30 years.

Discussion

Multiple aneurysms are often seen in patients aged over. According to relevant literature data multiple aneurysms are found in 83 % of patients with peripheral aneurysms³. On the other hand, there are reports on the incidence of femoral and popliteal artery aneurysms in patients with abdominal aortic aneurysms of 14% in men and 0% in women, whereas some previous studies report it to be between 3.2 and 3.9%¹⁰. According to these studies, the mean age of the male patients with multiple aneurysms is 73.4 ± 6 .

Our patient had a negative family history, which is in agreement with previous studies even though this parameter is unreliable because patients with aneurysms are often asymptomatic, and physical examination often fails to detect the disease, thus limiting the value of the patient's awareness of their relative's disease¹⁰.

According to our knowledge, this is a unique case report of multiple aneurysms originating from accelerated atherosclerosis in such a young patient^{12–15}. There are some reports of multiple aneurysms in patient with Bechet's disease that is characterized by mouth and genitalia ulcers, and uveitis, and in patients with neurofibromatosis; however, in the present case these were excluded as the patient exhibited no sign or symptoms of these diseases^{16,17}. Some reports describe a correlation between trauma, osteochondroma and development of aneurysms, however, these were sporadic cases, limited to aneurysms of lower extremities, and occurring in only one segment of the vascular tree which was exposed to trauma or osteochondroma^{18,19}. Marfan syndrome has

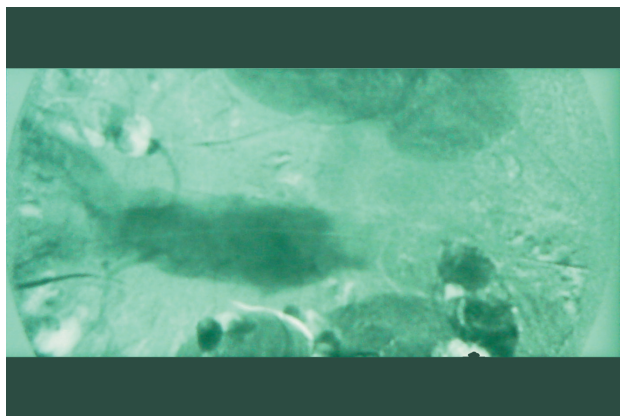


Fig. 2a. Angiography showing aneurysm of infrarenal part of abdominal aorta.

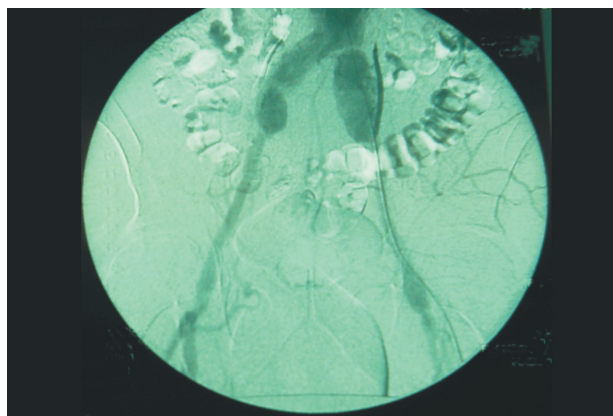


Fig. 2b. Aneurysms of common iliac arteries and femoral arteries.

distinct symptoms; however, our patient did not have any phenotypic characteristic of this disease¹.

Multiple aneurysms show a male predominance, which is by some authors related to genetic and biologic processes distinct from those contributing to patients with only AAA disease^{10,11}. If multiple aneurysms have a potential genetic origin, the nature of the consequential connective tissue disorder is mild progression with a peak in fifth or sixth decade of life. According to these observations, this patient may have some underlying genetic susceptibility as a predisposing factor in aneurysmal development supported by hyperlipidemia and adverse social behavior such as smoking.

Some authors hypothesize that specific genetic or some other factors that are not present in most patients with AAA are responsible for the occurrence of concomitant peripheral aneurysms, so the generalized vascular diathesis observed in some patients including our patient could be a particular entity not primarily connected with AAA disease^{1,10,11}. Our patient also had an aneurysm of the popliteal artery on the left leg, which is considered to be a more health threatening condition than femoral aneurysm, so the best therapeutic approach was bypass grafting with ligation and aneurysmal exclusion⁴⁻⁹. The size of his AAA was within the limit of elective surgery treatment, and considering his age and condition he should to undergo another surgical treatment¹, which he has not yet decided to. Nevertheless, he should be under

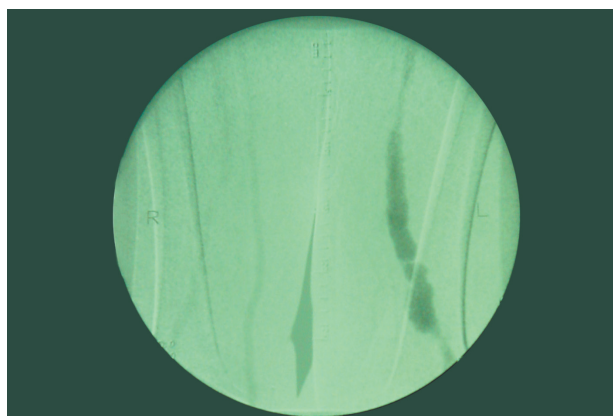


Fig. 2c. Aneurysm of left femoral superficial artery and popliteal artery and normal flow through the femoropopliteal bypass on the right side.

close clinical follow up after the next surgery, along with low cholesterol and triglyceride diet and therapy with hypolipidemics agents.

In conclusion, it should be emphasized that multiple aneurysms are not only a disorder of the elderly, as young age does not exclude aneurysmal disease of atherosclerotic origin. Genetic predilection of the disorder has to be considered and investigated in future studies.

REFERENCES

1. RUTHERFORD, R. B., Vascular surgery, (Saunders, Philadelphia, 2000). — 2. DENT, T. L., S. M. LINDENAUER, C. B. ERNST, W. J. FRY, Arch. Surg., 105 (1972) 338. — 3. YAMAMOTO, N., N. UNNO, H. MITSUOKA, T. UCHIYAMA, T. SAITO, H. KANEKO, S. NAKAMURA, Surg. Today., 32 (2002) 970. — 4. BLACKETT, R. L., Eur. J. Vasc. Endovasc. Surg., 25 (2003) 79. — 5. MAHMOOD, A., R. SALAMAN, M. SINTLER, S. R. SMITH, M. H. SIMMS, R. K. VOHRA, J. Vasc. Surg., 37 (2003) 586. — 6. HARDER, Y., H. NOTTER, P. NUSSBAUMER, A. LEISER, C. CANOVA, M. FURRER, World. J. Surg., 27 (2003) 788. — 7. ASCHER, E., N. MARKEVICH, R. W. SCHUTZER, S. KALLAKURI, T. JACOB, A. P. HIN-

GORANI, J. Vasc. Surg., 37 (2003) 755. — 8. EBAUGH, J. L., M. D. MORASCH, J. S. MATSUMURA, M. K. ESKANDARI, W. S. MEADOWS, W. H. PEARCE, J. Vasc. Surg., 37 (2003) 954. — 9. IRACE, L., R. GATTUSO, F. FACCENNA, F. CAPPELLO, A. SIANI, R. STUMPO, S. BOICEFF, F. BENEDETTI-VALENTINI, Minerva. Cardioangiol., 49 (2001) 251. — 10. DIWAN, A., R. SARKAR, J. C. STANLEY, G. B. ZELENOCK, T. W. WAKEFIELD, J. Vasc. Surg., 31 (2000) 863. — 11. SANDGREN, T., B. SONESSEN, T. RYDEN-AHLGREN, T. LANNE, J. Vasc. Surg., 34 (2001) 1079. — 12. BRUNS, C., H. ERASMI, P. LANDWEHR, Chirurg., 65 (1994) 892. — 13. VEINOT, J. P., M. LAMBA, Arch. Pathol. Lab. Med., 125 (2001) 831. —

14. KUDO, F. A., T. NISHIBE, K. MIYAZAKI, J. FLORES, K. YASUDA, J. Cardiovasc. Surg., 43 (2002) 515. — 15. GISSEROT, O., G. CELLARIER, J. BONAL, H. THOUARD, G. V. DUSSARAT, J. Mal. Vasc., 24 (1999) 306. — 16. BARTLETT, S. T., W. J. MCCARTHY 3RD, A. S. PALMER, W. R. FLINN, J. J. BERGAN, J. S. YAO, Arch. Surg., 123 (1988) 1004. — 17.

YOUNG, L. P., A. STANLEY, J. O. MENZOIAN, J. Vasc. Surg., 33 (2001) 1114. — 18. ESCHELMAN, D. J., J. R. GARDINER GA, D. M. DEELY, J. Vasc. Interv. Radiol., 6 (1995) 605. — 19. SMITS, A. B., H. D. PAVOORDT, F. L. MOLL, Ann. Vasc. Surg., 2 (1998) 370.

A. Ivkošić

*Selska 7, 10000 Zagreb, Croatia
e-mail: ante.ivkovic@hi.t-com.hr*

RIJEDAK SLUČAJ MULTIPLIH ANEURIZMI KOD MLADOG BOLESNIKA

SAŽETAK

Multiple aneurizme su klinički česte u populaciji iznad 60 godina starosti i uglavnom su uzrokovane aterosklerozom. Kod mlađe populacije etiologija je drugačija, pa su trauma, infekcije, Bechetova bolest, Marfanov sindrom, neurofibromatoza ili upalne bolesti odgovorne za razvoj arterijskih aneurizmi. Prezentiran je rijedak slučaj multiplih aneurizmi kod 40 godina starog bolesnika, koje zahvaćaju infrarenalni dio abdominalne aorte, obje ilijačne arterije, zajednička femoralna arterija, lijeva superficijalna femoralna arterija i poplitealne arterije na obje noge. Podrijetlo bolesti je bila progresivna ateroskleroza potencirana sa obiteljskom hiperlipidemijom i pretjeranim pušenjem.