



## RARE LARYNGEAL HAMARTOMA: A CASE REPORT

Karolina Veselski Krajinović<sup>1</sup>, Tomislav Stojadinović<sup>1</sup>, Ivana Pajić Matić<sup>1,6</sup>, Ivo Matić<sup>2,6</sup>, Alen Sekelj<sup>1</sup>,  
Ivana Mahovne<sup>3</sup>, Marcel Marcikić<sup>4</sup> and Krešimir Rotim<sup>5,6</sup>

<sup>1</sup>ENT Department, Dr. Josip Benčević General Hospital, Slavonski Brod, Croatia;

<sup>2</sup>Department of Anesthesia and Resuscitation, Dr. Josip Benčević General Hospital, Slavonski Brod, Croatia;

<sup>3</sup>Department of Pathology and Cytology, Dr. Josip Benčević General Hospital, Slavonski Brod, Croatia;

<sup>4</sup>Department of Surgery, Dr. Josip Benčević General Hospital, Slavonski Brod, Croatia;

<sup>5</sup>Department of Neurosurgery, Sestre milosrdnice University Hospital Center, Zagreb, Croatia;

<sup>6</sup>Josip Juraj Strossmayer University of Osijek, Faculty of Medicine, Osijek, Croatia

**SUMMARY** – Hamartoma (from the Greek language, where *hamartia* means defect or an error and *-oma* denoting a tumor or neoplasm) is a benign tumor-like mass composed of mature tissue or cells that are present in abnormal proportions or show a disorganized arrangement. Hamartomas are rarely seen in the head and neck area and especially rare in the larynx. Only few cases of laryngeal hamartoma have been reported in the literature so far. They are usually manifested by stridor, dysphonia and symptoms associated with airway obstruction. The diagnosis must be confirmed histologically and the method of choice in treatment is complete excision of the lesion. The authors present a case of laryngeal hamartoma of a 43-year-old woman treated for hoarseness and paralysis of the left vocal cord.

**Key words:** *Hamartoma; Larynx; Vocal cord paralysis*

### Introduction

The word hamartoma comes from the Greek language where *hamartia* means defect or an error and *-oma* a tumor or neoplasm<sup>1</sup>. Hamartoma is a benign

tumor-like mass composed of mature tissue or cells that are present in abnormal proportions or show a haphazard, disorganized arrangement<sup>2</sup>. They are considered as a developmental malformation and are most commonly found in the lungs, liver, spleen and kidney, rarely in the head and neck region, and extremely rarely in the larynx<sup>3</sup>. Hamartomas can be associated with inherited syndromes or sporadic, they can be solitary or multiple, asymptomatic or symptomatic, depending on the organ system that is affected.

---

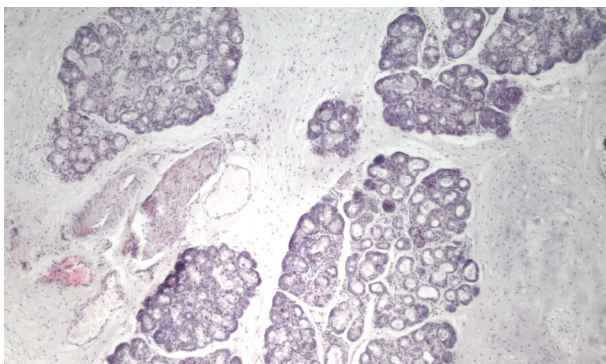
Correspondence to: *Karolina Veselski, MD*, ENT Department, Dr. Josip Benčević General Hospital, Andrije Štampara 42, HR-35000 Slavonski Brod, Croatia  
E-mail: karolina.veselski1@gmail.com

Received December 15, 2020, accepted November 10, 2021

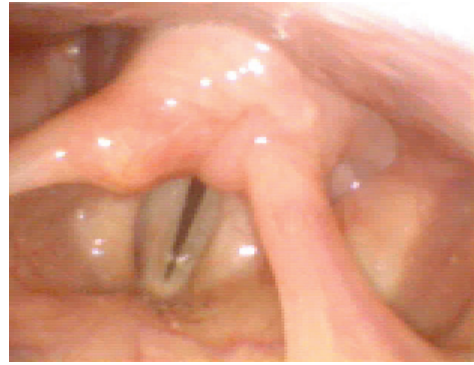\*This case was presented as a brief abstract at the 11<sup>th</sup> Croatian ENT Congress 2019 in Mali Lošinj, Croatia

## Case Report

A 43-year-old female patient was referred to our ENT Department because of sudden dysphonia, diagnosed left vocal cord paralysis, and a suspected tumor in the same area. The patient's past medical history included uterine polyp removal. She was not taking any chronic therapy. At first clinical examination, she had a prior medical work-up involving neck ultrasound, describing the thyroid of an inhomogeneous structure and a 7-mm diameter hypoechoic area with sharp contours in the right lobe of the thyroid. Ultrasound revealed no changes in the salivary and parotid glands, or any suspected, enlarged lymph nodes in the neck. Upon fine-needle aspiration of the thyroid node described, a diagnosis of subacute thyroiditis (de Quervain) was made. Computed tomography (CT) scan of the neck showed a 9-mm thick mass with rough edges in the posterior part of the left vocal cord, near the pyriform sinus, which was intensely postcontrast imbibed. ENT examination was normal, but indirect laryngeal mirror examination revealed left vocal cord paralysis and swollen left arytenoid. The patient was hospitalized and underwent laryngomicroscopy, which revealed a thickened left arytenoid and a submucosal mass in the same area. Suspected submucosal mass was removed with a part of the mucous membrane of the left arytenoid. Histologic finding showed the specimens to be partly covered by a multilayered squamous epithelium and partly by the respiratory epithelium without atypia. In the underlying stroma, there were neat, regular-looking, seromucous glands, mature adipose tissue, partly myxoid-altered connective tissue, cartilage

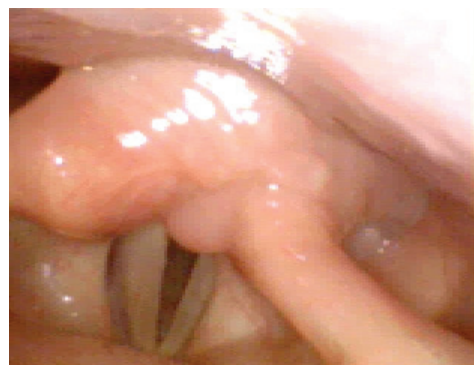

*Fig. 1. The image shows multiplied seromucous glands, multiplied myxoid connective tissue, blood vessels and nerves in mucosal stroma (HE X40).*



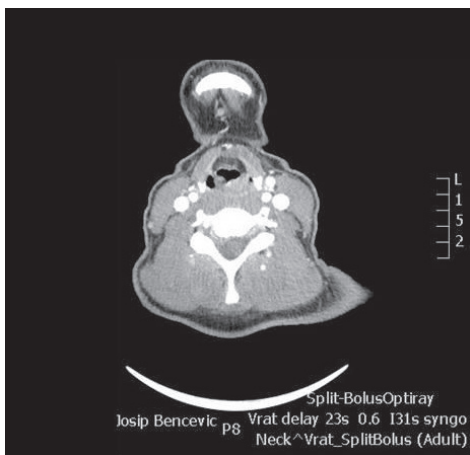
*Fig. 2. Postoperative follow-up flexible laryngoscopy: visible paralysis of the left hemilarynx.*

and multiplied blood vessels and nerves. Histologically and immunohistochemically (pan-CK, CD34, S100, and SMA), in terms of differential diagnosis, the finding was corresponding to hamartoma. From the received material, it was not possible to conclude with certainty whether the change described had been



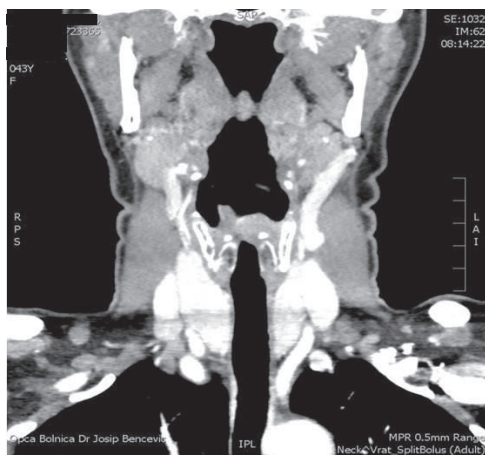
*Fig. 3. Flexible laryngoscopy: paralysis of the left vocal cord with submucosal mass in the left arytenoid.*

completely removed (Fig. 1). At the first postoperative follow-up visit, the patient's voice was subjectively improved, but flexible laryngoscopy showed the left vocal cord still in paramedial position and the site of the left arytenoid biopsy, while other local findings were normal. At the second postoperative follow-up visit, her voice was again dysphonic and flexible laryngoscopy revealed visible paralysis of the left hemilarynx with submucosal mass in the left arytenoid (Figs. 2 and 3). Follow-up CT scan showed an oval area of 12x9x8 mm in size in the posterior part of the left false vocal cord that was discretely postcontrast imbibed, which reduced the left pyriform sinus and corresponded to



*Fig. 4. Postoperative follow-up computed tomography (axial plane): in the posterior part of the left false vocal cord, an oval area (12x9x8 mm in size) that was discretely postcontrast imbided reduces the left pyriform sinus.*

the previously verified process. Other structures of the pharynx were normal (Figs. 4 and 5). The patient was re-hospitalized for laryngomicroscopy when extensive excision of the submucosal mass of the left arytenoid and left ventricular fold at the site of the scar was performed. Histopathologic findings showed that it was a scar and no hamartoma was found. Her voice was now satisfying but she reported occasional hoarseness and shortness of breath. Flexible laryngoscopy showed hyperemia of the right arytenoid, a condition after partial excision of the posterior third of the left ventricular



*Fig. 5. Postoperative follow-up computed tomography (coronal plane): previously verified process in the posterior part of the left false vocal cord.*

fold and left arytenoid. The left vocal cord appeared to be slower relative to the right vocal cord. Postoperative follow-up CT scan described asymmetry of the width of the pyriform sinuses but no imbibition for possible relapses. The patient has been regularly followed-up at our ENT outpatient clinic every 3-6 months and a follow-up period of at least 5 years has been planned. In the postoperative period of 16 months, the patient showed no signs of disease.

## Discussion

According to the definition, “Hamartoma is defined as a benign tumor-like mass composed of mature tissue or cells that are normally present in the location where it is found but occurring in abnormal proportions or arrangement”. The term was first mentioned in the literature by Albrecht with the aim of distinguishing tumor-like formations from true neoplasms<sup>4</sup>. Smith was the first to report on possible laryngeal hamartoma in 1959<sup>5</sup>, but it turned out to be rhabdomyosarcoma of the larynx, therefore, the first recorded case in the literature is considered to be laryngeal hamartoma in a 6-week-old baby described by Zapf *et al.* in 1981<sup>6,7</sup>. Laryngeal hamartomas are extremely rarely seen, with about 35 reported cases so far, especially if we exclude inadequately described cases in the literature<sup>8</sup>. This entity is usually seen in children aged 0-6 years or in adults aged 39-56 years. They are more common in men than in women<sup>9</sup>. Given histologic findings, hamartomas are classified into mesenchymal, epithelial, and glandular<sup>10-12</sup>. They are usually manifested by stridor, dysphonia, and symptoms associated with airway obstruction. To the best of our knowledge, laryngeal hamartoma followed by vocal cord paralysis, as in our patient, would be the fourth case described in the literature thus far. In differential diagnosis, other benign changes of the larynx, such as choristoma, dermoid cyst, rhabdomyoma or teratoma, but also malignant changes should be considered. Diagnostics includes imaging in the form of CT or magnetic resonance imaging. Definitive diagnosis is made histopathologically, and the method of choice in the treatment is complete excision of the lesion while preserving the laryngeal function. In only a few cases reported in the literature, hemilaryngectomy or total laryngectomy was required<sup>13</sup>. Recurrences are associated with incomplete resection of the lesion<sup>14</sup>.

## Conclusion

Laryngeal hamartomas are an extremely rare finding. They are mainly detected due to the symptoms they cause. The diagnosis must be confirmed histologically and the method of choice in the treatment is complete excision of the lesion. Laryngeal hamartoma should be included in the differential diagnosis of benign laryngeal lesions, particularly in children. The prognosis of patients with laryngeal hamartoma is excellent and patients should be monitored regularly.

## References

- Venes D, Taber CW. Taber's Cyclopedic Medical Dictionary. 22<sup>nd</sup> edn. Philadelphia: F.A. Davis, 2013.
- Patil S, Roopa SR, Majumdar B. Hamartomas of the oral cavity. *J Int Soc Prev Community Dent.* 2015;5(5):347-53.
- Uçar Ş, Zorlu P, Yıldırım I, Metin Ö. Hamartoma of the larynx: an unusual cause of stridor. *Balkan Med J.* 2014;31(4):349-51. DOI: 10.5152/balkanmedj.2014.13184
- Albrecht E. Über Hamartome. *Verh Dtsch Ges Pathol.* 1904;7:153-7. (in German)
- Smith HW. Skeletal muscle rhabdomyoma of the larynx. Report of a case. *Laryngoscope.* 1959;69:1528-36. DOI: 10.1288/00005537-195912000-00006
- Zapf B, Lehmann WB, Snyder GG 3<sup>rd</sup>. Hamartoma of the larynx: an unusual cause for stridor in an infant. *Otolaryngol Head Neck Surg.* 1981;89:797-9. DOI: 10.1177/019459988108900520
- Windfuhr JP. Laryngeal hamartoma. *Acta Otolaryngol.* 2004;124:301-8. DOI: 10.1080/00016480310014831
- Amir JA, Sheikh SS. Mesenchymal hamartoma of the larynx: a rare case report and review of literature. *Case Rep Clin Pathol.* 2015;2(3):40-3. DOI: <https://doi.org/10.5430/crcp.v2n3p40>
- García RE, Maza SJM, Herrero ST, Sánchez GS. Hamartoma condroide laringeo: un caso excepcional. *Acta Otorrinolaringol Esp.* 2016;67:117-9. (in Spanish)
- Leoncini G, Maio V, Mirabile L, Baggi R, Franchi A. Glandular hamartoma of the larynx: report of a case. *Auris Nasus Larynx.* 2008;35(1):149-51. DOI: 10.1016/j.anl.2007.03.015
- Alvaréz-Neri H, Sadowinski S, de La Torre C, Villamor P. Hamartoma of the vallecula in a five-month-old infant – a case report. *Iran J Otorhinolaryngol.* 2019;31(104):177-80.
- Kislal FM, Acar B, Acar M. Laryngeal fibrous hamartoma presenting with airway obstruction at birth. *J Craniofac Surg.* 2013;24:e383-e384. DOI: 10.1097/SCS.0b013e31829031fd
- Rinaldo A, Mannara GM, Fischer C, Ferlito, A. Hamartoma of the larynx: a critical review of the literature. *Ann Otol Rhinol Laryngol.* 1998;107:264-7. DOI: 10.1177/000348949810700314
- Colon JE, Jang DW, Del Signore A. Hamartoma of the larynx: a report of two cases. *Laryngoscope.* 2011;121:S128-S128.

## Sažetak

### PRIKAZ RIJETKOG SLUČAJA HAMARTOMA LARINKSA

*K. Veselski Krajinović, T. Stojadinović, I. Pajić Matić, I. Matić, A. Sekelj, I. Mahovne, M. Marcikić i K. Rotim*

Hamartom (iz grčkog *hamartia*, što znači greška, defekt i *-oma*, označava tumor ili neoplazmu) je benigna masa izgledom slična tumoru, sastavljena od zrelih tkiva ili stanica koje pokazuju poremećaj proporcija ili se pojavljuju u neorganiziranom rasporedu. Hamartomi rijetko zahvaćaju područje glave i vrata, a još rjeđe ih pronalazimo u području larinksa. Dosad je u literaturi opisano samo nekoliko slučajeva laringealnih hamartoma. Najčešće se manifestiraju stridorom, disfonijom te simptomima vezanim uz opstrukciju dišnih putova. Dijagnoza se postavlja patohistološki, a metoda izbora u liječenju je potpuna ekscizija lezije. Autori prikazuju slučaj laringealnog hamartoma u 43-godišnje žene obrađivane zbog promuklosti i pareze lijeve glasnice.

Cljučne riječi: *Hamartom; Larinks; Pareza glasnice*