

Clinical Case of Acral Hemorrhagic Darier's Disease is not Caused by Mutations in Exon 15 of the ATP2A2 Gene

Nives Pećina-Šlaus¹, Višnja Milavec-Puretić², Milovan Kubat³,
Ivana Furač³, Monika Karija³, Martina Fischer-Žigmund¹ and
Jasna Lipozenčić²

¹ Department of Biology, School of Medicine, University of Zagreb, Zagreb, Croatia

² Department of Dermatovenerology, University Hospital Center »Zagreb«, Zagreb, Croatia

³ Department of Forensic Medicine, School of Medicine, University of Zagreb, Zagreb, Croatia

ABSTRACT

Darier's disease (Dyskeratosis follicularis, DD) is a genetic disorder characterized by pathogenetic changes of keratinization with variant forms of cutaneous phenotype. Recently, it has been showed that Darier's disease cause mutations in the ATP2A2 gene, at 12q24.1. The gene encodes sarco-endoplasmic reticulum calcium ATPase type 2 (SERCA2). Mutations in exon 15 are reported to be the most consistent mutations associated with the acral hemorrhagic type of Darier's disease. By direct sequencing we investigated exon 15 of the ATP2A2 gene in a Croatian family in which one member had a hemorrhagic Darier's disease, but did not record any mutation in the family we investigated. Our results show that mutations in exon 15 of the ATP2A2 gene are not a necessary prerequisite for acral hemorrhagic type of Darier's disease. Our finding support the variability of clinical manifestations of Darier's disease and lack of genotype/phenotype consistency.

Key words: *keratosis follicularis, Darier's disease, ATP2A2 gene*

Introduction

Dyskeratosis follicularis (Darier's Disease, DD, MIM#124200) is a genetic skin disorder characterized by the loss of ad-

hesion between epidermal cells (acantholysis) and abnormal keratinization¹. Its prevalence has been estimated at 1.8/

100,000 inhabitants from Central England, 2.8/100,000 from Northeast England, 1/100,000 from Denmark, 2.2/100,000 from Slovenia and 1.3/100,000 from our country Croatia².

Dyskeratosis follicularis is caused by mutation in the ATP2A2 gene at 12q23-q24.1^{3,4}. This gene (GenBank accession nos M23115 and M23114) encodes the sarco/endoplasmic reticulum calcium-pumping ATPase (SERCA2), which is highly expressed in keratinocytes. The magnesium dependent enzyme catalyzes the hydrolysis of ATP coupled with the transport of the calcium⁵. It transports calcium ions from the cytosol into the sarcoplasmic/endoplasmic reticulum and has a central role in intracellular calcium signaling⁴.

The gene encodes for two isoforms generated by alternative splicing: class 1/ATP2A2a and class 2/ATP2A2b that differ in their carboxy termini and have distinct tissue-expression patterns⁶. The

first is located primarily in heart and slow-twitch skeletal muscle, whereas SERCA2b is present in smooth muscle and nonmuscle tissues. In adult skin sections only the longer isoform, SERCA2b is detected⁷. Extended mutation analysis in European Darier's disease patients using SSCP and/or direct sequencing identified 40 different patient specific mutations in 47 families^{4,8}. The majority (23 of 40) was likely to result in nonsense-mediated RNA decay. The remaining 17 were missense mutations distributed throughout the protein and were associated significantly with atypical clinical features. The clearest association was with the familial hemorrhagic variant, where all 4 families tested had a missense mutation. Three of the families (1 Scottish and 2 unrelated Italian families) exhibited the same asn767-to-ser substitution in the M5 transmembrane domain and a fourth family, from Sweden, had a cys268-to-phe substitution in the M3 transmembrane domain^{7,9} (Figure 1). Additional muta-

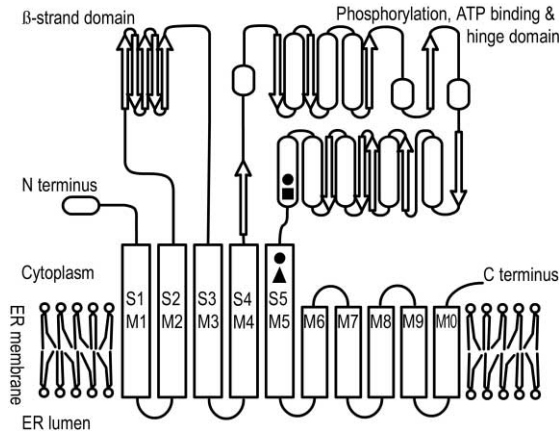


Fig. 1. Location of mutations in the human ATP2A2 polypeptide associated with hemorrhagic variant of Darier's disease (encoded in exon 15). The predicted secondary structure includes three cytoplasmic domains separated by a stalk sector from the transmembrane part of the molecule. The cytoplasmic domains contain a beta-strand, a phosphorylation domain and an ATP-binding domain. ATP binding domain is linked to the transmembrane region which includes 10 transmembrane coiled-coil helices, of which four contain Ca²⁺ binding sites. The mutations are represented by circles (missense), a triangle (deletion) and a square (frameshift and nonsense).

tions were found in two Chinese families¹⁰, but were not associated with specific clinical feature.

Clinically, dyskeratosis follicularis, manifests with keratotic papules and histologically by dyskeratosis¹¹. The disease begins very slowly, usually between 8 and 15 years of age, as numerous follicular papules covered with gray-brown crusts¹². Confluent papules enlarge and develop into verrucous or vegetating plaques. The papules are located on the seborrheic areas, flexural surfaces and sun-exposed areas of the skin. Nail changes are also an important sign¹³. The penetrance of the disease is complete in adults although expressivity is variable. Neuropsychiatric features, including mental retardation (in 10% of patients), schizophrenia, bipolar disorder, and epilepsy, have also been reported⁸. Stress, UV exposure, heat, sweat, friction and oral contraceptives may exacerbate disease symptoms¹.

Electron microscopy reveals that the essential abnormality is a defect in the synthesis and organization of the tonofilament-desmosome complex (attachment plaque), as well as perinuclear aggregation of keratin filaments and cytoplasmic vacuolization⁴.

It has been shown that the most consistent familial variant of Darier's disease, the one with acral hemorrhagic lesions⁷, is associated with mutations in exon 15 of the ATP2A2 gene. For this reason we decided to investigate exon 15 of the ATP2A2 gene in a Croatian family in which one member had a severe case of Darier's disease. We were curious to investigate genetic background of this extremely severe case of DD and discover whether mutations in exon 15 are prerequisite for acral hemorrhagic clinical phenotype.

Material and Methods

Patients

The diagnosis was made by dermatologists based on clinical and histopathological findings. History and clinical findings were recorded in 4 family members including neuropsychiatric and cardiac disease. The following clinical parameters were assessed: age of onset, pattern of disease, exacerbating factors, responsiveness to treatment, susceptibility to infection and progression of the disease with age. The disease was classified as severe.

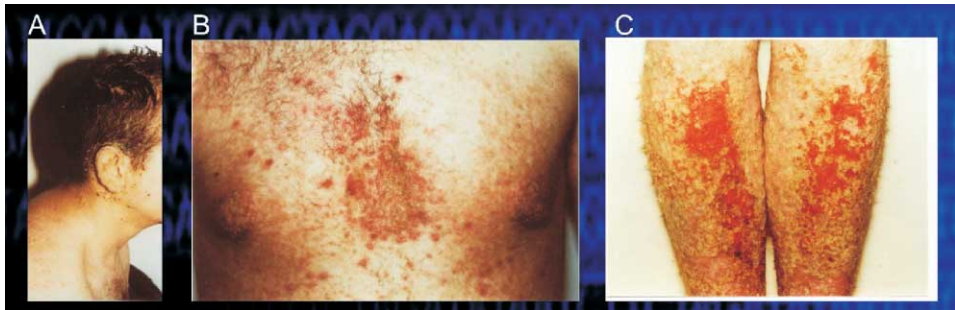


Fig. 2. Acral hemorrhagic type of Darier's disease. Patient with dyskeratosis follicularis before treatment. A. Crusting papules, simulating seborrhea, on the seborrheic areas of the face, forehead, ears and nasolabial furrows and on the scalp. B. Warty follicular papules widely distributed over the chest, on the seborrheic areas of the trunk. There are skin-colored, greasy, crusted papules, yellow-brown or brown. C. Punctate keratoses, haemorrhagic macules, papillomatous masses, vegetating, hypertrophic and warty masses with pyogenic infections on the lower extremities.

DNA extraction

We collected peripheral blood samples from 4 members of a Croatian family in which a proband had severe case of Darier's disease. We also obtained skin biopsy from the proband. Our study was approved by the local Ethics committee and all the family members gave informed consent. Genomic DNA was extracted from peripheral blood leukocytes using standard methods. Blood samples (5 ml) were lysed with 7 ml distilled water and centrifuged (15 min/5000 g). The pellet was then processed for DNA extraction using 1 ml extraction buffer (10 mM Tris HCl, pH 8.0; 0.1 M EDTA, pH 8.0; 0.5% sodium dodecyl sulfate) and incubated with proteinase K (final concentration 100 µg/ml; Sigma, USA; overnight at 37 °C). Phenol chloroform extraction and ethanol precipitation followed.

Polymerase chain reaction and sequencing

PCR amplification of exon 15 of the ATP2A2 gene was performed from genomic DNA. The optimal reaction mixture (50 µl) was: 0.4 µM of each primer (5'-TTT CCT CCT GCT TCC CAT TC-3' and 5'-GCA ATC TGG AGA GCA AAC TG-3'), 200 µM dNTP mix, 200ng DNA template, 0.1 U Taq polymerase (Perkin Elmer), 1 X PCR reaction buffer (50 mM KCl, 10 mM Tris HCl, pH 8.3, 1.5 mM MgCl₂). Amplification was carried out on a 9600 GeneAmp Thermal Cycler and the conditions were: initial denaturation, 4 min/95 °C; denaturation, 1 min/94 °C; annealing, 2 min/58 °C; extension, 1.5 min/72 °C; 35 cycles. All PCR products were run on 2% agarose gels.

The amplicons were purified with Concert Rapid PCR System (Gibco) to remove remaining amplification primers, dNTPs and buffer. Cycle sequencing was performed in a total volume of 20 µl using 8 µl ABI Prism Dye Terminator Cycle Sequencing Ready Reaction Kit with Am-

pliTaq FS Polymerase, 1 µl sequencing primer and 1–10 µl amplified DNA. The sequencing primers were the same as those used for PCR amplification. A perkin Elmer 9600 thermal cycler was used under the following conditions: 96 °C for 15 sec, 50 °C for 15 sec and 60 °C for 2 min for 25 cycles. The sequencing products were purified from residual terminators with CentriSep Spin Columns (Perkin Elmer) and dried in vacuum centrifuge. DNA was resolved in 5 µl loading buffer consisted of 4 µl deionized formamide and 1 µl EDTA. Samples were denatured on 95 °C for 3 min, quick chilled on ice and loaded on a denaturing polyacrylamide sequencing gel. Electrophoresis was run on an ABI 377 DNA Sequencer at 3 kV and 52 °C for 7 hours. Analysis was performed using ABI Prism Sequencing Analyser Software 2.1 and sequences were aligned and analyzed with Sequence Navigator Software.

Results

The proband in the investigated family was a 28 year-old male with histologically confirmed dyskeratosis follicularis. Skin lesions in the form of keratotic papules first appeared when he was 13 years old. He was treated with retinoids, topical keratolytic creams, ointments, and isotretinoin gel as an out patient at the Department of Dermatovenereology, Zagreb University Hospital Center during two years time period. The patient had personality problems, which resulted in antisocial behaviour.

At his second visit he had *Staphylococcal* sepsis with fever (41 °C), numerous keratotic papules and erosions of the skin involving the entire trunk and legs. The exacerbation of the disease started five days after an extreme sun exposure that resulted in sunburns. Besides high fever, the patient had numerous follicular keratotic red-brown papules on the clas-

sical sites (scalp, retroauricular regions, ears, sternal upper trunk, axillar and inguinal regions). Some lesions were confluent, with erosions and intertriginous madidations. He showed blisters on hands and feet including digits. The toenails were hyperkeratotic and yellowish (Figure 2).

Staphylococcus aureus was isolated in haemoculture and skin smears. Sepsis was confirmed with the standard laboratory tests. Based on all findings the disease was classified as acral hemorrhagic type, a rare variant of dyskeratosis follicularis¹⁴.

The recovery, with epithelisation of all erosions on the trunk, extremities and his neck and head, followed after 14 days of the treatment which included antibiotics parenterally (cloxacillin 4 × 3 g i.v. and amynoglicosides 2 × 120 mg i.v. in infusions)¹⁵, and systemically with retinoid (acitretin, 40 mg daily administered orally) and topically with antiseptics and keratolytics to promote epithelisation.

There were no symptoms of Darier's disease in the proband's family. The patient's sister suffered from cystic acneiform lesions for which she had been treated. In the mother's anamnesis heart problems were indicated but not specified. On the basis of family medical record we could not decide whether our case was sporadic or an inherited one.

Sequencing analysis of the exon 15 of the ATP2A2 gene did not reveal any mutation in the proband's genomic DNA, and none in the DNA from family members. Sequencing of the DNA from proband's skin also failed to identify any mutations. The sequence was also identical with 10 unrelated healthy Croatian control individuals indicating that there were no neutral polymorphisms among individuals investigated. Although mutations in exon 15 are reported to be the most consistent mutations associated

with the acral hemorrhagic type of Darier's disease, these mutations were not recorded in the family we investigated. Our results show that mutations in exon 15 of the ATP2A2 gene are not a necessary prerequisite for acral hemorrhagic type of Darier's disease.

The sequence data are shown in Figure 3.

Discussion

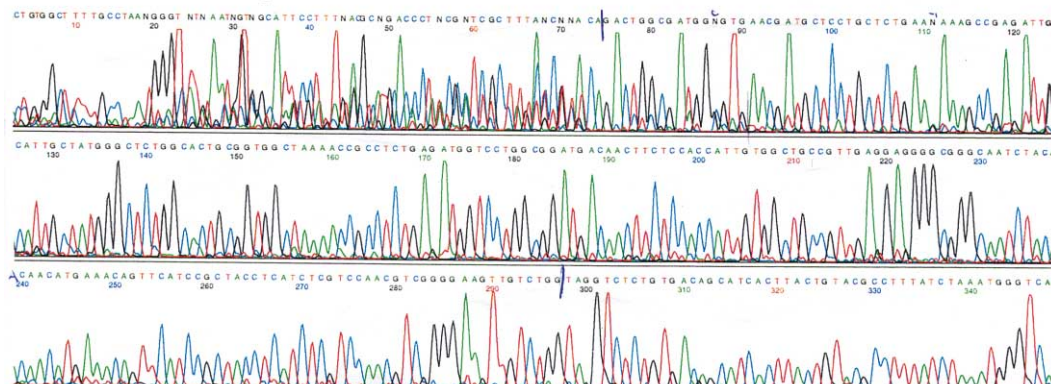
Genetic and molecular methods have identified the gene responsible for Darier's disease. Surprisingly, the culprit did not lye in keratin or desmosomal genes or other genes for molecules that mediate adhesion between keratinocytes, but rather in a gene that encodes a Ca²⁺ dependent pump, ATP2A2 gene^{5,12}. Mutations in ATP2A2 gene disrupt important domains of the molecule and are likely to result in complete or partial loss of function of the SERCA 2 mutated pumps. These findings support the proposition that haploinsufficiency (i.e. a normal phenotype requires more gene product than produced by a single copy of the gene), is a common mechanism for the dominant inheritance of DD. Haploinsufficiency results in impaired uptake of cytosolic calcium into the endoplasmic reticulum and consequent disruption of calcium signaling. In the epidermis the presumed result is loss of cellular adhesion, proliferation, impaired differentiation and disordered keratinization. All those calcium dependent processes are still inadequately explained at the cellular level and also in keratoses development and outcome. Pathological effects are produced under conditions of stress (UV exposure, as was the case with our patient), when calcium homeostasis is impaired. Compensatory molecular mechanisms contributing to extreme variability of the disease progression may exist in man.

```

                                gactggc gatggcgtga acgatgctcc
102901      tgctctgaag aaagccgaga ttggcattgc tatgggctct ggcactgcgg tggctaaaa
102961      cgcctctgag atggctctgg cggatgacaa cttctccacc attgtgctg cggttgagga
103021      ggggcgggca atctacaaca acatgaaca gttcatccgc tacctcatct cgccaacgt
103081      cggggaagt gtctgg
    
```

A

Forward sequence



Reverse sequence

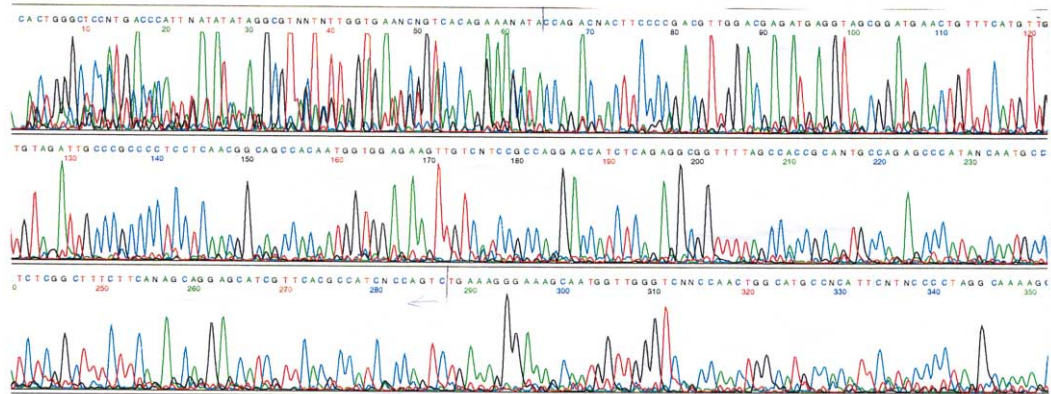


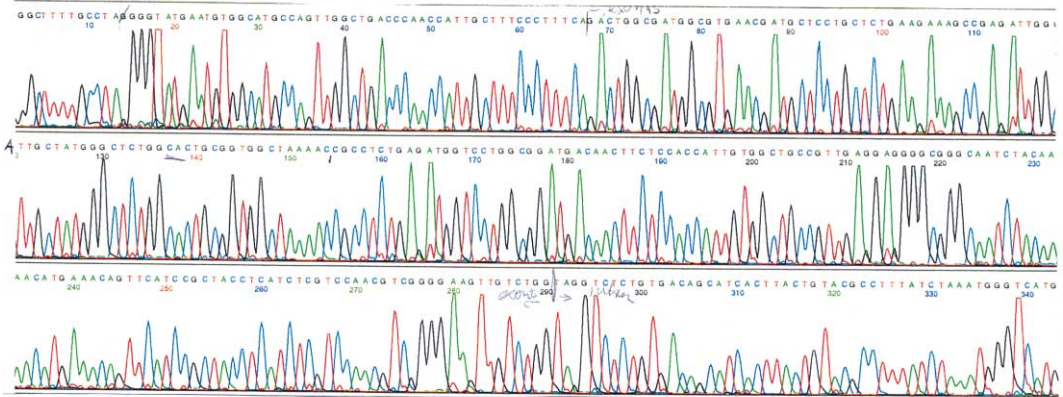
Fig. 3. Sequence of exon 15 ATP2A2 (SERCA2) gene retrieved from the Genome Database ([http:// www.gdb.org/](http://www.gdb.org/)). Sequencing data of proband's: A. skin biopsy.

It is known that some patients with dyskeratosis follicularis develop basal cell and squamous cell carcinomas¹⁶ and it is well known that sunlight can act as

tumor initiator and tumor promoter¹⁷ and that UV exposure exacerbates symptoms of Darier's disease. All the data presented support the link between sun, dis-

B

Forward sequence



Reverse sequence

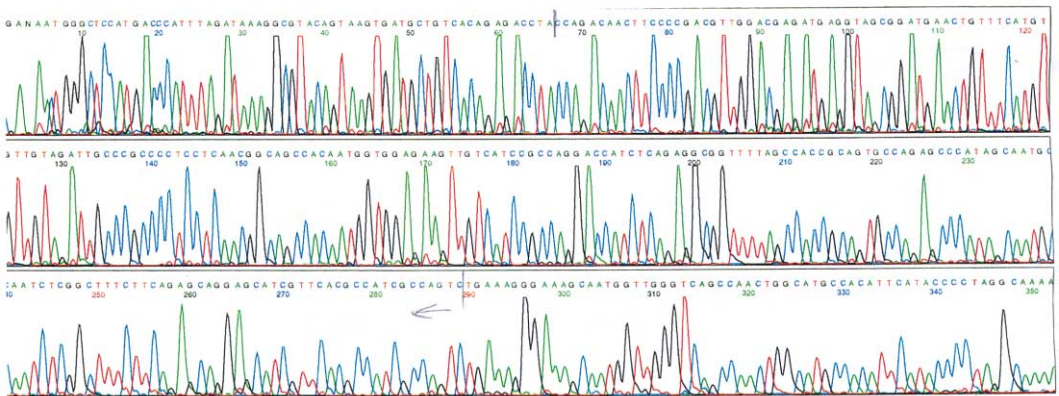


Fig. 3. Sequence of exon 15 *ATP2A2* (*SERCA2*) gene retrieved from the Genome Database (<http://www.gdb.org/>). Sequencing data of proband's: B. blood sample. Sequencing of the complementary strand confirms lack of mutation. The rest of the family's DNA sequences were identical with the ones shown.

ordered keratinocytes and skin cancer. It would be interesting to analyze Darier's disease in light of other molecular mechanisms of gene regulation, primarily promoter methylation and involvement of other modifying genes in clinical outcome of Darier's disease.

The cutaneous manifestations in DD vary considerably in severity even within families. In cases where unusual cutaneous manifestations are present, usually missense mutations were found. Nevertheless in two pedigrees investigated by Ruiz-Perez et al.⁷, no consistency of the

phenotype could be established. All the members affected had their own clinical features.

No clustering or hot spots of mutations in ATP2A2 gene have been observed⁴. It is also very interesting that the majority of reported mutations are family specific. Sakuntabhai et al.⁴ have found no mutation in two families with typical DD after direct sequencing of all the exons of ATP2A2 which is consistent with our report.

Lack of mutations observed in exon 15 of the ATP2A2 gene may obviously suggest that the subtle mutations could be confined to another region of the gene, but also that larger deletions removing whole exons could be involved. Another

explanation is the decrease in ATP2A2 protein expression via another molecular mechanism. We are aware that sequencing the whole coding region of the ATP2A2 gene is necessary for definitive answers and we leave it for future studies.

All these findings support the variability of clinical manifestations of Darier's disease and lack of genotype/phenotype consistency to which our finding also contributes.

Acknowledgement

This work was supported by grant 0108215 from Ministry of Science and Technology, Republic of Croatia.

REFERENCES

1. BRAUN-FALCO, O., G. PLEWIG, H. H. WOLFF, W. H. C. BURGDORF, Disorders of keratinization. In: BRAUN-FALCO, O., G. PLEWIG, H. H. WOLFF, W. H. C. BURGDORF (Eds.): *Dermatology*. (Springer, Berlin-Heidelberg-New York, 2001). — 2. MILJKOVIĆ, J., N. KECELJ, V. BALKOVEC, M. PENKO, A. KANSKY, *Acta Dermatoven. APA*, 9 (2000) 10. — 3. MONK, S., A. SAKUNTABHAI, S. A. CARTER, S. D. BRYCE, R. COX, L. HARRINGTON, E. LEVY, V. L. RUIZ-PEREZ, E. KATSANTONI, A. KODVAWALA, C. S. MUNRO, S. BURGE, M. LARREGUE, G. NAGY, J. REES, M. LATHROP, A. P. MONACO, T. STRACHAN, A. HOVNIANIAN, *Am. J. Hum. Genet.*, 62 (1998) 890. — 4. SAKUNTABHAI, A., V. RUIZ-PEREZ, S. CARTER, N. JACOBSEN, S. BURGE, S. MONK, M. SMITH, C. S. MUNRO, M. O'DONOVAN, N. CRADDOCK, R. KUCHERLAPATI, J. L. REES, M. OWEN, G. M. LATHROP, A. P. MONACO, T. STRACHAN, A. HOVNIANIAN, *Nat. Genet.*, 21 (1999) 271. — 5. BALE, S. J., J. R. TORO, *J. Cutan. Med. Surg.*, 4 (2000) 103. — 6. LYTTON, J., D. H. MACLENNAN, *J. Biol. Chem.*, 263 (1988) 15024. — 7. RUIZ-PEREZ, V. L., S. A. CARTER, E. HEALY, C. TODD, J. L. REES, P. M. STEIJLEN, A. J. CARMICHAEL, H. M. LEWIS, D. HOHL, L. ITIN, A. VAHLQUIST, T. GOBELLO, C. MAZZANTI, R. REGGAZINI, G. NAGY, C. S. MUNRO, T. STRACHAN, *Hum. Molec. Genet.*, 8 (1999) 1621. — 8. JACOBSEN, N. J., I. LYONS, B. HOOGENDOORN, S. BURGE, P. Y. KWOK, M. C. O'DONOVAN, N. CRADDOCK, M. J. OWEN, *Hum. Molec. Genet.*, 8 (1999) 1631. — 9. DAWSON, E., E. PARFITT, Q. ROBERTS, I. DANIELS, L. LIM, P. SHAM, M. NOTHEN, P. PROPPING, M. LANCZIK, W. MAIER, U. REUNER, J. WEISENBACH, M. GILL, J. POWELL, P. MCGUFFIN, M. OWEN, N. CRADDOCK, *Am. J. Med. Genet.*, 60 (1995) 94. — 10. YANG, Y., G. Q. LI, D. F. BU, X. J. ZHU, *J. Invest. Dermatol.*, 116 (2001) 482. — 11. KOWALEWSKI, C., W. MACKIEWICZ, D. SCHMITT, S. JABLONSKA, M. HAFTEK, *Arch. Dermatol. Res.*, 293 (2001) 1. — 12. GRIFFITHS, W. A. D., *Retinoids*, 15 (1999) 81. — 13. ZAIAS, N., A. B. ACKERMAN, *Arch. Dermatol.*, 107 (1973) 193. — 14. JORG, B., H. ERHARD, A. RUTTEN, *Hautarzt*, 51 (2000) 857. — 15. HO, V. C., R. M. A. CLOUTIER, W. A. D. GRIFFITHS, W. P. GULLIVER, G. J. LAUZON, D. MARCOUX, R. A. W. MILLER, E. H. MURRAY, G. D. SCHACTER, *Can. J. Dermatol.*, 7 (1995) 757. — 16. DOWNS, A. M., K. A. WARD, R. D. PEACHEY, *Clin. Exp. Dermatol.*, 22 (1997) 277. — 17. ZIEGLER, A., A. S. JONASON, D. J. LEFFELL, J. A. SIMON, H. W. SHARMA, J. KIMMELMAN, L. REMINGTON, T. JACKS, D. E. BRASH, *Nature*, 372 (1994) 773.

N. Pećina-Šlaus

Department of Biology, School of Medicine, University of Zagreb, Šalata 3,
10000 Zagreb, Croatia

**KLINIČKI SLUČAJ DYSKERATOSIS FOLLICULARIS (DARIEROVE
BOLESTI) HEMORAGIČNOG TIPA NIJE UZROKOVAN MUTACIJOM
EKSONA 15 GENA ATP2A2**

S A Ž E T A K

Dyskeratosis follicularis (Darierova bolest, DD) genetička je bolest karakterizirana patološkim promjenama keratinizacije, čija je posljedica različit klinički fenotip. Nedavno je otkriveno da *dyskeratosis follicularis* uzrokuju mutacije gena ATP2A2 na 12q24.1. Ovaj gen kodira proteinsku pumpu u sarko-endoplazmatskom retikulumu stanice, kalcijevu ATPazu tipa 2 (SERCA 2). Mutacije eksona 15 vezane su uz hemoragični tip Darierove bolesti. U našem radu istražen je ekson 15 ATP2A2 gena u obitelji iz Hrvatske čiji član ima hemoragični oblik DD. DNA izolirana iz biopsija kože, kao ni konstitutivna DNA iz krvi bolesnika nisu pokazale mutacije eksona 15/ATP2A2. Sekvenciranjem eksona 15 članova obitelji također nije nađena niti jedna mutacija. Ovi rezultati upućuju da mutacije eksona 15 nisu isključivi uzrok hemoragičnog oblika DD, te doprinose razumijevanju kliničkih manifestacija ove bolesti.