

Early Cancer in Congenital Choledochal Cyst

Ivan Kraus¹, Milivoj Rubinić¹, Miljenko Uravić², Dražen Kovač³,
Nada Brnčić⁴, Denis Kraus¹ and Božidar Vojniković⁵

¹ Department of Internal Medicine, University Hospital Center »Rijeka«, Rijeka, Croatia

² Department of Surgery, University Hospital Center »Rijeka«, Rijeka, Croatia

³ Department of Pathology, University Hospital Center »Rijeka«, Rijeka, Croatia

⁴ Department of Infectious Diseases, University Hospital Center »Rijeka«, Rijeka, Croatia

⁵ Department of Ophthalmology, University Hospital Center »Rijeka«, Rijeka, Croatia

ABSTRACT

We report a case of 35-yr-old woman with early cancer in congenital choledochal cyst. She had a five-year history of intermittent right upper abdominal pain and intermittent jaundice. In this period she had a few abdominal ultrasonographies, but the cholelithiasis had not been found. Now, she was admitted to our hospital because she felt right upper abdominal pain with slight jaundice and subfebrile temperature four weeks ago. Abdominal ultrasonography showed enormous dilatation of the common bile duct, which was suspected as choledochal cyst. Computed tomography and endoscopic retrograde cholangiopancreatography revealed cystic dilatation of extrahepatic bile duct. An anomalous pancreaticobiliary junction was not found. The patient with congenital choledochal cyst was operated on. The excision of choledochal cyst was done with hepaticojejunostomy Roux-en-Y. There were no lymph nodes metastases. On the central part of choledochal cysts mucosa, it was shown a white plain area of thickness 0.3 cm and 0.8 cm in diameter. Histologically it was well-differentiated tubular adenocarcinoma, which was limited to the mucosa and which did not penetrate to other parts of the bile duct wall. From our knowledge, only small number cases of early cholangiocarcinoma in choledochal cyst were until now reported. Nearly eight years after the operation the patient feels very well, and has optimal working ability (Karnofsky 100%).

Key words: congenital choledochal cyst, cholangiocarcinoma, case report

Introduction

The choledochal cyst is a rare development anomaly of the biliary tree occurring of one in 13,000 to 15,000 live births in Western countries¹. This is primarily a disease of children and young adults, but reported age range varies widely. Up to 1980, 1,375 cases of the impairment had been described, two third of them coming from Japan². So far in our country a number of congenital choledochal cysts have also been described^{3–7}. A well-recognized complication is carcinoma in the choledochal cyst^{8–10}. Although the choledochal cysts are a rare abnormality, it is important to be recognized because of its high association with carcinoma arising in the choledochal cyst wall epithelium. The incidence of carcinoma increases with age and is reported in 2.5% to 26% of cases¹⁰. Prognosis is usually very poor because of the extremely high malignant potential of biliary carcinoma¹¹. Preoperative diagnosis is rarely made. The relationship between the site of cancer, type of cyst and associated anomalies are unknown.

Patient and Methods

A 35-year-old female, presented with a five-year history of intermittent right upper abdominal colic and intermittent jaundice. In the past five years she had a few abdominal ultrasonographies, but the cholelithiasis had not been found. She was admitted to our hospital on January 22, 1996 because four weeks ago she felt right upper abdominal pain with slight jaundice and subfebrile temperature. Physical examination revealed slight pain under the right costal margin, but without any palpable mass. Routine hematological and biochemical laboratory investigations were unremarkable. Plain X-ray of the abdomen showed no pathological sign. Abdominal ultrasonography showed great dilatation of common bile duct (45 mm), which was suspected to choledochal

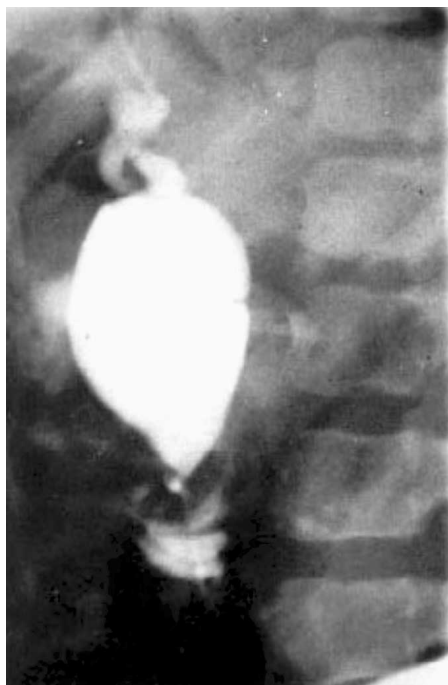


Fig. 1. ERCP revealing a choledochal cyst type Ia according to modified Todani classification.

cyst. Computed tomography also revealed a choledochal cyst. An endoscopic retrograde cholangiopancreatography revealed cystic dilatation of the extrahepatic bile duct (Figure 1). An anomalous junction of the pancreaticobiliary tract was not found. Upper digestive endoscopy showed no pathological findings. In accordance with modified Todani classification of congenital bile duct cysts, the biliary cyst was classified as type Ia. At laparotomy (January, 25, 1996) the gallbladder was found to be normal. A large choledochal cyst was found measuring approximately 8 cm in diameter. No palpable tumor of choledochal cyst was found and surrounding lymph nodes were not enlarged. On the central part of the cyst we found a little white plain tumor, under 10 mm in diameter. We assume that is malignant tu-

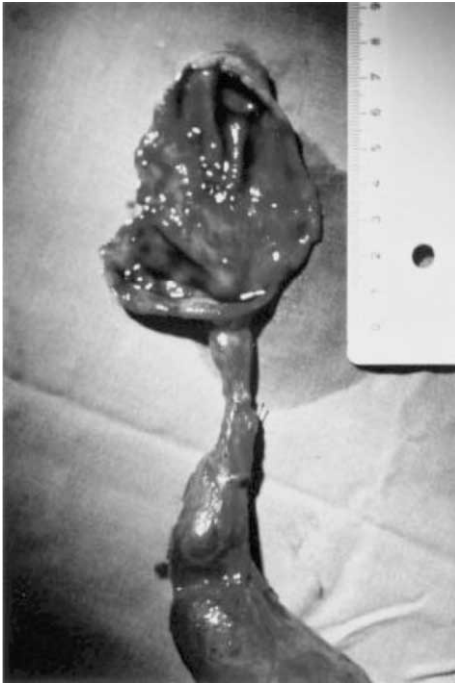

Fig. 2. Resected specimen of the choledochal cyst and gallbladder.

mor in cyst. Intraoperative histological examination of lymph nodes didn't found malignant infiltration. For this reasons we decided to make only an en-bloc resection of the choledochal cyst and gallbladder with hepaticojejunostomy Roux-en-Y. The gallbladder and excised choledochal cyst were sent for pathological examination (Figure 2). The patient was discharged from our hospital two weeks postoperatively without complications. On histological examination the gallbladder was 6×5 cm in size and gallbladder wall was 0.4 cm thick and without gallstones. The choledochal cyst was 8×5×4 cm in size and with few small gallstones. On the central part of choledochal cysts mucosa it was shown a white plain area of thickness 0.3 cm and 0.8 cm in diameter. The lesion was firm. Histological examination

revealed well-differentiated tubular adenocarcinoma, which was limited to the mucosa and which did not penetrate to other parts of the bile duct wall (Figure 3). In the resected bile duct it was observed epithelial hyperplasia accompanied by round cell infiltration and increased thickness of the wall with fibrosis. There were no lymph nodes metastases. We considered as a case of early cholangiocarcinoma in choledochal cyst. The patient is now nearly eight years in follow-up and feels very well, without any symptoms and with normal laboratory findings (Karnofsky 100%).

Discussion

Cholangiocarcinoma in choledochal cyst have been reported in many cases, whilst early cholangiocarcinoma in choledochal cyst is seen rarely^{8,9,12,13}. The most common histological type of cancer is adenocarcinoma, but it had been rarely reported also squamous carcinoma, anaplastic carcinoma and adenoacanthoma^{14–16}. The coincidence of choledochal cysts and neoplasia ranges from 2.5 to 26%¹⁰. The incidence of biliary tract carcinoma in patients with choledochal cysts is 5–35 times greater than that of general population. Cholangiocarcinoma in choledochal cyst appear oftens in female, with female to male ratio 2.5:1^{15,16}. Some authors suppose that this ratio is the result of higher gallstone incidence in females and possible hormonal factors such as estrogens and progesteron¹⁷. Otherwise, patients with choledochal cysts tend to develop cholangiocarcinoma twenty to thirty years earlier than patients with sporadic cholangiocarcinoma. It is well known that in more than 75% of patients with cholangiocarcinomas in choledochal cysts, the symptoms first appear in adulthood. Choledochal cysts are prone to complications: cholangitis, biliary cirrhosis, portal hypertension, cholelithiasis, spontaneous

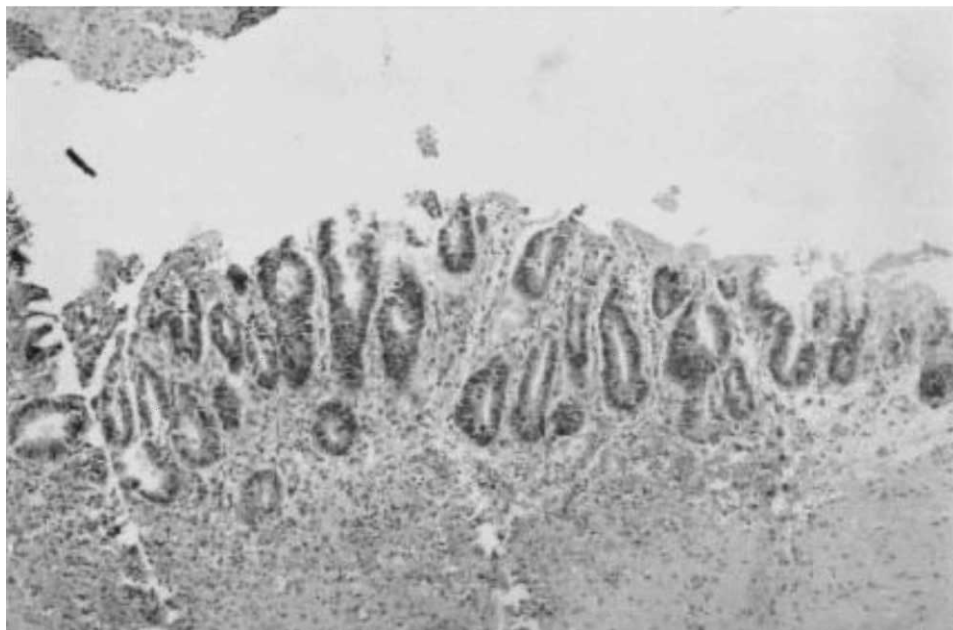


Fig. 3. Histological picture of early cholangiocarcinoma in the choledochal cyst.

rupture, liver abscess, pancreatitis and biliary carcinoma¹⁰. Factors possibly accounting for the development of cholangiocarcinomas in patients with choledochal cyst include: reflux of pancreatic juice as a result of anomalous arrangements of the pancreaticobiliary duct system, bile stasis, chronic inflammation, bacterial infection within choledochal cyst, stone within choledochal cyst, elevation of lysolecithin and trypsin concentration in the bile in patients with anomalous pancreaticobiliary ductal junction (APBDJ), secondary bile acids, protein kinase C isoform activation, possible mutations of the c-Ki-ras gene at codon 12 in the DNA of biliary epithelium, mutations of the p53 suppressor gene etc.^{18–23}. Many authors suppose that the most responsible factor for carcinogenesis of choledochal cyst is the longstanding inflammation of the biliary tree in patients with anomalous pancreaticobiliary ductal jun-

ction (APBDJ). The choledochus and pancreatic duct ordinarily enter the duodenum either separately or via a common channel located in the duodenal wall. The usually maximal length of the common channel is approximately 0.5 cm. An anomalous junction of the pancreaticobiliary tract is defined by the present an unusually long common channel whose length is 1 cm or longer. Babbitt et al.^{24,25} was the first to suggest that the anomalous arrangement of the pancreaticobiliary ducts might be involved in the etiology of congenital choledochal cyst. Since then, many authors have reported this condition frequently associated with congenital choledochal cyst. Tokiwa et al.²⁶ suppose that in patients with APBDJ this inflammation of the biliary tract is probably caused by the pancreatic juice reflux into the biliary tree. In pancreaticobiliary maljunction pancreatic juice regurgitates and the mixture of bile and pancreatic

juice stagnates in the biliary tree. The pancreatic juice and stagnant bile then acts as an irritant factor to the biliary epithelium, leading to chronic inflammation and metaplasia. Many studies establish the increasing rate of epithelial metaplasia in the wall of choledochal cyst with advancing age, and suggest that the changes are a continuing process with malignancy one of the end results²⁷. The cause of regurgitation of pancreatic juice into the biliary system might be due to a high-pressure difference between sphincter of Oddi and the duodenum in addition to the lack of sphincter function at the abnormal junction of the pancreaticobiliary ductal system²⁸. Pandey and Shukla²⁹ suggest that secondary bile acids play an important role in biliary carcinogenesis. It is likely that stasis of bile within choledochal cysts contributes to bacterial overgrowth and generation of unconjugated secondary bile acids³⁰. Also it was experimentally shown that bile from congenital choledochal cyst could significantly promote the proliferation of human cholangiocarcinoma QBC939 cells compared with normal bile. This proliferative effect of bile from congenital choledochal cyst could be abolished by addition of cyclooxygenase-2 specific inhibitor celecoxib³¹. It is clear, that many factors play some role in biliary carcinogenesis. Some of them are entirely included in biliary carcinogenesis, but some are hypothetical. As we mentioned earlier, only a 14 cases of early cholangiocarcinoma in extrahepatic choledochal cyst were reported till 1998⁸. Of the 14 cases, only 3 survived for more than 5 years after radical operation^{12,13}. Yoshikane et al.⁸ reported an early cholangiocarcinoma in choledochal cyst in 33-year old Japanese woman. This was the case of multiple early cancers. One cholangiocarcinoma in choledochal cyst was correctly diagnosed before the operation, but authors also found a second tumor at operation, which was

not diagnosed before the operation. At pathology examination the first tumor showed adenocarcinoma limited to fibromuscular layer, and the second tumor limited to mucosa.

Kawamoto et al.⁹ reported a case of early cholangiocarcinoma localized in the intrahepatic duct which was associated with choledochal cyst including the intra- and extrahepatic duct (type IV A cyst). This case was in 23-year old Japanese woman, and also was diagnosed before the operation. Our case differs from previously described, because we didn't make the diagnosis of cholangiocarcinoma in choledochal cyst before the operation. The diagnosis of early cholangiocarcinoma in choledochal cyst was surprising for us. Our patient is alive nearly eight years after operation, and we don't know if any such patient previously described, is alive so long. This case is also rare because in our patient pancreaticobiliary malfunction was not found. An anomalous pancreaticobiliary ductal union has been reported in 90% of patients with cystic dilatation of the bile duct. It is obvious from our case, that another pathological factors play a role in development of cholangiocarcinoma in choledochal cysts.

Correct preoperative diagnosis of cholangiocarcinoma in choledochal cyst is often very difficult to establish. The diagnosis of this tumor includes: abdominal ultrasonography, radionuclide hepatobiliary scanning with HIDA (hydroxyiminodiacetic acid), intravenous cholangiotomography, percutaneous transhepatic cholangiography (PTC), abdominal computed tomography (CT), endoscopic retrograde cholangiopancreatography (ERCP), intraductal ultrasonography, cholangioscopy (baby scope) with cytological examination and MR cholangiography^{10,32,33}. It is obvious that the therapy of choice is surgery. The extent of surgical treatment must be based on the extent of the disease and intraoperative findings. If a cho-

langiocarcinoma is found intraoperatively in a choledochal cyst, an en-bloc resection with partial duodenopancreaticectomy and central liver resection, if necessary, should be performed⁸. The radical resection appears to be the only chance for cure. This type of operation shows a five-year survival rate of 10 to 30%. In our case we didn't make a radical operation, i.e. partial duodenopancreaticectomy, because the tumor was smaller than 10

mm and intraoperative pathohistological analysis of surrounding lymph nodes didn't show malignant infiltration. Nevertheless, we agree with other authors, that for cholangiocarcinoma in choledochal cyst the best method of operation is en-bloc radical resection with partial duodenopancreaticectomy and central liver resection, if necessary.

REFERENCES

1. YAMAGUCHI, M., Am. J. Surg., 140 (1980) 653. — 2. LIPSETT, P. A., J. L. CAMERON, J. HBP Surg., 3 (1996) 389. — 3. RUBINIĆ, M., N. IVANIŠ, M. PERŠIĆ, D. BANIĆ, Radiol. Jugosl., 24 (1990) 323. — 4. BAKRAN, I., S. KNEŽEVIĆ, Liječ. Vjesn., 91 (1969) 757. — 5. PERŠIĆ, M., A. LEKOVIĆ, Ž. FUČKAR, M. RUBINIĆ, Liječ. Vjesn., 110 (1988) 319. — 6. BAKULA, B., I. ZORIĆIĆ, T. KOLAK, Croat. J. Gastroenterol. Hepatol., 1 (1992) 45. — 7. HUIS, M., M. BALIJA, T. BOIĆ, M. ŠTULHOFER, Acta Med. Croat., 52 (1998) 171. — 8. YOSHIKANE, H., S. HASHIMOTO, H. HIDANO, A. SAKAKIBARA, T. AYAKAWA, S. MORI, Y. KOJIMA, J. Gastroenterol., 33 (1998) 454. — 9. KAWAMOTO, S., T. HIRAOKA, S. MARUTA, E. WATANABE, K. KANEMITSU, T. TSUJI, Hepatogastroenterology, 45 (1998) 428. — 10. FIEBER, S. S., F. C. NANCE, Am. Surg., 63 (1997) 982. — 11. JAN, Y. Y., H. M. CHEN, M. F. CHEN, Hepatogastroenterology, 47 (2000) 337. — 12. SAITO, H., T. MISHIMA, R. ISHIHARA, N. SUZUKI, K. TAKANO, J. Jpn. Soc. Clin. Surg., 50 (1989) 772. — 13. HASHIMURA, N., M. MATSUMOTO, H. SUZUKI, M. EGUCHI, K. YAMAMURA, S. HIRAI, K. NARUMI, S. KOBAYASHI, N. SASAKIBARA, Tan To Sui, 9 (1988) 857. — 14. TODANI, T., Y. WATANABE, M. NARUSUE, K. TABUCHI, K. OKAJIMA, Am. J. Surg., 134 (1977) 263. — 15. TODANI, T., K. TABUCHI, Y. WATANABE, T. KOBAYASHI, Cancer, 44 (1979) 1134. — 16. BLOUSTEIN, P. A., Am. J. Gastroenterol., 67 (1977) 40. — 17. HOLZINGER, F., H. U. BAER, M. SCHILLING, E. J. STAUFFER, M. W. BUCHLER, Z. Gastroenterol., 34 (1996) 382. — 18. KOMI, N., T. TAMURA, Y. MIYOSHI, M. HINO, S. YADA, H. KAWAHARA, Jpn. J. Surg., 15 (1985) 273. — 19. FUNABIKI, T., K. SUGIUE, T. MATSUBARA, H. AMANO, M. OCHIAI, Keio J. Med., 40 (1991) 118. — 20. KATO, T., K. MATSUDA, M. KAYABA, Keio J. Med., 38 (1989) 167. — 21. HOLZINGER, F., H. U. BAER, M. W. BUCHLER, Dig. Surg., 12 (1995) 208. — 22. SUGIYAMA, Y., H. KOBORI, K. HAKAMADA, D. SEITO, M. SASAKI, World J. Surg. 24 (2000) 17. — 23. BABBITT, D. P., Ann. Radiol., 12 (1969) 231. — 24. BABBITT, D. P., R. J. STARSHAK, A. R. CLEMETT, Am. J. Radiol., 119 (1973) 57. — 25. TOKIWA, K., S. ONO, N. IWAI, J. Hepatobiliary. Pancreat. Surg., 6 (1999) 213. — 26. KOMI, N., T. TAMURA, S. TSUGE, Y. MIYOSHI, H. UDAKA, H. TAKEHARA, J. Pediatr. Surg., 21 (1986) 430. — 27. IMAZU, M., N. IWAI, K. TUKIWA, T. SHIMOTAKE, O. KIMURA, S. ONO, Eur. J. Pediatr. Surg., 11 (2001) 24. — 28. PANDEY, M., V. K. SHUKLA, Eur. J. Cancer Prev., 9 (2000) 165. — 29. REVILLE, R. M., G. VAN STIEGMANN, G. T. EVERSON, Gastroenterology, 99 (1990) 525. — 30. WU, G. S., S. Q. ZOU, X. W. LUO, J. H. WU, Z. R. LIU, World J. Surg., 9 (2003) 184. — 31. MERKLE, E. M., K. NUSSLE, B. GLASBRENNER, R. TOMCZAK, G. PRECLIK, A. RIEBER, Z. Gastroenterol., 36 (1998) 215. — 32. AKKIZ, H., S. O. COLAKOGLU, Y. ERGUN, H. DEMIRYUREK, A. AKINOGLU, I. TUNCER, HBP Surg., 10 (1997) 211.

I. Kraus

Department of Internal Medicine, University Hospital Center »Rijeka«, Krešimirova 42, 51000 Rijeka, Croatia

RANI KARCINOM U KONGENITALNOJ CISTI HOLEDOKUSA

S A Ž E T A K

Opisujemo bolesnicu od 35 godina s ranim karcinomom u kongenitalnoj cisti hloedokusa. Premda su ciste hloedokusa rijetke abnormalnosti, vrlo važno ih je prepoznati, zbog mogućeg razvoja karcinoma u zidu ciste. Naša je bolesnica s kongenitalnom cistom hloedokusa operirana te je napravljena ekscizija ciste i hepatikojejunostomija po Rouxu. U centralnom dijelu ciste pronađena je mala, bijela izraslina debljine 0,3 cm i promjera 0,8 cm. Histološki je to bio dobro diferencirani tubularni adenokarcinom, koji je bio ograničen samo na sluznicu i nije prodro u dublje dijelove stijenke ciste. To je rani holangiokarcinom u cisti hloedokusa. Blizu osam godina nakon operacije bolesnica se osjeća dobro i ima normalnu radnu aktivnost (Karnofsky 100%).