

Seizure freedom with vagus nerve stimulation in neurofibromatosis type 1: A case report

Asja Hodzic^{*1}, Andreja Bujan Kovac², Andrej Desnica³, Biljana Dapic Ivancic², David Ozretic⁴, Goran Mrak³, Niko Njiric³, Jakob Nemir³, Sibila Nankovic², Vlatko Sulentic², Zeljka Petelin Gadze²

¹ Department of Internal Medicine, Tesanj General Hospital, Tesanj, Bosnia and Herzegovina

² Department of Neurology, University Hospital Centre Zagreb and School of Medicine, University of Zagreb, Referral Centre of the Ministry of Health of the Republic of Croatia for Epilepsy, Affiliated Partner of the ERN EpiCARE, Zagreb, Croatia

³ Department of Neurosurgery, University Hospital Centre Zagreb and School of Medicine, University of Zagreb, Affiliated Partner of EUROCAN, Zagreb, Croatia

⁴ Clinical Department for Diagnostic and Interventional Neuroradiology, University Hospital Centre Zagreb and School of Medicine, University of Zagreb, Zagreb, Croatia

OPEN ACCESS

Correspondence:

Asja Hodzic
hodzic.as@gmail.com

This article was submitted to RAD
CASA - Medical Sciences
as the original article

Conflict of Interest Statement:

The authors declare that the research was conducted in the absence of any commercial or financial relationships that could be construed as a potential conflict of interest.

Received: 28 April 2023

Accepted: 01 June 2023

Published: 26 June 2023

Citation:

Hodzic A, Bujan Kovac A, Desnica A, Dapic Ivancic B, Ozretic D, Mrak G, Njiric N, Nemir J, Nankovic S, Sulentic V, Petelin Gadze Z. Seizure freedom with vagus nerve stimulation in neurofibromatosis type 1: A case report 556=62-63 (2023): 86-90
DOI: 10.21857/y54jofvwem

Copyright (C) 2023 Hodzic A, Bujan Kovac A, Desnica A, Dapic Ivancic B, Ozretic D, Mrak G, Njiric N, Nemir J, Nankovic S, Sulentic V, Petelin Gadze Z. This is an open-access article distributed under the terms of the Creative Commons Attribution License (CC BY). The use, distribution or reproduction in other forums is permitted, provided the original author(s) and the copyright owner(s) are credited and that the original publication in this journal is cited, in accordance with accepted academic practice. No use, distribution or reproduction is permitted which does not comply with these terms.

ABSTRACT:

Epileptic seizures in neurofibromatosis type 1 (NF1) have been a subject of investigation of numerous studies, however, their etiology has not yet been elucidated. They are usually well controlled with antiseizure medications (ASMs), but in some pharmaco-resistant patients, vagus nerve stimulation (VNS) might present a complementary treatment modality. We present a 24-year-old male patient with NF1 who had temporal lobe seizures - focal autonomic seizures with impaired awareness and oroalimentary automatisms, as well as focal motor seizures with retained awareness, in addition to moderate intellectual disability. The most significant magnetic resonance (MRI) abnormalities included infiltrative changes of medulla oblongata, pons and cerebellum, as well as signal intensity changes with mild compression in the apex of the temporal lobes, insular cortex, putamen and medial part of the frontal lobe, all more prominent on the right, along with right mesial temporal sclerosis. Interictal electroencephalogram (EEG) showed two independent epileptic foci – one in the right frontocentrotemporal region and the other in the left centrotemporal region. Throughout the years, he had been treated with several ASMs in monotherapy or polytherapy without success in seizure control. *After an extensive preoperative evaluation, VNS implantation was performed and the patient has been seizure free for almost two years.* Although a palliative intervention, VNS could be a powerful tool in the treatment of these patients and even lead to seizure freedom. To the best of our knowledge, this is the first case report where seizure freedom was achieved in a patient with NF1 following VNS implantation.

KEYWORDS: Neurofibromatosis, Pharmaco-resistant epilepsy, Vagus nerve stimulation, Seizure freedom

SAŽETAK:

IZOSTANAK NAPADAJA UZ STIMULACIJU VAGUSNOG ŽIVCA U NEUROFIBROMATOZI TIP I: PRIKAZ SLUČAJA
Epileptički napadaji u neurofibromatozi tip 1 (NF1) bili su predmet istraživanja brojnih studija, međutim njihova etiologija još nije razjašnjena. Obično se dobro kontroliraju antiepileptičkim lijekovima (ASM), ali kod nekih farmakorezistentnih pacijenata, stimulacija vagusnog živca (VNS) može predstavljati komplementarni modalitet liječenja. Prikazujemo 24-godišnjeg pacijenta sa NF1

koji je imao epileptične napadaje temporalnog režnja - žarišne autonomne napadaje sa poremećajem svjesnosti i oroalimentarnim automatizmima, kao i žarišne motoričke napadaje sa očuvanom svjesnosti, uz umjerene intelektualne teškoće. Najznačajnije abnormalnosti nalaza magnetne rezonancije (MRI) uključivale su infiltrativne promjene u meduli oblongati, ponsu i cerebelumu, kao i promijenjeni intenzitet signala sa blagim kompresivnim učinkom u vršcima temporalnih režnjeva, inzularnom korteksu, putamenu i medijalnom dijelu frontalnog režnja, sve izraženije s desne strane, zajedno sa znakovima mezijalne temporalne skleroze s desne strane. Interiktalni elektroencefalogram (EEG) pokazao je dva nezavisna epileptična fokusa – jedan desno frontocentrotemporalno, a drugi lijevo centrotemporalno. Tokom godina, liječen je s nekoliko ASM u monoterapiji ili politerapiji bez uspjeha u kontroli napadaja. Nakon opsežne predoperativne obrade, urađena je implantacija VNS-a i pacijent je već skoro dvije godine bez napadaja. Iako predstavlja palijativnu intervenciju, VNS bi mogao biti moćno sredstvo u liječenju ovih pacijenata, te čak dovesti i do potpune kontrole napadaja. Koliko nam je poznato, ovo je prvi slučaj u kojem je opisan izostanak napadaja kod pacijenta sa NF1 nakon implantacije VNS-a.

KLJUČNE RIJEČI: Neurofibromatoza, farmakorezistentna epilepsija, stimulacija vagusnog živca, izostanak napadaja

INTRODUCTION

Neurofibromatosis type 1 (NF1) is an autosomal dominant disorder first described in 1882 by Frederick von Recklinghausen. Cardinal features of this disease include multiple café-au-lait macules, Lisch nodules (iris hamartomas), intertriginous freckling and neurofibromas. It is caused by a mutation of the neurofibromin 1 gene located on chromosome 17q11.2 which encodes neurofibromin, a tumor suppressor protein. Neurofibromatosis type 1 belongs to a broad group of neurocutaneous disorders together with neurofibromatosis type 2, tuberous sclerosis, Von Hippel-Lindau disease, Sturge-Weber syndrome and many others. It is the most common of them all with a prevalence of about 1/3000 (1). In addition to its typical features, a range of neurological manifestations may be present as well, such as brain tumors, cerebrovascular disease, learning disability, behavioural problems, attention deficit, headache and epilepsy. Unidentified bright objects present a distinctive radiological finding in the form of T2-hyperintensities on magnetic resonance imaging (MRI) of the brain, usually seen in the brainstem, cerebellum, thalamus and basal ganglia (2). Although previous studies estimated that epileptic seizures occurred in approximately 4-7% of the cases, recent data suggest that the prevalence of seizures goes up to 14% (3). They are usually well controlled with antiseizure medications (ASMs), however, in some drug resistant patients, vagus nerve stimulation (VNS) might present a complementary treatment modality.

CASE PRESENTATION

We present a 24-year-old male patient who was clinically diagnosed with NF1 at the age of two and had been having epileptic seizures ever since. Initially, the patient only had temporal lobe seizures - focal autonomic seizures (epigastric aura) with

impaired awareness and oroalimentary automatisms, lasting for a few minutes. One year prior to presenting to our institution, he developed focal motor seizures with retained awareness as well, usually affecting his left arm. Both types of seizures occurred three to four times a month, respectively and were followed by fatigue, nausea and postictal confusion. The patient was under medical care for his comorbidities: moderate intellectual disability, arterial hypertension and osteopenia. Family history was negative for epilepsy and neurofibromatosis. Physical and neurological examinations revealed decreased limb muscle strength, multiple café au lait spots and cutaneous neurofibromas. Throughout the years, he had been treated with several ASMs in monotherapy or polytherapy: carbamazepine (CBZ), methylphenobarbital (MPB), valproate (VPA), oxcarbazepine (OXC), levetiracetam (LEV), topiramate (TPM), lacosamide (LCM), without success in seizure control. We performed a comprehensive preoperative diagnostic evaluation. The most significant magnetic resonance (MRI) abnormalities included infiltrative changes of medulla oblongata, pons and cerebellum (Figure 1), as well as signal intensity changes with mild compression in the apex of the temporal lobes, insular cortex, putamen and medial part of the frontal lobe, all more prominent on the right, along with right mesial temporal sclerosis (Figure 2). The patient also underwent continuous video-EEG monitoring, however, due to his behavior disturbances the procedure could not last longer and his mother decided to end the procedure after less than 24 hours. During that time, no seizures were observed. Interictal electroencefalogram (EEG) showed two independent epileptic foci – one in the right frontocentrotemporal region and the other in the left centrotemporal region (Figure 3). Since the patient had been diagnosed with a pharmacoresistant form of multifocal epilepsy, the multidisciplinary team decided to per-

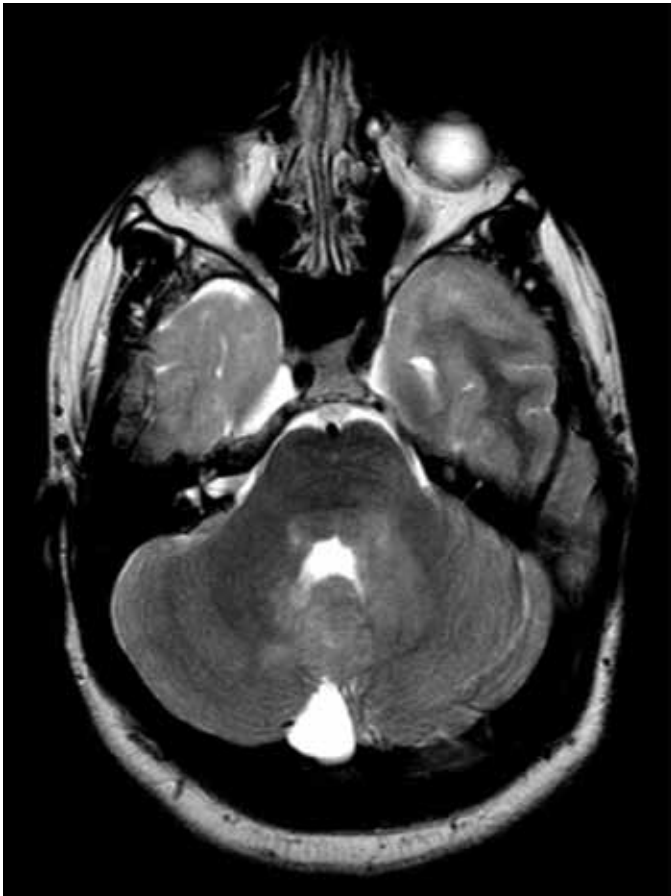

Figure 1. T2-weighted brain MRI: Axial view showing characteristic NF changes of cerebellum and brainstem.

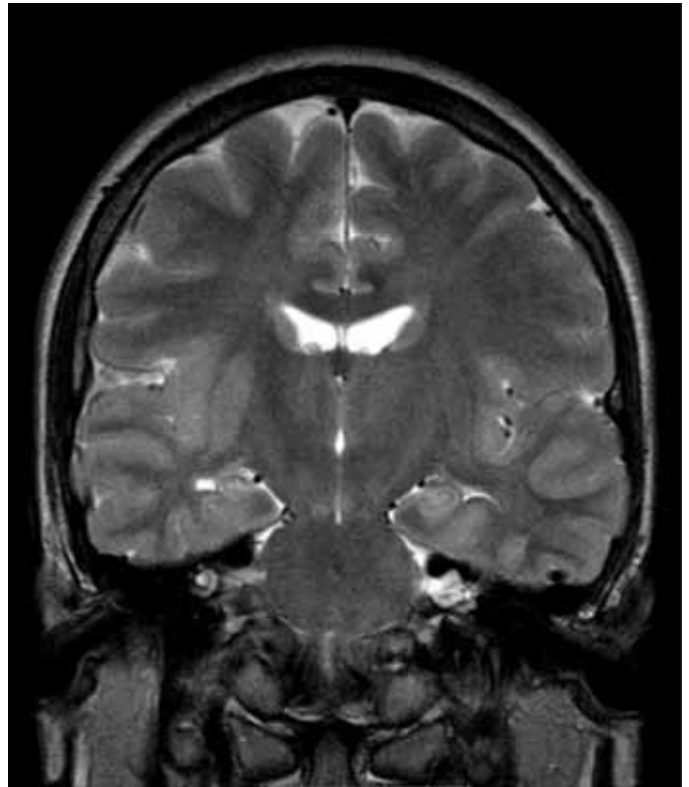


Figure 2. T2-weighted brain MRI: Coronal view showing right mesial temporal sclerosis.

form VNS implantation (LivaNova model 106), after a thorough cardiological assessment, in agreement with his parents. The postoperative course was uneventful and the patient recovered as anticipated. VNS was initiated on the fourth postoperative day at 0.25 mA and gradually increased in the following months. The patient continued taking ASMs: VPA (1500 mg), OXC (1200 mg), LCM (400 mg). Final stimulation parameters were: Output Current 2 mA, Signal Frequency 30 Hz, Pulse Width 500 μ s, 30 s Signal On Time, 5 min Signal Off Time, Duty Cycle 10%; Magnet Output Current 2.25 mA, Pulse Width 500 μ s, 60 s Signal On Time; AutoStim Output Current 2 mA, Pulse Width 500 μ s, 60 s Signal On Time, Seizure detection ON, Heartbeat Detection (Sensitivity) 2, 30% Threshold for AutoStim. In the following months, he did not report any side effects of the VNS. He became seizure free two years after the VNS implantation and a slight dose reduction of ASMs was made: VPA (1250 mg), OXC (900 mg), LCM (400 mg). The patient has been seizure free for almost two years.

DISCUSSION

Epileptic seizures in NF1 have been a subject of investigation of numerous studies, however, their etiology has not yet been elucidated. Approximately half of the cases of seizures in NF1 patients are structural, most frequently brain tumors, cortical and vascular malformations, whereas the role of unidentified bright objects in seizure pathogenesis has been precluded. The majority of seizures are focal in origin, which sometimes progress to bilateral tonic-clonic seizures. It is estimated that the prevalence of refractory epilepsy in patients with NF1 is 26%, compared to 30% in the general epileptic population (4). While there are several studies published in literature about the efficacy of VNS therapy in the treatment of refractory epilepsy in other neurocutaneous disorders, such as tuberous sclerosis (5, 6), scientific data about its use in NF1 are scarce. This is largely due to the fact that epilepsy, as well as drug resistant epilepsy, is less frequent in comparison to other most common neurocutaneous disorders: tuberous sclerosis and Sturge Weber syndrome (7). Moreover,

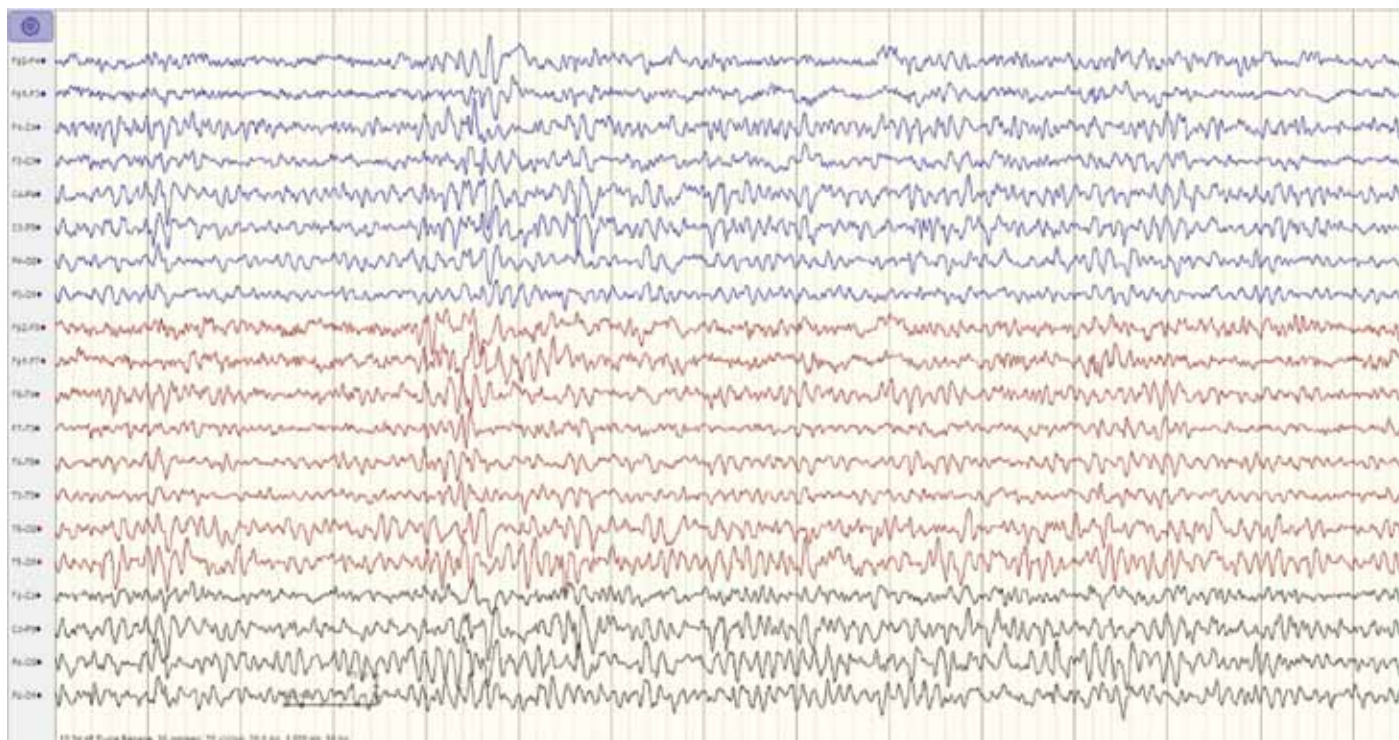


Figure 3. Interictal EEG showing slow sharp waves and spike – wave complexes right fronto – centro – temporal, mostly temporal, and slow sharp waves left centro – temporal with paroxysmal tendency of sharp waves.

an underlying pathology of the vagus nerve itself can be present as a consequence of the sole nature of the disease, for instance vagal neurofibromas, which presents a contraindication for VNS treatment. In our case, the patient had been treated with seven antiepileptic drugs with no adequate seizure control ever being achieved. Despite the fact that his MRI findings were stationary over the years, a change of semiology occurred and he developed an additional seizure type, which supports previous reports of poor electro-clinical and neuroradiological correlation between epilepsy and NF1 (8, 9). Since there was more than one epileptogenic focus, resective surgical approach was not a treatment option and VNS was the therapeutic modality that allowed the best possible seizure control for our patient. Although efficacy of adjunctive VNS therapy in refractory epilepsy has been well documented, only 8.0% of patients achieve seizure freedom (10), which is the case with our patient. Furthermore, it has been shown that VNS has a positive effect on depressive symptoms in patients with epilepsy (11) and that could provide a second-

ary benefit of its utility in neurofibromatosis, considering that depression is a frequent comorbidity in these patients (12).

CONCLUSION

Pharmacoresistant epilepsy in NF1 is a complex entity which requires a multidisciplinary approach. Our case demonstrated that VNS, although a palliative intervention, could be a powerful tool in the treatment of these patients and even lead to seizure freedom. To the best of our knowledge, this is the first case report where seizure freedom was achieved in a patient with NF1 following VNS implantation. We also want to emphasize the importance of documenting such cases and the need for carefully designed and well-conducted clinical studies to provide evidence of efficacy of VNS in this population.

ACKNOWLEDGMENTS

The authors acknowledge no conflicts of interest. The patient's consent was obtained. We did not receive any material support.

REFERENCES

1. Friedman JM. Epidemiology of neurofibromatosis type 1. *Am J Med Genet.* 1999 Mar 26;89(1):1-6.
2. Hsieh HY, Fung HC, Wang CJ, Chin SC, Wu T. Epileptic seizures in neurofibromatosis type 1 are related to intracranial tumors but not to neurofibromatosis bright objects. *Seizure.* 2011 Oct;20(8):606-11.
3. Sorrentino U, Bellonzi S, Mozzato C, Brasson V, Toldo I, Parrozzani R, Clementi M, Cassina M, Trevisson E. Epilepsy in NF1: Epidemiologic, Genetic, and Clinical Features. A Monocentric Retrospective Study in a Cohort of 784 Patients. *Cancers (Basel).* 2021 Dec 17;13(24):6336.
4. Bernardo P, Cinalli G, Santoro C. Epilepsy in NF1: a systematic review of the literature. *Childs Nerv Syst.* 2020 Oct;36(10):2333-2350.
5. Hajtovic S, LoPresti MA, Zhang L, Katlowitz KA, Kizek DJ, Lam S. The role of vagus nerve stimulation in genetic etiologies of drug-resistant epilepsy: a meta-analysis. *J Neurosurg Pediatr.* 2022 Mar 18:1-14.
6. Tong X, Wang X, Qin L, Zhou J, Guan Y, Teng P, Wang J, Yang Y, Li T, Luan G. Vagus nerve stimulation for drug-resistant epilepsy induced by tuberous sclerosis complex. *Epilepsy Behav.* 2022 Jan;126:108431.
7. Stafstrom CE, Staedtke V, Comi AM. Epilepsy Mechanisms in Neurocutaneous Disorders: Tuberous Sclerosis Complex, Neurofibromatosis Type 1, and Sturge-Weber Syndrome. *Front Neurol.* 2017 Mar 17;8:87.
8. Serdaroglu E, Konuskan B, Karli Oguz K, Gurler G, Yalnizoglu D, Anlar B. Epilepsy in neurofibromatosis type 1: Diffuse cerebral dysfunction? *Epilepsy Behav.* 2019 Sep;98(Pt A):6-9.
9. Shin A, Byun JC, Hwang SK, Kwon S, Lee YJ. Clinical Characteristics of Epilepsy and Its Risk Factors in Neurofibromatosis Type 1: A Single-Center Study. *Ann Child Neurol.* 2021;29(1):1-7.
10. Englot DJ, Rolston JD, Wright CW, Hassnain KH, Chang EF. Rates and Predictors of Seizure Freedom With Vagus Nerve Stimulation for Intractable Epilepsy. *Neurosurgery.* 2016 Sep;79(3):345-53.
11. Assenza G, Tombini M, Lanzone J, Ricci L, Di Lazzaro V, Casciato S et al. Antidepressant effect of vagal nerve stimulation in epilepsy patients: a systematic review. *Neurol Sci.* 2020 Nov;41(11):3075-3084.
12. Houpt AC, Schwartz SE, Coover RA. Assessing Psychiatric Comorbidity and Pharmacologic Treatment Patterns Among Patients With Neurofibromatosis Type 1. *Cureus.* 2021 Dec 7;13(12):e20244.

