



REFRACTORY GUILLAIN-BARRÉ SYNDROME IN A PATIENT WITH ASYMPTOMATIC MULTIPLE MYELOMA SUCCESSFULLY TREATED WITH LOW-DOSE RITUXIMAB

Ivan Krečak^{1,2} and Velka Gverić-Krečak¹

¹Department of Internal Medicine, General Hospital of Šibenik-Knin County, Šibenik, Croatia;

²Faculty of Medicine, University of Rijeka, Rijeka, Croatia

SUMMARY – Despite being extremely rare, Guillain-Barré syndrome (GBS) has been recognized as a neurological complication of multiple myeloma, with variable responses to plasmapheresis (PEX), intravenous immunoglobulins (IVIG), and anti-myeloma therapies. In this paper, we report a case of a female patient with asymptomatic multiple myeloma (aMM) who initially presented as PEX- and IVIG-refractory GBS. After failure of PEX, IVIG, and anti-myeloma therapy (bortezomib, melphalan, and prednisone), the patient was eventually successfully treated with low-dose rituximab (100 mg/m² per week in four doses). To the best of our knowledge, this is the first case to report successful treatment of refractory GBS potentially associated to aMM with low-dose rituximab. Additional studies are needed to elucidate the pathophysiological processes and the interplay between the dysregulated immune response, monoclonal immunoglobulin (MG), and neural tissue damage in GBS patients. Also, the potential role of rituximab in the treatment of MG-associated GBS warrants further exploration.

Key words: *Guillain-Barré syndrome; Rituximab; Monoclonal immunoglobulin; Multiple myeloma*

Introduction

Guillain-Barré syndrome (GBS) is an acute-onset, immune-mediated disorder of the peripheral nervous system, typically presenting with rapidly evolving ascending muscle weakness. Currently, plasmapheresis (PEX) and intravenous immunoglobulins (IVIG) are considered to be first-line treatments. However, persistent disability is seen in 20%-30% of patients, and treatment of refractory GBS still remains unsatisfactory¹. Despite being extremely rare, GBS has been recognized as a neurological complication of multiple myeloma, with variable responses to PEX, IVIG, and

anti-myeloma therapies²⁻⁵. Moreover, the term ‘monoclonal gammopathy of clinical significance (MGCS)’ has emerged recently as an increasingly recognized condition with diverse clinical presentations, where small plasma/B-cell clones can produce severe organ damage, mostly due to direct toxicity of monoclonal immunoglobulin (MG). Currently, recommendations for the treatment of MGCS rely mainly on plasma/B-cell clone-directed therapies^{6,7}. In this paper, we report a case of a female patient with asymptomatic multiple myeloma (aMM) who initially presented as PEX- and IVIG-refractory GBS, which we successfully treated with low-dose rituximab, after failure of conventional anti-myeloma therapy.

Case Report

An 85-year-old Caucasian female patient was urgently admitted to the Neurology Department due to ascending symmetrical lower limb weakness that lasted

Correspondence to: *Ivan Krečak, MD, PhD*, Department of Internal Medicine, General Hospital of Šibenik-Knin County, Stjepana Radića 83, HR-22000 Šibenik, Croatia
E-mail: krecak.ivan@gmail.com

Received December 24, 2019, accepted September 3, 2020

for four days. She was otherwise in a generally good clinical condition, afebrile, normotensive, and had no other complaints. There was no history of acute infections in the preceding two months. At admission, deep tendon reflexes on her lower limbs were absent, with distal sensory loss. Cerebrospinal fluid examination showed elevation in protein levels (1.2 g/L), with no pleocytosis (2 cells *per* μ L). Nerve conduction studies were consistent with demyelination. Anti-ganglioside antibodies were negative. Serological tests for viral hepatitis were negative, and indicated a prior infection with cytomegalovirus and Epstein-Barr virus (EBV). The diagnosis of GBS (acute inflammatory demyelinating polyneuropathy subtype)¹ was proposed and the patient was placed on therapeutic PEX (5x, 1.5 plasma volumes/day). Even though ascending muscle weakness stopped after PEX, the clinical response was still unsatisfactory; the patient was completely immobile with distal sensory loss. Then, IVIG were administered (0.4 g/kg *per* day for five consecutive days). Clinical response to IVIG was also transient and minimal; the patient was able to move her legs for three days, but very slowly and with extreme fatigue. During this time, diagnostic workup revealed that she had serum MG of the IgA kappa type (15 g/L), kappa/lambda ratio was 30, there was no anemia, renal insufficiency or hypercalcemia. Bone marrow examination revealed 25% of aberrant CD20-CD138+CD56+ plasma cells, and her karyotype was XX. No amyloid deposits were detected in bone marrow, or from the biopsies obtained from the rectum and subcutaneous fatty tissue, while echocardiography ruled out restrictive cardiomyopathy. Positron emission computed tomography revealed no compressive fractures, osteolyses, or extramedullary disease. The diagnosis of aMM was made. This condition needed no specific treatment *per se*^{8,9}, however, we were unable to differentiate whether this hematologic disorder might have been responsible for the neurological condition, so we decided to treat the patient with VMP protocol (bortezomib, melphalan and prednisone), an effective anti-myeloma chemotherapeutic in the elderly¹⁰, in parallel with physical therapy adjusted to her age. After three cycles, there was no clinical response; the patient was still immobile, with absent deep tendon reflexes on her lower limbs. VMP treatment was complicated with pneumonia and deep vein thrombosis of the leg, which we successfully treated with ceftriaxone and rivaroxaban, respectively. Hematologic reevaluation showed partial remission; there

were 10% of plasma cells in bone marrow and IgA was 7 g/L. Despite partial remission of aMM achieved with VMP, the patient's neurological deficit showed no clinical response, so we reconsidered the hypothesis that this relatively small plasma cell clone in bone marrow might be responsible for the current neurological condition. Then, we decided to treat the patient with rituximab (a chimeric human/murine anti-CD20 monoclonal antibody). Because of the advanced age, and due to a recent infectious complication, low-dose rituximab (100 mg *per* week in four doses) was administered; this dosage of rituximab was previously reported to be safe and effective for the treatment of other autoimmune disorders, i.e., immune thrombocytopenia¹¹. One week after the first dose of rituximab, the patient dramatically improved; she started to move her feet, and distal sensory loss disappeared. Then, additional three doses of low-dose rituximab were administered. Despite the advanced age, her neurological deficit gradually continued to improve. Three months after the start of rituximab, the patient was able to walk slowly with help from her husband, even though her lower limb weakness did not resolve completely. Twelve and eight months after the start of VMP and rituximab treatment, respectively, the patient's neurological deficit remained stable and did not progress, nor did aMM; bone marrow plasma cells and MG were in the range of 10%-15% and 7-12 g/L, respectively. Figure 1 summarizes patient management from the time of GBS diagnosis.

Ethics

The patient presented in this paper signed the informed consent form for the off-label use of rituximab and for this publication. General Hospital of Šibenik-Knin county does not require ethical approval for reporting individual cases or case series.

Discussion

Peripheral neuropathies are well-known complications of monoclonal gammopathies, and in the vast majority of patients, the MG is of the IgM type. Treatment with rituximab is usually considered in the case of refractory IgM neuropathies, while plasma/B-cell clone directed (immuno)chemotherapies are proposed treatments for symptomatic multiple myeloma or Waldenström macroglobulinemia³.

The role of rituximab in the treatment of refractory GBS has not been systematically explored, possibly

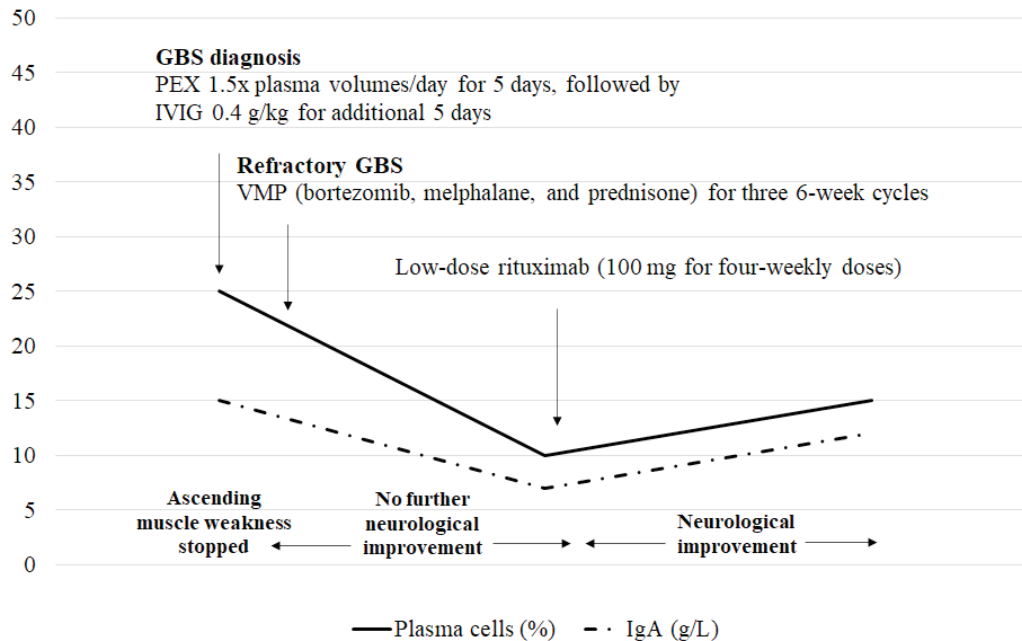


Fig. 1. Patient management from the time of the Guillain-Barré syndrome (GBS) diagnosis.

PEX = plasmapheresis; IVIG = immunoglobulins; IgA = immunoglobulin A

due to the fact that some authors report a potential causative association between the use of rituximab and GBS development¹²⁻¹⁴. To the best of our knowledge, this is the first case to report successful treatment of refractory GBS potentially associated to aMM with low-dose rituximab. We identified only one case report of GBS associated with EBV viremia after allogeneic bone marrow transplantation that demonstrated good clinical response to full-dose rituximab (375 mg/m² per week in four doses). In that case, dysregulated immune response in the context of EBV viremia and graft-versus-host disease could have been responsible for GBS development¹⁵. On the other hand, rituximab has been increasingly used in the treatment of PEX- and IVIG-refractory chronic inflammatory demyelinating polyneuropathy (CIDP), a disorder resembling GBS but with a slower onset (typically over several weeks), and with a relapsing pattern¹⁶. CIDP is also an immune disorder of the peripheral nerves which causes muscle weakness, and rituximab has been shown to be particularly effective in CIDP when associated with hematologic or autoimmune diseases¹⁷. Similarly, in our aMM patient with refractory GBS, the neurological deficit considerably improved after treatment with low-dose rituximab.

In recent years, MGCS has emerged as a newly recognized concept with diverse clinical presentations and plasma/B-cell clone-directed therapies, with peripheral neuropathy being one of the MG-related complications. However, the decision to treat the 'small clones' in the context of MGCS should consider the patient risk factors, organs involved, and the natural disease course^{6,7}. In our case, aMM needed no anti-myeloma treatment, in line with the current recommendations^{8,9}. Although we were initially unable to differentiate whether aMM might be associated with a potentially life-threatening neurological complication, it seemed prudent to treat the underlying hematologic disorder, especially because the usual treatment for this life-threatening neurological condition failed. However, in our elderly patient, the VMP chemotherapy treatment was complicated with significant toxicities, venous thrombosis and pneumonia. Furthermore, GBS proved to be refractory to anti-myeloma treatment. Conversely, rituximab showed a remarkable therapeutic effect in our patient, an observation indicating that immune dysregulation might have been the main cause of the neurological condition. In addition, most associations of neuropathy and MG have been found to be coincidental³. On the other hand, inflammatory cytokine imbalance has been shown to

frequently accompany multiple myeloma¹⁸. With this in mind, immunotherapies, such as rituximab, might have a safer toxicity profile for the treatment of MG-associated refractory GBS, especially in the elderly, for whom chemotherapy-induced toxicities are of major concern. However, additional studies are needed to elucidate the pathophysiological processes between the dysregulated immune response, MG, and neural tissue damage in GBS. These studies might also clarify whether rituximab could be an additional therapeutic option for the treatment of MG-associated refractory GBS.

In recent years, safe and effective immunotherapies against plasma-cell clones have been developed (i.e., daratumumab)¹⁹, and their use in this clinical context seems attractive and biologically plausible. However, prospective clinical trials are needed to elucidate whether targeting both the plasma cell-clones and the inflammatory microenvironment with these agents in the context of MG-associated neuropathies could be useful. Finally, clinicians should be aware that multidisciplinary approach to these patients is mandatory in order to avoid delays in diagnosis, optimize the treatments, and improve the quality of life.

References

- Meena AK, Khadilkar SV, Murthy JMK. Treatment guidelines for Guillain-Barré syndrome. *Ann Indian Acad Neurol*. 2011;14(Suppl 1):S73-S81. doi: 10.4103/0972-2327.83087.
- Iqbal AN, Le Q, Motiwala R, Clay LJ, Motiwala T, Lendvaiet N, *et al*. Guillain-Barré syndrome complicating multiple myeloma. *Blood*. 2008;112:5135. doi: 10.1182/blood.V112.11.5135.5135.
- Chaudhry HM, Mauermann ML, Rajkumar SV. Monoclonal gammopathy associated peripheral neuropathy: diagnosis and management. *Mayo Clin Proc*. 2017;92(5):838-50. doi: 10.1016/j.mayocp.2017.02.003.
- Dai X, Sun X, Ni H, Zhu X. Guillain Barré syndrome in a multiple myeloma patient after the first course of bortezomib therapy: a case report. *Oncol Lett*. 2015;10(5):3064-6. doi: 10.3892/ol.2015.3634.
- Mactier RA, Khanna R. Guillain-Barré syndrome in kappa light chain myeloma. *South Med J*. 1987;80(8):1054-5. doi: 10.1097/00007611-198708000-00029.
- Fernand JP, Bridoux F, Dispenzieri A, Jaccard A, Kyle RA, Leung N, *et al*. Monoclonal gammopathy of clinical significance: a novel concept with therapeutic implications. *Blood*. 2018;132(14):1478-85. doi: 10.1182/blood-2018-04-839480.
- Merlini G, Stone MJ. Dangerous small B-cell clones. *Blood*. 2006;15;108(8):2520-30. doi: 10.1182/blood-2006-03-001164.
- Kapoor P, Rajkumar SV. Smoldering multiple myeloma: to treat or not to treat. *Cancer J*. 2019;25(1):65-71. doi: 10.1097/PPO.0000000000000350.
- Rajkumar SV. Multiple myeloma: 2016 update on diagnosis, risk-stratification, and management. *Am J Hematol*. 2016;91(7):719-34. doi: 10.1002/ajh.24402.
- San Miguel JF, Schlag R, Khuageva NK, Dimopoulos MA, Shpilberg O, Kropff M, *et al*. Bortezomib plus melphalan and prednisone for initial treatment of multiple myeloma. *N Engl J Med*. 2008;359:906-17. doi: 10.1056/NEJMoa0801479.
- Li Y, Shi Y, He Z, Chen Q, Liu Z, Yu L, Wang C. The efficacy and safety of low-dose rituximab in immune thrombocytopenia: a systematic review and meta-analysis. *Platelets*. 2019;30(6):690-7. doi: 10.1080/09537104.2019.1624706.
- Terenghi F, Ardolino G, Nobile-Orazio E. Guillain-Barré syndrome after combined CHOP and rituximab therapy in non-Hodgkin lymphoma. *J Peripher Nerv Syst*. 2007;12(2):142-3. doi: 10.1111/j.1529-8027.2007.00134.x.
- Carmona A, Alonso JD, de las Heras M, Navarrete A. Guillain Barré syndrome in a patient with diffuse large cell lymphoma and rituximab maintenance therapy. An association beyond anecdotal evidence? *Clin Transl Oncol*. 2006;8(10):764-6. PMID: 17074678.
- Marino D, Farina P, Jirillo A, De Franchis G, Simonetto M, Aversa SM. Neurological syndrome after R-CHOP chemotherapy for a non-Hodgkin lymphoma: what is the diagnosis? *Int J Hematol*. 2011;94(5):461-2. doi: 10.1007/s12185-011-0942-4.
- Ostronoff F, Perales MA, Stubblefield MD, Hsu KC. Rituximab-responsive Guillain-Barré syndrome following allogeneic hematopoietic SCT. *Bone Marrow Transplant*. 2008;42(1):71-2. doi: 10.1038/bmt.2008.81.
- Roux T, Debs R, Maisonobe T, Lenglet T, Delorme C, Loupre C, *et al*. Rituximab in chronic inflammatory demyelinating polyradiculoneuropathy with associated diseases. *J Peripher Nerv Syst*. 2018;23(4):235-40. doi: 10.1111/jns.12287.
- Muley SA, Jacobsen B, Parry G, Usman U, Ortega E, Walk D, *et al*. Rituximab in refractory chronic inflammatory demyelinating polyneuropathy. *Muscle Nerve*. 2020 May;61(5):575-9. doi: 10.1002/mus.26804.
- Musolino C, Allegra A, Innao V, Gaetano Allegra A, Pioggia G, Gangemi S. Inflammatory and anti-inflammatory equilibrium, proliferative and antiproliferative balance: the role of cytokines in multiple myeloma. *Mediators Inflamm*. 2017;2017:1852517. doi: 10.1155/2017/1852517.
- Franssen LE, Mutis T, Lokhorst HM, van de Donk NWCJ. Immunotherapy in myeloma: how far have we come? *Ther Adv Hematol*. 2019;10:2040620718822660. doi: 10.1177/2040620718822660.

Sažetak

REFRAKTORNI GUILLAIN-BARRÉOV SINDROM U BOLESNIKA S ASIMPTOMATSKIM MULTIPLIM MIJELOMOM USPJEŠNO LIJEČENIM NISKOM DOZOM RITUKSIMABA

I. Krečak i V. Gverić-Krečak

Guillain-Barréov sindrom (GBS) iznimno rijetko komplicira multipli mijelom. Način liječenja ove neurološke komplikacije u kontekstu multiplog mijeloma nije definiran s obzirom na to da plazmafereza, intravenski imunoglobulini i (imuno)kemoterapije usmjereni na plazmastanični klon polučuju vrlo varijabilne kliničke odgovore. U ovom radu prikazujemo klinički tijek bolesnice s asimptomatskim multiplim mijelomom (aMM) koja se pri dijagnozi prezentirala kao refraktorni GBS. Nakon neuspješnog liječenja plazmaferezom, imunoglobulinima i kemoterapijom (bortezomib, melfalan i prednizon) bolesnicu smo uspješno liječili niskim dozama rituksimaba (100 mg/m^2 na tjedan u četiri doze). Koliko nam je poznato, ovo je prvi slučaj u kojem je refraktorni GBS potencijalno povezan s aMM uspješno liječen niskim dozama rituksimaba. Dodatne studije su potrebne kako bi razjasnile patofiziološke procese između monoklonskog imunoglobulina (MG) i oštećenja perifernog živčanog sustava u bolesnika s GBS. Također, uloga rituksimaba u liječenju bolesnika s GBS povezanim s MG zaslužuje dodatna istraživanja.

Ključne riječi: *Guillain-Barréov sindrom; Rituksimab; Monoklonski imunoglobulin; Multipli mijelom*