

Posterior sternoclavicular dislocation in a 15-year old boy: case report

Rok Kralj¹, Bruno Bumčič², Josip Pejić³, Igor Bumčič¹, Stjepan Višnjić¹, Rado Žic⁴

Posterior sternoclavicular joint dislocation is a very rare injury, representing less than 5% of all shoulder girdle injuries. While anterior dislocations may be treated non-operatively, posterior dislocations should either be reduced closed or open and fixed. In cases of concomitant injuries to the mediastinal structures, an open reduction is mandatory. We present a case of a 15-year old boy who presented with a posterior sternoclavicular joint dislocation without concomitant injuries in whom we have performed a chest X-ray but a computerised tomography was needed for a definitive diagnosis. An open reduction and cerclage with 3 non-absorbable sutures provided a stable fixation and the patient remained free of symptoms during the follow-up period.

Key words: STERNOCLAVICULAR JOINT; JOINT DISLOCATIONS; ADOLESCENT

INTRODUCTION

Sternoclavicular joint (SCJ) dislocation is a very rare injury, representing less than 5% all shoulder girdle injuries (1). SCJ dislocations can either be anterior or posterior disruptions. Posterior dislocations occur because of a rupture of the posterior capsule which normally provides greatest stability regarding posterior translation (2). Usually, posterior sternoclavicular joint (PSCJ) dislocations occur during athletic events, secondary to a significant indirect force to the posterolateral shoulder, forcing the lateral clavicle anteriorly and the medial clavicle posteriorly. PSCJ dislocations can cause an injury to the structures in close proximity, such as the trachea, the esophagus and neurovascular structures. These injuries if present, generally occur acutely, but may also be late presenting if the injury is untreated. (1)

A SCJ injury in the adolescent patient may consist of a true dislocation at the joint or a medial clavicular physeal fracture with displacement. PSCJ dislocation or medial clavicular physeal fracture in adolescents may be treated by closed reduction or open reduction and internal fixation (1, 3). Even though that closed reduction was deemed as the mainstay of treatment in the acute setting, successful outcomes are much rarer in delayed presentations (1).

CASE PRESENTATION

A 15 year old boy was admitted to our hospital after suffering a fall on his head and on the right shoulder during a bas-

ketball practice. A physical examination revealed pain during palpation of the medial end of the right clavicle. An X-ray taken on the day of injury has shown that the right clavicle is dislocated from the SCJ and positioned 15 mm more caudally than the clavicle on the left side (Figure 1). Even though it was not possible to discern on the basis of the X-ray whether the dislocation was posterior or anterior, the fact that there was no prominent mass in front of the sternum suggested that we were dealing with a posterior sternoclavicular dislocation or physeal fracture. In order to further distinguish if there were any concomitant injuries of the mediastinum present, a CT was performed which ruled out a vascular injury, lesions of the pulmonary parenchyma or pneumomediastinum (Figure 2). Ultrasound examination of the right subclavian vein has shown undisturbed flow without signs of thrombosis. After a consultation with a thoracic surgeon (P.J.), we have reached an indication for surgical treatment. Incision which extended from the medial part of

¹ Department of Pediatric Surgery, Children's Hospital Zagreb, Klaićeva 16, Zagreb

² School of Medicine, University of Osijek "Josip Juraj Strossmayer, Josipa Huttlera 4, Osijek

³ Department of Thoracic Surgery, Dubrava University Hospital, Avenija Gojka Šuška 6, Zagreb

⁴ Department of plastic, reconstructive and aesthetic surgery, Dubrava University Hospital, Avenija Gojka Šuška 6, Zagreb

Correspondence to:

Rok Kralj dr. med.; Children's Hospital Zagreb; Klaićeva 16, 10000 Zagreb; e-mail: Rok.Kralj@kdb.hr

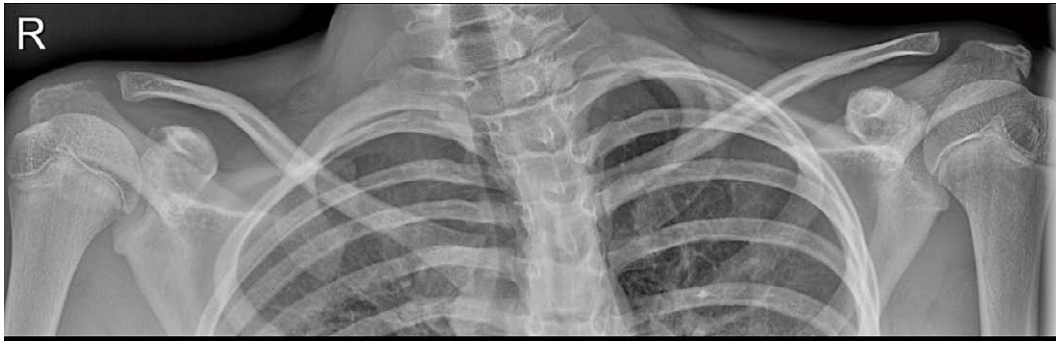

FIGURE 1. Radiographic examination reveals a sternoclavicular dislocation whereby it is difficult to determine the direction of dislocation.

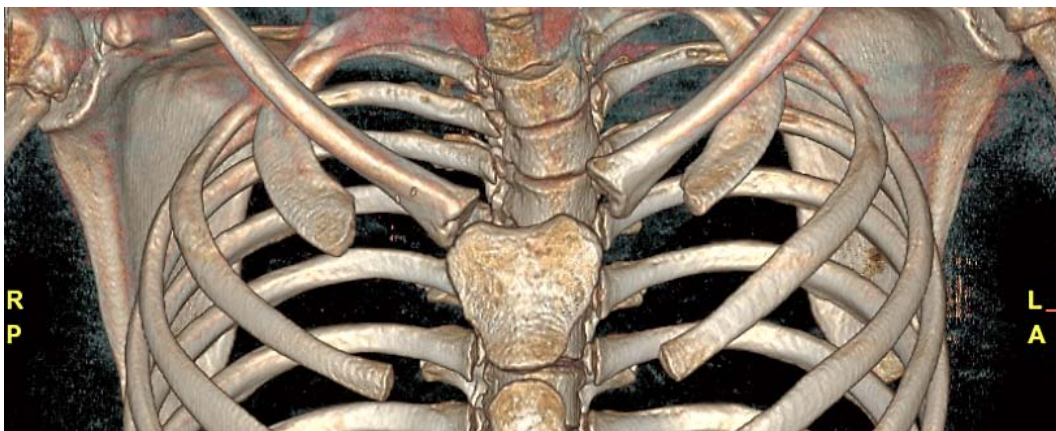


FIGURE 2. Computerised tomography enables better understanding of the direction of dislocation as well as to diagnose injuries of the mediastinal structures.

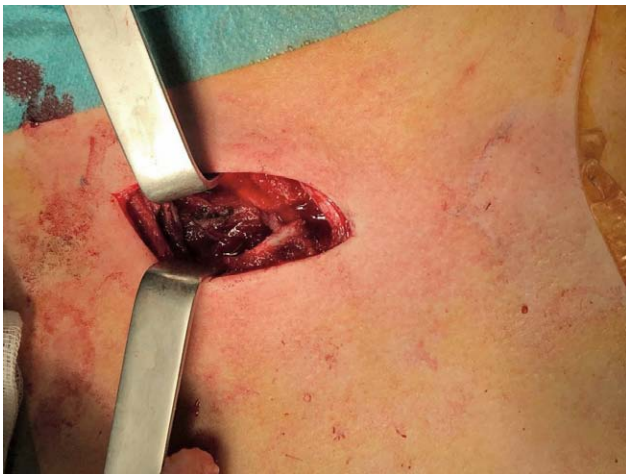

FIGURE 3. An incision from the medial part of the right clavicle to the medial part of the sternum enables a direct approach to the sternoclavicular joint.

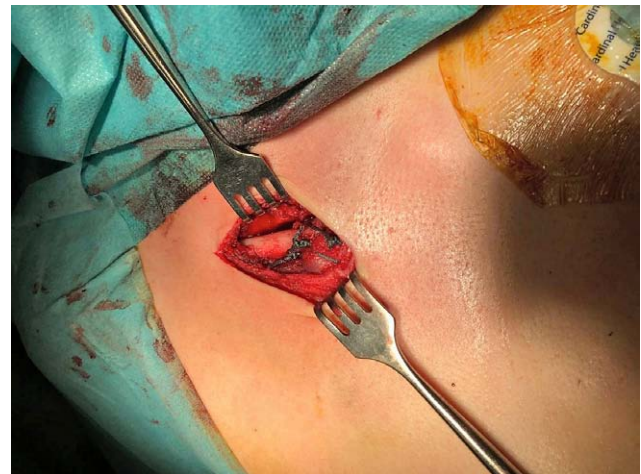


FIGURE 4. Osseous sutures (Ethibond 5) of the clavicle to the sternum and the anterior sternoclavicular joint have enabled a stable reduction.

the right clavicle to the medial part of the sternum has enabled a direct approach to the SCJ (Figure 3). Upon visualisation of the articular surface on the lateral edge of the sternal manubrium we have extracted the posteriorly displaced clavicle which was clearly dislocated, not fractured. Subsequently, we have drilled three 2.0 mm holes from the medial

end through the articular surface of the right clavicle and introduced three Ethibond 5 sutures which were driven through the periosteum of the sternum and sutured to the anterior SCJ, a procedure that enabled a stable reduction (Figure 4). The early postoperative course was uneventful and the patient was discharged on the 2 postoperative day.

The patient was provided with an orthosis for the shoulder and was instructed to have the shoulder immobilized for four weeks after surgery. Afterwards, physical therapy was started and the patient achieved a full painless range of motion 7 weeks after surgery. During a 6 months follow-up period, the patient did not experience any complaints. Follow-up with an ultrasound 8 weeks after surgery has shown that the reduction was maintained although a slight (7 mm) posterior displacement was still present.

DISCUSSION AND CONCLUSION

As previously stated, posterior clavicle dislocations are very rare and thus high degree of suspicion is warranted during workup for traumatic injuries of the medial end of the clavicle. The medial clavicular physis ossifies at approximately 21-24 years of age and accordingly, physeal fractures of the medial clavicle are more frequent in the pediatric population (4, 5). Even though, in the past, it was thought that the majority of these injuries are physeal fractures, experience gained from surgical treatment has shown that fractures and dislocations are equally represented (6). Sternoclavicular fracture dislocations are commonly caused by high-energy trauma and posterior fracture dislocations can result in life-threatening injuries (6). Typical presenting symptom is pain localized to the medial end of the clavicle (3) although patients may complain of shortness of breath, dyspnea, dysphagia, odynophagia, hoarseness, weakness or paresthasias in the ipsilateral arm if there is a concomitant brachial plexus injury. Clinical examination alone may not provide clues whether the clavicle is dislocated anteriorly or posteriorly due to edema that commonly occurs. In the case of a suspected posterior sternoclavicular dislocation, the emergency room staff should exclude the possibility of arterial (arterial insufficiency in the limb) or venous compression (congestion) (6). Initial diagnostic modality will always be plain radiographs but the interpretation of these can be a challenge because of the overlap of the clavicle, sternum, lungs, ribs and spine. Therefore, the modality of choice is computerised tomography which can help to evaluate the soft-tissue structures such as the esophagus, trachea, lungs and the brachiocephalic vessels. Atraumatic anterior dislocations should be treated conservatively (6). The remodeling potential of the medial clavicle and the stability that can be obtained qualify reduction as a possible therapeutic option. However, there is concern about the recurrent instability (4, 7, 8) and the fact that the procedure itself can result in mediastinal hemorrhage. Hence, *Schwartz et al.* believe that an open reduction is always a reasonable choice. In cases when concomitant injuries are present, open reduction is mandatory (6). The most widely utilised surgical technique is the fixation with non-absorbable sutures in a figure-of-eight pattern while tendinous allografts

are used in cases of chronic posterior symptomatic dislocations (6). While the majority of publications reveal that cerclage with non-absorbable suture is the most common therapeutic option in adolescent patients (1, 9) there are numerous alternatives for chronic dislocations such as - fixation with a Balser plate (10), ledge plates (11), K wires (12), suture anchors (13). In our case, we opted for a fixation with three intraosseous sutures which were driven through drill holes in the clavicle and through the periosteum of the sternum and the anterior SCJ capsule which resulted with a stable fixation. Literature reports have shown that, even though there is no standard therapeutic method, a good functional outcome can be expected with an open reduction, regardless of the technique used (1, 14, 15).

REFERENCES

1. Tepolt F, Carry PM, Heyn PC, Miller NH. Posterior Sternoclavicular Joint Injuries in the Adolescent Population: A Meta-analysis. *Am J Sports Med.* 2014;42:2517-24.
2. Spencer EE, Kuhn JE, Huston LJ, et al. Ligamentous restraints to anterior and posterior translation of the sternoclavicular joint. *J Shoulder Elbow Surg.* 2002;11:43-7.
3. Waters PM, Bae DS, Kadiyala RK. Short-term outcomes after surgical treatment of traumatic posterior sternoclavicular fracture-dislocations in children and adolescents. *J Pediatr Orthop.* 2003;23:464-9.
4. Bae DS. Traumatic sternoclavicular joint injuries. *J Pediatr Orthop.* 2010;30:63-8. doi:10.1097/BPO.0b013e3181c8766d 2.
5. Bae DS, Kocher MS, Waters PM, Micheli LM, Griffey M, Dichtel L. Chronic recurrent anterior sternoclavicular joint instability. Results of surgical management. *J Pediatr Orthop.* 2006;26:71-4. doi:10.1097/01.bpo.0000187998.91837.b2
6. Schwartz BS, Pency R, Eglseder A, Abzug JM. AC dislocations, SC dislocations and scapula fractures. In: Abzug JM, Kozin SH, Zlotolow DA, ed. *The Pediatric Upper Extremity.* New York, Heidelberg, Dordrecht, London, Springer 2015:1277.
7. Groh GI, Wirth MA. Management of traumatic sternoclavicular injuries. *J Am Acad Orthop Surg.* 2011;19:1-7.
8. Goldfarb CA, Bassett GS, Sullivan S, et al. Retrosternal displacement after physeal fracture of the medial clavicle in children treatment by open reduction and internal fixation. *J Bone Joint Surg Br.* 2001;83:1168-72.
9. Kraus R, Zwingmann J, Jablonski M, Bakir S. Dislocations of the acromioclavicular and sternoclavicular joint in children and adolescents: A retrospective clinical study and big data analysis of routine data. *PLOS ONE* 2020;15:e0244209.
10. Franck WM, Müller O, Henning F. Die traumatische sternoklavikuläre Instabilität. Eine therapeutische Alternative. *Der Unfallchirurg.* 2000;103:834-8.
11. Hecox SE, Wood GW. Ledge plating technique for unstable posterior sternoclavicular dislocation. *J Orthop Trauma.* 2010;24:255-7.
12. Ishii N, Matsumura N, Iwamoto T, Sato K, Nakamura M, Matsumoto M. Temporary sternoclavicular stabilization using innovative blocking technique with Kirschner wires for the treatment of posterior sternoclavicular injury in adolescent patients. *J Bone Joint Surg.* 2018;8:e:76.
13. Rutkowski SP, Grote S, Flatz W, Haasters, Böcker W, Ockert B. Akute dorsale Sternoklavikulargelenkluxation. *Unfallchirurg.* 2016;119:34652.
14. Kirby JC, Edwards E, Kamali Moaveni A. Management and functional outcome following sternoclavicular joint dislocation. *Injury.* 2015;46:1906-13.
15. Swarup I, Cazzulino A, Williams BA, Defrancesco C, Spiegel D, Shah AS. Outcomes after surgical fixation of posterior sternoclavicular physeal fractures and dislocations in children. *J Pediatr Orthop.* 2021;4:11-6.

SAŽETAK

Posteriorna sternoklavikularna dislokacija u 15-godišnjeg dječaka: prikaz slučaja

Rok Kralj, Bruno Bumči, Josip Pejić, Igor Bumči, Stjepan Višnjić, Rado Žić

Posteriorne dislokacije sternoklavikularnog zgloba su rijetke ozljede koje čine manje od 5% ozljeda ramenog obruča. Dok se anteriorne dislokacije mogu liječiti neoperativno, posteriorne dislokacije treba ili zatvoreno reponirati ili provesti otvorenu repoziciju i fiksaciju. U slučajevima pridruženih ozljeda medijastinalnih struktura, otvorena repozicija je obavezna. Mi prikazujemo slučaj 15-godišnjeg dječaka koji se prezentirao sa posteriornom dislokacijom sternoklavikularnog zgloba bez pridruženih ozljeda kod kojega smo napravili RTG toraksa ali je za definitivnu dijagnozu bila potrebna kompjuterizirana tomografija. Otvorena repozicija i serklaža sa 3 ne-resorptivna šava je omogućila stabilnu fiksaciju te je pacijent bio bez simptoma tijekom perioda praćenja.

Ključne riječi: STERNOKLAVIKULARNI ZGLOB; DISLOKACIJE ZGLOBOVA; ADOLESCENT