

Three-Dimensional Ultrasonography for the Evaluation of Atherosclerotic Stenoses of the Carotid Trunk

E. Tetičkovič¹, M. Gajšek-Marchetti², J. Matela³ and V. Flis⁴

¹ Department of Neurology, Maribor Teaching Hospital, Maribor, Slovenia

² Medical Research Department, Maribor Teaching Hospital, Maribor, Slovenia

³ Department of Radiology, Maribor Teaching Hospital, Maribor, Slovenia

⁴ Department of Vascular Surgery, Maribor Teaching Hospital, Maribor, Slovenia

ABSTRACT

Three-dimensional ultrasonography is a significant novelty in neurosonology as it offers the possibility of an even more successful evaluation of atherosclerotic stenoses of the carotid trunk than previous ultrasonographic investigations. In 37 patients with signs of transitory ischemic attack and in 5 patients with reversible ischemic neurologic deficit we compared the findings of three-dimensional ultrasonography of carotid arteries on the neck with those of three-dimensional CT angiography. In 20 of these patients in which carotid thrombendarterectomy had been carried out, the findings of both diagnostic methods were also compared with the angiographic and operative findings. In 2 out of the total of 42 compared findings of three-dimensional ultrasonography, three-dimensional CT angiography and angiography of the carotid trunk, we assessed a difference in the evaluation of the degree of carotid stenosis while all other findings were in accordance as regards the evaluation of the degree of stenosis and plaque analysis. Of 20 operative findings, one showed insignificant deviations from the findings of both diagnostic methods. It is our opinion that three-dimensional ultrasonography is a reliable diagnostic method in evaluating atherosclerotic stenoses of carotid arteries. Every subtotal stenosis or internal carotid artery occlusion established by three-dimensional ultrasonography must be compared with three-dimensional CT angiography or classic angiography due to the objective possibility of false ultrasonographic interpretation and the significance of carotid thrombendarterectomy.

Introduction

For many years great significance in discovering and evaluating carotid artery stenosis on the neck was attributed to angiography – an invasive method involving the risk of thromboembolic complications due to catheter manipulation. The rapid development of computer-aided ultrasonographic devices made it possible for noninvasive ultrasonography to win more and more recognition. Three-dimensional ultrasonography (3D US) of cerebral vessels is a significant novelty in the field of neurologic angiosonography¹. Three-dimensional reconstructive techniques were used already years ago in various imaging investigations, particularly in computerized tomography (CT) and magnetic resonance (MR). In the early 80s, the development of this technique began also in ultrasonography (US) which was at that time applied in the field of obstetrics and gynecology¹. Soon the three-dimensional technique appeared also in the field of internal medicine. In 1982 Geiser and coworkers² presented their dynamic three-dimensional reconstruction of the left ventricle of the human heart. Ten years later Franceschi, Bondi and Rubin (1992)³ were among the first to demonstrate the possibilities of three-dimensional vascular US. In recent years more and more authors⁴⁻⁸ report on the significance of 3D US in carotid diseases before and after carotid endarterectomy. The clinical applicability of 3D US of cerebral vessels is increasing.

Patients and Methods

Between June 1999 and November 2000, we performed 3D US and 3D CT angiography (3D CTA) of carotid arteries on the neck in 42 patients, 37 of which had experienced a transitory ischemic attack (TIA) and 5 a reversible ischemic neurologic deficit (RIND). Of these 42 pa-

tients, 29 were men and 13 were women. Their age was between 36 and 76 years, the median 61 years. In 20 patients (12 men and 8 women) carotid thrombendarterectomy (TEA) was carried out due to a hemodynamically significant stenosis (> 75%) of the internal carotid artery (ACI). In these 20 patients angiography was also done prior to surgery. Thus the findings of 3D US were compared with those of 3D CTA in 42 patients, in 20 operated patients also with the angiographic and operative findings. The degree of stenosis was classified according to the ECST (European Carotid Surgery Trialists' Collaborative Group 1991) method.

Local degree of stenosis (ECST method):

$$\frac{C - A}{C} 100\% \text{ stenosis,}$$

where:

A = residual diameter in the stenosis region,

C = original vessel diameter.

3D US was done with a VOLUSON 530 D – Kretz US device using a linear S-VNW 5-10 MHz probe (Figure 1). The probe is placed at the middle of the neck so that its tip is perpendicular to the m. sternocleidomastoideus. A transversal section of the carotid trunk is thus obtained. Moving the probe in the caudal and cra-



Fig. 1. The 3D ultrasonographic 5-10 MHz probe for carotid trunk imaging.

nial direction gives significant data regarding the position of the bifurcation, on blood flow direction, pathomorphologic changes in the intima, and above all on the patency at the ACI and ACE origin. Just before the bifurcation, the probe is rotated for 90° so that its tip is parallel to the carotid trunk. A slight tilting of the probe allows the selective presentation of the ACI and ACE.

Multislice spiral computed tomography (MSCT) and later 3D imaging of the investigated vascular segment were carried out with a TOSHIBA X-press/9X device.

The starting point for 3D US of carotid arteries is represented by a good B-scan while the volume scan can also be obtained by activating the Color Doppler (ANGIO-MODE).

The three-dimensional image of volume body actually develops in three basic phases:

1. Automatic volume scanning;
2. Multiplanar volume analysis;
3. 3D reconstruction (volume rendering)⁹.

Automatic volume scanning

The volume scan is obtained by sweeping the B-scan around its axis («fan scan»). The starting point is a US B-scan on which we choose the area of interest we wish to scan. The best B-scan of the carotid trunk in longitudinal section is always chosen. The position and size of the area of interest is determined by the VOL-BOX – the computer box whose size and position can be changed at will. The duration of scanning is 2-10 seconds, not depending on the chosen VOL-BOX size but rather on the movement of the object we wish to visualize. If artifacts are to be expected due to volume body (vessel) movement, a greater scanning speed is used. After the termination of scanning, the probe is turned off automatically and three images of the volume body (vessel)

appear on the screen. The volume scan can also be obtained by activating the Color Doppler. The region of the presented Color Doppler signal is at the same time also the starting point of volume scan acquisition. The further scanning procedure is quite the same as in standard volume scanning.

Multiplanar image analysis

After terminated volume scanning, a simultaneous presentation of three orthogonal planes of the volume body appears on the screen: the longitudinal, transversal and horizontal. The position of the volume body on the screen is determined by the relative coordinate system. It is represented by three axes in orthogonal position, their point of intersection being the triaxial center of rotation. These axes are shown as X, Y and Z coordinates. After volume scanning, the initial position of the volume body is obtained on the screen (Figure 2). By rotating the volume body around three orthogonal axes or by choosing the center of rotation around any of three axes, we can visualize any sector of the volume body. For this purpose we have six options independent of each other at our disposal: three rotations and three translations (rectilinear movement). It concerns the rotations around the X, Y and Z-axis or a parallel shift along the same axes.

3D reconstruction (volume rendering)

Volume reconstruction (volume rendering) is a computer processed three-dimensional presentation of volume body structures on a two-dimensional screen. As in volume scanning, in 3D rendering also we determine volume size and position with the computer box – RENDER-BOX. All structures outside this space are excluded from volume reconstruction. By simultaneous shifting of the RENDER-BOX through various depths of the scanned volume body in three orthogonal

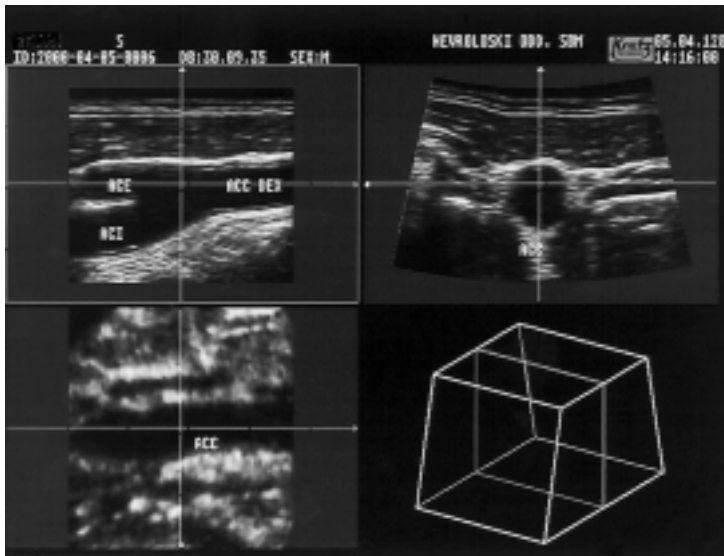


Fig. 2. Multiplanar analysis – initial position of volume body: simultaneous visualization of three orthogonal planes – longitudinal and transverse in upper two quadrants, the horizontal in the left lower quadrant.

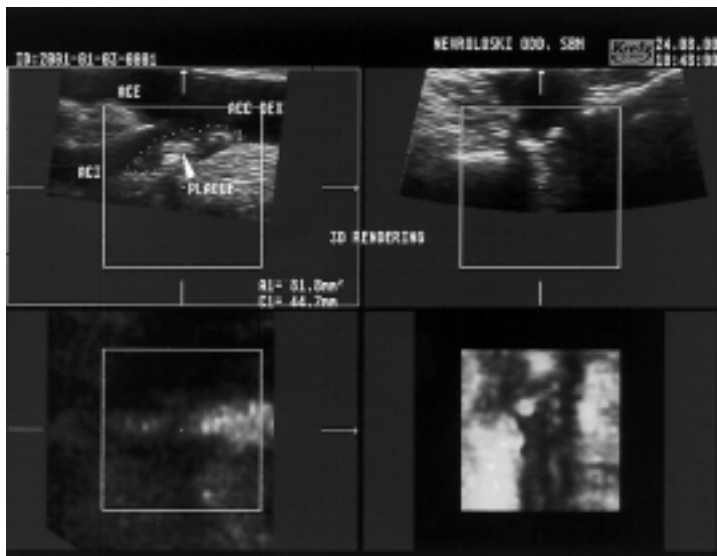


Fig. 3. 3D reconstruction (volume rendering) of hemodynamically significant stenosis of the right internal carotid artery (ACI): shift of RENDER – BOX through longitudinal imaging of the vessel in the left upper quadrant, transverse section in the right upper quadrant and horizontal section in the left lower quadrant. In the right lower quadrant, 3D image of the carotid trunk.

planes, we get a three-dimensional image of the volume body (Figure 3). For a more precise analysis, the image can be enlarged at will. To obtain the real 3D impression of the body shown, the CINE-MODE is applied. It concerns the rotation of the 3D-image set in a certain initial and final position of vertical rotation. During the rotation between these two initial positions, a series of consecutive 3D images follows, generating a real volume perception of the imaged volume body.

By means of the CUT 3D mode we can pick out the vessel or a certain section of it from the remaining visualized tissue (Figure 4). As a matter of routine, the complete process with all three described phases takes 30-50 minutes.

Results

All 3D US findings were compared with 3D CTA findings and in 20 patients with the results of classic angiography performed prior to carotid TEA. In 40 patients (95.2%) we established a complete accordance of 3D US findings with 3D CTA findings, in the evaluation of the degree of stenosis as well as in plaque analysis. There were 21 cases of hemodynamically significant (75-95%) ACI stenosis caused in 10 patients by calcinated plaques, in 8 by heterogeneous and in 3 by soft plaques. Subtotal stenosis was found in 9 patients, in 4 caused by calcinated plaques, in 3 by heterogeneous and in 2 by soft plaques. ACI occlusion was found in 4 patients, hemodynamically insignificant stenosis (< 75%) in 6 patients owing particularly to calcinated plaques. A significant difference in the findings was found in 2 cases (4.8%) before carotid TEA, in both an objective reason could be stated.

In 19 patients with carotid TEA we found operative findings fully identical with 3D US, 3D CTA and angiographic

findings (95%), an insignificant deviation was only found in one patient (Table 1).

Discussion

All over the world, several types of modern 3D US devices are in use, allowing an equally reliable diagnosis. 3D US holds an important place in the diagnosis

TABLE 1
CORRELATION OF 3D US FINDINGS WITH 3D CTA AND ANGIOGRAPHIC FINDINGS BEFORE CAROTID TEA

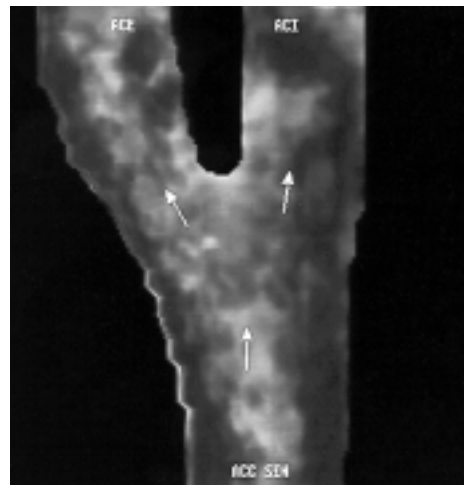
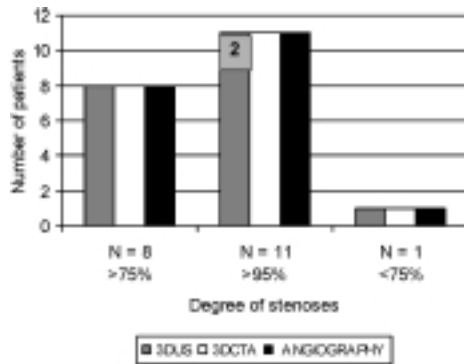


Fig. 4. CUT 3D – a possibility of selective presentation of the normal carotid trunk.

of atherosclerotic plaques in carotid vessels on the neck. They may cause a hemodynamically significant stenosis or they can be a potential cause of cerebral thromboembolism. Carotid disease is a frequent cause of TIA or reversible ischemic neurologic deficit (RIND), in 30% it is the cause of ischemic ICV¹⁰. Compared to the conventional 2D US, 3D US of carotid arteries allows a more precise analysis of atherosclerotic plaques: it reveals more data regarding the structure of plaque and its surface which, by enlargement of the 3D image in CINE-MODE, reveals even the smallest ulcerations in which the thrombotic process – the origin of cerebral embolism – may occur^{11,12}. Early discovery of very small initial atherosclerotic plaques, measurement of their size, area, volume and following of their movement imply – apart from intima thickness measurement – an objective monitoring of the atherosclerotic process^{13,14} (Figure 5). 3D US offers possibilities of clinical acquirement of even more relevant data on the correlation of biological age with early atherosclerotic changes as well as the correlation of arterial hypertension, hyperlipidemia, diabetes and other risk factors for ICV with the

progress of atherosclerotic changes in the intima of carotid arteries¹⁵. According to various authors, the specificity and sensitivity of 3D US are high: Bendick (1998)¹⁶ states a specificity of 87% and a sensitivity of 100%. Huston (1998)¹⁷ states the values of 91% and 96% respectively. Our assessed sensitivity of 95.2% does not deviate essentially from the values reported by other authors.

In our analysis of significant differences between 3D US, 3D CTA and angiographic findings, we established an objective reason in both cases. The first was a case of extremely high bifurcation due to which 3D US could only demonstrate the initial part of the ACI. In this part no residual ACI lumen could be seen, there was no Doppler signal or color coding of flow and the power mode revealed no minimum flow either. However, distally from the described site of occlusion, 3D CTA and angiography revealed a resumed blood flow which could not be displayed by 3D US. Consequently, it was a case of subtotal ACI stenosis (Figures 6 and 7). In the second case, an extensive acoustic shadow caused by calcinated plaque concealed the minimum patency of the ACI lumen, making it impossible for 3D US to detect the subtotal stenosis of the ACI.

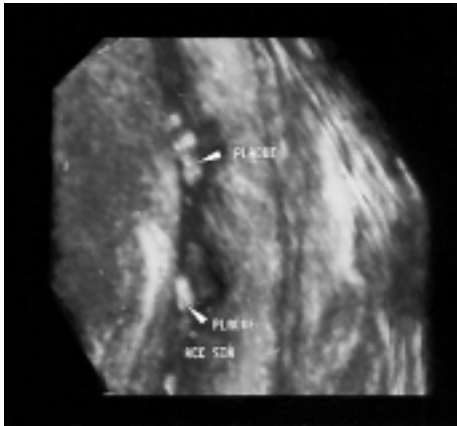


Fig. 5. Three-dimensional presentation of carotid trunk with multiple small calcinated plaques (CINE-MODE).

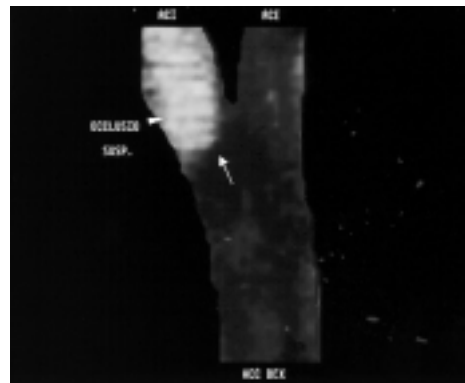


Fig. 6. Pseudoocclusion of the right ACI – CUT 3D.

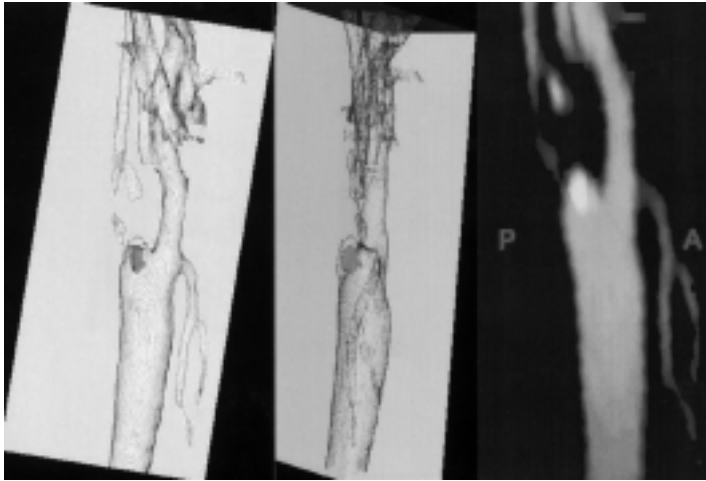


Fig. 7. Distally from the ACI pseudoocclusion, 3D CTA again shows the ACI lumen.

The 3D US study of carotid plaque morphology is important in evaluating their role in the risk of ICV occurrence¹⁸, but it is also important for setting the indications for carotid TEA¹⁹⁻²³.

In analyzing plaque morphology we consider the descriptive parameters stated by Bartels (1999)²⁴ as well as the classification of the degree of ACI stenosis according to Doppler-sonographic and morphologic criteria.

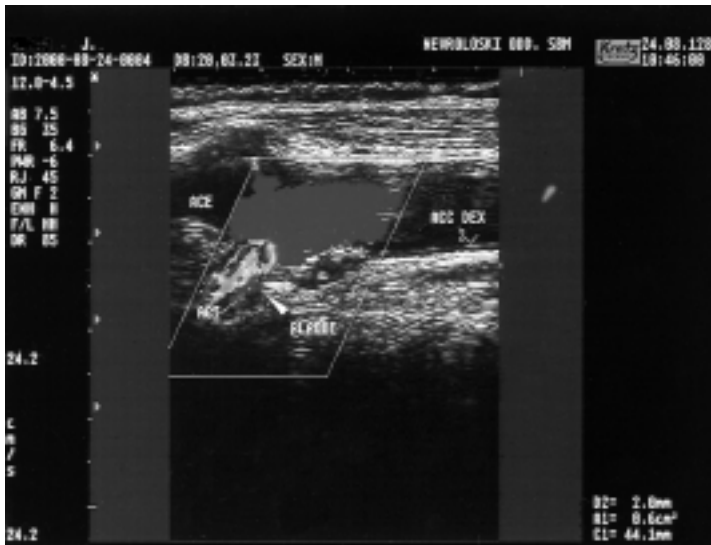


Fig. 8. A hemodynamically significant stenosis caused by fibrocalcified plaque at the origin of the right ACI: B-scan with color flow map (CFM).

We believe that preoperative 3D US and 3D CTA should be done in all patients in which carotid TEA is indicated, just as it should in suspected ACI occlusion due to a possible actual subtotal stenosis representing an indication for carotid TEA. Besides, Sameshima and coworkers (1999)²⁵ suggest 3D US or MR angiography (MRA) as initial screening diagnostic methods for assessing ACI stenosis, and 3D CTA for preoperative evaluation of the degree of stenosis and postoperative evaluation in carotid TEA (Figures 8-10). This implies the possibility of carotid TEA without previous invasive angiography, the risks of which are well known²⁶.

Conclusions

3D US of precerebral arteries is a significant novelty in discovering and evaluating atherosclerotic stenoses of the carotid trunk. It can be applied as a reliable screening method in the identification carotid stenoses. As a screening method, 3D CTA is certainly less accessible and more costly. At all events, 3D US should be complemented by 3D CTA in all unclear cases and in patients with indications for carotid TEA. Despite the good correlation of 3D CTA with angiography, most angiurgeons still demand classic angiography before carotid TEA. 3D CTA should also be done to confirm the diagnosis when a subtotal stenosis or occlusion of the ACI is identified by 3D US. Confirmation of the diagnosis is imperative as TEA is indicated in subtotal ACI stenosis while merely conservative therapy is indicated in ACI occlusion. Certainly, two-dimensional US is also a good screening method and, like in 3D US, should also be combined with 3D CTA or MRA in the same cases.

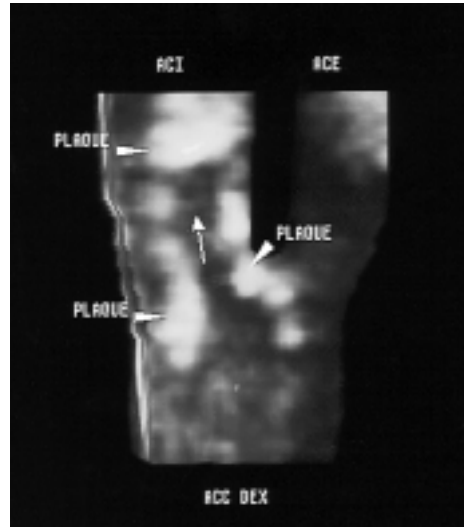


Fig. 9. The same stenosis of the ACI in CUT 3D image.

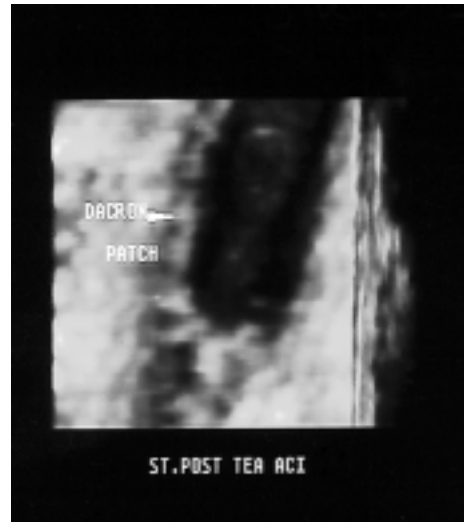


Fig. 10. The post-TEA status of the same ACI stenosis: in the anterior wall of the bifurcation, the dacron patch is clearly visible.

REFERENCES

1. RICCABONA, M., T. R. NELSON, D. H. PRETORIUS, *Ultraschall Klin. Prax.*, 10 (1995) 35. – 2. GEISER, E. A., M. ARIET, D. A. CONETTA, S. M. LUPKIEWICZ, L. G. CHRISTIE, *Am. Heart J.*, 103 (1982) 1056. – 3. FRANCESCHI, D., J. BONDI, J. R. RUBIN, *J. Vasc. Surg.*, 15 (1992) 800. – 4. ROSENFELD, K., P. BOFFETTI, J. KAUFMAN, R. WEINSTEIN, S. RAZVI, J. M. ISNER, *Am. J. Cardiol.*, 70 (1992) 379. – 5. RANKIN, R. N., A. FENSTER, D. B. DOWNEY, P. L. MUNK, M. F. LEVIN, A. D. VELLETT, A. J. R., 161 (1993) 695. – 6. HAMPER, U. M., V. TRAPANOTTO, S. SHETH, M. R. DEJONG, C. J. CASKEY, *Radiology*, 191 (1994) 397. – 7. DELCKER, A., H. POLZ, *Cerebrovasc. Dis.*, 3 Suppl. (1996) 2. – 8. GRIEWING, B., U. SCHMINKE, C. MORGENSTERN, M. L. WALKER, C. KESSLER, *J. Neuroimaging*, 7 (1997) 40. – 9. GRITZKY, A., H. BRANDL, The voluson (Kretz) technique. In: MERZ, E. (Ed.): 3D Ultrasound in obstetrics and gynecology. (Lippincot Williams & Wilkins, New York, 1998). – 10. SERENA, J., Carotid stenosis classification and measurement: plaque morphology. In: Neurosonology. (CEFNS, Seville, 1998). – 11. BLUTH, E., C. R. MERRITT, M. A. SULLIVAN, *J. Ultrasound Med.*, 1 (1988) 73. – 12. DELCKER, A., H. C. DIENER, *Br. J. Radiol.*, 67 (1994) 672. – 13. SALONEN, R., J. T. SALONEN, *Atherosclerosis*, 81 (1990) 33. – 14. PIGNOLI, T., E. TREMOLI, A. POLI, P. ORESTE, R. PAOLETTI, *Circulation*, 6 (1996) 1399. – 15. PALOMBO, C., M. KOKAZOVA, C. MORIZZO, F. ANDREUCCETTI, A. TONDINI, P. PALCHETTI, *Stroke*, 29 (1998) 1631. – 16. BENDICK, P. J., W. BROWN, D. HERNANDEZ, J. L. GLOWER, P. G. BOVE, *Am. J. Surg.*, 176 (1998) 183. – 17. HUSTON, J., D. A. NICHOLS, P. H. LUETMER, C. H. RYDBERG, B. D. LEWIS, F. B. MEYER, *Am. J. Neuro-radiol.*, 19 (1998) 309. – 18. GEROUKAKOS, G., R. W. HOBSON, A. NICOLAIDES, *Br. J. Surg.*, 5 Suppl. (1996) 582. – 19. HANSEN, F., D. BERQUIEST, B. LINDBLED, M. LINDH, T. MATZSCH, T. LANNE, *Eur. J. Vasc. Endovasc. Surg.*, 12 (1996) 231. – 20. PRESTIGIACOMO, C. J., E. CONNOLLY, D. O. QUEST, *Neurosurg. Clin. N. Am.*, 7 (1996) 577. – 21. CARTIER, R., P. CARTIER, A. FONTAINE, *Can. J. Surg.*, 36 (1993) 411. – 22. DAWSON, D. L., R. E. ZIERLER, D. E. STRANDNESS, A. W. CLOWES, T. R. KOHLER, *J. Vasc. Surg.*, 18 (1993) 673. – 23. MIKSIČ, K., V. FLIS, G. KOŠIR, M. PAVLOVIČ, E. TETIČKOVIČ, *Cardiovasc. Surg.*, 5 (1997) 190. – 24. BARTELS, E.: Color-coded duplex ultrasonography of the cerebral vessels: Atlas and manual. (Schattauer, Stuttgart, 1999). – 25. SAMESHIMA, T., S. FUTAMI, Y. MORITA, *Surg. Neurol.*, 51 (1999) 300. – 26. GERRATY, R. P., D. N. BOWSER, B. INFELD, P. J. MITCHELL, S. M. DAVIS, *Stroke*, 27 (1996) 1543.

E. Tetičkovič

Department of Neurology, Maribor Teaching Hospital, Ljubljanska 5, 2000 Maribor, Slovenia

TRODIMENZIONALNA ULTRASONOGRAFIJA U EVALUACIJI ATEROSKLEROTSKE STENOZE KAROTIDNOG DEBLA

SAŽETAK

Trodimenzionalna ultrasonografija značajna je novost u neurosonologiji jer pruža mogućnost još uspješnije procjene aterosklerotske stenozе karotidnog debla od prijašnjih ultrazvučnih pretraga. U 37 bolesnika sa znakovima tranzitornog ishemičnog napada te u 5 bolesnika s reverzibilnim neurološkim deficitom, uspoređeni su nalazi trodimenzionalne ultrasonografije karotidnih arterija na vratu s onima trodimenzionalne CT-angiografije. U 20 bolesnika u kojih je učinjena karotidna trombendarterektomija, nalazi obje dijagnostičke metode su također uspoređeni s angiografskim i operativnim nalazima. Od ukupno 42 nalaza trodimenzionalne ultrasonografije, trodimenzionalne CT-angiografije i angiografije karotidnog debla, samo je u dva nalaza pronađena raz-

lika u procjeni stupnja karotidne stenozе, dok su kod svih ostalih bolesnika nalazi bili suglasni i to u odnosu na procjenu stupnja stenozе i analizu plaka. Od 20 operativnih nalaza samo kod jednog bolesnika nalaz nije pokazao značajne promjene u odnosu na druge dvije dijagnostičke metode. Prema našem mišljenju, trodimenzionalna ultrasonografije je pouzdana dijagnostička metoda u procjeni aterosklerotičnih stenozа karotidnih arterija. Svaka sub-totalna stenozа ili okluzija unutrašnje karotidne arterije ustanovljena trodimenzionalnom ultrasonografijom mora se usporediti s trodimenzionalnom CT-angiografijom ili klasičnom angiografijom zbog objektivne mogućnosti lažne ultrasonografske interpretacije i značaja karotidne trombo endarterektomije.