

# Artificial intelligence in magnetic resonance imaging of the knee

Petra Kujundžić<sup>1</sup>, Tatjana Matijaš<sup>1</sup>

<sup>1</sup>University of Split, University Department of Health Studies, Split, Croatia

Corresponding author: **Tatjana Matijaš**, e-mail: [tmatijas@ozs.unist.hr](mailto:tmatijas@ozs.unist.hr)

DOI: <https://doi.org/10.55378/rv.47.2.5>

---

## Summary

**Introduction:** Technological progress leads to an increasing use of radiological imaging, and an increase in the number of imaging results in an increased workload for radiologists. The driver of the application of AI in radiology is considered to be the reduction of the workload of radiologists and the need for faster and more accurate diagnosis.

**Aim:** The aim of this paper is to bring the reader closer to the implementation of AI in radiology, especially in the MRI modality, and how deep learning algorithms improve image reconstruction.

**Discussion:** Numerous studies have confirmed the importance of implementing machine learning, a subset of artificial intelligence, in the radiology system. In this review paper, numerous researches on the application of deep learning in magnetic resonance imaging are highlighted, and the emphasis is on models for automatic segmentation. Automatic segmentation has shown excellent results in the early detection of osteoarthritis, then in anterior cruciate ligament and meniscus tears, the most common knee injuries, and more recently, the deep learning model has excelled in automatic bone age estimation. Automatic segmentation has achieved, above all, high accuracy and precision, objectivity and time saving.

**Conclusion:** Previous research has already highlighted the significant advantage of using machine learning in radiology and the exceptional compatibility between the work of radiologists and machine learning, which achieves precise and quick diagnoses. All this is a great incentive for further research, and technological progress will certainly speed up its integration into clinical practice.

**Keywords:** artificial intelligence; automatic segmentation; deep learning; MRI

**Abbreviations and acronyms:** AI (Artificial Intelligence), ANN (Artificial Neural Network), CNN (Convolutional Neural Network), DL (Deep Learning), fCNN (Fully Convolutional Neural Network), HNN (Holistically Nested Networks), ML (Machine Learning), MRI (Magnetic Resonance Imaging), NMR (Nuclear Magnetic Resonance), OA (osteoarthritis), SL (Supervised Learning), TBM (Transport Based Morphometry), UL (Unsupervised Learning), VN (Variational Network)

---

## Introduction

Radiology is a branch of medical science that, with the help of imaging and radiation technology, establishes a diagnosis and leads to the treatment of diseases. Technological progress has led to the increasing use of imaging, where higher resolution images are obtained and the visualization of smaller anatomical structures and abnormalities is possible. The increased need for radiological imaging has increased the workload of radiologists, so the driver of the application of artificial intelligence (AI) in radiology is considered precisely to reduce the workload of radiologists, as well as the need for ever greater precision and efficiency in diagnostics, but also in therapy [1].

## Magnetic resonance imaging

Magnetic Resonance Imaging (MRI) is an imaging method for obtaining tomographic sections in the transverse, sagittal and coronal planes [2]. Its working principle is based on nuclear magnetic resonance (NMR), a spectroscopic method that uses a magnetic field and radio frequency energy to reveal and analyze microscopic data on the chemical and physical properties of molecules [3]. The beginning of this method dates back to 1882 with the discovery of the use of a rotating magnetic field in an electric motor by Nikola Tesla, and the practical application of MRI for medical purposes is attributed to Raymond Damadian who, along with the discovery that different tissues have

different relaxation times, together constructed the first MRI device with his students in 1977 and performed the first scan of the human body [4].

### Basic parts of the magnetic resonance device

MRI devices are located inside Faraday cage, a room specially built to protect the device from unwanted external influences. The basic part of the device, the bore, consists of densely wound superconducting threads through which a strong electric current passes and creates a homogeneous magnetic field. The magnet itself is located in the center of the device and ensures the uniformity and strength of the magnetic field, and considering its technical characteristics, MRI devices are divided into permanent, resistive and superconducting ones [2, 3]. The most commonly used superconducting magnet is the only one that can produce a magnetic field with a strength above 1 T. In addition to magnets, gradient and radio frequency coils should be highlighted as necessary parts of every MRI device. Gradient coils are located in three main planes (X,Y,Z) and together with gradient amplifiers form time-varying gradient magnetic fields and are considered one of the most important elements responsible for image quality [3, 5]. On the other hand, radio frequency coils can be both transmitting and receiving and are shaped according to the recorded part of the body to achieve better signal reception. The signal they then receive is sent to a radio frequency preamplifier, followed by processing in an analog-to-digital converter and electronically modified into a digital image signal [3].

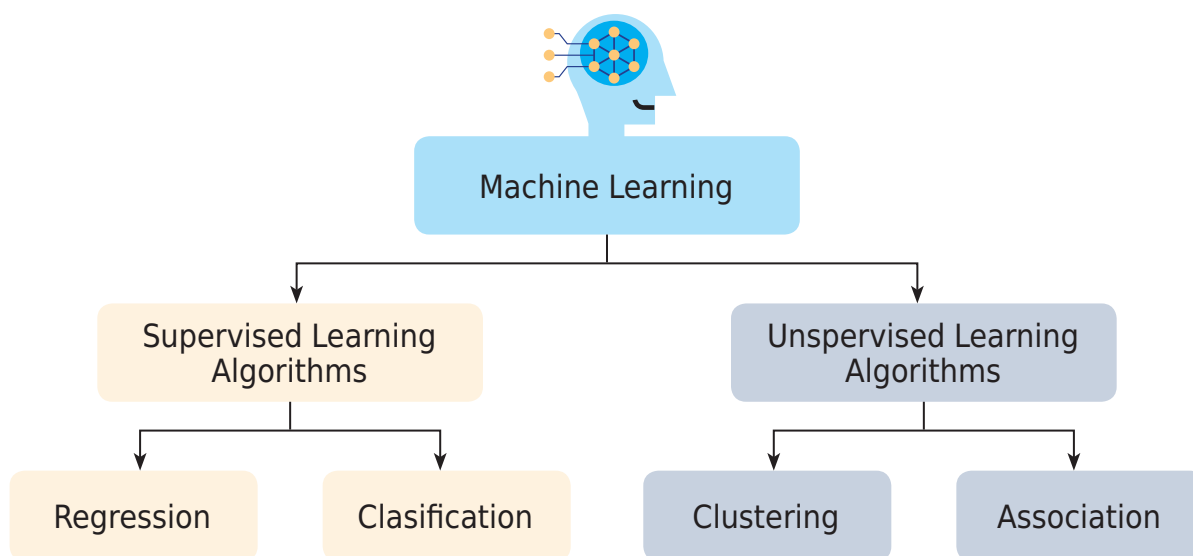
### Principle of operation of the magnetic resonance device

Substances found in the human body are composed of mutually different atoms, which determines different physical and magnetic properties. Given that the human body is largely made of water, of which hydrogen is a con-

stituent part, it is precisely its properties that are used to obtain an MRI image. Since the hydrogen ion is positively charged and has a large spin magnetic moment, MRI uses the very property of the magnetic spin to obtain an image. The hydrogen nucleus consists of one positively charged proton and creates its own magnetic field, and magnetization requires a strong external magnetic field that will align the protons in the direction of the magnetic field. In order to measure the magnetizing moment, it must first receive external energy by means of which it moves from the parallel direction, and this is achieved by the action of a radio frequency wave. After the end of the radio frequency wave, the magnetization vector returns from the transverse to the longitudinal plane, during which the energy from the previously excited protons is released and given to the environment. This phenomenon is called longitudinal magnetization recovery, or T1 relaxation. At the same time, there is a loss of rotation of the magnetization vectors of hydrogen nuclei in the same phase, that is, there is a so-called dephasing, decay of transverse magnetization or T2 relaxation [3, 5].

### Artificial Intelligence

AI can be defined as a set of computer algorithms that have the ability to perform certain complex tasks [6]. It is based on collecting, storing and processing data, then training machines and learning from previously provided data to successfully perform tasks [7]. When it comes to its implementation in medicine, which began in the 1950s [8], radiology is considered the most desirable branch [9]. A significant advantage due to the application of AI in radiology is the progress of radiology from subjectively determined perception skills to objective and scientifically guided data processing. It also provides increasing multidisciplinary in the team and success in treating patients by recognizing minimal abnormalities invisible to the human eye [7].



**Figure 1.** Division of machine learning

Source: <https://www.shiksha.com/online-courses/articles/differences-between-supervised-and-unsupervised-learning/>

## Machine learning

The main component of AI is machine learning (ML). It is defined as a subset of algorithms [6] that, using the provided data, enable machine learning [7]. The basic task is to find natural patterns and relationships in the data, then perform insights based on them and make predictions and make decisions [10]. ML algorithms can be organized into different categories, and the most common division is into supervised learning (SL) and unsupervised learning (UL) (Figure 1) [1].

SL consists of models trained with a pre-known set of input and output data that work on the principle of predicting the output using the available input data [10]. It is most often used in the procedures of classification, classification of input data into categories, and regression, prediction of numerical values [11]. With UL, the goal is to find latent patterns in known input variables without prior knowledge of the output, and in this way the algorithm itself must come to know what it shows [12].

## Deep learning

Deep learning (DL) is a subset of ML based on artificial neural networks (ANN), which are configured on the principle of biological neural networks in the human brain [13]. An ANN is composed of interconnected neurons, and in traditional ML, 2 to 3 layers of neurons enable the performance of complex tasks due to their interconnection [14]. In the evaluation of medical images, deep convolutional neural networks (CNN), are the most successful, characterized by automatic pattern recognition in complex data sets by combining feature selection and classification into one algorithm, without human intervention during training [15]. DL is also used in radiology for classification, segmentation and detection. In the classification, CNN is used and the object is assigned to a predetermined class, and it is used in the classification of the image itself, in determining the presence and type of abnormality, as well as in prediction. With segmentation, the image is divided into different segments, and the method of classification of individual voxels is most often applied. A certain issue that limits the application of this method and makes it computationally inefficient prompted the development of a fully convolutional neural network, (fCNN), whose advantage is manifested in avoiding repeated turns by analyzing the image in a wider context and labeling segments of all voxels simultaneously [16]. Segmentation can be divided into manual, semi-automatic and automatic. With manual segmentation, the radiologist marks the regions of interest manually, which makes it time-consuming and insufficiently precise. This lack of manual segmentation prompted the development of semi-automatic segmentation that segments specific regions with the help of software based on data obtained from manual segmentation. Given that the similarity between manual and semi-automatic segmentation in segmentation time was established, a significant shift was observed only with automatic segmentation, which performs the segmentation process completely automatically using software, without previous manual segmentation [17]. Finally, DL was also applied in detection whose task is to localize and specify the object in the image, and this step is significant in the identification of abnormalities [14].

## The aim of the paper

The aim of this paper is to describe AI and its application in radiology, especially in the MRI modality. In this review paper, the basic concepts of how DL algorithms improve image reconstruction and lead to faster and more accurate results, both in the detection of knee diseases and injuries, and in the assessment of bone age, are discussed.

## Discussion

### Application of artificial intelligence in magnetic resonance imaging

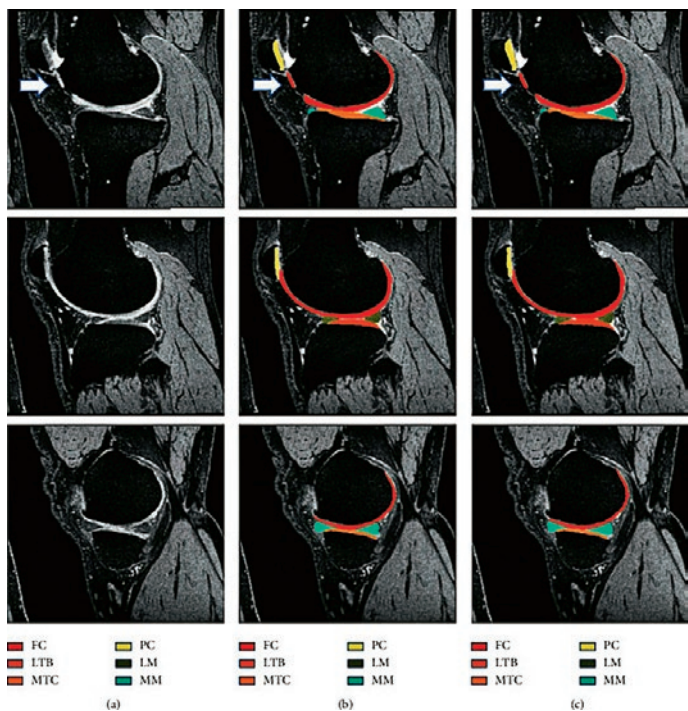
Due to the precise presentation of anatomical and functional data without the use of ionizing radiation, MRI is considered one of the most effective radiological methods for establishing a medical diagnosis [18]. By increasing the strength of the magnetic field, the signal-to-noise ratio increases and the spatial resolution of the image improves, and the image acquisition process itself is accelerated [19]. Since image reconstruction is at the very center of MRI work, it is an area of interest in numerous researches as well as in the application of DL. In addition to reconstruction, DL also found its application in image post-processing and contributed to quality improvement by reducing artifacts and removing noise. A significant limitation of MRI is the duration of imaging, which is especially a problem when imaging the musculoskeletal system due to the risk of motion artifacts [16]. Therefore, the application of DL led to the development of accelerated acquisitions, and the most effective was the variational network (VN), based on multiple coils, applied specifically in knee MRI imaging [20].

### Artificial intelligence in magnetic resonance imaging of the knee

MRI has proven to be the gold standard in knee imaging due to good contrast and soft tissue imaging, especially in the detection of knee injuries, among which the most common are meniscus injuries and anterior cruciate ligament tears, then in the diagnosis and prevention of knee diseases and age assessment. AI has found its application in the creation of different knee segmentation models and thus contributed to faster, more precise and reliable diagnosis, but also in the actual visualization of the knee anatomy and its segmentation, which enables a three-dimensional display and excellent diagnostic interpretation. Segmentation of several different tissues achieves a more detailed anatomical view and thus enables the knee to be viewed in all three dimensions, which is also important for the detection of potential pathology [21].

### Application of artificial intelligence in osteoarthritis

Osteoarthritis (OA) is a degenerative joint disease that can also affect the meniscus and ligament [22]. The knee joint is most often affected, which is characterized by irreversible degeneration of the articular cartilage. Given that this is an irreversible damage, early diagnosis of this disease is important to stop its spread and postpone total knee replacement [23]. Given that bone degeneration can



**Figure 2.** Presentation of the original MRI image (a) of the knee cartilage, and comparison of manual (b) and automated segmentation (c)

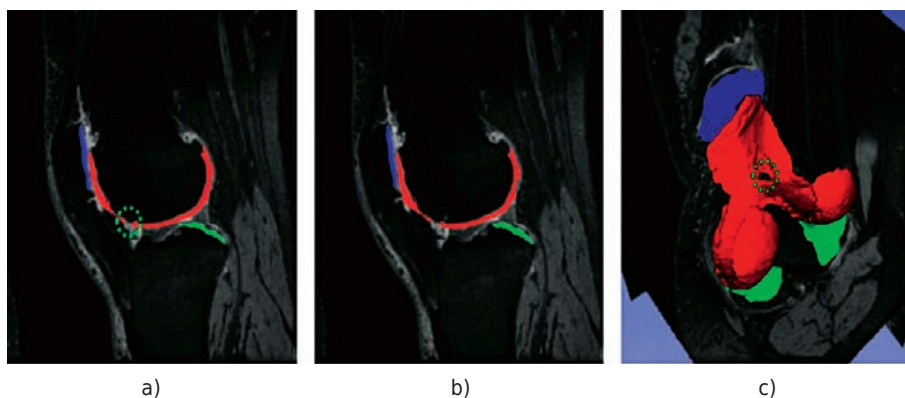
Source: <https://www.ncbi.nlm.nih.gov/pmc/articles/PMC8598325/>

only be seen in advanced conditions with classical radiography, MRI is considered the most effective, providing greater potential in early diagnosis of OA due to better cartilage representation [24] and quantitative biomarker analysis [23]. One of the most important parts of the diagnostic medical image is the segmentation process, which makes it possible to distinguish pathology from healthy tissue [25]. Segmentation divides the image into meaningful parts, and it consists of the classification of each pixel of the image into certain classes [26]. Today, automatic segmentation has found wide application in diagnostics due to its speed and the fact that it does not

depend on the intervention of a doctor, which makes it a precise and accurate approach (Figure 2) [23].

Initially, the segmentation was based on the application of 2D DL, when it comes to the assessment of knee OA, and mostly CNN segmentation was based on the U-net architecture composed of encoders and decoders [27,28]. Technological progress led firstly to the application of automatic segmentation with a combination of 2D and 3D modeling [29], and then to the development of segmentation based only on the 3D model, among which the first to develop “ $\mu$  - Net” for multi-class segmentation of cartilage (Figure 3) and meniscus [23].

Also, DL enabled the development of a super-resolution algorithm for processing MRI images that reconstructs low-resolution images into high-resolution images, which reduces noise and artifacts in the image to a minimum and improves the quality of the image itself [30]. The use of AI has attracted considerable attention from scientists in the detection of OA in presymptomatic healthy individuals [31], and the approach described and applied in several studies is three-dimensional transport-based morphometry (TBM) [32-35]. Due to the direct display of early biochemical cartilage deformations, this approach proved to be suitable for diagnostic use and pre-clinical detection of the disease in the reversible phase, and the results showed that it is able to identify the risk of developing the disease even three years before the diagnosis is established [36]. The disadvantage of CNN is the need for a large memory, which led to the creation of an adequate replacement, the so-called holistically nested network (HNN), which memory size is reduced by half [37]. A landmark study of 2481 participants presented a DL-based model for automatic segmentation on a 3 T MRI device, which calculated cartilage thickness values for 14 separate regions of interest in the knee joint and was able to incrementally measure changes in the structure of the cartilage itself and on that way actually determine the process of development of the disease itself. The results showed that cartilage thickness wears out proportionally with aging and was more prominent in men than in women of any age group [38], and automatic segmentation based on DL proved to be very effective when applied to a large population of people [39].



**Figure 3.** Presentation of 3D visualization of cartilage segments on a sagittal section (a,b) and presentation of cartilage segmentation (c)

Source: <https://www.ncbi.nlm.nih.gov/pmc/articles/PMC8598325/>

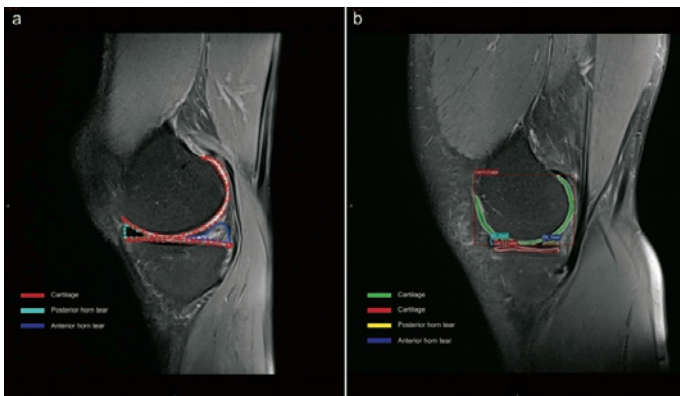
## Application of artificial intelligence in knee injury diagnostics

Meniscus injuries and anterior cruciate ligament tears are among the most common knee injuries. When diagnosing knee injuries, the most suitable method is MRI, and automated interpretation models based on CNN have been developed using AI. One of them is MRNet, whose usefulness is based on the speed of establishing a diagnosis, i.e. it only takes a few minutes to perform all the classifications in relation to the interpretation by a doctor, which can take up to several hours [40]. In particular, when diagnosing meniscal injury, the Mask R-CNN method based on DL was developed and proved to be effective due to improved data processing and reduced possibility of error (Figure 4) [41].

Furthermore, the CNN model should be highlighted, the importance of which lies in the fact that, in addition

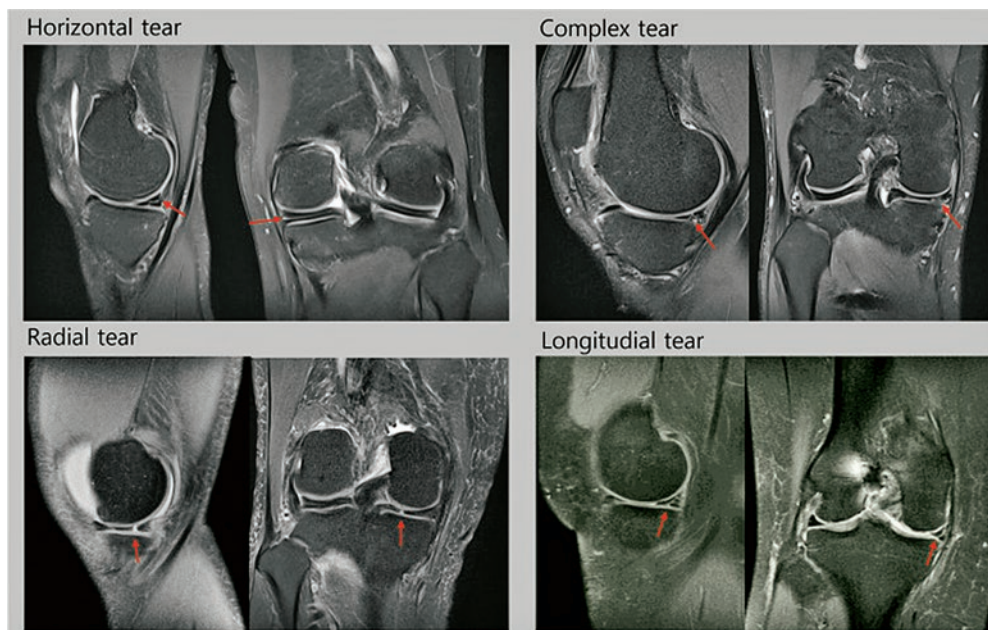
to the detection of the meniscus rupture itself, it can also successfully determine the type of rupture (Figure 5) [42].

The proven connection between pathological conditions of the meniscus and osteoarthritis has awakened a growing interest in the early detection of pathologies in order to diagnose osteoarthritis in early stage. Conventional MRI sequences are unsuitable for quantitative data evaluation, which led to the use of ultrashort echo time sequences. The DL model proposed for automatic segmentation of the meniscus showed successful results compared to the results of two radiologists who performed manual segmentation and thus proved to be relevant for displaying quantitative meniscus data important in diagnosing and monitoring osteoarthritis [43]. When classifying rupture of the anterior cruciate ligament, in addition to the aforementioned model, presented by the so-called Inception-v3 DTL CNN model which, compared to previously used models, achieved a higher training accuracy by 3.1% and testing accuracy by 9.9%, when it comes to crack detection [44]. The importance of the classification of anterior cruciate ligament rupture is also in the prevention of osteoarthritis [45]. One study proved a connection between the anterior cruciate ligament and the femoral intracondylar fossa, and it was shown that those patients who have a lower volume of the femoral intracondylar fossa have a higher risk of anterior cruciate ligament rupture. For the reconstruction of the anterior cruciate ligament, the so-called notchplasty to increase the intracondylar fossa, and in order to avoid frequent performance of this procedure, the preoperative application of MRI is introduced to display the structures of the knee joint using automatic segmentation based on DL due to its excellent ability to independently learn from the provided data (Figure 6). This Res-UNet model achieved a segmentation speed of 3 to 5 seconds, which is very useful compared to manual segmentation that required 10 minutes to achieve the same results, and this model proved to be useful in clinical application [46].



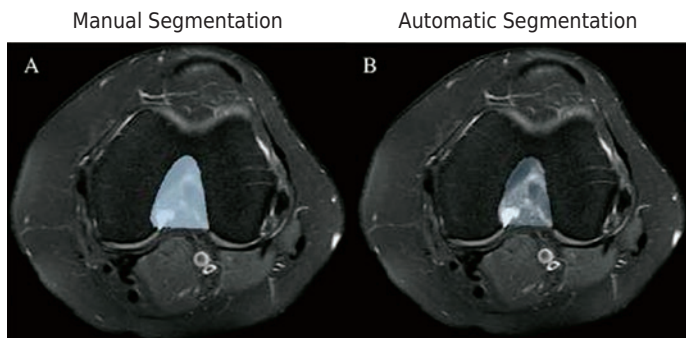
**Figure 4.** Visual representation of the MRI meniscus data set. Figure (a) shows object labeling and Figure (b) is derived from a deep learning model

Source: <https://www.ncbi.nlm.nih.gov/pmc/articles/PMC9253363/>



**Figure 5.** Presentation of MRI images of all types of meniscal tears

Source: <https://www.ncbi.nlm.nih.gov/pmc/articles/PMC9150332/>

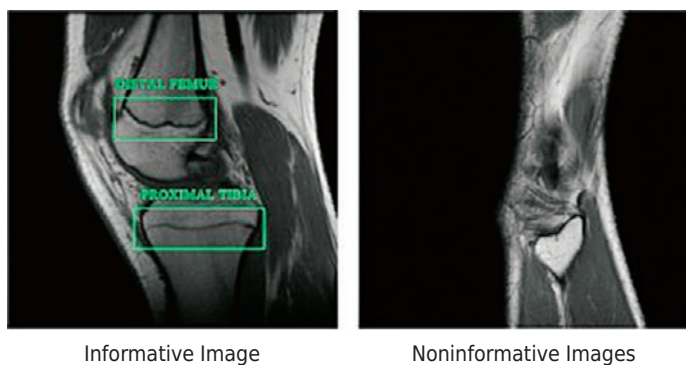


**Figure 6.** Comparison of manual volume segmentation of the femoral intracondylar notch (a) and automatic segmentation using the Res-UNet model

Source: <https://www.ncbi.nlm.nih.gov/pmc/articles/PMC9074347/>

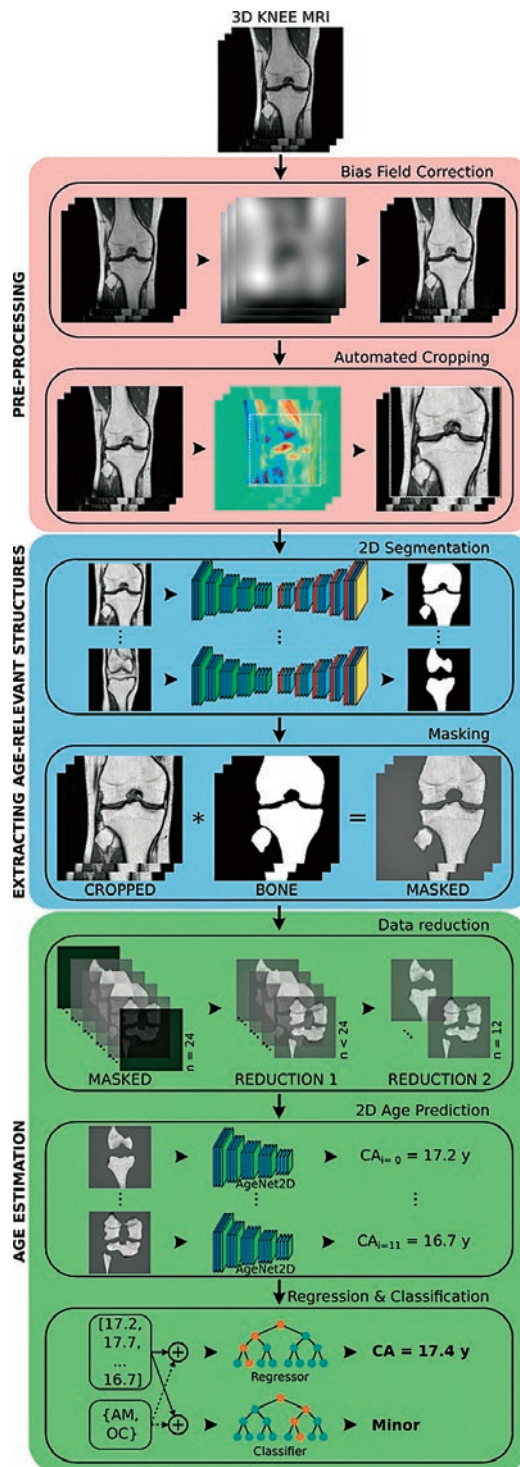
### Application of artificial intelligence in age estimation

In addition to helping to diagnose diseases mainly related to the growth of children [47, 48], the importance of bone age is also evident in unidentified individuals for determining juvenile status, which is often the case in immigration and legal proceedings [49]. Initially, traditional methods were used to estimate age, whereby bone age was determined using the bones of the wrist and hand [47], and bone development was shown using standard X-rays [50]. Two methods were most often used, Greulich Pyle (GP), where bone age was determined by comparing the patient's image with the closest reference image in the atlas, and Tanner-Whitehouse 2 (TW2), a method based on a scoring system that proved to be more objective, and more reproducible than the GP method, but more time-consuming [48]. In addition to radiography of the hand, radiography of the knee also proved to be suitable due to the possibility of displaying the epiphyses of



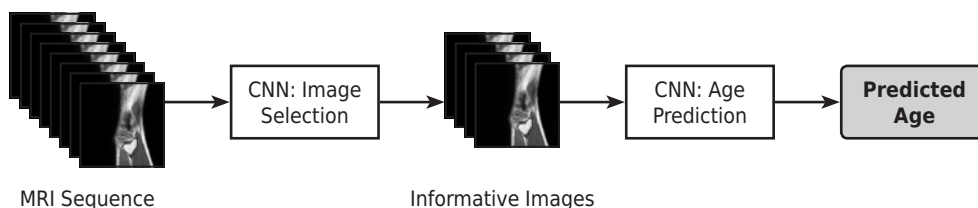
**Figure 7.** Examples of informative (taken) and non-informative (discarded) images for segmentation

Source: <https://www.ncbi.nlm.nih.gov/pmc/articles/PMC6923761/>



**Figure 9.** Proposed model for automatic age estimation

Source: <https://www.ncbi.nlm.nih.gov/pmc/articles/PMC7870623/>



**Figure 8.** Presentation of the proposed CNN model for automatic age estimation

Source: <https://www.ncbi.nlm.nih.gov/pmc/articles/PMC6923761/>

three bones simultaneously without superimposing other structures with a small dose of radiation [51]. Due to the time-consuming and inaccuracy of traditional methods, the automatic age estimation based on DL, which is based on radiographs of the hand, was first introduced [52], and after the automation of age estimation based on hand radiographs proved successful, the DL model for automatic age estimation based on radiographs of the knee, which stood out for its high accuracy and excellent performance was also presented [51]. Certain shortcomings of traditional methods have encouraged the use of automatic segmentation to avoid the long duration of age estimation and the dependence on the subjective assessment of radiologists [49] and the use of MRI for earlier detection of cartilage ossification changes [53]. Automatic segmentation began to be applied in MRI of the knee due to the knowledge about the intensity of the cartilage signal in the knee, which is displayed in men up to 30 years of age, and in women 29 years of age, and due to the balanced maturation of the ossification centers in both sexes. When training the DL model, informative images with visible growth zones and non-informative images with no clearly visible growth zones were used (Figure 7).

The DL model was trained in a way to classify the most informative part of the image, namely the growth plate, epiphysis and metaphysis (Figure 8), and the importance of the model in this study is its ability to determine chronological age in addition to bone age, as well as a high percentage of classification accuracy minors in both sexes [49].

Because there is no ionizing radiation, MRI has become the primary method of choice for age estimation in unidentified young humans, and the automatic segmentation model consists of three parts. In the first step, the uneven signal is corrected as a consequence of the inhomogeneous magnetic field and the volume of interest is determined by automatic cropping. This is followed by the

extraction of structures relevant to age estimation and finally the age estimation based on the processed data. This principle stood out with excellent results in good regression, using the most coronary sections, and in the classification whose importance stands out the most in forensic age assessment (Figure 9) [54].

## Conclusion

Technological progress manifests itself in radiology primarily through the development of different imaging modalities, but also through the implementation of AI, which excelled in automatic analysis and establishment of diagnosis. MRI is a modality that stands out for its excellent contrast of soft tissue without the use of ionizing radiation, and ML, which proved to be the most significant for radiological practice, found its application in the creation of various models for automated segmentation of the knee and thus contributed to faster, more accurate and more reliable disease diagnosis. and knee injury, but also age estimation. Since it is still an abstract topic, there are many opinions that AI is a threat to radiologists, but it will never be able to completely replace radiologists, since their work includes contact with the patient, their medical judgment, interventional procedures and numerous other tasks that cannot be replaced by the computer itself. In contrast, the integration of AI in radiology, but also in other branches of medical science, should be viewed optimistically, as a help and relief primarily for radiologists when processing the large amount of data they encounter.

All data in this paper are part of the results of the undergraduate thesis "Application of artificial intelligence in magnetic resonance imaging of the knee" written at the University Department of Health Studies, University of Split [55]. ■

## Umjetna inteligencija u oslikavanju koljena magnetnom rezonancijom

### Sažetak

**Uvod:** Tehnološkim napretkom dolazi do sve veće uporabe radioloških snimanja, a povećanjem broja snimanja dolazi do povećanog radnog opterećenja radiologa. Pokretačem primjene AI u radiologiji smatra se upravo smanjenje radnog opterećenja radiologa i potreba za bržom i preciznijom uspostavom dijagnoze.

**Cilj rada:** Cilj ovog rada je približiti čitatelju implementaciju AI u radiologiji, posebno kod modaliteta MRI te na koji način algoritmi dubokog učenja pospješuju rekonstrukciju slike.

**Rasprava:** Brojna su istraživanja potvrdila značaj implementacije strojnog učenja, podskupa umjetne inteligencija, u radiološki sustav. U ovom preglednom radu izdvojena su brojna istraživanja primjene dubokog učenja kod magnetne rezonancije, a naglasak je na modelima za automatsku segmentaciju. Automatska segmentacija pokazala je izvrsne rezultate kod ranog otkrivanja osteoartritisa, zatim kod puknuća prednjeg križnog ligamenta i meniska, najčešćih ozljeda koljena, a također se u novije vrijeme model dubokog učenja istaknuo i kod automatske procjene koštane dobi. Automatskom segmentacijom postigla se, prije svega visoka točnost i preciznost, objektivnost i ušteda vremena.

**Zaključak:** Dosadašnja istraživanja već su istaknula značajnu prednost primjene strojnog učenja u radiologiji te iznimnu kompatibilnost u radu radiologa i strojnog učenja, čime se postižu precizne i brze dijagnoze. Sve je to veliki poticaj za daljnja istraživanja, a tehnološki napredak zasigurno će ubrzati njegovu integraciju u kliničku praksu.

**Ključne riječi:** automatizirana segmentacija; duboko učenje; MRI; umjetna inteligencija

## Literature

1. Wang S, Summers RM. Machine learning and radiology. *Med Image Anal.* 2012 Jul;16(5):933-51. doi: 10.1016/j.media.2012.02.005. Epub 2012 Feb 23. PMID: 22465077; PMCID: PMC3372692.
2. Janković, S., Mihanović, F. *Uvod u radiologiju*, Split: Sveučilište u Splitu, 2014.
3. Janković, S., Mihanović F. *Radiološki uređaji i oprema u radiologiji, radioterapiji i nuklearnoj medicini*, Split: Sveučilište u Splitu, 2015.
4. <https://two-views.com/mri-imaging/history.html#sthash.K8hb7k0A.dpbs> (accessed on 5.9.2023.)
5. Miletić, D. Tehnike slojevnog snimanja. *Medicinski fakultet Rijeka*. Sveučilište u Rijeci 2012; 53-57.
6. Erickson BJ, Korfiatis P, Akkus Z, Kline TL. Machine Learning for Medical Imaging. *Radiographics.* 2017 Mar-Apr;37(2):505-515. doi: 10.1148/rg.2017160130. Epub 2017 Feb 17. PMID: 28212054; PMCID: PMC5375621.
7. Pesapane F, Codari M, Sardaneli F. Artificial intelligence in medical imaging: threat or opportunity? Radiologists again at the forefront of innovation in medicine. *Eur Radiol Exp.* 2018 Oct 24;2(1):35. doi: 10.1186/s41747-018-0061-6. PMID: 30353365; PMCID: PMC6199205.
8. Shortliffe EH. Artificial Intelligence in Medicine: Weighing the Accomplishments, Hype, and Promise. *Yearb Med Inform.* 2019 Aug;28(1):257-262. doi: 10.1055/s-0039-1677891. Epub 2019 Apr 25. PMID: 31022745; PMCID: PMC6697517.
9. Amisha, Malik P, Pathania M, Rathaur VK. Overview of artificial intelligence in medicine. *J Family Med Prim Care.* 2019 Jul;8(7):2328-2331. doi: 10.4103/jfmpc.jfmpc\_440\_19. PMID: 31463251; PMCID: PMC6691444.
10. Bolf N, Bolf (ur.) N. *Osvježimo znanje: Strojno učenje. Kemija u industriji* [Internet]. 2021 [accessed on 20.06.2023.];70(9-10):591-593.
11. <https://www.mygreatlearning.com/blog/what-is-machine-learning/> (accessed on 7.9.2023.)
12. [https://www.sas.com/en\\_us/insights/analytics/machine-learning.html](https://www.sas.com/en_us/insights/analytics/machine-learning.html) (accessed on 7.9.2023.)
13. IBM Cloud Learn Hub - Deep Learning (accessed on 20.06.2023.) Available at: <https://www.ibm.com/cloud/learn/deep-learning#toc-how-deep-l-vLjWmX4>
14. Mazurowski MA, Buda M, Saha A, Bashir MR. Deep learning in radiology: An overview of the concepts and a survey of the state of the art with focus on MRI. *J Magn Reson Imaging.* 2019 Apr;49(4):939-954. doi: 10.1002/jmri.26534. Epub 2018 Dec 21. PMID: 30575178; PMCID: PMC6483404.
15. Soun JE, Chow DS, Nagamine M, Takhtawala RS, Filippi CG, Yu W, Chang PD. Artificial Intelligence and Acute Stroke Imaging. *AJNR Am J Neuroradiol.* 2021 Jan;42(1):2-11. doi: 10.3174/ajnr.A6883. Epub 2020 Nov 26. PMID: 33243898; PMCID: PMC7814792.
16. Lin DJ, Johnson PM, Knoll F, Lui YW. Artificial Intelligence for MR Image Reconstruction: An Overview for Clinicians. *J Magn Reson Imaging.* 2021 Apr;53(4):1015-1028. doi: 10.1002/jmri.27078. Epub 2020 Feb 12. PMID: 32048372; PMCID: PMC7423636.
17. Dionisio FCF, Oliveira LS, Hernandez MA, Engel EE, de Azevedo-Marques PM, Nogueira-Barbosa MH. Manual versus semiautomatic segmentation of soft-tissue sarcomas on magnetic resonance imaging: evaluation of similarity and comparison of segmentation times. *Radiol Bras.* 2021 May-Jun;54(3):155-164. doi: 10.1590/0100-3984.2020.0028. PMID: 34108762; PMCID: PMC8177681.
18. Wang S, Su Z, Ying L, Peng X, Zhu S, Liang F, Feng D, Liang D. ACCELERATING MAGNETIC RESONANCE IMAGING VIA DEEP LEARNING. *Proc IEEE Int Symp Biomed Imaging.* 2016 Apr;2016:514-517. doi: 10.1109/ISBI.2016.7493320. Epub 2016 Jun 16. PMID: 31709031; PMCID: PMC6839781.
19. Laeder A, Beiderwellen K, Kraff O, Maderwald S, Wrede K, Ladd ME, Lauenstein TC, Forsting M, Quick HH, Nassenstein K, Umutlu L. 1.5 versus 3 versus 7 Tesla in abdominal MRI: A comparative study. *PLoS One.* 2017 Nov 10;12(11):e0187528. doi: 10.1371/journal.pone.0187528. PMID: 29125850; PMCID: PMC5695282.
20. Hammernik K, Klatzer T, Kobler E, Recht MP, Sodickson DK, Pock T, Knoll F. Learning a variational network for reconstruction of accelerated MRI data. *Magn Reson Med.* 2018 Jun;79(6):3055-3071. doi: 10.1002/mrm.26977. Epub 2017 Nov 8. PMID: 29115689; PMCID: PMC5902683.
21. Kulseng CPS, Nainamalai V, Grøvik E, Geitung JT, Årøen A, Gjesdal KI. Automatic segmentation of human knee anatomy by a convolutional neural network applying a 3D MRI protocol. *BMC Musculoskelet Disord.* 2023 Jan 18;24(1):41. doi: 10.1186/s12891-023-06153-y. PMID: 36650496; PMCID: PMC9847207.
22. Allen K. D., Bongiorno D., Caves K., et al. STepped exercise program for patients with knee OsteoArthritis (STEP-KOA): protocol for a randomized controlled trial. *BMC Musculoskeletal Disorders.* 2019;20(1):p. 254. doi: 10.1186/s12891-019-2627-8.
23. Yeoh PSQ, Lai KW, Goh SL, Hasikin K, Hum YC, Tee YK, Dhanalakshmi S. Emergence of Deep Learning in Knee Osteoarthritis Diagnosis. *Comput Intell Neurosci.* 2021 Nov 10;2021:4931437. doi: 10.1155/2021/4931437. PMID: 34804143; PMCID: PMC8598325.
24. Zheng Z, He R, Lin C, Huang C. Multimodal Magnetic Resonance Imaging to Diagnose Knee Osteoarthritis under Artificial Intelligence. *Comput Intell Neurosci.* 2022 Jun 23;2022:6488889. doi: 10.1155/2022/6488889. PMID: 35785062; PMCID: PMC9246643.
25. Ahn C, Bui TD, Lee YW, Shin J, Park H. Fully automated, level set-based segmentation for knee MRIs using an adaptive force function and template: data from the osteoarthritis initiative. *Biomed Eng Online.* 2016 Aug 24;15(1):99. doi: 10.1186/s12938-016-0225-7. PMID: 27558127; PMCID: PMC4997678.
26. Awan MJ, Rahim MSM, Salim N, Rehman A, Garcia-Zapirain B. Automated Knee MR Images Segmentation of Anterior Cruciate Ligament Tears. *Sensors (Basel).* 2022 Feb 17;22(4):1552. doi: 10.3390/s22041552. PMID: 35214451; PMCID: PMC8876207.
27. Pedoia V., Norman B., Mehany S. N., Bucknor M. D., Link T. M., Majumdar S. 3D convolutional neural networks for detection and severity staging of meniscus and PFJ cartilage morphological degenerative changes in osteoarthritis and anterior cruciate ligament subjects. *Journal of Magnetic Resonance Imaging.* 2019;49(2):400-410. doi: 10.1002/jmri.26246.
28. Cheng R., Alexandridi N. A., Smith R. M., et al. Fully automated patellofemoral MRI segmentation using holistically nested networks: implications for evaluating patellofemoral osteoarthritis, pain, injury, pathology, and adolescent development. *Magnetic Resonance in Medicine.* 2020;83(1):139-153. doi: 10.1002/mrm.27920.
29. Liu F, Zhou Z., Jang H., Samsonov A., Zhao G., Kijowski R. Deep convolutional neural network and 3D deformable approach for tissue segmentation in musculoskeletal magnetic resonance imaging. *Magnetic Resonance in Medicine.* 2018;79(4):2379-2391. doi: 10.1002/mrm.26841.
30. Hu Y, Tang J, Zhao S, Li Y. Deep Learning-Based Multimodal 3 T MRI for the Diagnosis of Knee Osteoarthritis. *Comput Math Methods Med.* 2022 Apr 29;2022:7643487. doi: 10.1155/2022/7643487. PMID: 35529263; PMCID: PMC9076302.
31. Kundu S, Ashinsky BG, Bouhrara M, Dam EB, Demehri S, Shifat-E-Rabbi M, Spencer RG, Urish KL, Rohde GK. Enabling early detection of osteoarthritis from presymptomatic cartilage texture maps via transport-based learning. *Proc Natl Acad Sci U S A.* 2020 Oct 6;117(40):24709-24719. doi: 10.1073/pnas.1917405117. Epub 2020 Sep 21. PMID: 32958644; PMCID: PMC7547154.
32. Basu S, Kolouri S, Rohde GK. Detecting and visualizing cell phenotype differences from microscopy images using transport-based morphometry. *Proc Natl Acad Sci U S A.* 2014 Mar 4;111(9):3448-53. doi: 10.1073/pnas.1319779111. Epub 2014 Feb 18. PMID: 24550445; PMCID: PMC3948221.
33. Kundu S, Kolouri S, Erickson KI, Kramer AF, McAuley E, Rohde GK. Discovery and visualization of structural biomarkers from MRI using transport-based morphometry. *Neuroimage.* 2018 Feb 15;167:256-275. doi: 10.1016/j.neuroimage.2017.11.006. Epub 2017 Nov 5. PMID: 29117580; PMCID: PMC5912801.
34. Wang W, Slepčev D, Basu S, Ozolek JA, Rohde GK. A linear optimal transportation framework for quantifying and visualizing variations in sets of images. *Int J Comput*



- Vis. 2013 Jan 1;101(2):254-269. doi: 10.1007/s11263-012-0566-z. PMID: 23729991; PMCID: PMC3667970.
35. Kolouri S, Tosun AB, Ozolek JA, Rohde GK. A continuous linear optimal transport approach for pattern analysis in image datasets. *Pattern Recognit.* 2016 Mar 1;51:453-462. doi: 10.1016/j.patcog.2015.09.019. PMID: 26858466; PMCID: PMC4742369.
  36. Kundu S, Ashinsky BG, Bouhrara M, Dam EB, Demehri S, Shifat-E-Rabbi M, Spencer RG, Urish KL, Rohde GK. Enabling early detection of osteoarthritis from presymptomatic cartilage texture maps via transport-based learning. *Proc Natl Acad Sci U S A.* 2020 Oct 6;117(40):24709-24719. doi: 10.1073/pnas.1917405117. Epub 2020 Sep 21. PMID: 32958644; PMCID: PMC7547154.
  37. Cheng R, Alexandridi NA, Smith RM, Shen A, Gandler W, McCreedy E, McAuliffe MJ, Sheehan FT. Fully automated patellofemoral MRI segmentation using holistically nested networks: Implications for evaluating patellofemoral osteoarthritis, pain, injury, pathology, and adolescent development. *Magn Reson Med.* 2020 Jan;83(1):139-153. doi: 10.1002/mrm.27920. Epub 2019 Aug 11. PMID: 31402520; PMCID: PMC6778709.
  38. Si L, Xuan K, Zhong J, Huo J, Xing Y, Geng J, Hu Y, Zhang H, Wang Q, Yao W. Knee Cartilage Thickness Differs Alongside Ages: A 3-T Magnetic Resonance Research Upon 2,481 Subjects via Deep Learning. *Front Med (Lausanne).* 2021 Feb 9;7:600049. doi: 10.3389/fmed.2020.600049. PMID: 33634142; PMCID: PMC7900571.
  39. Shah RF, Martinez AM, Pedroia V, Majumdar S, Vail TP, Bini SA. Variation in the Thickness of Knee Cartilage. The Use of a Novel Machine Learning Algorithm for Cartilage Segmentation of Magnetic Resonance Images. *J Arthroplasty.* 2019 Oct;34(10):2210-2215. doi: 10.1016/j.arth.2019.07.022. Epub 2019 Jul 24. PMID: 31445869; PMCID: PMC7251923.
  40. Bien N, Rajpurkar P, Ball RL, Irvin J, Park A, Jones E, Bereket M, Patel BN, Yeom KW, Shpanskaya K, Halabi S. Deep-learning-assisted diagnosis for knee magnetic resonance imaging: development and retrospective validation of MRNet. *PLoS medicine.* 2018 Nov 27;15(11):e1002699.
  41. Li J, Qian K, Liu J, Huang Z, Zhang Y, Zhao G, Wang H, Li M, Liang X, Zhou F, Yu X, Li L, Wang X, Yang X, Jiang Q. Identification and diagnosis of meniscus tear by magnetic resonance imaging using a deep learning model. *J Orthop Translat.* 2022 Jun 26;34:91-101. doi: 10.1016/j.jot.2022.05.006. PMID: 35847603; PMCID: PMC9253363.
  42. Shin H, Choi GS, Shon OJ, Kim GB, Chang MC. Development of convolutional neural network model for diagnosing meniscus tear using magnetic resonance image. *BMC Musculoskelet Disord.* 2022 May 30;23(1):510. doi: 10.1186/s12891-022-05468-6. PMID: 35637451; PMCID: PMC9150332.
  43. Byra M, Wu M, Zhang X, Jang H, Ma YJ, Chang EY, Shah S, Du J. Knee menisci segmentation and relaxometry of 3D ultrashort echo time cones MR imaging using attention U-Net with transfer learning. *Magn Reson Med.* 2020 Mar;83(3):1109-1122. doi: 10.1002/mrm.27969. Epub 2019 Sep 19. PMID: 31535731; PMCID: PMC6879791.
  44. Sridhar S, Amutharaj J, Valsalan P, Arthi B, Ramkumar S, Mathupriya S, Rajendran T, Waji YA. A Torn ACL Mapping in Knee MRI Images Using Deep Convolution Neural Network with Inception-v3. *J Healthc Eng.* 2022 Feb 8;2022:7872500. doi: 10.1155/2022/7872500. PMID: 35178233; PMCID: PMC8846973.
  45. Awan MJ, Rahim MSM, Salim N, Rehman A, Nobanee H, Shabir H. Improved Deep Convolutional Neural Network to Classify Osteoarthritis from Anterior Cruciate Ligament Tear Using Magnetic Resonance Imaging. *J Pers Med.* 2021 Nov 9;11(11):1163. doi: 10.3390/jpm11111163. PMID: 34834515; PMCID: PMC8617867.
  46. Li M, Bai H, Zhang F, Zhou Y, Lin Q, Zhou Q, Feng Q, Zhang L. Automatic segmentation model of intercondylar fossa based on deep learning: a novel and effective assessment method for the notch volume. *BMC Musculoskelet Disord.* 2022 May 6;23(1):426. doi: 10.1186/s12891-022-05378-7. PMID: 35524293; PMCID: PMC9074347.
  47. Manzoor Mughal A, Hassan N, Ahmed A. Bone age assessment methods: a critical review. *Pakistan Journal of Medical Sciences.* 2014 Jan;30(1):211-215. DOI: 10.12669/pjms.301.4295. PMID: 24639863; PMCID: PMC3955574.
  48. Satoh M. Bone age: assessment methods and clinical applications. *Clinical Pediatric Endocrinology : Case Reports and Clinical Investigations : Official Journal of the Japanese Society for Pediatric Endocrinology.* 2015 Oct;24(4):143-152. DOI: 10.1297/cpe.24.143. PMID: 26568655; PMCID: PMC4628949.
  49. Dallora A, Berglund J, Brogren M, Kvist O, Diaz Ruiz S, Dübbel A, Anderberg P. Age Assessment of Youth and Young Adults Using Magnetic Resonance Imaging of the Knee: A Deep Learning Approach. *JMIR Med Inform* 2019;7(4):e16291 URL: <https://medinform.jmir.org/2019/4/e16291> DOI: 10.2196/16291
  50. Bhat AK, Kumar B, Acharya A. Radiographic imaging of the wrist. *Indian Journal of Plastic Surgery : Official Publication of the Association of Plastic Surgeons of India.* 2011 May;44(2):186-196. DOI: 10.4103/0970-0358.85339. PMID: 22022028; PMCID: PMC3193630.
  51. Demircioğlu A, Quinsten AS, Forsting M, Umutlu L, Nassenstein K. Pediatric age estimation from radiographs of the knee using deep learning. *Eur Radiol.* 2022 Jul;32(7):4813-4822. doi: 10.1007/s00330-022-08582-0. Epub 2022 Mar 1. PMID: 35233665; PMCID: PMC9213267.
  52. Halabi SS, Prevedello LM, Kalpathy-Cramer J, Mamonov AB, Bilbily A, Cicero M, Pan I, Pereira LA, Sousa RT, Abdala N, Kitamura FC, Thodberg HH, Chen L, Shih G, Andriole K, Kohli MD, Erickson BJ, Flanders AE. The RSNA Pediatric Bone Age Machine Learning Challenge. *Radiology.* 2019 Feb;290(2):498-503. doi: 10.1148/radiol.2018180736. Epub 2018 Nov 27. PMID: 30480490; PMCID: PMC6358027.
  53. Hao HX, Wang YH, Zhou ZL, Liu TA, Chen J, He YH, Wan L, Xia WT. Research Progress of Age Estimation in the Living by Knee Joint MRI. *Fa Yi Xue Za Zhi.* 2023 Feb 25;39(1):66-71. English, Chinese. doi: 10.12116/j.issn.1004-5619.2022.220503. PMID: 37038858.
  54. Mauer MA, Well EJ, Hermann J, Groth M, Morlock MM, Maas R, Säring D. Automated age estimation of young individuals based on 3D knee MRI using deep learning. *Int J Legal Med.* 2021 Mar;135(2):649-663. doi: 10.1007/s00414-020-02465-z. Epub 2020 Dec 17. PMID: 33331995; PMCID: PMC7870623.
  55. Kujundžić P. Primjena umjetne inteligencije kod magnetne rezonancije koljena (Završni rad). Split: Sveučilište u Splitu, Sveučilišni odjel zdravstvenih studija; 2023 (pristupljeno 3.9.2023.) Available at: <https://repo.ozs.unist.hr/islandora/object/ozs%3A1413>