

# Complications of Pneumatic Retinopexy

D. Kovačević and I. Bedenicki

Clinical Hospital Rijeka, Department of Ophthalmology, Rijeka, Croatia

## ABSTRACT

*Twenty-eight patients with rhegmatogenous retinal detachment were treated by pneumatic retinopexy using intravitreal perfluoropropane (C3F8) gas. Reattachment was successfully achieved in 22 eyes (78.6%) after one treatment. Most of the eyes were myopic and had a single retinal break or group of breaks within one o'clock hour. All retinal complications developed in the inferior retinal quadrants with postoperative proliferative vitreoretinopathy (PVR) as one of the most serious complications, occurring in 3 (10.7%) eyes. New retinal breaks developed in 2 (7.1%) eyes.*

## Introduction

Pneumatic retinopexy consists of transconjunctival injection of the expandable gas into the vitreous after cryotherapy of retinal breaks (Figure 1). Postoperative head-up position is necessary for at least three days. Although generally safe procedure, it may be associated with certain adverse outcomes<sup>1</sup>. It can be a useful alternative to conventional retinal detachment surgery in carefully selected cases<sup>2</sup>. The procedure is controversial and the literature reports variable initial success rates, sometimes smaller than achieved by conventional scleral buckle<sup>3</sup>. The goal of this study was to evaluate the efficiency and complications of pneumatic retinopexy in treatment of rhegmatogenous retinal detachment.

## Patients and Methods

From January 1995. to March 1998. patients with rhegmatogenous retinal detachment were selected for pneumoretinopexy according to following criteria:

- 1) no previous surgical procedures for detachment
- 2) retinal breaks in the upper 120°
- 3) retinal breaks extended no more than to one o'clock hour
- 4) absence of proliferative retinopathy

Twenty-eight patients (17 men and 11 women) (aged 35 to 71 years) were selected for treatment. Twenty-four patients were phakic, 2 pseudophakic and 2 aphakic. 18 patients were highly myopic. These 28 patients represented 40% of all new patients with rhegmatogenous reti-

nal detachment referred to our Department. Preoperative duration of detachment was less than 10 days. Sixteen patients (57.1%) had single retinal breaks and 12 (42.9%) had multiple retinal breaks. The follow-up was at least one year.

Surgery was performed on an outpatient basis, after administration of 0.8 cc of Xylocaine subconjunctivally. 10%-povidone iodine was applied to the cornea and conjunctiva before procedure. Cryopexy was done under indirect ophthalmoscopic control. Perfluoropropane gas was injected through pars plana with a 30-gauge needle into the vitreous space. The volume was between 0.4 and 0.7 cc of pure C3F8. Postoperatively, patients were positioned head-up or tilted for three days.

**Results**

Retinal reattachment was achieved in 22 eyes (78.6%). Twenty phakic eyes (83.3%) were successfully operated, 16 of them (66.6%) were highly myopic. In the group of aphakic and pseudophakic patients the failure rate was 50% (4 eyes) and additional surgery was needed, scleral buckling or vitreoretinal surgery. Macular detachment was present in only 3 (10.7%) of all retinal detachments. In cases of more extended and highly bullous retinal detachments we chose scleral buckling procedure. Retinal redetachment was present in 4 (14.3%) phakic and

2 (7.1%) pseudophakic eyes. The formation of new holes in uninvolved retinal areas was present in 3 (10.7%) eyes and it was managed by scleral buckling procedure. Vitreous hemorrhage occurred postoperatively in 2 (7.1%) patients. Proliferative vitreoretinopathy developed in 3 (10.7%) eyes and required additional vitreoretinal surgery (Figure 2).

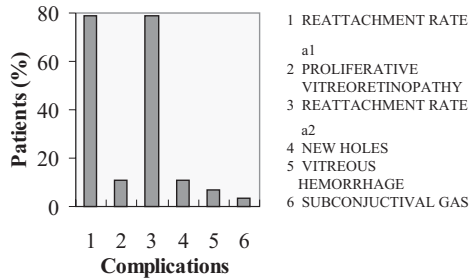


Fig. 2. Complications.

**Discussion and Conclusion**

Many complications mentioned above can be prevented by good examination (indirect ophthalmoscope!) and by mastering relatively simple surgical technique. Postoperative position and adequate patient co-operation is also very important for the successful results and good visual outcome.

In our study we did not perform drainage of subretinal fluid and paracentesis as some authors describe<sup>10</sup>. Paracentesis was not necessary because of a relatively small amount of pure C3F8 (no more than 0.7 cc) and drainage was performed only in highly bullous detachments, as part of scleral buckling procedure.

Good results were obtained in the group of phakic myopic eyes, which made 2/3 of the phakic group. Vitreous changes in myopic eyes (liquefaction) may facilitate the position of the gas bubble in vitreous cavity and minimize traction forces between the gas bubble and vitreous

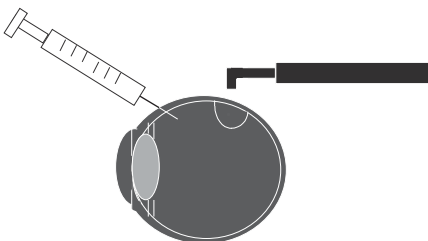


Fig. 1. CRYO – C3F8 – Head position.

strands<sup>11</sup>. Contact between gas and retinal surface is more easily obtained and retinal breaks more firmly sealed. The gas bubble moves in the vitreous regardless of immobilized head of the patient. These movements may contribute to the proliferative vitreoretinopathy development.

Although we had a small number of aphakic and pseudophakic eyes, in this group results were disappointing. Prima-

ry scleral buckling procedure may be a better choice for these patients. Proliferative vitreoretinopathy is still a major problem in both groups with very high percentage (10.7%).

Pneumatic retinopexy as a primary procedure is a good choice in selected cases of initial retinal detachments in phakic eyes with preserved macular function.

## REFERENCES

1. ABECIA, E., I. PINILLA, J. M. OLIVAN, J. M. LAROSSA, V. POLO, F. N. HONURABIA, *Retina*, 20 (200) 156. — 2. ASSI, A. C., D. G. CHARTERIS, R. W. PEARSON, Z. J. GREGOR, *Eye*, 13 (1999) 725. — 3. TRONAMBE, P. E., *Trans. Am. Ophthalmol. Soc.*, 95 (1977) 551. — 4. TRILLO, M., M. FACINO, R. TERRILE, M. CORRAZA, C. MOSCI, F. BALDI, C. A. TRILLO, *Ophthalmologica*, 207 (1993) 140. — 5. WHITACARE, M. M., M. A. MAINSTER, *Am. J. Ophthalmol.*, 110 (1990) 33. — 6. HILTON, F. G., P. TORNA-
- BE P., *Retina*, 11 (1991) 285. — 7. GANDORFER, A. A. KAMPIK, *Ophthalmologie*, 97 (2000) 367. — 8. WONG, D., A. M. ANSONS, A. H. CHIGNELL, R. YEORH, *Eye* 4 (1990) 469. — 9. STEINMETZ, R. L., A. E. KREIGER, Y. SIDICARO, *Am. J. Ophthalmol.*, 107 (1989) 191. — 10. GUNDUS, K., I. GUNALP, *Int. Ophthalmol.*, 18 (1994) 143. — 11. ALGVERE, P., K. HALLNASS, B. M. PALMQUIST, *Am. J. Ophthalmol.* 106 (1998) 400.

*D. Kovačević*

*Clinical Hospital Center Rijeka, Department of Ophthalmology, Krešimirova 42, 51000 Rijeka, Croatia*

## KOMPLIKACIJE PNEUMATSKE RETINOPEKSIJE

### SAŽETAK

Dvadeset i osam pacijenata s regmatogenom ablacijom retine tretirano je pneumatskom retinopeksijom s pomoću intravitrealnog perfluoropropan (C3F8) plina. Uspjeh je postignut u 22 (78.6%) očiju u prvoj operaciji. Većina očiju bila je miopska s jednom ili više ruptura unutar područja jednog sata periferije retine. Sve retinalne komplikacije razvile su se u donjim kvadrantima s proliferativnom vitreoretinopatijom kao jednom od najozbiljnijih komplikacija u 10.7% očiju. Nove retinalne rupture razvile su se postoperativno u 7.1% očiju.