

Ectopic Lens Extraction in Children

V. Pfeifer and K. Morela

University Eye Clinic Ljubljana, Ljubljana, Slovenia

ABSTRACT

Ectopia lentis continues to be a therapeutic challenge for ophthalmologists. It can occur as an isolated condition, after ocular trauma, in association with other ocular disorders, as part of a systemic mesodermal disease or as a complication of general metabolic disorders. Minimal subluxation of the lens may cause no visual symptoms, but in more advanced cases serious optical disturbances arise. The most important is amblyopia. Surgical treatment options include iris manipulation, lens discission, aspiration, intracapsular or extracapsular extraction, and pars plana lensectomy. The choice of surgical technique remains controversial because of poor visual results and high rate of perioperative complications, including vitreous loss and retinal detachment. We describe a surgical technique based on the use of the Cionni endocapsular tension ring, dry irrigation aspiration of lens material, centering of the capsular bag and foldable intraocular lens implantation into the bag. Eight patients were surgically treated with this surgical technique (4 boys and 4 girls, all together 11 eyes). The final BCVA after the follow-up period improved in 9 patients and it remained the same as before operation in one patient. Statistical comparison of preoperative and postoperative visual acuities showed significant improvement. On the other hand, there was no correlation between preoperative and postoperative visual acuity. This surgical procedure is an alternative approach in solving the challenging cases of ectopia lentis with good postoperative visual rehabilitation.

Introduction

Ectopia lentis, or a displaced lens, is perhaps the most common congenital lenticular anomaly other than cataract. This usually bilateral condition may be caused by an extensive malformation of zonular fibers, resulting in the displacement of the lens in a direction opposite to the area of the affected zonules. This displacement,

commonly superior or superomedial, is generally the same in both eyes. Late spontaneous dislocation of the lens into the anterior chamber or into the vitreous may be a result of ectopia lentis. Following spontaneous dislocation, a lens generally becomes cataractous, and further complications may arise with the development of elevated intraocular pressure¹.

Ectopia lentis can occur as an isolated condition², after ocular trauma³, in association with other ocular disorders (such as ectopia pupillae^{4,5}, aniridia⁶, congenital glaucoma⁷, and megalocornea⁸), as part of a systemic mesodermal disease (as in Marfan⁹ or Weill-Marchesani syndrome¹⁰), as a complication of general metabolic disorders (such as homocystinuria¹¹, hyperlysinemia, and combined xanthine and sulfite oxidase deficiency¹²). It has also been reported with Ehler-Danlos syndrome¹³, Struge-Weber syndrome¹⁴, Sticker (Marshall) syndrome¹⁵, and many others¹⁶. Both, simple ectopia and complicated ectopia lentis have strong hereditary tendencies. The former is, for the most part, transmitted as a dominant trait, whereas the latter is usually recessive. Of all systemic disorders associated with ectopia lentis, Marfan syndrome, Weill-Marchesani syndrome and homocystinuria account for over 75% of the observed lens displacements¹⁷.

Ectopia lentis continues to be a therapeutic challenge for ophthalmologists. Minimal subluxation of the lens may cause no visual symptoms, but in more advanced cases serious optical disturbances arise. The most important is amblyopia. Indications for lens surgery include, besides uncorrectable visual acuity, dislocation of the lens to the anterior chamber, lens opacity, lens-induced uveitis or glaucoma, and imminent complete luxation of the lens^{18,19}. The most common indication for surgery is bisection of the pupil by the lens^{20,21}.

Patients and Methods

We describe a surgical technique based on the use of the Cionni endocapsular tension ring^{22–25}, dry irrigation aspiration of lens material, centering of the capsular bag²⁶ and foldable intraocular lens implantation into the bag. Temporal anterior limbal approach is used. A 2.5-mm

slit knife is used to create the incision, later, two side-port incisions are performed. Depending on the extent of mydriasis intracameral adrenaline can be used. Viscoelastic is injected into the anterior chamber. Overpressure should be avoided. With a band needle anterior capsule is perforated and Utrata forceps is used for capsulorhexis. It should be smaller rather than bigger. The edge of the capsule is pulled into the centripetal direction to avoid centrifugal tear, the same as in normal congenital cataract. In case of extremely poor zonular support contra action to the pulling of Utrata forceps is performed with O’gava lens dialler. Then, hydrodissection is performed. The hydrodissection canulla is pointed under the anterior capsule and elevated while BSS is instilled exactly under the capsule to achieve a total separation of the cortex. Dry irrigation and aspiration of the lens material is done while maintaining the anterior chamber by injecting low viscosity viscoelastic. The capsular bag is maintained with viscoelastic. The iris extension hooks can be used to maintain capsular shape. Double-armed 10–0 Vy-cril suture with a straight needle is guided through the small hole in a Cionni capsular extension ring. The ring is than implanted into the capsular bag with IOL implantation forceps and Sinsky hook, rotated with the ear to the area of the biggest zonular defect and left in place. In this area conjunctiva is cut and sclera exposed. One and a half millimeter behind the limbus 27-gauge needle is introduced through the sclera into the anterior cham-

TABLE 1
PREOPERATIVE DIRECTION OF SUBLUXATION

Direction of subluxation	No. of eyes
Temporal	4
Superotemporal	2
Superior	3
Superonasal	1
Inferonasal	1

ber. From the opposite side, the straight Vycril needle is guided through the paracentesis opening into the anterior chamber and further into the lumen of 27-gauge needle. Both needles are pulled out. The procedure is repeated with second Vycril needle. The sutures are tied and Cionni ring and the capsule centered.

The foldable acrylic IOL is implanted into the bag. The lens is folded with haptics downwards and the haptics are captured between the optics. As the IOL unfolds the haptics are led directly into the capsular bag. The IOL canters perfectly in the bag. Careful irrigation and aspiration of the viscoelastic is performed. The incision is, if needed, sutured. At the end of the procedure the Vancomycin is injected.

With mentioned surgical technique 8 patients were surgically treated (4 boys and 4 girls, all together 11 eyes). The mean age at the time of surgery was 7.1 years (Table 1 and 2).

Results

The final BCVA after the follow-up period improved in 9 patients and it remained the same in one patient. In one

eye amblyopia was detected before surgery. There were no serious complications intraoperatively or postoperatively. Most of the implanted IOLs were well centered, in only one case we noticed mild, asymptomatic decentring. Follow-up times ranged between 2 and 21 months (mean 10.5). Statistical comparison of preoperative and postoperative visual acuities showed significant improvement (Fig. 1.). On the other hand, there was no

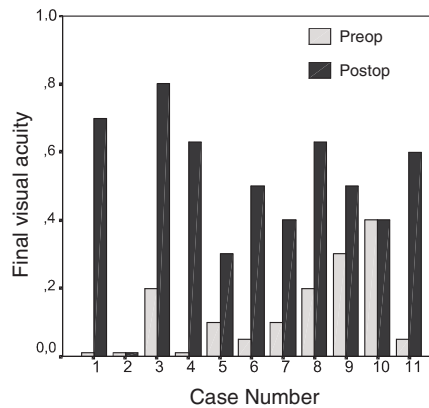


Fig. 1. Statistical comparison of preoperative and final postoperative visual acuities after the follow-up period.

TABLE 2
PREOPERATIVE AND POSTOPERATIVE FINDINGS

Patient No.	Age at surgery (yr)	BCVA before surgery	BCVA after surgery	Final BCVA	Follow-up (mo)
1	6	CF	0.2	0.7	21
	6	CF	CF	CF	19
2	6	0.2	0.3	0.8	20
	8	CF	0.7	0.63	2
3	5	0.1	0.1	0.3	2
	5	0.05	0.3	0.5	7
4	4	< 0.1	0.3	0.4	2
5	11	0.2	0.5	0.63	2
6	13	0.3	0.4	0.5	14
7	7	0.4	0.4	0.4	17
8	6	0.05	0.2	0.6	9

BCVA – Best corrected visual acuity, CF – Counting fingers

correlation between preoperative and postoperative visual acuity. However, the results of this study should be viewed in respect to a small number of cases.

Conclusion

This surgical procedure presents an alternative approach in solving challeng-

ing cases of ectopia lentis with good postoperative visual rehabilitation. Because of a risk of amblyopia in young children, ectopia lentis should be regularly reassessed in these patients and surgical procedure considered as soon as uncorrectable optical errors become significant.

REFERENCES

1. GRESSEL, M. G.: Lens induced glaucoma. In: Tasman W, Jaeger E. A. (Eds.): Duane's clinical ophthalmology. (Lippincott-Raven, Philadelphia, 1997).
2. SELAND, J. H., Acta Ophthalmol., 51 (1973) 520.
3. ROSENBAUM, L. J., S. M. PODOS, Am J Ophthalmol., (1976) 1095.
4. SPENCER, W. H.: Ophthalmic Pathology. (W. B. Saunders Co, Philadelphia, 1985)
5. BYLES, D. B., K. K. NISCHAL, H. CHENG, Ophthalmology, 105 (1998) 1331.
6. DAVID, R., L. Mac BEATH, T. JENKINS, Br J Ophthalmol., 62 (1978) 118.
7. KWITKO, M.: Glaucoma in Infants and Children. (Appleton Century Crofts, New York, 1973).
8. KRAFT, S. P., G. F. JUDISCH, D. M. GRAYSON, J Pediatr Ophthalmol Strabismus, 21 (1984) 190.
9. MAUMENEE, I. H., Trans Am Ophthalmol Soc., 79 (1981) 684.
10. JENSEN, A. D., H. E. CROSS, D. PATON, Am J Ophthalmol., 77 (1974) 261.
11. CROSS, H. E., A. D. JENSEN, Am J Ophthalmol., 75 (1973) 405.
12. JOHNSON, J. L., S. K. WADMAN: Molybdenum cofactor deficiency. In: Scriver CR, Bedaut AL, Sly WS, Valle D, eds. The Metabolic Basis of Inherited Diseases, (McGraw Hill, New York, 1989).
13. MAY, M. A., G. R. BEAUCHAMP, J Pediatr Ophthalmol Strabismus, 24 (1987)
14. FILATO, V., D. R. GUYER, Ann Ophthalmol., 24 (1992) 260.
15. SCHLOTE, T., M. VÖLKER, M. KNORR, H. J. THIEL, Klin Monatsbl Augenheilkd., 210 (1997) 227.
16. HILES, D. A., L. A. KITTY: Disorders of the lens. In: Isenberg SJ, ed. The Eye in Infancy. (St. Louis, CV, Mosby, 1994).
17. CROSS, H. E.: Differential diagnosis and treatment of dislocated lenses. In: Bergsma D, Bron AJ, Cotlier E, eds. The Eye and Inborn Errors of Metabolism. (New York, Alan R Liss, 1976).
18. CHANDLER, P. A., Arch Ophthalmol., 71 (1964) 765.
19. NELSON, L. B., I. H. MAUMENEE, Surv Ophthalmol., 27 (1982) 143.
20. SALEHPOUR, O., T. LAVY, J. LEONARD, D. TAYLOR, J Pediatr Ophthalmol Strabismus, 33 (1996) 8.
21. YU, Y. S., Y. H. KANG, K. H. LIM, Ophthalmic Surg Lasers, 28 (1997) 1006.
22. CIONNI, R. J., R. H. OSHER, J. Cataract Refract Surg., 21 (1995) 245.
23. CIONNI, R. J., R. H. OSHER, J. Cataract Refract Surg., 24 (1998) 1299.
24. GIMBEL, H. V., R. SUN, J. P. HESTON, Ophthalmic Surg Lasers, 28 (1997) 273.
25. DIETLEIN, T. S., P. C. JACOBI, W. KONEN, G. K. KRIEGLSTEIN, J. Cataract Refract Surg., 26 (2000) 937.
26. MERRIAM, J. C., L. ZHENG, J. Cataract Refract Surg., 23 (1997) 1295.

V. Pfeifer

University Eye Clinic Ljubljana, Zaloška 29A, 1000 Ljubljana, Slovenia

EKSTRAKCIJA EKTOPIČNE LEĆE U DJECE

S A Ž E T A K

Ectopia lentis i dalje predstavlja terapijski izazov u oftalmologiji. Može se javiti kao izolirani slučaj, nakon očne traume, u vezi s drugim oftalmološkim poremećajima, kao dio sistemske mezodermalne bolesti ili kao komplikacija sistemskih metaboličkih poremećaja. Minimalna subluksacija leće ne mora uzrokovati poremećaje vida, no u uznapredovalim slučajevima javljaju se jaki poremećaji, a najznačajnija je ambliopija. Kirurški tretmani uključuju manipulaciju šarenicom, izrezivanje leće, aspiraciju, intrakapsularnu ili ekstrakapsularnu ekstrakciju i pars plana lensektomiju. Izbor kirurškog postupka kontroverzan je zbog slabih vidnih rezultata i čestih postoperativnih komplikacija koje uključuju gubitak vitreusa i ablaciju mrežnice. U ovom radu opisujemo kirurški postupak koji se zasniva na upotrebi Cionni edokapsularnog tenzijškog prstena, suhoj irigacijskoj aspiraciji materijala leće, centriranju kapsularne vrećice i implantaciji foldable intraokularne leće u vrećicu. Osam pacijenata tretirano je ovom metodom (4 dječaka i 4 djevojčice, ukupno 11 očiju). Konačna vidna oštrina (BCVA) nakon praćenja popravila se kod 9 pacijenata, a ostala je nepromijenjena kod jednog pacijenta. Statističkom usporedbom preoperativnih i postoperativnih vidnih oštrina utvrđen je znatan napredak. S druge strane, nije utvrđena korelacija između preoperativne i postoperativne vidne oštrine. Ovaj kirurški postupak predstavlja alternativni pristup rješavanju teških slučajeva ectopie lentis s dobrim postoperativnim oporavkom vida.