

# Brachytherapy – Optional Treatment for Choroidal Neovascularization Secondary to Age-Related Macular Degeneration

B. Šarić, J. Šikić, D. Katušić and N. Vukojević

Department of Ophthalmology, School of Medicine, University of Zagreb, Zagreb, Croatia

## ABSTRACT

*Age-related macular degeneration (ARMD) presents the main cause of irreversible loss of central vision in older population, due to a progressive neuroretinal damage and damage of retinal pigment epithelium of foveal area. This observation emphasizes the insufficiency of all presently used therapeutic procedures. Therefore, investigation has been conducted at the University Eye Clinic Zagreb for the last three years testing the effects of brachytherapy with direct episcleral application of ruthenium applicators to the posterior pole of the globe. Forty-two patients aged 58–79 were followed for a min. of 12 months. During this period their central visual acuities remained stable. Six patients showed one-line improvement of visual acuity and 8 patients showed no changes. Twenty-one patient lost 1–2 lines of visual acuity and 7 patients lost more than 2 lines. According to this we can conclude that patients treated with brachytherapy showed significantly better results compared to the control subjects, which is very encouraging.*

## Introduction

Age-related macular degeneration (ARMD) presents the leading cause of blindness. Patients suffering from this macular disease are handicapped in a way that they cannot read, write or watch television. This pathologic process is associated with the development of choroidal neovascular membrane (CNVM). These »new« blood vessels have been reported

to leak fluid, blood and lipids, which is followed by fibrovascular scarring beneath and into the retina, causing severe irreversible loss of vision<sup>1–4</sup>. Although most patients suffer from a slowly developing atrophic form of age-related macular degeneration, 10% of patients have a rapidly evolving neovascular form, and among them 25% develop the same neovascular process in the fellow eye<sup>1,4–6</sup>.

Laser photocoagulation is the only proven treatment of this disease; however, less than 20% of patients with well-demarcated »classic« CNVMs are eligible for this treatment<sup>7–11</sup>. Photocoagulation results in the destruction of the overlying retina. Immediately after laser treatment patients develop dense and poorly tolerated central scotoma and experience an immediate and permanent decline in central visual acuity. This kind of treatment is also associated with an unacceptably high persistence and recurrence rate of CNVM<sup>7,11–13</sup>.

These factors and the progressive aging of our society place ARMD in the center of interest of numerous medical investigations, which have been trying to develop new modalities of treatment for CNVMs. These new treatment modalities can be grouped in four major categories: photodynamic therapy, pharmacologic inhibition of CNVM formation with antiangiogenic agents, surgical intervention, and radiation therapy. All of these experimental treatment modalities are directed toward destroying CNVMs, and they all show limitations<sup>2,11,14</sup>.

Relatively low levels of ionizing radiation have been used to induce regression of choroidal hemangiomas and other vascular malformations as well as choroidal tumors without destruction of the overlying retina<sup>15,16</sup>. Ionizing radiation may prevent proliferation of endothelial cells of newly formed subretinal capillaries as well as induce obliteration of the aberrant new vessels<sup>17</sup>.

The potential of radiation to affect regression of subretinal neovascularization and its components has led to multiple clinical trials<sup>18–24</sup>. Evaluated were radiation doses, dose rates, and radiation delivery systems.

Our experience with implant brachytherapy led us to expect that the use of ophthalmic plaques might decrease com-

plications caused by the radiation dose delivered to most normal ocular (neovascular glaucoma, ischemic optic neuropathy, choroidal teleangiectasia, venous occlusion, edematous retinopathy with exudation and choroidal hematoma), periocular, and intracranial structures, compared to the external beam radiotherapy<sup>25–28</sup>. Presented are methods of application and our preliminary clinical findings after ophthalmic plaque radiotherapy for CNVM secondary to age-related macular degeneration.

## Patients and Methods

A prospective clinical trial was performed. Forty-two patients with subretinal CNVM were referred to brachytherapy because they were untreatable according to Macular Photocoagulation Study criteria. Control group consisted of 27 patients who refused laser or irradiation therapy. To be included in the study group, patients had to fulfill the following eligibility criteria: (1) angiographic evidence of classic or occult CNVM due to age-related macular degeneration; (2) involvement of the foveal avascular zone; (3) best-corrected visual acuity of 0.05 or better; and (4) CNVM not closer than 1 mm to the edge of the optic disc.

All the patients had developed classic or occult CNVM and had noted recent visual loss or metamorphosis before they were included in this study. The study group consisted of 42 patients (20 men and 22 women). The mean age was 70 years (range, 58 to 79 years). Min. follow-up period was 12 months after which patients showed stabilized central visual acuity. According to fluorescein angiography performed before surgery, 24 patients were classified as occult and 18 as classic CNVM. The control group was very similar to the study group according to age, sex and CNVM type distribution (Table 1).

**TABLE 1**  
 PATIENTS' DEMOGRAPHIC AND RADIOTHERAPEUTIC CHARACTERISTICS

PATIENT No./Age/Sex	CNVM Type	Retinal depth	Dose of Ruthenium 106 (Gy)
1. /58/ M	Occult	1,7 mm	24
2. /62/ M	Occult	1,4 mm	24
3. /61/ F	Occult	1,9 mm	25
4. /78/ M	Occult	1,9 mm	26
5. /79/ F	Occult	1,9 mm	25
6. /75/ F	Occult	2,0 mm	26
7. /70/ F	Occult	1,9 mm	25
8. /71/ F	Occult	1,7 mm	24
9. /59/ M	Occult	1,2 mm	26
10. /59/ F	Occult	1,4 mm	26
11. /65/ M	Occult	1,7 mm	26
12. /71/ F	Occult	1,9 mm	24
13. /69/ M	Occult	1,2 mm	24
14. /68/ M	Occult	1,3 mm	25
15. /64/ M	Occult	1,7 mm	25
16. /75/ F	Occult	1,9 mm	25
17. /72/ F	Occult	1,9 mm	24
18. /77/ M	Occult	2,0 mm	26
19. /79/ M	Occult	1,2 mm	26
20. /74/ F	Occult	1,4 mm	25
21. /68/ F	Occult	1,8 mm	26
22. /67/ F	Occult	1,5 mm	24
23. /58/ M	Occult	1,6 mm	24
24. /59/ F	Occult	1,9 mm	25
25. /75/ M	Classic	1,6 mm	24
26. /63/ F	Classic	1,4 mm	26
27. /79/ F	Classic	2,1 mm	24
28. /77/ M	Classic	2,3 mm	25
29. /73/ M	Classic	1,9 mm	25
30. /78/ F	Classic	1,8 mm	25
31. /65/ M	Classic	1,5 mm	26
32. /69/ F	Classic	2,0 mm	26
33. /71/ F	Classic	2,0 mm	26
34. /78/ F	Classic	2,1 mm	24
35. /73/ M	Classic	1,9 mm	24
36. /75/ M	Classic	1,7 mm	25
37. /64/ F	Classic	1,8 mm	24
38. /69/ M	Classic	1,6 mm	25
39. /75/ F	Classic	1,8 mm	25
40. /77/ M	Classic	1,9 mm	26
41. /73/ F	Classic	2,1 mm	24
42. /71/ F	Classic	2,0 mm	25

Each patient underwent a complete initial ophthalmic examination. After refraction (best-corrected visual acuity) and applanation tonometry, direct/indirect, contact/noncontact, slit-lamp ophthalmoscopic techniques were used as required. Fundus photography as well as fluorescein angiography were performed at the initial visit and again immediately before surgery, because of the rapid growth of CNVM. Smallness of these lesions required standardized A-scan and interpolated A/B scan ultrasonography to measure retinal depth (chorioretinal thickness at the macula). Dosimetric calculations showed very little difference between average retinal depth and default depth of 2 mm.

Ruthenium 106 ophthalmic applicator model CCB (Bebig/Berlin-Germany) was used. Dosimetric calculations were performed according to the Collaborative Ocular Melanoma Study protocol<sup>29–32</sup> in collaboration with medical physicists.

To facilitate surgical procedure plaque implantation was performed under general anesthesia. After conjunctival peritomy and opening of Tenon's fascia in temporal quadrants, sterile radioactive applicator was gently slid underneath the lateral rectus muscle toward the posterior sclera correspondent to macula. The posterior edge of the applicator was gently pushed toward the optic nerve. Episcleral sutures were placed through the suture eyelets to secure the plaque. Indirect ophthalmoscopy and transscleral illumination were used to confirm the position of the applicator. Subconjunctival anesthetic, antibiotic, and corticosteroid was given after the closure of the conjunctiva. Surgical removal of the applicator was performed under local anesthesia.

Patients were treated with a maximum dose of 24–26 Gy (mean, 25 Gy) to the overlying retina, in a period of 22–48 hours (mean, 36 hours). Radiation side effects were not registered. The only postoperative complication in our study was

transient diplopia which developed in 6 patients, but diminished within a month.

Ophthalmic examinations consisting of visual acuity check, ophthalmoscopy, fundus photography and fluorescein angiography were scheduled to be performed at a minimum of 3-month intervals for at least one year.

## Results

Ophthalmic plaque irradiation was found to be capable of delivering the efficacious dose of irradiation to the area of choroidal neovascular membrane without exceeding the threshold dose considered to cause radiation retinopathy or other radiation complications in normal human eyes described in other researches<sup>28,33–35</sup>.

Since June 1997, we have treated 42 patients with low-dose radiotherapy for classic and occult CNVM. Presented are results of 24 patients with occult and 18 patients with classic subretinal choroidal neovascularization followed for a period of min. 12 months (Table 2).

After 12 months, ophthalmoscopy and fluorescein angiography examinations revealed exudative macular lesions marked as improved, stable or progressive. Improved lesions were defined as having decreased or resolved components (hemorrhage, exudate, and fluid). Decreased blood flow was observed in classic neovascular membranes, while lower fluorescence was observed in occult neovascular membranes. Stable lesions were found to be relatively unchanged or only slightly enlarged with minimal regression of components. Progressive lesions were found increased in size or with more components. Overall, 23 (54.8%) lesions were noted stable or improved after the follow-up period of 12 months following brachytherapy. In the same period, occult CNVM group showed better results, with 16 out of 24 (66.6%) lesions being stable or improved, than classic CNVM group,

**TABLE 2**  
RESULTS OF RUTHENIUM 106 PLAQUE RADIOTHERAPY FOR CNVM

RADIOTHERAPY GROUP				CONTROL GROUP			
No. of patients	CNVM status	Visual acuity	No. of patients	CNVM status	Visual acuity		
	Initial	/12 mos	In/12 mos	Initial	/12 mos	In/12 mos	
1.	Occult	Improve	0.4/0.6	1.	Occult	Progress	0.3/0.1
2.	Occult	Stable	0.05/0.05	2.	Occult	Stable	0.6/0.4
3.	Occult	Improve	0.3/0.3	3.	Occult	Progress	0.5/0.2
4.	Occult	Stable	0.05/0.05	4.	Occult	Progress	0.7/0.2
5.	Occult	Improve	0.6/0.5	5.	Occult	Progress	0.7/0.3
6.	Occult	Progress	0.7/0.5	6.	Occult	Progress	0.7/0.05
7.	Occult	Progress	0.2/0.1	7.	Occult	Progress	0.4/0.2
8.	Occult	Stable	0.4/0.3	8.	Occult	Stable	0.6/0.5
9.	Occult	Progress	0.5/0.3	9.	Occult	Stable	0.2/0.2
10.	Occult	Progress	0.6/0.4	10.	Occult	Progress	0.5/0.3
11.	Occult	Stable	0.4/0.3	11.	Occult	Progress	0.8/0.3
12.	Occult	Progress	0.3/0.1	12.	Occult	Progress	0.6/0.2
13.	Occult	Improve	0.5/0.5	13.	Occult	Stable	0.4/0.4
14.	Occult	Progress	0.6/0.2	14.	Occult	Stable	0.5/0.5
15.	Occult	Stable	0.4/0.2	15.	Occult	Stable	0.3/0.3
16.	Occult	Improve	0.5/0.4	16.	Classic	Stable	0.5/0.4
17.	Occult	Improve	0.3/0.3	17.	Classic	Progress	0.6/0.3
18.	Occult	Stable	0.05/0.05	18.	Classic	Progress	0.8/0.5
19.	Occult	Progress	0.2/0.05	19.	Classic	Progress	0.3/0.1
20.	Occult	Stable	0.2/0.3	20.	Classic	Progress	0.6/0.4
21.	Occult	Improve	0.3/0.7	21.	Classic	Progress	0.5/0.05
22.	Occult	Stable	0.5/0.2	22.	Classic	Progress	0.8/0.1
23.	Occult	Progress	0.3/0.7	23.	Classic	Progress	0.7/0.1
24.	Occult	Stable	0.3/0.1	24.	Classic	Progress	0.5/0.3
25.	Classic	Improve	0.5/0.7	25.	Classic	Stable	0.6/0.4
26.	Classic	Stable	0.3/0.3	26.	Classic	Progress	0.7/0.1
27.	Classic	Progress	0.6/0.1	27.	Classic	Progress	0.6/0.1
28.	Classic	Progress	0.7/0.4				
29.	Classic	Stable	0.2/0.2				
30.	Classic	Improve	0.5/0.7				
31.	Classic	Progress	0.3/0.1				
32.	Classic	Stable	0.2/0.1				
33.	Classic	Progress	0.5/0.3				
34.	Classic	Progress	0.6/0.4				
35.	Classic	Progress	0.4/0.1				
36.	Classic	Stable	0.5/0.4				
37.	Classic	Stable	0.7/0.6				
38.	Classic	Progress	0.3/0.05				
39.	Classic	Progress	0.3/0.1				
40.	Classic	Progress	0.4/0.05				
41.	Classic	Progress	0.6/0.1				
42.	Classic	Progress	0.3/0.1				

with 7 out of 18 (38.8%) lesions being stable or improved (Figure 1). In control group no improvement was registered and only 8 out of 27 (29.6%) lesions were found to be stable (Figure 2). By comparing radiotherapy and control group statistically significant difference was found ( $\chi = 4.20 / p < 0.05$ ). During the follow-up period, in radiotherapy group 14 eyes (58.3%) preserved or improved for 1 or more lines baseline visual acuity, in contrast to control group where only 3 eyes (11.1%) preserved baseline visual acuity and no eyes showed improvement at all (Figure 3). The two groups were compared according to initial visual acuities and visual acuities achieved 12 months after radiotherapy (Mann-Whitney U test and T-test for dependent samples). Statistically significant difference observed between these two groups ( $p > 0.001$ ) is certain evidence of efficacy of radiation on the improvement and stabilization of visual acuity.

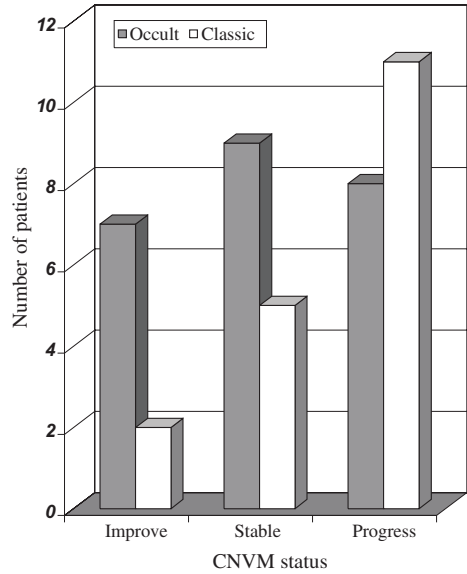


Fig. 1. CNVM status 12 months after ruthenium 106 plaque radiotherapy.

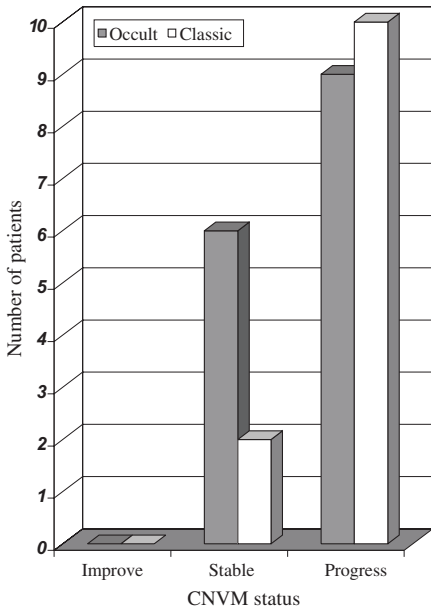


Fig. 2. CNVM status after 12 months follow-up in control group.

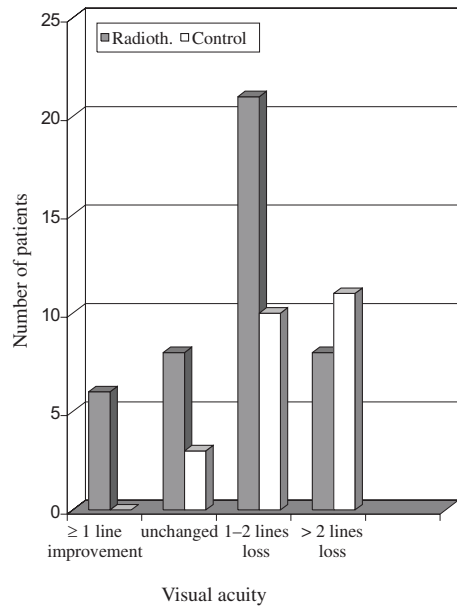


Fig. 3. Visual acuity results in ruthenium 106 plaque radiotherapy group vs. control group after 12 months follow-up.

Not one patient experienced an immediate irreversible loss of central vision or complained of scotoma formation associated with laser treatment. After plaque radiotherapy we marked resolution of hemorrhage, exudates, and subretinal fluid. Till now, no radiation retinopathy, optic neuropathy, or cataract have been noted.

## Discussion

Low dose brachytherapy has been used to inhibit choroidal neovascularization growth and reduce scar formation. The exact mechanism has not been determined<sup>36,37</sup>. It has been suggested that radiation may affect the production of cytokines that regulate the production of new blood vessels<sup>38,39</sup>, and may directly destroy neovascular endothelial cells. Radiotherapy has also been shown to inhibit fibroblast proliferation and resultant scar formation, characteristic for the end-stage exudative macular degeneration<sup>40–42</sup>.

We have initiated a prospective clinical study on ophthalmic plaque radiotherapy for the treatment of choroidal neovascular membranes. Compared to the external beam, plaque radiotherapy de-

livers most of the radiation to the targeted macula, whereas all ocular structures outside the treatment area can be calculated to receive less irradiation<sup>20,44</sup>.

For the evaluation of this study, it is important to note that all of our patients presented with visual loss, metamorphosis, or both before treatment and most of them had improved or stabilized vision after treatment. Irradiated patients showed better visual acuity and retinal status outcome than the control group. We also marked better results in occult CNVM group than in classic CNVM group<sup>43</sup>.

This study clearly demonstrates that brachytherapy can be used as an optional treatment for CNVM in ARMD. It is a unilateral treatment that allows a large dose of irradiation to be delivered to the macula with less irradiation to normal ocular structures, compared to the external beam radiotherapy. Unlike laser photocoagulation, brachytherapy can be used for subfoveal, both occult and classic, CNVM. Also, patients do not experience an immediate irreversible visual loss and scotoma onset.

## REFERENCES

1. BRESSLER, N. M., S. B. BRESSLER, S. L. FINE, *Surv. Ophthalmol.*, 32 (1988) 375. — 2. GARCIA LAYANA, A., *Rev. Med. Univ. Navarra*, 42 (1998) 42. — 3. WEINBERGER, A. W., S. WOLF, T. KUBE, U. SOLBACH, H. DOBBERSTEIN, U. M. SCHLEICHER, B. KIRCHHOF, *Klin. Monatsbl. Augenheilkd.*, 214 (1999) 96. — 4. GUYER, D. R., S. L. FINE, M. G. MAGUIRE, *Arch. Ophthalmol.*, 104 (1986) 702. — 5. LIEBOWITZ, H. M., D. E. KRUEGER, L. R. MAUNDER, *Surv. Ophthalmol.*, 24 (1980) 335. — 6. KLEIN, B. E., R. KLEIN, *Arch. Ophthalmol.*, 100 (1982) 571. — 7. BERSON, A. M., P. T. FINGER, U. CHAKRAVARTHY, *Semin. Radiat. Oncol.*, 9 (1999) 155. — 8. Macular Photocoagulation Study Group., *Arch. Ophthalmol.*, 109 (1991) 1109. — 9. Macular Photocoagulation Study Group., *Arch. Ophthalmol.*, 109 (1991) 1220. — 10. Macular Photocoagulation Study Group., *Arch. Ophthalmol.*, 112 (1994) 480. — 11. CIULLA, T. A., R. P. DANIS, A. HARRIS, *Surv. Ophthalmol.*, 43 (1998) 134. — 12. Macular photocoagulation Study Group., *Arch. Ophthalmol.*, 112 (1994) 489. — 13. YANNUZZI, L. A., *Arch. Ophthalmol.*, 112 (1994) 462. — 14. SHIRAGA, F., I. TAKASU, C. SHIRAGAMI, *Semin. Ophthalmol.*, 13 (1998) 31. — 15. MADREPERLA, S. A., J. L. HUNGERFORD, N. P. PLOWMAN, *Ophthalmology*, 104 (1997) 1773. — 16. FLICKINGER, J. C., B. E. POLLOCK, D. KONDZIOLKA, L. D. LUNSFORD, *Int. J. Radiat. Oncol. Biol. Phys.*, 36 (1996) 873. — 17. BERGINK, G. J., A. F. DEUTMAN, J. F. VAN DEN BROEK, R. W. VAN DER MAAZEN, *Graefes. Arch. Clin. Exp. Ophthalmol.*, 232 (1994) 591. — 18. CHAKRAVARTHY, U., R. F. HOUSTON, D. B. ARCHER, *Br. J. Ophthalmol.*, 77 (1993) 265. — 19. THOLEN, A. M., A. MEISTER, P. P. BERNASCONI, E. P. MESSMER, *Klin. Monatsbl. Augenheilkd.*, 216 (2000) 112. — 20. FINGER, P. T., A. BERSON, D. A. SHERR, *Ophthalmology*, 103 (1996) 878. — 21. BERSON, A. M., P. T. FINGER, D. A. SHERR, *Int. J. Radiat. Oncol. Phys.*, 36 (1996) 861. — 22. FRIERE, J., W. A. LONGTON, C. T. MIYAMOTO, L. W.



- BRADY, Int. J. Radiat. Oncol. Phys., 36 (1996) 857. — 23. YONEMOTO, L. T., J. D. SLATER, E. J. FRIEDRICHSEN, Int. J. Radiat. Oncol. Phys., 36 (1996) 867. — 24. HART, P. M., V. CHAKRAVARTHY, G. MACKENZIE, Brit. J. Ophthalmol., 80 (1996) 1046. — 25. FINGER, P. T., Surv. Ophthalmol., 42 (1997) 215. — 26. JAAKKOLA, A., J. HEIKKONEN, P. TOMMILA, Graefes. Arch. Clin. Exp. Ophthalmol., 236 (1998) 24. — 27. FINGER, P. T., A. BUFFA, S. MISHRA, Ophthalmology, 101 (1994) 256. — 28. MAUGET-FAYSSE, M., R. COQUARD, C. FRANCAIS-MAURY, D. MILEA, C. CHIQUET, P. MARTIN, P. ROMESTAING, J. P. ROMANET, J. P. GERARD, J. Fr. Ophthalmol., 23 (2000) 127. — 29. KEPKA, A. G., P. M. JOHNSON, R. W. KLINE, Med Phys., 15 (1988) 375. — 30. LUXTON, G., Med. Phys., 15 (1988) 397. — 31. CHIU-TSAO, S. T., L. L. ANDERSON, Med. Phys., 18 (1991) 449. — 32. MEIGOONI, A. S., S. SABNIS, R. NATH, Endocuriether. Hypertherm. Oncol., 6 (1990) 107. — 33. SPAIDE, R. F., A. LEYS, B. HERRMANN-DELEMAZURE, P. STALMANS, M. TITTL, L. A. YANNUZZI, K. M. BURKE, Y. L. FISHER, K. B. FREUND, D. R. GUYER, J. S. SLAKTER, J. A. SORENSON, Ophthalmology, 106 (1999) 2254. — 34. MAUGET-FAYSSE, M., C. CHIQUET, D. MILEA, P. ROMESTAING, J. P. GERARD, P. MARTIN, F. KOENIG, Br. J. Ophthalmol., 83 (1999) 923. — 35. ARCHER, D. B., T. A. GARDINER, Curr. Opin. Ophthalmol., 5 (1994) 59. — 36. BICKNELL, R., A. L. HARRIS, Eur. J. Cancer, 27 (1991) 781. — 37. HART, P. M., D. P. ARCHER, V. CHAKRAVARTHY, Br. J. Ophthalmol., 79 (1995) 562. — 38. DEGOWIN, R. L., L. J. LEWIS, J. C. HOAK, J. Lab. Clin. Med., 84 (1974) 42. — 39. JOHNSON, L. K., J. P. LONGENECKER, L. F. FAJARDO, Anal. Quant. Cytol., 4 (1982) 188. — 40. FUKS, Z., R. S. PERSAUD, A. ALFIERI, Cancer. Res., 54 (1994) 2582. — 41. HAIMOVITZ-FRIEDMAN, A., I. VLODAVSKY, A. CHAUDHURI, Cancer. Res., 51 (1991) 2552. — 42. HALLAHAN, D. E., S. VIRUDACHALAM, J. L. SCHWARTZ, Radiat. Res., 128 (1992) 345. — 43. HASS, A., U. PRETTENHOFER, M. STUR, R. HANSELMAYER, B. FEIGL, A. BERGHOLD, G. LANGMANN, J. FAULBORN, Ophthalmology, 107 (2000) 1358. — 44. BERGNIK, G. J., C. B. HOYNG, R. W. VAN DER MAAZEN, A. F. DEUTMAN, W. A. VAN DALL, Doc. Ophthalmol., 97 (1996) 61.

B. Šarić

*Clinical Hospital Center Zagreb, Department of Ophthalmology, Kišpatičeva 12  
10000 Zagreb, Croatia*

## **BRAHITERAPIJA – LIJEČENJE IZBORA U TRETMANU CNVM KOD ARMD**

### **S A Ž E T A K**

ARMD (Age-Related Macular Degeneration) predstavlja vodeći uzrok nepovratnog gubitka centralnog vida u starijoj populaciji, što nastaje zbog progresivnog oštećenja neuroretine i retinalnog pigmentnog epitela foveolarnog područja. Ova činjenica govori o neefikasnosti danas poznatih metoda liječenja. Posljednje tri godine provodimo brahiterapiju direktnom episkleralnom implantacijom rutenijskih aplikatora u projekciji stražnjeg pola bulbosa. Nakon provedenog tretmana pratili smo 42 pacijenta u dobi od 58–79 godina, kroz period od minimalno 12 mjeseci, nakon kojih dolazi do konačne stabilizacije centralne vidne oštine. Uočili smo poboljšanje centralne vidne oštine za 1 ili više redova kod 6 pacijenata, a bez promjene bilo je 8 pacijenata. Pogoršanje vidne oštine od 1–2 reda registrirano je kod 21 pacijenta, te za više od 2 reda kod 7 pacijenata. Ovi su rezultati ohrabrujući jer su značajno bolji od onih u kontrolnoj grupi.