

Severe Trichinellosis Cured with Pulse Doses of Glucocorticoids

B. Vojniković¹, N. Brnčić², G. Zamolo³, R. Budiselić⁴, S. Njirić¹
and S. Novak⁴

¹ Department of Ophthalmology, Clinical Hospital Center, Rijeka, Croatia

² Department of Infectious diseases, Clinical Hospital Center Rijeka, Croatia

³ Institute of Pathology, Medical faculty Rijeka, Croatia

⁴ Department of Internal Medicine, Clinical Hospital Center, Rijeka, Croatia

ABSTRACT

Trichinellosis is a worldwide zoonotic disease caused by a nematode Trichinella spiralis. We studied a case of Trichinella spiralis infection with severe eye involvement, febrile condition, generalised malaise and muscular weakness in a young female patient. Comprehensive ophthalmologic, infectologic, neurological and immunologic examinations including electro diagnostic tests and CT scan of the head were performed, but the diagnosis was confirmed only by histological examination of biopsy specimens of skeletal muscle. The patient did not respond to standard corticosteroid therapy and improved only after pulse doses of 1000 mg methylprednisolon. Although most authors recommend moderately high doses of corticosteroids in the treatment of Trichinellosis, in severe cases extremely high doses might be necessary.

Introduction

Trichinellosis is a worldwide zoonotic disease closely related to cultural and dietary habits caused by a nematode *Trichinella* spp. Human infection is acquired through ingestion of undercooked meat containing infective encysted larvae¹. Traumatic and immunological alterations are responsible for the main clinical features, including diarrhea, febrile syndrome, myalgias, oculoalpebral signs and eosinophi-

lia.² There has been an increase in the number of human Trichinellosis cases in Croatia associated with war in the former Yugoslavia.

Case Report

A 25-year old female was admitted to Ophthalmologic facility after a 2-day period of eyelid oedema with spiking fever and suspicion on bilateral orbital cellulitis. Physical examination was normal except her febrile condition and eye dis-

turbances. The lids, conjunctiva and extraocular muscles were inflamed with severe conjunctival vascular congestion and bilateral protrusion (Figure 1). Fundus examination showed bilateral vasculitis with retinal haemorrhages (Figure 2). Orbital computerised tomography (CT) revealed inflamed and extraordinary thick extraocular muscles (Figure 3). Laboratory parameters on admission showed: Erythrocyte sedimentation rate (ESR) 27, hemoglobin 13,3 g/dL, white blood cells (WBCs) $7.5 \times 10^9/L$ with 76% neutrophils, 13% lymphocytes, 5% eosinophils, 4% monocytes, 2% basophils, alanine transaminase (ALT) 41.2 IU/L (normal < 31), aspartat transaminase (AST) 30.7 IU/L (normal < 31.0) lactic dehydrogenase (LDH) 230.5 IU/L (normal < 225), creatine kinase (CK) 212.3 IU/L (normal < 145.0). Alkaline phosphatase, amylase, bilirubin, urea, creatinine, prothrombine time, electrolytes, blood glucose, urin analysis showed normal values.

Following admission, antibiotic therapy along with oral 64 mg methyl-prednisolon and parabolbar injections of methyprednisolon acetate (Depo-Medrol) at 40 mg was initiated. In spite of administered therapy, the high fever persisted for another days, her condition was worsening with the appearance of headache, generalized malaise, dysphagia, weakness of masseters and neck muscles. On fifth hospital day, neurological, infectological and immunological examination were performed.

Anamnestic epidemiological data directed to Trichinellosis and some similar cases in neighboring was categoric negative. In spite of normal eosinophils, negative epidemiological history, and non-respond to corticosteroid therapy, serologic examination for Trichinellosis was indicated. In meantime, high fever persisted, weakness of muscles was progressing to lumbal region and patient was unable to walk. Electromyoneurographic (EMNG)

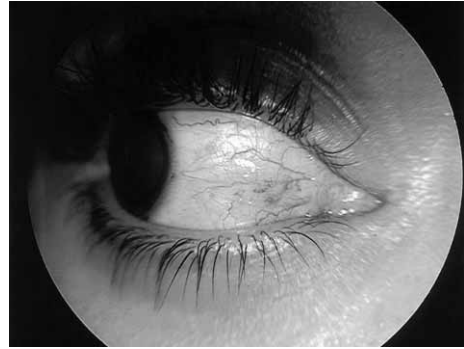

Fig. 1. Conjunctival vascular congestion over a thickened medial rectus muscle

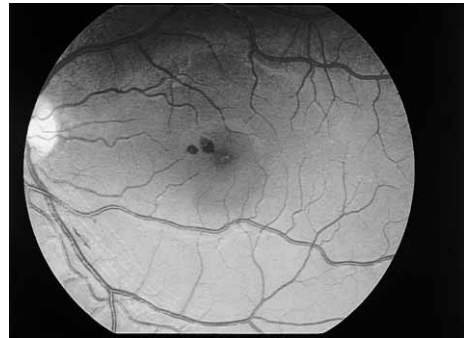

Fig. 2. Fundus photography showing vasculitis and retinal haemorrhages

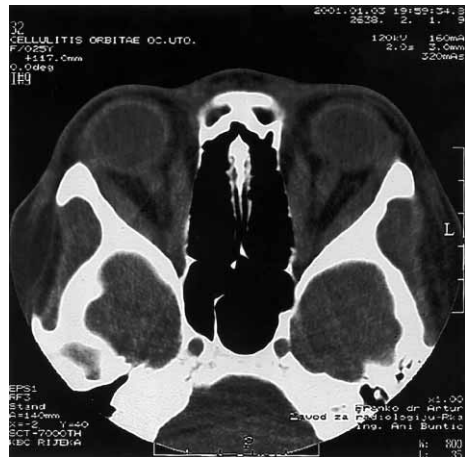

Fig. 3. Orbital axial CT scan prior to therapy showing bilateral proptosis and enormous extraocular muscles enlargement

analysis revealed a primary myogenic pattern. Electrocardiogram (ECG) examination was normal. On 13. hospital day she was transferred to Department for immunologic disorders with the diagnosis of possible acute polymyositis syndrome. Pulse dose of 1000 mg methylprednisolon was started and fever critically fell down. Enzyme-linked immunosorbent assay (ELISA) IgM *Trichinella* test was positive and IgH highly suspicious.

Elevated serum creatine kinase and lactic dehydrogenase levels indicated considerable muscle involvement.³

Pathohistological skin (Figure 4) and striated muscle (Figure 5) biopsy finding was as follows:

»Histologically skin is built of normal epidermis with slightly hyaline thickened basal membrane. Around teleangiectatic capillaries in papillary dermis fairly extensive mononuclear infiltration can be noticed.

Muscle tissue is built of variably wide muscle fibres among which cysts with encapsulated parasites are found. Among muscle fibres in perimysium inflamed infiltrates and eosinophil granulocytes are found. Histological finding indicates Trichinellosis.«

In that way definitive diagnosis was established.

On further inquiry, it was revealed that the patient had eaten smoked pork meat in Dalmatia two weeks prior to the onset of symptoms.

Following initiating pulse dose of corticosteroids, gradual but constant improvement of clinical and laboratory findings was observed. Two weeks later orbital CT scan showed completely normalized findings of extraocular muscles (Figure 6). After 28 in-hospital days the patient was discharged and steroids were tapered over the next two months.

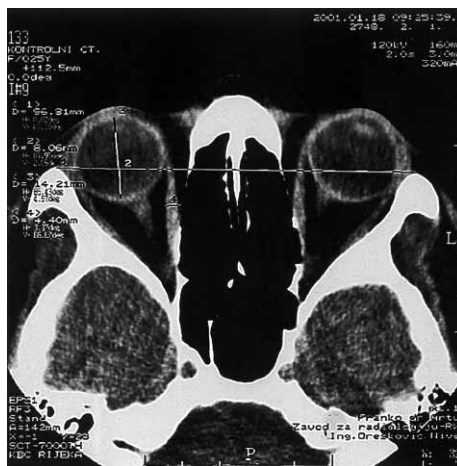

Fig. 4. Striated muscle (HE) showing encapsulated larvae of *Trichinella spiralis* ($\times 400$)

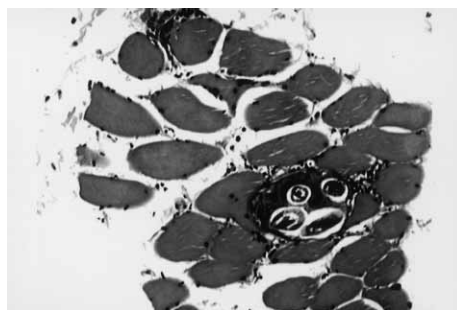


Fig. 5. Skin (HE) – perivascular mononuclear infiltrate in dermis ($\times 400$).

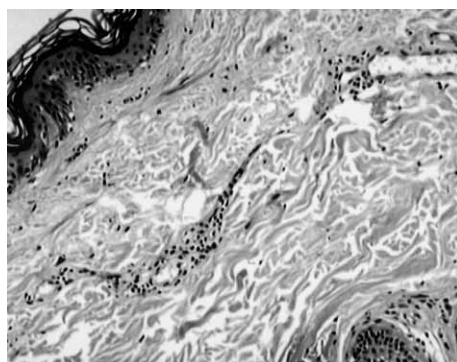


Fig. 6. Orbital axial CT scan after corticosteroid pulse therapy – normalization of findings

Discussion

The patient here described presented with severe immunologic reaction to *Trichinella spiralis* infestation.

Although ocular involvement is common in Trichinellosis, in this case ocular clinical features were particularly striking, especially in the initial phase of the disease. Therefore the patient was emergently admitted to Eye clinic with suspicion on bilateral orbital cellulitis.

Eyelid oedema, conjunctival congestion and subconjunctival haemorrhages and bilateral protrusion of the eye balls due to enormous extraocular muscles enlargement have been present. Consequently all the ductions and the versions have been reduced causing diplopia due to restrictive myopathy.

On ophthalmoscopic examination the typical traits of ocular pathology including toxic vasculitis and retinal haemorrhages mostly in the macular region have been found.

In spite of started corticosteroid therapy (64 kg methyl prednisolon orally) proptosis persisted and there was still pain on attempted moving the globe. The clinical status of the patient progressively deteriorated.

Orbital CT scanning revealed enlarged extraocular muscles but no retrobulbar expanding process or orbital infiltration.

At this point the most likely diagnoses suggested by CT scan seemed orbital myositis or endocrine ophthalmopathy.

Besides constant fever during the course of the disease, there were also myalgia, dysphagia⁴, muscular weakness and generalised malaise so acute polymyositis syndrome was suspected. Trichinellosis was also included in the differential diagnosis and testing in that direction was started. Serious diagnostic problem was the absence of corresponding epide-

miological data, at least in the beginning of investigation.⁵

As in all cases when doubt remains, muscle biopsy was indicated and it demonstrated the presence of *Trichinella spiralis* encapsulated larvae in striated muscle specimen. Serologic tests supported the diagnosis, too.

In the meantime corticosteroid pulse therapy was started as well as parabulbar injections of methyl prednisolon-acetate at 40 mg. Only then patient promptly started to improve.

Conclusion

Treatment of Trichinellosis is definitely quite difficult. Since the manifestation of the disease is of variable intensity (depending upon the extent of invasion and the immune response of the host), the treatment is related to severity of the disease. Anthelmintic therapy is used only for an early period, probably in the first 3 days following infection.⁶ If applied it prevents subsequent muscular invasion but has little if any effect on muscle larvae. In the treatment of symptomatic Trichinellosis most authors recommend oral prednisolon at 30 to 60 mg/day for a period of 10–14 days.^{7,8,9} They are used in treatment of acute stage of Trichinellosis since they suppress symptoms and signs of immediate type hypersensitivity and shorten the duration of the disease.

But in this case the patient did not respond to such therapy and even got worse developing most disturbing clinical status. Therefore, unconventionally high dosed corticosteroid therapy was started and only at his point improvement was observed.

It is concluded that the decision about the treatment should be made on individual basis.

REFERENCES

1. TARATUTO, A. L., Brain Pathol., 7 (1997) 663.
- 2. DWORKIN, M. S., H. R. GAMBLE, D. S. ZARLENGA, P.O. TENNICAN, J. Infect. Dis., (1996) 663.
- 3. CHURCHILL, D. R., C. MORRIS, A. FAKOYA, J. Infect., 33 (1996) 103. — 4. WANG, Z. Q., J. CUI, F. WU, F. R. MAO, X. X. JIN, Acta Trop., 71 (1998) 255.
- 5. NIKOLIC, S., M. VUJOSEVIC, M. SASIC, J. POLUGA, S. MISIC, Lj. NAJDANOVIC, Srp., Arh., 126 (1998) 209. — 6. DENNETT, X., S. J. SIEJKA, J. R. ANDREWS, I. BEVERIDGE, D. M. SPRATT, Med. J. Aust., 168 (1998) 226. — 7. KOCIECKA, W., Vet. Parasit., 93 (2000) 365. — 8. PRIN, L., S. DUBUCQUOI, Med. Trop., 58 (1998) 433. — 9. JASMER, D. P., J. Cell Biol., 21 (1993) 785.

B. Vojniković

Clinical Hospital Center Rijeka, Department of Ophthalmology, Krešimirova 42, 51000 Rijeka, Croatia

TEŽAK OBLIK TRIHINELOZE IZLIJEČEN VISOKIM DOZAMA GLUKOKORTIKOIDA

SAŽETAK

Trihinelozu je zoonoza raširena u cijelom svijetu uzrokovana nematodom *Trichinella spiralis*. Prikazan je slučaj mlade djevojke zaražene *Trihinellom spiralis* s teškom slikom očne patologije, febrilitetom i progresivnom slabošću skeletne muskulature. Izvršeni su temeljiti oftalmološki, infektološki, neurološki i imunološki pregledi uključujući elektrodijagnostične pretrage kao i CT glave, ali je konačna dijagnoza potvrđena tek na temelju patohistološkog nalaza biopsije uzorka skeletnog mišića. Pacijentica nije reagirala na uobičajene doze kortikosteroida, a do poboljšanja je došlo tek nakon primjene pulsne doze od 1000 mg metilprednizolona. Iako većina autora preporučuje umjereno visoke doze kortikosteroida u liječenju trihineloze, teški slučajevi mogu ponekad zahtijevati ekstremno visoke doze.