



T2 MAPPING OF ACETABULAR CARTILAGE IN PATIENTS WITH PRIMARY OSTEOARTHRITIS AND DDH-INDUCED SECONDARY OSTEOARTHRITIS ANALYSED WITH 7 TESLA MICRO-MRI

Tea Duvančić¹, Andreja Vukasović Barišić², Mihovil Plečko³, Ana Čizmić⁴, Ivan Boháček^{1,3} and Domagoj Delimar^{1,3}

¹Department of Orthopaedic Surgery, School of Medicine, University of Zagreb, Zagreb, Croatia

²University Hospital Bjelovar, Bjelovar, Croatia

³Department of Orthopaedic Surgery, University Hospital Center Zagreb, Zagreb, Croatia

⁴University Hospital Centre Sisters of Mercy, Clinic for Traumatology, Zagreb, Croatia

SUMMARY – The aim of our study was to compare acetabular cartilage affected by primary and DDH-induced secondary osteoarthritis (OA) using T2 mapping, which gives us information about cartilage water and collagen content, and the orientation of collagen fibrils. Samples of the osteochondral unit were obtained intraoperatively during total hip arthroplasty from the acetabulum of 15 patients with primary OA (pOA-Ac) and 15 patients with DDH-induced secondary OA (sOA-Ac). The samples were then scanned on a 7 Tesla micro-magnetic resonance imaging (micro-MRI) machine and the T2 values of all samples were calculated. The results were compared using a t-test. The average T2 values for the sOA-Ac and pOA-Ac groups were 57.28 ± 31.87 ms and 37.54 ± 11.17 ms, respectively. The calculated p-value was 0.019, making results statistically significant at $p < 0.5$. This is one of the first studies performed ex vivo on the acetabular cartilage of human dysplastic hips, using a 7 Tesla MRI machine. Our results show that acetabular cartilage in DDH-induced secondary OA is more damaged than in primary OA, and offer 7 Tesla T2 reference values of acetabular cartilage for both the primary and DDH-induced secondary OA.

Keywords: *Developmental Dysplasia of the Hip; Acetabulum; Osteoarthritis; Magnetic Resonance Imaging*

Introduction

The aim of this study was to compare acetabular cartilage affected by primary and DDH-induced secondary osteoarthritis (OA) using T2 mapping. OA disrupts the structure and physiological function of the main macromolecules in the articular cartilage by

changing their composition and architecture. Loss of type II collagen is among the initial biochemical alterations connected to OA. A well-organised collagen network is disrupted by the decrease in collagen content, which causes a loss in tensile stiffness and a rise in the ability to absorb and retain water, which increases the amount of water in the cartilage^{1,2}. According to histological analyses of the articular cartilage, the collagen network becomes disorganised at the beginning of OA, and the collagen content decreases as the disease progresses³⁻⁵. Both primary and DDH-induced secondary OA cause similar chemical changes in the tissue, but secondary OA tends to progress faster.

Correspondence to: *Domagoj Delimar*

Department of Orthopaedic Surgery, University Hospital Center Zagreb, School of Medicine, University of Zagreb

Šalata 6-7, 10000 Zagreb, Croatia

e-mail: domagoj.delimar@kbc-zagreb.hr

tel. + 385 1 2368 911

DDH is characterised by a shallow acetabulum, which results in poor femoral head stabilisation and high articular loading. Due to special joint anatomy, DDH patients have an inhomogeneous stress distribution within the joint, which can lead to premature OA and more severe symptoms compared to primary OA, including severe pain even in the absence of obvious signs of tissue damage⁶⁻¹¹.

Magnetic resonance imaging (MRI) is a radiological method used in medical diagnostic imaging of soft tissues. Given its excellent soft tissue contrast and high spatial resolution, MRI is a perfect method for articular cartilage visualisation and assessment¹²⁻¹⁵. Various compositional MRI approaches have been developed in recent years. These techniques enable the assessment of the biochemical composition of articular cartilage even before its morphological manifestation. They are routinely used in the clinic since they allow the diagnosis of OA in its early stages^{16,17}. One of these techniques, and the focus of this study, is T2 mapping. It is a compositional MRI technique based on T2 relaxation times, which reflect cartilage water and collagen content, and the orientation of collagen fibrils in the cartilage matrix. T2 mapping does not require a contrast agent, which gives it an advantage over other MR-based imaging methods^{14,16,18-21}. Although some literature references link T2 values with proteoglycan content²², it has since been proven that T2 values have a low correlation with the loss of proteoglycans^{23,24}.

Most of the information on T2 relaxometry of articular cartilage comes from studies performed on the knee. These studies have demonstrated that osteoarthritic cartilage has elevated T2 values, suggesting disorganisation of the collagen fibrils and an increase in water content, i.e., degeneration of the tissue. A range of T2 values, where greater values indicate a higher degree of deterioration, show the gradation in the tissue's metabolic changes^{17,18,25-27}. Studies performed on clinical 3 Tesla MRI machines have shown that T2 values are a valuable indicator of cartilage biochemical composition and can be used to detect degenerative changes even in the early stages of OA progression. There is some information on T2 mapping of the hip cartilage, but those studies are still scarce in number. According to these studies, T2 values are linked to morphological cartilage degeneration and can be used in the diagnosis of early stages of hip OA²⁸⁻³¹.

The development of high-field strength magnets has enabled the improvement of articular cartilage im-

aging. The 7 Tesla MRI offers increased tissue imaging details, a higher signal-to-noise ratio, and a better ability to distinguish between healthy and degenerated tissue. It has also found its clinical use, detecting abnormalities that go unnoticed on MRIs with lower field strengths^{13,32-36}. Even though it has been demonstrated that 7 Tesla T2 mapping of the hip cartilage has a strong clinical potential, it comes with its challenges. The main obstacle in T2 mapping of the hip cartilage is its thin and complex anatomy, making good protocol development a necessity^{37,38}. Given the relatively small number of T2 mapping studies performed on the hip cartilage, there is a need for further optimization and development before it is widely used in the clinical setting.

The purpose of this study was to investigate biochemical differences between the acetabulum of patients with DDH-induced secondary OA and the acetabulum of patients with primary OA using T2 mapping performed on a 7 Tesla MRI machine.

Methods

2.1. Patients

Samples were obtained from patients with DDH-induced secondary OA (n=15; mean age 54.0; age range 37-67; 15 females; Crowe stages III and IV) and patients with primary OA (n=15; mean age 58.4; age range 50-69; 7 females, 8 males; Kellgren-Lawrence stages III and IV). Exclusion criteria were a history of malignant or autoimmune diseases, a history of steroid medication, and the presence of other diseases or conditions that might influence cartilage development (e.g., femoroacetabular impingement, avascular necrosis...). This study was approved by the University Hospital Centre Zagreb and the School of Medicine Research Ethics Committees. All patients gave informed consent to participate in the study.

2.2. Samples

Samples of the osteochondral unit were obtained intraoperatively, with a 10 mm diameter cylindrical chisel (Small Joint OATS Set, 10mm AR-8981-10S, Arthrex, Naples, Florida, US), from the acetabulum of patients with DDH-induced secondary OA (sOA-Ac) and the acetabulum of patients with primary OA (pOA-Ac). The samples were obtained from the posterior-superior zone according to Wasielewski. They were washed in saline solution and scanned on a micro-MRI machine immediately following the surgery.

2.3. micro-MR imaging of osteochondral tissue samples

Micro-MR imaging of the samples was performed on an ultra-high field (7 Tesla) preclinical MRI scanner (BioSpec 70/20 USR, Bruker Biospin, Germany) in a Tx/Rx configuration, using an 86 mm volume coil (MT0381, Bruker Biospin) for transmitting (Tx) and a 2-element mouse brain surface coil (MT0042, Bruker Biospin) for receiving (Rx). Scans were acquired using Paravision software (Paravision 6.0.1, Bruker Biospin, Germany).

T2 mapping was performed. The micro-MRI protocol included longitudinal/sagittal orientation, FOV size 15x12x5 mm, in-plane resolution 120 x 120 μ m, 13 slices per scan, slice thickness of 300 μ m, the gap between slices of 100 μ m, multislice multi-echo (MSME) sequence with 20 echo images, 2500 ms TR/TE, echo spacing of 7 ms and a scan time of 42 min.

2.4. Data analysis

Data analysis was performed using ImageJ software (v2.3.0., National Institutes of Health, Bethesda, MD, USA). For each sample, three regions of interest (ROI) were manually selected, omitting sample margins to avoid the penetration of saline solution in the ROI. ROI's T2 values were measured. The mean values of each sample were calculated. The Shapiro-Wilk analysis was performed to test whether the data were normally distributed. Mean values for each experimental group were calculated and compared using a t-test.

Results

The T2 values for the acetabular cartilage obtained from primary and DDH-induced secondary OA patients varied from 18.45 to 66.24 ms, and from 24.36 to 115.45 ms, respectively (Table 1). The Shapiro-Wilk analysis showed the data were normally distributed. The average T2 values for the pOA-Ac and sOA-Ac groups were 37.54 \pm 11.17 ms and 57.28 \pm 31.87 ms, respectively (Figure 1). The calculated p-value was 0.019, making the results statistically significant at p<0.05.

Discussion

The aim of this study was to analyse the chemical composition of acetabular cartilage in patients with primary and DDH-induced secondary OA. We used 7 Tesla MRI T2 mapping. T2 mapping gives us information about cartilage water and collagen content, as

Table 1. T2 relaxation times (in ms) of the acetabulum of patients with primary osteoarthritis (pOA-Ac) and the acetabulum of patients with DDH-induced secondary osteoarthritis (sOA-Ac). Average T2 values (Avg. T2) are means (in ms) \pm standard deviation.

Sample No.	T2' / ms	
	pOA-Ac	sOA-Ac
1	18.45	24.36
2	22.17	26.85
3	30.31	31.67
4	30.95	34.81
5	31.51	37.23
6	31.77	38.44
7	33.15	39.87
8	36.47	40.97
9	40.47	41.19
10	41.59	46.57
11	43.57	72.06
12	44.00	86.83
13	44.33	109.28
14	48.13	113.68
15	66.24	115.45
Avg. T2 \pm SD [†]	37.54 \pm 11.17	57.28 \pm 31.87

T2 values in milliseconds

[†]Average T2 values in milliseconds \pm standard deviation

well as the orientation of collagen fibrils, with higher T2 values representing a higher degree of tissue degeneration²⁵⁻²⁷. Although cartilage T2 values rely highly on the scanning parameters, T2 values for healthy articular cartilage obtained from the hip joint vary on average between 18.8 to 41.8 ms^{39,40}. T2 mapping is a well-established method for the analysis of human cartilage, but this is one of the first such studies performed *ex vivo* on the acetabular cartilage of human dysplastic hips, using a 7 Tesla MRI machine.

Most of the published studies were performed on clinical MRI machines with the field strength of 3 Tesla. At a higher field strength, T2 values of articular cartilage tend to be smaller compared with 3 Tesla⁴⁰. In general, higher field strength enables a higher signal-to-noise ratio and an improved differentiation between healthy and degenerated tissue. In the clinical context, there are cases where MRI results might be

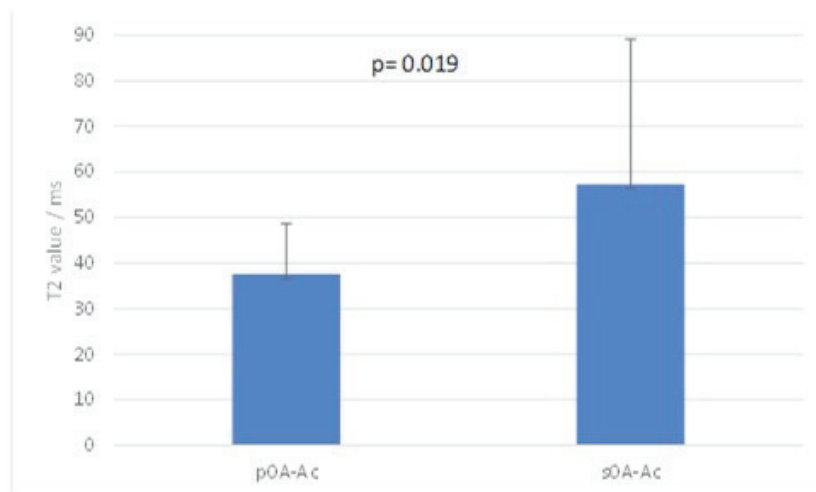


Figure 1. Graphical representation of average T2 values (in ms) for acetabular cartilage obtained from patients with primary osteoarthritis (pOA-Ac) and DDH-induced secondary osteoarthritis (sOA-Ac). Error bars represent standard deviations.

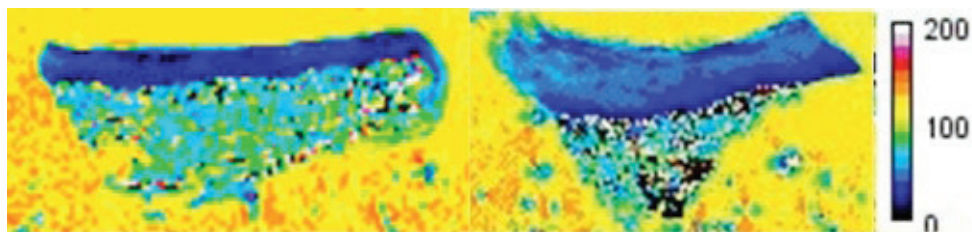


Figure 2. T2 maps of the acetabulum obtained from a patient with primary osteoarthritis (left) and a patient with DDH-induced secondary osteoarthritis (right). The yellow background represents water. Scale bar represents T2 values in ms.

disregarded if they contradict the clinical presentation. A more accurate visualisation, provided by high-field strength MRIs, has a great potential to help distinguish early pathological changes from artefacts. In terms of research, new-generation MRIs provide improved spatial resolution and better-quality images that can resolve even small morphological structures in the tissue^{32,41-43}.

To our knowledge, there is currently no information on T2 values of human acetabular osteoarthritic cartilage obtained from a 7 Tesla scanner. Here we present reference 7 Tesla T2 values of acetabular cartilage for both the primary and DDH-induced secondary OA. In our study, the average T2 values of pOA-Ac and sOA-Ac cartilage were 37.54±11.17 ms and 57.28±31.87 ms, respectively. At the significance level of $p < 0.05$, we found statistically significant dif-

ferences between the two experimental groups. Our results show that acetabular cartilage in DDH-induced secondary OA is more damaged than in primary OA, which agrees with previously published data. It has been demonstrated that DDH-induced secondary OA causes the loss of collagen and an increase in water content in the articular cartilage matrix, explaining an increase in T2 values. Compared with primary OA, DDH causes more severe symptoms and accelerated tissue degeneration, which can be explained by a higher degree of biochemical changes affecting the cartilage^{8-10,44,45}.

When comparing standard deviation (SD) values, we noticed a higher variability within the secondary OA group (Table 1). As previously mentioned, studies on the knee joint have shown that T2 values increase as OA progresses^{46,47}. *In vivo* studies on humans

showed a similar pattern with the hip joint, and validated the use of T2 mapping as a tool for measuring the degree of cartilage deterioration³¹. Heterogeneity can therefore be explained by the presence of different stages of OA progression among DDH patients. Even though all the DDH patients included in this study were diagnosed with severe stages of OA, DDH is known to cause severe pain^{10,11}, meaning some of the patients might have asked for medical help in earlier stages of OA progression. One of the clinical manifestations of DDH is a shallow acetabulum, which results in abnormal articular cartilage loading¹¹. All the sOA-Ac and pOA-Ac samples were obtained from the same anatomical region (posterior-superior zone according to Wasielewski), but due to altered anatomy of the DDH acetabulum those regions might have been under different degrees of biomechanical loading, therefore suffering different degrees of damage, offering another explanation for a variance in T2 values within the DDH group.

We suggest further investigation of articular cartilage in patients with advanced stages of DDH, with the future focus on complimentary MRI and immunohistochemistry examination of acetabular cartilage of DDH patients, in order to gain a more thorough understanding of the differences between primary and secondary OA.

Disclosure of conflict of interest

None.

References

- Liess C, Lüsse S, Karger N, Heller M, Glüer C-C. Detection of changes in cartilage water content using MRI T2-mapping in vivo. *Osteoarthr Cartil.* 2002;10(12):907-13. doi: 10.1053/joca.2002.0847.
- Hosseininia S, Lindberg LR, Dahlberg LE. Cartilage collagen damage in hip osteoarthritis similar to that seen in knee osteoarthritis; A case-control study of relationship between collagen, glycosaminoglycan and cartilage swelling. *BMC Musculoskelet Disord.* 2013;14(1):1-7. doi: 10.1186/1471-2474-14-18.
- Saarakkala S, Julkunen P, Kiviranta P, Mäkitalo J, Jurvelin JS, Korhonen RK. Depth-wise progression of osteoarthritis in human articular cartilage: investigation of composition, structure and biomechanics. *Osteoarthr Cartil.* 2010;18(1):73-81. doi: 10.1016/j.joca.2009.08.003.
- Li X, Majumdar S. Quantitative MRI of articular cartilage and its clinical applications. *J Magn Reson Imaging.* 2013;38(5):991-1008. doi: 10.1002/jmri.24313
- Mantripragada VP, Gao W, Piuze NS, Hoemann CD, Muschler GF, Midura RJ. Comparative Assessment of Primary Osteoarthritis Progression Using Conventional Histopathology, Polarized Light Microscopy, and Immunohistochemistry. *Cartilage.* 2020;13(1):1494S-1510S. doi: 10.1177/1947603520938455.
- Fang H, Huang L, Welch I, Norley C, Holdsworth DW, Beier F, et al. Early Changes of Articular Cartilage and Subchondral Bone in The DMM Mouse Model of Osteoarthritis. *Sci Rep.* 2018;8(1):2855. doi: 10.1038/s41598-018-21184-5.
- Nishii T, Tanaka H, Sugano N, Sakai T, Hananouchi T, Yoshikawa H. Evaluation of cartilage matrix disorders by T2 relaxation time in patients with hip dysplasia. *Osteoarthr Cartil.* 2008;16(2):227-33. doi: 10.1016/j.joca.2007.06.003.
- Bohaček I, Plečko M, Duvančić T, Smoljanović T, Barišić AV, Delimar D. Current knowledge on the genetic background of developmental dysplasia of the hip and the histomorphological status of the cartilage. *Croat Med J.* 2020;61(3):260-70. doi: 10.3325/cmj.2020.61.260.
- Müller M, Rakow A, Wassilew GI, Winkler T, Perka C. Prediction of time to prosthesis implantation as a function of joint anatomy in patients with developmental dysplasia of the hip. *J Orthop Surg Res.* 2019;14(1):471. doi: 10.1186/s13018-019-1511-4.
- Chu L, He Z, Qu X, Liu X, Zhang W, Zhang S, et al. Different subchondral trabecular bone microstructure and biomechanical properties between developmental dysplasia of the hip and primary osteoarthritis. *J Orthop Transl.* 2020;22:50-7. doi: 10.1016/j.jot.2019.09.001.
- Harris MD, Shepherd MC, Song K, Gaffney BMM, Hillen TJ, Harris-Hayes M, et al. The biomechanical disadvantage of dysplastic hips. *J Orthop Res.* 2022;40(6):1387-96. doi: 10.1002/jor.25165.
- Kumar PA, Gunasundari R, Aarthi R. Systematic Analysis and Review of Magnetic Resonance Imaging (MRI) Reconstruction Techniques. *Curr Med Imaging.* 2021;17(8):943-55. doi: 10.2174/1573405616666210105125542.
- Paunipagar BK, Rasalkar DD. Imaging of articular cartilage. *Indian J Radiol Imaging.* 2014;24(3):237-48. doi: 10.4103/0971-3026.137028.
- Braun HJ, Gold GE. Advanced MRI of articular cartilage. *Imaging Med.* 2011;3(5):541-55. doi: 10.2217/iim.11.43.
- Crema MD, Roemer FW, Marra MD, Burstein D, Gold GE, Eckstein F, et al. Articular Cartilage in the Knee: Current MR Imaging Techniques and Applications in Clinical Practice and Research. *Radiographics.* 2011;31(1):37-61. doi: 10.1148/rg.311105084.
- Guerhazi A, Alizai H, Crema MD, Trattning S, Regatte RR, Roemer FW. Compositional MRI techniques for evaluation of cartilage degeneration in osteoarthritis. *Osteoarthr Cartil.* 2015;23(10):1639-53. doi: 10.1016/j.joca.2015.05.026.
- Mills ES, Becerra JA, Yensen K, Bolia IK, Shontz EC, Kebaish KJ, et al. Current and Future Advanced Imaging Modalities for the Diagnosis of Early Osteoarthritis of the Hip. *Orthop Res Rev.* 2022;14:327-38. doi: 10.2147/ORR.S357498.
- Gao KT, Padoia V, Young KA, Kogan F, Koff MF, Gold GE, et al. Multiparametric MRI characterization of knee articular cartilage and subchondral bone shape in collegiate basketball players. *J Orthop Res.* 2021;39(7):1512-22. doi: 10.1002/jor.24851.

19. Fernquest S, Palmer A, Gammer B, Hirons E, Kendrick B, Taylor A, et al. Compositional MRI of the Hip: Reproducibility, Effect of Joint Unloading, and Comparison of T2 Relaxometry with Delayed Gadolinium-Enhanced Magnetic Resonance Imaging of Cartilage. *Cartilage*. 2021;12(4):418-30. doi: 10.1177/1947603519841670.
20. Roemer FW, Crema MD, Trattnig S, Guermazi A. Advances in imaging of osteoarthritis and cartilage. *Radiology*. 2011;260(2):332-54. doi: 10.1148/radiol.11101359.
21. Nieminen MT, Rieppo J, Tö J, Hakumäki JM, Silvennoinen J, Hyttinen MM, et al. T2 Relaxation Reveals Spatial Collagen Architecture in Articular Cartilage: A Comparative Quantitative MRI and Polarized Light Microscopic Study. *Magn Reson Med*. 2001;46(3):487-93. doi: 10.1002/mrm.1218.
22. Wayne JS, Kraft KA, Shields KJ, Yin C, Owen JR, Disler DG. MR Imaging of Normal and Matrix-depleted Cartilage: Correlation with Biomechanical Function and Biochemical Composition. *Radiology*. 2003;228(2):493-9. doi: 10.1148/radiol.2282012012.
23. Collins AT, Hatcher CC, Kim SY, Ziemian SN, Spritzer CE, Guilak F, et al. Selective Enzymatic Digestion of Proteoglycans and Collagens Alters Cartilage T1rho and T2 Relaxation Times. *Ann Biomed Eng*. 2019;47(1):190-201. doi: 10.1007/s10439-018-02143-7.
24. Menezes NM, Gray ML, Hartke JR, Burstein D. T2 and T1rho MRI in Articular Cartilage Systems. *Magn Reson Med*. 2004;51(3):503-9. doi: 10.1002/mrm.10710.
25. Roemer FW, Eckstein F, Duda G, Guermazi A, Maschek S, Sharma L, et al. Is Lamellar Cartilage Composition as Determined by T2 Relaxometry Associated with Incident and Worsening of Cartilage or Bone Marrow Abnormalities?. *Cartilage*. 2021;13(1_suppl):757S-766S. doi: 10.1177/1947603520932197.
26. Mittal S, Pradhan G, Singh S, Batra R. T1 and T2 mapping of articular cartilage and menisci in early osteoarthritis of the knee using 3-Tesla magnetic resonance imaging. *Polish J Radiol*. 2019;84:e549-64. doi: 10.5114/pjr.2019.91375
27. Prasad AP, Nardo L, Schooler J, Joseph GB, Link TM. T1ρ and T2 relaxation times predict progression of knee osteoarthritis. *Osteoarthr Cartil*. 2013;21(1):69-76. doi: 10.1016/j.joca.2012.09.011.
28. Wyatt C, Kumar D, Subburaj K, Lee S, Nardo L, Narayanan D, et al. Cartilage T1ρ and T2 relaxation times in patients with mild-to-moderate radiographic hip osteoarthritis. *Arthritis Rheumatol*. 2015;67(6):1548-56. doi: 10.1002/art.39074.
29. Pedoia V, Gallo MC, Souza RB, Majumdar S. A longitudinal Study using voxel-based relaxometry: association between cartilage T1ρ and T2 and patient reported outcome changes in hip osteoarthritis. *J Magn Reson Imaging*. 2017;45(5):1523-33. doi: 10.1002/jmri.25458.
30. Nishii TMD, Tanaka HMD, Sugano NMD, Sakai TMD, Hananouchi TMD, Yoshikawa HMD. Evaluation of cartilage matrix disorders by T2 relaxation time in patients with hip dysplasia. *Osteoarthr Cartil*. 2008;16(2):227-33. doi: 10.1016/j.joca.2007.06.003.
31. Gallo MC, Wyatt C, Pedoia V, Kumar D, Lee S, Nardo L, et al. T1ρ and T2 Relaxation Times are Associated with Progression of Hip Osteoarthritis. *Osteoarthr Cartil*. 2016;24(8):1399-407. doi: 10.1016/j.joca.2016.03.005.
32. Wyatt C, Guha A, Venkatachari A, Li X, Krug R, Kelley DE, et al. Improved differentiation between knees with cartilage lesions and controls using 7T relaxation time mapping. *J Orthop Transl*. 2015;3(4):197-204. doi: 10.1016/j.jot.2015.05.003.
33. Trattnig S, Springer E, Bogner W, Hangel G, Strasser B, Dymerska B, et al. Key clinical benefits of neuroimaging at 7 T. *Neuroimage*. 2018;168:477-89. doi: 10.1016/j.neuroimage.2016.11.031.
34. Trattnig S, Bogner W, Gruber S, Szomolanyi P, Juras V, Robinson S, et al. Clinical applications at ultrahigh field (7 T). Where does it make the difference?. *NMR Biomed*. 2016;29(9):1316-34. doi: 10.1002/nbm.3272.
35. Bogner W, Chmelik M, Andronesi OC, Sorensen AG, Trattnig S, Gruber S. In vivo 31P spectroscopy by fully adiabatic extended image selected in vivo spectroscopy: a comparison between 3 T and 7 T. *Magn Reson Med*. 2011;66(4):923-30. doi: 10.1002/mrm.22897.
36. Bangerter NK, Taylor MD, Tarbox GJ, Palmer AJ, Park DJ. Quantitative techniques for musculoskeletal MRI at 7 Tesla. *Quant Imaging Med Surg*. 2016;6(6):715-30. doi: 10.21037/qims.2016.12.12.
37. Lazik A, Theysohn JM, Geis C, Johst S, Ladd ME, Quick HH, et al. 7 Tesla quantitative hip MRI: T1, T2 and T2* mapping of hip cartilage in healthy volunteers. *Eur Radiol*. 2016;26(5):1245-53. doi: 10.1007/s00330-015-3964-0.
38. Juras V, Mlynarik V, Szomolanyi P, Valkovič L, Trattnig S. Magnetic Resonance Imaging of the Musculoskeletal System at 7T: Morphological Imaging and Beyond. *Top Magn Reson Imaging*. 2019;28(3):125-35. doi: 10.1097/RMR.000000000000205.
39. Aringhieri G, Zampa V, Tosetti M. Musculoskeletal MRI at 7 T: do we need more or is it more than enough?. *Eur Radiol Exp*. 2020;4(1):1-14. doi: 10.1186/s41747-020-00174-1.
40. Braun HJ, Dragoo JL, Hargreaves BA, Levenston ME, Gold GE. Application of Advanced Magnetic Resonance Imaging Techniques in Evaluation of the Lower Extremity. *Radiol Clin North Am*. 2013;51(3):529-45. doi: 10.1016/j.rcl.2012.12.001.
41. Cashman G, Attariwala R. Influence of MRI field strength on clinical decision making in knee cartilage injury-A case study. *J Can Chiropr Assoc*. 2014;58(4):395-400.
42. Trattnig S, Friedrich KM, Bogner W, Welsch GH. Advanced musculoskeletal MRI at ultra-high field (7 T). *Imaging Med*. 2010;2(1):99-114. doi: 10.2217/IIM.09.26.
43. Nowogrodzki A. The world's strongest MRI machines are pushing human imaging to new limits. *Nature*. 2018;563(7729):24-6. doi: 10.1038/d41586-018-07182-7.
44. Li C, Peng Z, Zhou Y, Su Y, Bu P, Meng X, et al. Comprehensive analysis of pathological changes in hip joint capsule of patients with developmental dysplasia of the hip. *Bone Joint Res*. 2021;10(9):558-70. doi: 10.1302/2046-3758.109.BJR-2020-0421.R2.
45. Hernandez PA, Wells J, Usheva E, Nakonezny PA, Barati Z, Gonzalez R, et al. Early-Onset Osteoarthritis originates at the

- chondrocyte level in Hip Dysplasia. *Sci Rep.* 2020;10(1):627. doi: 10.1038/s41598-020-57431-x.
46. Baum T, Joseph GB, Karampinos DC, Jungmann PM, Link TM, Bauer JS. Cartilage and meniscal T2 relaxation time as non-invasive biomarker for knee osteoarthritis and cartilage repair procedures. *Osteoarthr Cartil.* 2013;21(10):1474–84. doi: 10.1016/j.joca.2013.07.012.
47. Li X, Benjamin Ma C, Link TM, Castillo DD, Blumenkrantz G, Lozano J, et al. In vivo T(1rho) and T(2) mapping of articular cartilage in osteoarthritis of the knee using 3 T MRI. *Osteoarthr Cartil.* 2007;15(7):789–97. doi: 10.1016/j.joca.2007.01.011.

Sažetak

T2 MAPIRANJE HRSKAVICE ACETABULUMA KOD BOLESNIKA S PRIMARNIM OSTEOARTRITISOM I SEKUNDARNIM OSTEOARTRITISOM INDUCIRANIM RAZVOJNIM POREMEĆAJEM KUKA ANALIZIRANO NA MIKRO-MR UREĐAJU SNAGE 7 TESLA

T. Duvančić, A. Vukasović Barišić, M. Plečko, A. Čizmić, I. Bobaček i D. Delimar

Svrha ovog rada bila je usporediti acetabularnu hrskavicu prikupljenu od pacijenata s primarnim i sekundarnim osteoartritisom (OA) uzrokovanim razvojnim poremećajem kuka koristeći T2 mapiranje, koje se koristi za analizu sadržaja vode i kolagena u hrskavici, i orijentacije kolagenih vlakana. Uzorci acetabuluma prikupljeni su tijekom operacije ugradnje totalne endoproteze kuka od 15 pacijenata s primarnim OA (pOA-Ac) i 15 pacijenata sa sekundarnim OA uzrokovanim razvojnim poremećajem kuka (sOA-Ac), te su snimljeni mikro-magnetskom rezonancijom (mikro-MR) na uređaju jačine 7 Tesla. Izračunate su T2 mape svih uzoraka, a rezultati su uspoređeni pomoću t-testa. Srednje T2 vrijednosti za sOA-Ac i pOA-Ac iznosile su 57.28 ± 31.87 ms, odnosno 37.54 ± 11.17 ms. Izračunata p vrijednost iznosila je 0.019, što znači da je razlika između skupina statistički značajna uz razinu značajnosti $p < 0.05$. Ovo je jedna od prvih ex vivo studija acetabularne hrskavice pacijenata s razvojnim poremećajem kuka provedenih na mikro-MR uređaju jačine 7 Tesla. Naši rezultati upućuju na to da je acetabularna hrskavica pacijenata sa sekundarnim osteoartritisom uzrokovanim razvojnim poremećajem kuka više oštećena od one pacijenata s primarnim OA. Naša studija pruža informacije o referentnim T2 vrijednostima acetabularne hrskavice zahvaćene primarnim i sekundarnim OA dobivenim na MR uređaju jačine 7 Tesla.

Ključne riječi: *razvojna displazija kukova, acetabul, osteoartritis, magnetska rezonancija*