

Investigation of the effects of p-Coumaric acid on MDA, some antioxidants and histopathological parameters in nephrotoxicity induced by bisphenol A in rats

Burak Batuhan Laçın, Merve Bolat and Ali Çınar*

Department of Physiology, Faculty of Veterinary Medicine, Atatürk University, Erzurum, Turkey

LAÇIN, B. B., M. BOLAT, A. ÇINAR: Investigation of the effects of p-Coumaric acid on MDA, some antioxidants and histopathological parameters in nephrotoxicity induced by bisphenol A in rats. Vet. arhiv 94, 155-164, 2024.

ABSTRACT

The aim of this study was to investigate p-Coumaric acid (PCA) as a protector in detecting oxidative and targeted damage in the elongation tissue of rats induced by bisphenol A (BPA). BPA is an environmental pollutant widely used in many areas. The widespread use of this substance increases its transmission to humans. BPA causes damage to many tissues and organs. One of the most frequently damaged organs is the kidney. In this study, fifty healthy male rats were used to determine the effects of BPA and PCA. A total of five experimental groups were formed with ten animals in each group. Group 1 was set as the Control, Group 2 as BPA, Group 3 as BPA+PCA50, Group 4 as BPA+PCA100, and Group 5 as PCA100. The experiment lasted 14 days. Hematoxylin eosin staining and ELISA analyses were performed on kidney tissues at the end of the experiment. Malondialdehyde (MDA), glutathione (GSH), superoxide dismutase (SOD), and nitric oxide (NO) levels were determined in the kidney tissues by ELISA analysis. It was observed that kidney MDA and NO levels increased in the groups administered BPA while SOD and GSH levels decreased. Histopathologically, degeneration and necrosis in the tubular epithelium, glomerular atrophy, and hyperemia in the vessels were observed in the kidney tissues of the BPA groups. In the BPA+PCA groups it was seen that PCA prevented the negative effects of BPA in a dose-dependent manner, and helped in the maintenance of values close to the control group.

Key words: kidney; bisphenol A; p-Coumaric acid; rat; toxicity; oxidative stress

Introduction

Bisphenol A (BPA) is one of the most common compounds used synthetically and industrially worldwide. Polycarbonate plastics, epoxy resins, polysulfone resin, polyphenylene ether resin, and unsaturated polyester resin can be counted as areas of BPA use. BPA is also widely used in

consumer baby bottles, toys, and dental fillings (MIKOŁAJEWSKA et al., 2015; KATARIA et al., 2015). Due to its wide range of use, it is abundant in our environment (DI BELLA et al., 2018; LO TURCO et al., 2020). Epidemiological studies have shown that more than 90% of people tested have

*Corresponding author:

Ali Çınar, Department of Physiology, Faculty of Veterinary Medicine, Atatürk University, Erzurum, Turkey, e-mail: d.cinar@atauni.edu.tr

detectable levels of BPA (CALAFAT et al., 2008). At the same time, many studies have found that BPA is also found in foods, the environment, and bodily fluids (CAO et al., 2011; FENICHEL et al., 2012; MOUNEIMNE et al., 2017). Numerous in vivo and in vitro experiments have shown that BPA can cause various effects in vital organs such as the testes, brain, heart, liver, and pancreas, and even accumulate in these organs (TAKAHASHI and OISHI, 2003; RICHTER et al., 2007; POSNACK, 2014; XIA et al., 2014). The kidneys are among the tissues most affected by BPA exposure (JIANG et al., 2020; DEVECİ and ERDAL, 2022).

Mitochondria are a source of energy for cells and take part in many biological processes (TAO et al., 2016; TAO et al., 2018). Mitochondria are the primary site of reactive oxygen species (ROS) and reactive nitrogen species (RNS) produced inside a cell. ROS and RNS induce oxidative stress in the cell (BHARGAVA and SCHNELLMANN, 2017). BPA can cause organ dysfunction through oxidative damage by increasing the formation of ROS and RNS (KABUTO et al., 2003; TEKIN and CELEBİ, 2022). The increased ROS reacts with the lipid membranes in the cell wall and causes the emergence of lipid peroxidation products. One of these products is malondialdehyde (MDA). MDA, along with other aldehydes, is one of the most studied substances and was recently discovered in the peroxidation of polyunsaturated fatty acids (TURK et al., 2008). At the same time, BPA also damages the glutathione (GSH) and superoxide dismutase (SOD) antioxidant enzyme system in cells (TEKIN and CELEBİ, 2022). Depending on the exposure to BPA, the cells' nitric oxide (NO) level and ROS increase (PEERAPANYASUT et al., 2019). With these effects, BPA causes oxidative stress and, thus, oxidative damage in kidney tissue.

P-Coumaric acid (PCA) is a polyphenol found in plants, and forms part of the human diet. It is commonly found in fruits and vegetables such as apples, pears, potatoes, and tomatoes, and in beverages such as tea, coffee, and beer (KING and YOUNG, 1999). Recent studies have reported that p-Coumaric acid has antioxidant (CASTELLUCCIO et al., 1995), cardio-protective (PRASANNA et al., 2013), anti-melanogenic (AN

et al., 2010); p-Coumaric acid not only inhibits human), anti-mutagenic (FERGUSON et al., 2003), anti-platelet (LUCERI et al., 2007), anti-inflammatory and immunomodulatory properties (PRAGASAM et al., 2013). Phenolic compounds such as PCA are well known for their antioxidant properties. It removes ROS from cells and regulates endogenous antioxidant enzymes, thus preventing oxidative damage to biomolecules (ABDEL-WAHAB et al., 2003).

Kidneys have a role in maintaining homeostasis, and are one of the most important organs for life. It has been observed that BPA is present in the urine of those who come into contact with products containing BPA.

In the literature review, sufficient and direct research investigating the effects of p-Coumaric acid on bisphenol A-induced nephrotoxicity could not be found. In this regard, TEKIN et al. (2021) conducted research on the effects of p-Coumaric acid (PCA) on kidney damage molecule-1 (KIM-1) levels in BPA-induced nephrotoxicity. Therefore, in this study, we aimed to investigate the effects of p-Coumaric acid on MDA, some antioxidants, and histopathological parameters in nephrotoxicity induced by bisphenol A, and to contribute to the literature in this way.

Materials and methods

Chemicals and Animals. PCA (Cas No: 501-98-4) and BPA (Cas No: 80-05-7) were purchased from Sigma-Aldrich (St. Louis, Missouri, USA). Commercial rat ELISA kits were used according to the manufacturer's protocol to determine the level of malondialdehyde (MDA) (Cat. No: SL0475Ra), glutathione (GSH) (Cat. No: SL0998Ra), superoxide dismutase (SOD) (Cat. No: SL0664Ra), and nitric oxide (NO) (Cat. No: SL0365Ra) activities in rats (Sunlong Biotech Co., Ltd, Zhejiang, China).

Powdered PCA was dissolved in distilled water. After soaking in olive oil for 30 minutes, BPA was prepared daily by dissolving it with the help of a magnetic stirrer, and administered to the rats intragastrically (i.g).

Our study used 50 male adult Sprague-Dawley rats weighing 180-230 grams, with ten animals in

each experimental group. The rats were obtained from Atatürk University Medical Experimental Application and Research Center (ATADEM). The rats were fed ad libitum with standard pellet-type chow at this center. The rats were housed at 24°C in a 12-hour dark and 12-hour light cycle. Five experimental groups were formed from the 50 rats used in the study, with 10 in each group. This study protocol was approved by the Atatürk University Animal Experiments Local Ethics Committee (HADYEK, Decision No: 2022/10-186).

Experimental design. Before starting the experimental study, the 50 healthy 10-week-old male rats were weighed and distributed with ten animals in each of the five different experimental groups. The rats were weighed using scales daily, and the applications were made according to their current weights. The application of active substances to the experimental groups was carried out between 09:00 and 10:00 hours every day for 14 days. The BPA application was made 1 hour after the PCA application.

The experimental groups were formed as follows:

1. Control: 1 ml of olive oil i.g was given for 14 days.
2. Bisphenol A (100 mg/kg): BPA was administered at 100 mg/kg as, i.g for 14 days (GULES et al., 2019).
3. BPA + PCA (50 mg/kg): 100 mg/kg BPA and 50 mg/kg PCA i.g were given for 14 days (TEKIN et al., 2021).
4. BPA (100 mg/kg) + PCA (100 mg/kg): BPA at a dose of 100 mg/kg and PCA at a dose of 100 mg/kg were administered i.g for 14 days (TEKIN et al., 2021).
5. PCA (100mg/kg): 100mg/kg dose of PCA i.g was given for 14 days (TEKIN et al., 2021).

Collection of samples. On the 15th day of the experimental study, the rats were anesthetized with sevoflurane and decapitated. Immediately afterward, kidney tissue samples from the rats were stored in a deep freezer at -80°C until biochemical analysis.

Biochemical analysis. Homogenization of kidney tissues. Small sections were taken from

equal parts of the kidney tissues, transferred to Eppendorf tubes, and completed with 1.5 ml PBS (Phosphate buffered saline) solution with a pH of 7.4. Samples were homogenized in a MagNA Lyser device at 5000 rpm for 80 seconds. Homogenates were centrifuged at 6500 rpm for 5 minutes, and the supernatants were transferred to separate tubes.

Analysis of oxidant and antioxidant enzyme activities in kidney tissue. To determine malondialdehyde (MDA), glutathione (GSH), superoxide dismutase (SOD), and nitric oxide (NO) activities, commercial rat ELISA kits were used according to the kit protocol. The ELISA process was performed with Biotech's ELISA Microplate Washer and Reader. The standard curves of the results obtained from the ELISA were created using Four-Parameter Logistic Regression. The probabilities of the samples were also calculated from the standard curves created.

Histopathological Examination. Kidney tissue samples taken at the end of the experiment were fixed in a 10% formaldehyde solution for 48 hours and embedded in paraffin blocks at the end of routine tissue follow-up procedures. Sections of 4 µm thickness were taken from each block. The preparations prepared for histopathological examination were stained with hematoxylin-eosin (HE), and examined with a light microscope (Olympus BX 51, JAPAN). Sections were evaluated as absent (-), mild (+), moderate (++) , and severe (+++) according to their histopathological features. The '-' symbol represents 0–5% damage, the '+' symbol represents 10%–20%, the '++' symbol 20–40%, and the '+++ ' symbol represents more than 40% damage.

Statistical Analysis. The data we obtained were presented as mean value ± standard mean error (SEM). The significance level was determined as P<0.05. One-way analysis of variance (ANOVA) was used to determine the differences between groups. The Kruskal-Wallis test was used to analyze the differences between groups in the histopathological examinations, and the Mann-Whitney U test was used to compare matched groups. SPSS and GraphPad programs were used in these tests.

Results

Effects of p-Coumaric acid on bisphenol A-induced renal oxidative stress. It was observed that the MDA level obtained from kidney tissues of BPA-induced rats was higher when compared to the control group, and there was a statistical difference between these results ($P < 0.01$). Statistical analysis revealed that the MDA level obtained from the BPA+PCA50 group was higher when compared to the control group ($P < 0.05$) but was lower than the BPA group ($P < 0.05$). When the values obtained from the BPA+PCA100 and PCA100 groups were compared with the control, no statistically significant difference was observed between them ($P > 0.05$) (Fig. 1).

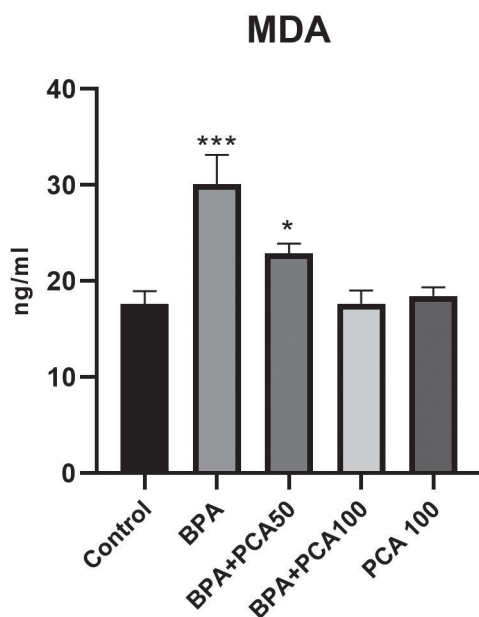


Fig. 1. Effects of PCA and BPA application on MDA levels in the experimental groups (***) $P < 0.01$, *) $P < 0.05$; $n = 10$)

It was determined that the nitric oxide level of the homogenates obtained from the kidney tissue of the rats administered BPA was higher than the control group, and there was a statistical difference between them ($P < 0.01$). The NO values obtained from the BPA+PCA50 group were determined by ELISA analyses, and were lower than the group

in which BPA was applied alone. There was a statistical difference between them ($P < 0.05$). At the same time, it was observed that the values obtained from the BPA+PCA50 group were higher than the control group, and there was a statistical difference between them ($P < 0.05$). When the NO values obtained from the BPA+PCA100 and PCA100 groups were compared with the control group, it was observed that there was no statistical difference between them ($P > 0.05$) (Fig. 2).

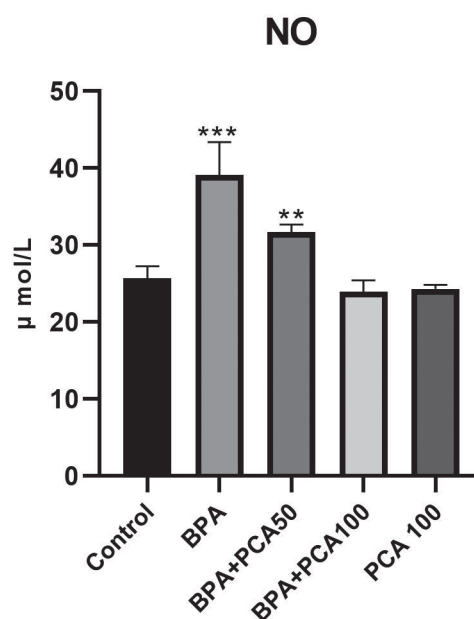


Fig. 2. Effects of PCA and BPA application on NO levels in the experimental groups (***) $P < 0.01$, **) $P < 0.05$; $n = 10$)

It was determined that the GSH and SOD levels in the kidney tissues of BPA-induced rats was lower compared to the control group, and there was a statistical difference between them ($P < 0.01$). It was determined that these levels obtained from the BPA+PCA50 group were lower than the control group, and there was a statistical difference between them ($P < 0.05$). When the SOD levels obtained from the BPA+PCA100 and PCA100 groups were compared with the control, it was observed that there was no statistical difference between them ($P > 0.05$) (Fig. 3, 4).

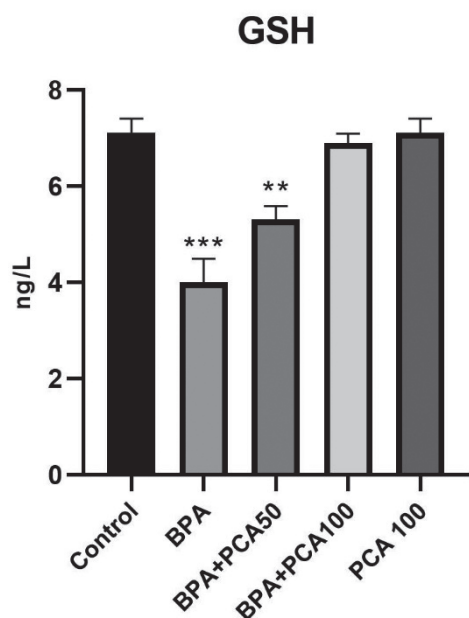


Fig. 3. Effects of PCA and BPA application on GSH levels in the experimental groups (***) $P < 0.01$, (**) $P < 0.05$; $n = 10$)

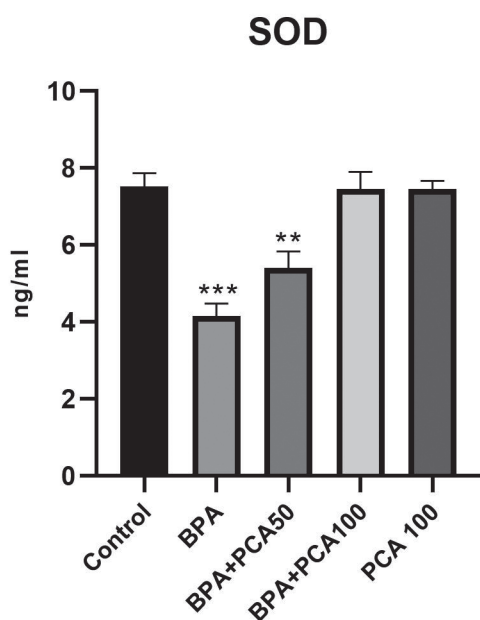


Fig. 4. Effects of PCA and BPA application on SOD levels in the experimental groups (***) $P < 0.01$, (**) $P < 0.05$; $n = 10$)

Histopathological Findings

Control and PCA100 groups. A normal histological appearance was detected when the kidney tissues were examined histopathologically (Fig. 5).

BPA group. When kidney tissues were examined histopathologically, severe degeneration and necrosis of the tubular epithelial cells, severe atrophy of the glomerulus, and severe hyperemia of the vessels were observed (Fig. 5).

BPA+PCA50 group. When kidney tissues were examined histopathologically, moderate degeneration and mild necrosis in the tubular epithelial cells, moderate atrophy in the glomeruli, and severe hyperemia in the vessels were detected (Fig. 5).

BPA+PCA100 group. When kidney tissues were examined histopathologically, mild degeneration of the tubular epithelial cells, mild atrophy of the glomerulus, and moderate hyperemia of the vessels were observed (Fig. 5). A statistically significant difference ($P < 0.05$) was detected compared to the BPA group. Histopathological findings are summarized in Table 1.

Discussion

The kidneys are one of the essential organs in the body. The kidneys have critical roles which are basically removing metabolites and harmful substances from the body, maintaining water balance, maintaining electrolyte and acid-base balance, regulating blood pressure, stimulating the production of erythrocytes, and activating Vitamin D3 in the body (O’SULLIVAN et al., 2017). With these tasks, the kidneys have a crucial role in maintaining homeostasis in the body. BPA has been detected in food samples, the environment, human blood and serum, placenta, urine, and cosmetic products used. Detection of BPA in biological samples is a significant problem because these tissues and organs are susceptible to the toxic effects of BPA (DI BELLA et al., 2018; ANET et al., 2019). PCA is a compound with anti-oxidative and anti-inflammatory effects (BOZ, 2015). In this study, we examined the harmful effects of BPA and the protective effects of PCA in the kidney tissue

of rats. This study showed that BPA decreased the level of renal antioxidants in the kidney tissue, increased the levels of MDA and NO, and caused

degeneration and necrosis in the tubular epithelium, atrophy in the glomerulus, and hyperemia in the vessels, while PCA reduced these effects.

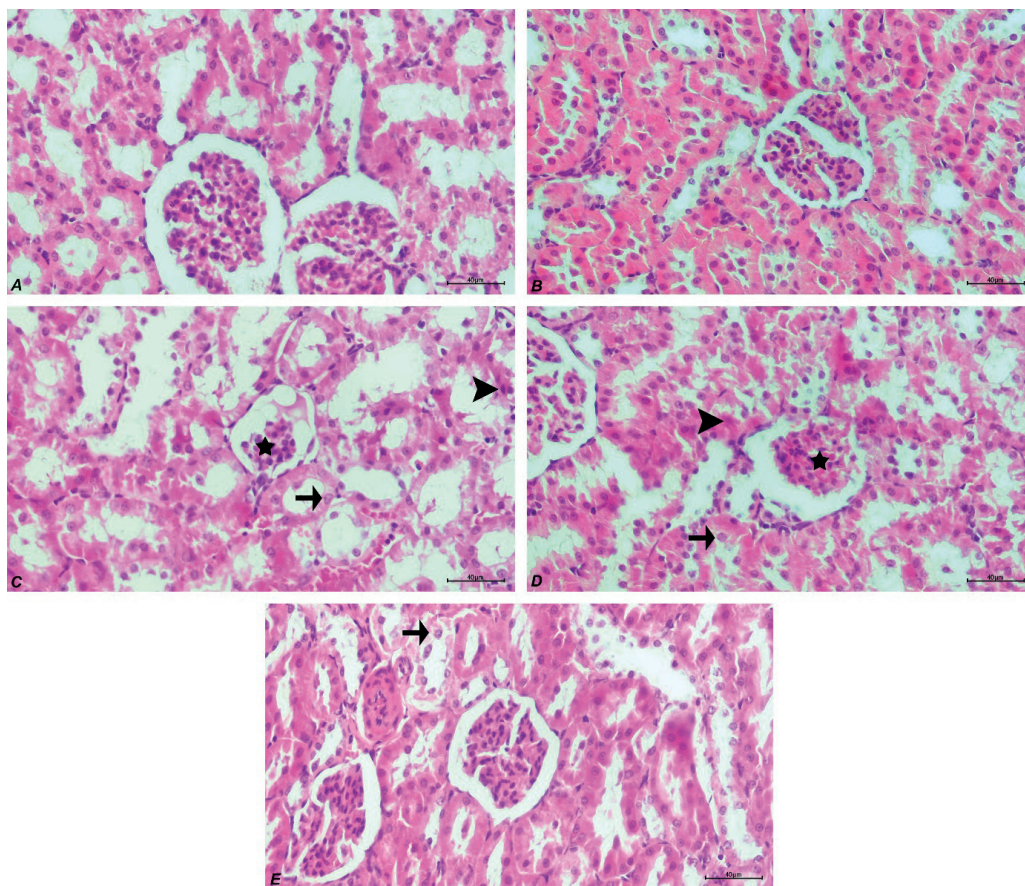


Fig. 5. Kidney tissue, Control group (A) and PCA group (B) - normal histological appearance, BPA (C) and BPA+PCA50 (D), degeneration (arrow) and necrosis (arrowhead) in tubular epithelial cells, atrophy of the glomeruli (star), degeneration of BPA+PCA100 (E) tubular epithelial cells (arrow), H&E, Bar:40µm

Table 1. Histopathological findings and scoring in kidney tissues

	Degeneration of tubular epithelium	Necrosis of tubule epithelium	Atrophy of the glomeruli	Hyperemia in the veins
Control	-	-	-	-
PCA	-	-	-	-
BPA	+++	+++	+++	+++
BPA+PCA50	++	+	++	+++
BPA+PCA100	+	-	+	++

An increased amount of ROS in a cell causes cellular oxidative stress and, thus, oxidative damage (RATLIFF et al., 2016) regardless of species, is enhanced generation of reactive oxygen species (ROS). Previous studies have shown that oxidative stress significantly affects mammalian cells exposed to BPA (ZHAO et al., 2019). In fact, in one study, increased ROS and RNS in kidney tissue cells due to BPA exposure reacted with lipids in the cell wall and increased MDA, a lipid peroxidation product (JAYA et al., 2019). In our research, while MDA levels increased significantly due to BPA application, SOD and GSH levels decreased significantly. In another study, BPA reduced the levels of SOD and GSH, which are involved in the antioxidant defense system in a cell. (KOBROOB et al., 2018). In BPA+PCA groups, MDA and antioxidant levels were close to the control. JAYA et al. (2019) and KOBROOB et al. (2018) also observed similar findings in parallel with our study.

NO is an inactive free radical. NO synthesized from L-arginine by nitric oxide synthase (NOS) induces apoptosis, inflammation, and autophagy. One study indicated that NO levels increase under heavy oxidative stress, autophagy, and apoptosis (HE et al., 2014). Similarly, in our study, NO levels increased in kidney tissue cells due to BPA application. Depending on the dose, the NO level was lower in the BPA+PCA groups.

Our research showed that there was degeneration and necrosis in the tubular epithelium, glomerular atrophy, and hyperemia in the vessels in the kidney tissue due to BPA application. Damage to the tissue due to BPA application was evaluated histopathologically. A study that supports our findings showed glomerular and tubular degeneration, vascular congestion, and cell infiltrations due to BPA application (ASLANTURK and UZUNHISARCIKLI, 2020). It was determined that the application of PCA and BPA significantly reduced these changes in a dose-dependent manner.

In summary, human beings are constantly exposed to BPA throughout their lives. BPA accumulates in vital organs, especially the kidneys. As a result of this study, using a rat model, it can be said that PCA can minimize many harmful effects caused by BPA. Accordingly, MDA and NO levels

increase. It was observed that GSH and SOD levels, which have roles in the antioxidant defense system, decreased due to BPA application. At the same time, BPA administration causes degeneration and necrosis in the tubular epithelial cells of kidney tissue, glomerular atrophy, and hyperemia in the vessels. It was observed that the application of PCA and BPA dose-dependently prevented oxidative stress and tissue damage caused by the application of BPA to the tissues.

Contributions of the Authors

BL and AC were involved in the study's design, implementation, and publication. MB participated in both the experiment's implementation and writing the article.

Conflicts of Interest

The authors declare that there is no conflict of interest.

Ethical approval

This study protocol was approved by the Atatürk University Animal Experiments Local Ethics Committee (HADYEK, Decision No: 2022/10-186).

References

- ABDEL-WAHAB, M. H., M. A. EL-MAHDY, M. F. ABDEL-ELLAH, G. K. HELAL, F. M. A. HAMADA (2003): Influence of p-Coumaric acid on doxorubicin-induced oxidative stress in rat's heart. *Pharmacol. Res.* 48, 461-465. [https://doi.org/10.1016/s1043-6618\(03\)00214-7](https://doi.org/10.1016/s1043-6618(03)00214-7)
- AN, S. M, J. S. KOH, Y. C. BOO (2010): P-Coumaric acid not only inhibits human tyrosinase activity in vitro but also melanogenesis in cells exposed to UVB. *Phytother. Res.* 24, 1175-1180. <https://doi.org/10.1002/ptr.3095>
- ANET, A., S. OLAKKARAN, A. K. PURAYIL, G. H. PUTTASWAMYGOWDA (2019): Bisphenol A induced oxidative stress mediated genotoxicity in *Drosophila melanogaster*. *J. Hazard. Mater.* 370, 42-53. <https://doi.org/10.1016/j.jhazmat.2018.07.050>
- ASLANTURK, A., M. UZUNHISARCIKLI (2020): Protective potential of curcumin or taurine on nephrotoxicity caused by bisphenol A. *Environ. Sci. Pollut. Res. Int.* 27, 23994-24003. <https://doi.org/10.1007/s11356-020-08716-1>

- BHARGAVA, P., R. G. SCHNELLMANN (2017): Mitochondrial energetics in the kidney. *Nat. Rev. Nephrol.* 13, 629-646.
<https://doi.org/10.1038/nrneph.2017.107>
- BOZ, H. (2015): p-Coumaric acid in cereals: presence, antioxidant and antimicrobial effects. *Int. J. Food Sci. Technol.* 50, 2323-2328.
<https://doi.org/10.1111/ijfs.12898>
- CALAFAT, A. M., X. YE, L. Y. WONG, J. A. REIDY, L. L. NEEDHAM (2008): Exposure of the U.S. population to bisphenol A and 4-tertiary-octylphenol: 2003-2004. *Environ. Health Perspect.* 116, 39-44.
<https://doi.org/10.1289/ehp.10753>
- CAO, X-L., C. PEREZ-LOCAS, G. DUFRESNE, G. CLEMENT, S. POPOVIC, F. BERARDIN, R. W. DABEKA, M. FEELEY (2011): Concentrations of bisphenol A in the composite food samples from the 2008 Canadian total diet study in Quebec City and dietary intake estimates. *Food Addit. Contam. Part A Chem. Anal. Control Expo. Risk Assess.* 28, 791-798.
<https://doi.org/10.1080/19440049.2010.513015>
- CASTELLUCCIO, C., G. PAGANGA, N. MELIKIAN, G. PAULBOLWELL, J. PRIDHAM, J. SAMPSON, C. RICE-EVANS (1995): Antioxidant potential of intermediates in phenylpropanoid metabolism in higher plants. *FEBS Lett.* 368, 188-192.
[https://doi.org/10.1016/0014-5793\(95\)00639-q](https://doi.org/10.1016/0014-5793(95)00639-q)
- DEVECI, M. Z. Y., H. ERDAL (2022): Determination of dynamic thiol-disulfide levels in dairy cattle with foot disease. *Vet. arhiv* 92, 657-666.
<https://doi.org/10.24099/vet.arhiv.1785>
- DI BELLA, G., H. BEN MANSOUR, A. BEN TEKAYA, A. BELTIFA, A. G. POTORTÌ, E. SAIYA, G. BARTOLOMEO, G. DUGO, L. LO TURCO (2018): Plasticizers and BPA Residues in Tunisian and Italian Culinary Herbs and Spices. *J. Food Sci.* 83, 1769-1774.
<https://doi.org/10.1111/1750-3841.14171>
- FENICHEL, P., H. DECHAUX, C. HARTHE, J. GAL, P. FERRARÌ, P. PACINÌ, K. WAHLER-MAGNER, M. PUGEAT, F. BRUCKER-DAVIS (2012): Unconjugated bisphenol A cord blood levels in boys with descended or undescended testes. *Hum. Reprod.* 27, 983-990.
<https://doi.org/10.1093/humrep/der451>
- FERGUSON, L. R., I. F. LIM, A. E. PEARSON, J. RALPH, P. J. HARRIS (2003): Bacterial antimutagenesis by hydroxycinnamic acids from plant cell walls. *Mutat. Res.* 542, 49-58.
<https://doi.org/10.1016/j.mrgentox.2003.08.005>
- GULES, O., M. YILDIZ, Z. NASEER, M. TATAR (2019): Effects of folic acid on testicular toxicity induced by bisphenol-A in male Wistar rats. *Biotech. Histochem.* 94, 26-35.
<https://doi.org/10.1080/10520295.2018.1493222>
- HE, H., Y. S. FENG, L. H. ZANG, W. W. LIU, L. Q. DING, L. X. CHEN, N. KANG, T. HAYASHI, S. I. TASHIRO, S. ONODERA, F. QIU, T. IKEJIMA (2014): Nitric oxide induces apoptosis and autophagy; autophagy down-regulates NO synthesis in physalin A-treated A375-S2 human melanoma cells. *Food Chem. Toxicol.* 71, 128-135.
<https://doi.org/10.1016/j.fct.2014.06.007>
- JAYA, A. S. G., M. GOWTHAMI, G. SRIKANTH, M. M. KRISHNA, K. R. SIRESSHA, M. SAJJARAO, K. NAGARJUNA, M. NAGARJUNA, G. K. CHINNABOINA, A. MISHRA, N. SREEHARSHA (2019): Protective role of luteolin against bisphenol A-induced renal toxicity through suppressing oxidative stress, inflammation, and upregulating Nrf2/ARE/HO-1 pathway. *IUBMB Life* 71, 1041-1047.
<https://doi.org/10.1002/iub.2066>
- JIANG, W., H. ZHAO, L. ZHANG, B. WU, Z. ZHA (2020): Maintenance of mitochondrial function by astaxanthin protects against bisphenol A-induced kidney toxicity in rats. *Biomed. Pharmacother.* 121, 109629.
<https://doi.org/10.1016/j.biopha.2019.109629>
- KABUTO, H., S. HASUIKE, N. MINAGAWA, T. SHISHIBORI (2003): Effects of bisphenol A on the metabolisms of active oxygen species in mouse tissues. *Environ. Res.* 93, 31-35.
[https://doi.org/10.1016/s0013-9351\(03\)00062-8](https://doi.org/10.1016/s0013-9351(03)00062-8)
- KATARIA, A., L. TRASANDE, H. TRACHTMAN (2015): The effects of environmental chemicals on renal function. *Nat. Rev. Nephrol.* 11, 610-25.
<https://doi.org/10.1038/nrneph.2015.94>
- KING, A., G. YOUNG (1999): Characteristics and occurrence of phenolic phytochemicals. *J. Am. Diet. Assoc.* 99, 213-218.
[https://doi.org/10.1016/S0002-8223\(99\)00051-6](https://doi.org/10.1016/S0002-8223(99)00051-6)
- KOBROOB, A., W. PEERAPANYASUT, N. CIHATTIPAKORN, O. WONGMEKIAT (2018): Damaging effects of bisphenol A on the kidney and the protection by melatonin: Emerging evidences from in vivo and in vitro studies. *Oxid. Med. Cell. Longev.* 2018, 3082438.
<https://doi.org/10.1155/2018/3082438>
- LO TURCO, V., A. G. POTORTÌ, H. BEN MANSOUR, G. DUGO, G. DI BELLA (2020): Plasticizers and BPA in spices and aromatic herbs of Mediterranean areas. *Nat. Prod. Res.* 34, 87-92.
<https://doi.org/10.1080/14786419.2019.1591403>
- LUCERI, C., L. GIANNINI, M. LODOVICI, E. ANTONUCCI, R. ABBATE, E. MASINI, P. DOLARA (2007): p-Coumaric acid, a common dietary phenol, inhibits platelet activity in vitro and in vivo. *Br. J. Nutr.* 97, 458-463.
<https://doi.org/10.1017/S0007114507657882>
- MIKOŁAJEWSKA, K., J. STRAGIEROWICZ, J. GROMADZIŃSKA (2015): Bisphenol A—Application, sources of exposure and potential risks in infants, children

- and pregnant women. *Int. J. Occup. Med. Environ. Health*. 28, 209-241.
<https://doi.org/10.13075/ijom.1896.00343>
- MOUNEIMNE, Y., M. NASRALLAH, N. KHOUEIRY-ZGHEIB, L. NASREDDINE, N. NAKHOUL, H. ISMAIL, M. ABIAD, L. KOLEIAT, H. TAMIM (2017): Bisphenol A urinary level, its correlates, and association with cardiometabolic risks in Lebanese urban adults. *Environ. Monit. Assess.* 189, 517.
<https://doi.org/10.1007/s10661-017-6216-8>
- O'SULLIVAN, E. D., J. HUGHES, D. A. FERENBACH (2017): Renal aging: causes and consequences. *J. Am. Soc. Nephrol.* 28, 407-420.
<https://doi.org/10.1681/ASN.2015121308>
- PEERAPANYASUT, W., A. KOBROOB, S. PALEE, N. CHATTIPAKORN, O. WONGMEKIAT (2019): Activation of Sirtuin 3 and Maintenance of Mitochondrial Integrity by N-Acetylcysteine Protects Against Bisphenol A-Induced Kidney and Liver Toxicity in Rats. *Int. J. Mol. Sci.* 20, 267.
<https://doi.org/10.3390/ijms20020267>
- POSNACK, N. G. (2014): The Adverse Cardiac Effects of Di(2-ethylhexyl)phthalate and Bisphenol A. *Cardiovasc. Toxicol.* 14, 339-357.
<https://doi.org/10.1007/s12012-014-9258-y>
- PRAGASAM, S. J., V. VENKATESAN, M. RASOOL (2013): Immunomodulatory and anti-inflammatory effect of p-Coumaric acid, a common dietary polyphenol on experimental inflammation in rats. *Inflammation* 36, 169-176.
<https://doi.org/10.1007/s10753-012-9532-8>
- PRASANNA, N., D. N. KRISHNAN, M. RASOOL (2013): Sodium arsenite-induced cardiotoxicity in rats: protective role of p-Coumaric acid, a common dietary polyphenol. *Toxicol. Mech. Methods.* 23, 255-262.
<https://doi.org/10.3109/15376516.2012.748116>
- RATLIFF, B. B., W. ABDULMAHDI, R. PAWAR, M. S. WOLIN (2016): Oxidant mechanisms in renal injury and disease. *Antioxid. Redox Signal.* 25, 119-146.
<https://doi.org/10.1089/ars.2016.6665>
- RICHTER, C., L. BIRNBAUM, L. S. BIRNBAUM, F. FARABOLLINI, R. R. NEWBOLD, B. S. RUBIN, C. E. TALSNESS, J. G. VANDENBERGH, D. R. WALSER-KUNTZ, F. S. VOM-SAAL (2007): In vivo effects of bisphenol A in laboratory rodent studies. *Reprod. Toxicol.* 24, 199-224.
<https://doi.org/10.1016/j.reprotox.2007.06.004>
- TAKAHASHI, O., S. OISHI (2003): Toxicology SO-F and chemical, 2003 U. Testicular toxicity of dietarily or parenterally administered bisphenol A in rats and mice. *Food Chem. Toxicol.* 41, 1035-1044.
[https://doi.org/10.1016/s0278-6915\(03\)00031-0](https://doi.org/10.1016/s0278-6915(03)00031-0)
- TAO, S., L. NIU, L. CAI, Y. GENG, C. HUA, Y. NI, R. ZHAO (2018): N-(3-oxododecanoyl)-L-homoserine lactone modulates mitochondrial function and suppresses proliferation in intestinal goblet cells. *Life Sci.* 201, 81-88.
<https://doi.org/10.1016/j.lfs.2018.03.049>
- TAO, S., Y. LUO, B. HE, J. LIU, X. QIAN, Y. NI, R. ZHAO (2016): Paraoxonase 2 modulates a proapoptotic function in LS174T cells in response to quorum sensing molecule N-(3-oxododecanoyl)-L-homoserine lactone. *Sci. Rep.* 6, 28778.
<https://doi.org/10.1038/srep28778>
- TEKIN, S., F. CELEBI (2022): Investigation of the effect of hesperidin on some reproductive parameters in testicular toxicity induced by Bisphenol A. *Andrologia* 54, 14562.
<https://doi.org/10.1111/and.14562>
- TEKIN, S., Y. DAG, M. BOLAT, E. SENGUL (2021): Effects of p-Coumaric Acid on Kidney Injury Molecule-1 in Bisphenol A induced Nephrotoxicity in Rats. *J. Lab. Anim. Sci. Pract.* 1, 1-7.
- TURK, R., D. JURETIĆ, D. GEREŠ, A. SVETINA, N. TURK, Z. FLEGAR-MEŠTRIĆ (2008): Influence of oxidative stress and metabolic adaptation on PON1 activity and MDA level in transition dairy cows. *Anim. Reprod. Sci.* 108, 98-106.
<https://doi.org/10.1016/j.anireprosci.2007.07.012>
- XIA, W., Y. JIANG, Y. LI, Y. WAN, J. LIU, Y. MA, Z. MAO, H. CHANG, G. LI, B. XU, S. XU (2014): Early-life exposure to bisphenol A induces liver injury in rats involvement of mitochondria-mediated apoptosis. *PLoS One* 9, 90443.
<https://doi.org/10.1371/journal.pone.0090443>
- ZHAO, Z., W. QU, K. WANG, S. CHEN, L. ZHANG, D. WU, Z. CHEN (2019): Bisphenol A inhibits mucin 2 secretion in intestinal goblet cells through mitochondrial dysfunction and oxidative stress. *Biomed. Pharmacother.* 111, 901-908.
<https://doi.org/10.1016/j.biopha.2019.01.007>

Received: 4 December 2022

Accepted: 26 April 2023

Online publication date: 15 March 2024

LAÇIN, B. B., M. BOLAT, A. ÇINAR: Istraživanje učinaka p-kumarične kiseline na malondialdehid (MDA), neke antioksidanse i histopatološke pokazatelje kod nefrotoksičnosti uzrokovane bisfenolom A u štakora. Vet. arhiv 94, 155-164, 2024.

SAŽETAK

Cilj je rada bio istražiti zaštitnu ulogu p-kumarične kiseline (PCA) u otkrivanju oksidacijskog i ciljanog oštećenja pri elongaciji tkiva štakora uzrokovanoj bisfenolom A (BPA). BPA je polutant iz okoliša široko upotrebljavan u mnogim područjima. Rasprostranjena upotreba ove kemikalije povećava njezine učinke na ljude. BPA uzrokuje oštećenja mnogih tkiva i organa, a jedan od organa koji može biti najviše zahvaćen jest bubreg. U ovom je istraživanju upotrijebljeno 50 zdravih mužjaka štakora kako bi se ustanovili učinci BPA-a i PCA-a. Životinje su podijeljene u pet pokusnih skupina po deset jedinki. Skupina 1 bila je kontrolna, skupini 2 dan je BPA, skupini 3 BPA i PCA50, skupini 4 BPA i PCA100, a skupini 5 PCA100. Pokus je trajao 14 dana. Po završetku pokusa su na tkivu bubrega primijenjeni bojenje hematoksilin-eozinom i ELISA test. Testom ELISA utvrđene su razine malondialdehida (MDA), glutationa (GSH), superoksid-dismutaze (SOD) i dušikova oksida (NO). Uočene su povećane razine MDA-a i NO-a u bubregu štakora u skupinama kojima je primijenjen BPA, dok su se razine SOD-a i GSH-a snizile. U tkivu bubrega štakora kojima je primijenjen BPA histopatološki je uočena degeneracija i nekroza u tubularnom epitelu, glomerularna atrofija i hiperemija u krvnim žilama. U skupinama BPA i PCA zapaženo je da je PCA spriječio negativne učinke BPA-a i, ovisno o dozi, pomogao da se održe približne vrijednosti kao u kontrolnoj skupini.

Ključne riječi: bubreg; bisfenol A; p-kumarična kiselina; štakor; toksičnost; oksidacijski stres
