

Mehanička komplikacija infarkta miokarda – ili ne? – Prikaz slučaja

A Mechanical Complication in Myocardial Infarction – or not? – A Case Report

Fabio Kadum*,
Ana Petretić,
Koraljka Benko,
Slavica Kovačić

Klinički bolnički centar Rijeka,
Rijeka, Hrvatska
University Hospital Centre
Rijeka, Rijeka, Croatia

SAŽETAK: Prikazujemo 55-godišnjeg bolesnika sa subakutnim infarktomiokarda i hemoragičnim perikardijalnim izljevom koji je doveo do tamponade srca. Bolesnik se očitovao kliničkom slikom šoka s anamnestičkim podatkom o trodnevnoj vrućici, a u noći prijema opetovanim sinkopama. Učinjenom koronarografijom utvrđena je subakutna okluzija prve marginalne grane lijeve koronarne arterije te je u istom aktu učinjena perkutana koronarna intervencija navedene lezije, kao i perikardiocenteza uz evakuaciju 450 mL hemoragičnog perikardijalnog izljeva. Ekstenzivnom slikovnom obradom isključena je ruptura slobodne stijenke lijeve klijetke. Laboratorijskom obradom nije dokazano postojanje pridružene imunološke ili maligne bolesti. Po učinjenome, tijekom hospitalizacije i u šestomjesečnom razdoblju praćenja, stanje bolesnika je stabilno, a perikardijalni je izljev u regresiji.

SUMMARY: We present the case of a 55-year-old male patient with subacute myocardial infarction and hemorrhagic pericardial effusion that led to cardiac tamponade. The patient presented with the clinical picture of shock and a medical history of a three-day fever, as well as repeated syncope the night before admission. Coronarography established subacute occlusion of the first marginal branch of the left coronary artery, and percutaneous coronary intervention was performed on the first marginal branch, and pericardiocentesis was performed as well, which resulted in the evacuation of 450 mL of hemorrhagic pericardial effusion. Extensive imaging eliminated rupture of the left ventricular free wall. Laboratory testing did not demonstrate the presence of comorbid immunological or malignant diseases. The patient's status subsequently remained stable during hospitalization and in the six-month follow-up, and the pericardial effusion is in regression.

KLJUČNE RIJEČI: infarkt miokarda, perikardiocenteza, tamponada srca.

KEYWORDS: myocardial infarction, pericardiocentesis, cardiac tamponade.

CITATION: *Cardiol Croat.* 2024;19(7-8):314-21. | <https://doi.org/10.15836/ccar2024.314>

***ADDRESS FOR CORRESPONDENCE:** Fabio Kadum, Klinički bolnički centar Rijeka, Tome Stričića 3, HR-51000 Rijeka, Croatia. / Phone: +385-51-407225 / E-mail: kadum.fabio@gmail.com

ORCID: Fabio Kadum, <https://orcid.org/0009-0007-4525-9103> • Ana Petretić, <https://orcid.org/0000-0002-5767-1206>
Koraljka Benko, <https://orcid.org/0000-0001-7556-0860> • Slavica Kovačić, <https://orcid.org/0000-0002-7419-224X>

TO CITE THIS ARTICLE: Kadum F, Petretić A, Benko K, Kovačić S. A Mechanical Complication in Myocardial Infarction – or not? – A Case Report. *Cardiol Croat.* 2024;19(7-8):314-21. | <https://doi.org/10.15836/ccar2024.314>

TO LINK TO THIS ARTICLE: <https://doi.org/10.15836/ccar2024.314>

RECEIVED:
May 26, 2024

UPDATED:
June 25, 2024

ACCEPTED:
July 2, 2024



Uvod

Perikardijalni izljev u akutnom infarktu miokarda nije rijetka pojava. Incidencija iznosi između 15 i 28 % u bolesnika koji se prezentiraju prvim infarktomiokarda, a sama zahvaćenost perikarda povezana je s većom stopom morbiditeta i mortaliteta tih bolesnika^{1,2}. Zahvaćenost perikarda može se manifestirati kao perikardijalni izljev, epistenokardični perikarditis ili Dresslerov sindrom. Danas, u eri primarnih perkutanih koronarnih intervencija (PCI), viđa se rjeđe nego što je to bilo u eri fibrinolize. Epistenokardični perikarditis obično je samoograničavajuća pojava koja nastupa tijekom prvoga tjedna bolesti dok je Dresslerov sindrom autoimunosna bolest koja se može pojaviti i do nekoliko mjeseci na-

Introduction

Pericardial effusion in acute myocardial infarction is not a rare phenomenon. The incidence is between 15% to 28% in patients who present with first myocardial infarction, and affection of pericardium is associated with higher rates of morbidity and mortality in these patients^{1,2}. The pericardial area being affected can manifest as pericardial effusion, pericarditis episteno-cardica, or Dressler syndrome. It is less common today, in the era of percutaneous coronary interventions (PCI), than it was in the era of fibrinolysis. Pericarditis episteno-cardica is usually a self-limiting phenomenon that occurs during the first week of the disease, while Dressler syndrome is an autoimmune disease that can

kon preboljelog infarkta. Postinfarktni perikardijalni izljev malokad je dovoljno velik da uzrokuje tamponadu srca, a potencijalni su uzroci zahvaćenost perikarda s hemoragičnim perikarditisom, transmuralni infarkt s rupturom slobodne stijenke klijetke te ijtrogena perforacija koronarnih arterija tijekom PCI-a³.

Prikaz bolesnika

Pedesetpetogodišnji muškarac dovezen je u Objedinjeni hitni bolnički prijem (OHBP) vozilom izvanbolničke hitne medicinske pomoći (HMP) zbog višestrukih sinkopa i febrilnosti. U noći prijema bolesnik se nekoliko puta budio da bi provjerio vrijednost tjelesne temperature te pritom u nekoliko navrata gubi svijest. Od djelatnika HMP-a doznaje se da je bolesnik posljednja tri dana prije prijema bio febrilan do 38,5 °C te da je prema potrebi uzimao paracetamol i ibuprofen. Prehospitalno je bolesnik bio hipotenzivan s vrijednostima arterijskoga tlaka (AT) od 70/30 mmHg te hladno preznoj. Snimljenim 12-kanalnim elektrokardiografskim (EKG) zapisom verificira se sinusni ritam uz tek diskretnu elevaciju ST-segmenta u inferolateralnim odvodima (slika 1).

manifest as much as several months after the infarction. Postinfarction pericardial effusion is rarely large enough to cause cardiac tamponade, and its causes include the pericardium being affected by hemorrhagic pericarditis, transmural infarction with rupture of the ventricular free wall, and iatrogenic perforation of coronary arteries during PCI³.

Case report

A 55-year-old man was brought to the Joint Emergency Hospital Admission (JEHA) by an ambulance vehicle due to multiple incidents of syncope and febrility. During the first night after admission, the patient lost consciousness several times when waking to routinely measure body temperature values. Emergency medical personnel reported that the patient had been febrile during the three days before admission, with a body temperature of 38.5 °C. The patient was using paracetamol and ibuprofen to reduce body temperature. Pre-admission, the patient was hypotensive, with arterial pressure (AP) values of 70/30 mmHg and presenting with cold sweat. A 12-lead electrocardiogram (ECG) verified sinus rhythm with discrete ST-segment elevation in the inferolateral leads (Figure 1).

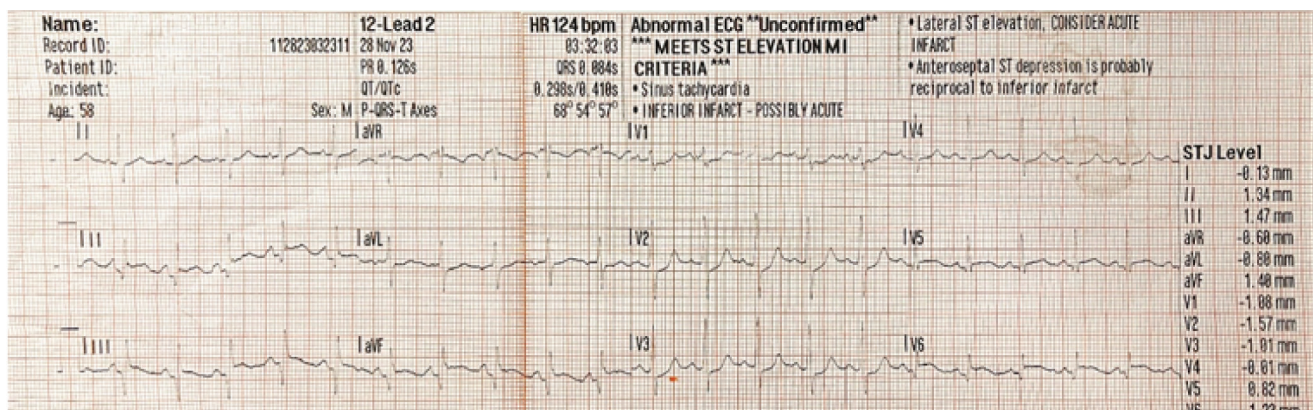


FIGURE 1. Prehospital electrocardiogram showing discrete ST-segment elevation in the inferolateral leads.

Nakon dolaska u OHPB bolesnik je pri svijesti, lošega općeg stanja, subfebrilan (37,6 °C), psihomotorno nemiran, blijede i hladno preznojene kože. Bolesnik je preuhranjen, indeks tjelesne mase iznosio je 29,6 kg/m² te je riječ o pušaču koji posljednjih 30 godina puši deset cigareta na dan.

U fizikalnom je statusu nemjerljivih vrijednosti AT-a te tahikardan do 120 otkucaja u minuti uz vrijednosti saturacije kisika od 95 %. Auskultacijski je utišan šum disanja nad bazama pluća, a akcija srca je ritmična uz tihe srčane tonove, a šumovi se nisu čuli. Uz promptno zbrinjavanje ponovljen je EKG kojim je verificirana depresija ST-segmenta u prekordijalnim odvodima V1 – V3 (slika 2). Bolesnik se istodobno počinje žaliti na nelagodu u gornjem dijelu abdomena uz omaglicu u sjedećem položaju, zbog čega je uz hitno uzorkovanje laboratorijskih nalaza primijenjen ultrazvuk prema protokolima *Focused Abdominal Sonography for Trauma* i *Focus-Assessed Transthoracic Echocardiography*. Osim cirkumferentnoga perikardijalnog izljeva gušće konzistencije,

Upon admission to JEHA, the patient was conscious, in a poor general state, subfebrile (37.6 °C), exhibiting psychomotor agitation, and with pallid skin covered in cold sweat. The patient was overweight, with a body-mass index of 29.6 kg/m², and was a smoker, having smoked 10 cigarettes per day for 30 years.

With regard to the patient's physical state, his AP was unmeasurable and he presented with tachycardia with up to 120 beats per minute and 95% oxygen saturation. Auscultation found muffled breath sounds at the lung bases, and the action of the heart was rhythmic, with quiet heart tones and no murmur. Prompt treatment included another ECG, which verified ST-segment depression in the precordial leads V1-V3 (Figure 2). The patient simultaneously began complaining about discomfort in the upper part of the abdomen, as well as lightheadedness in the sitting position, which led to rapid sampling for laboratory tests and the performance of an ultrasound examination according to the Focused Abdominal

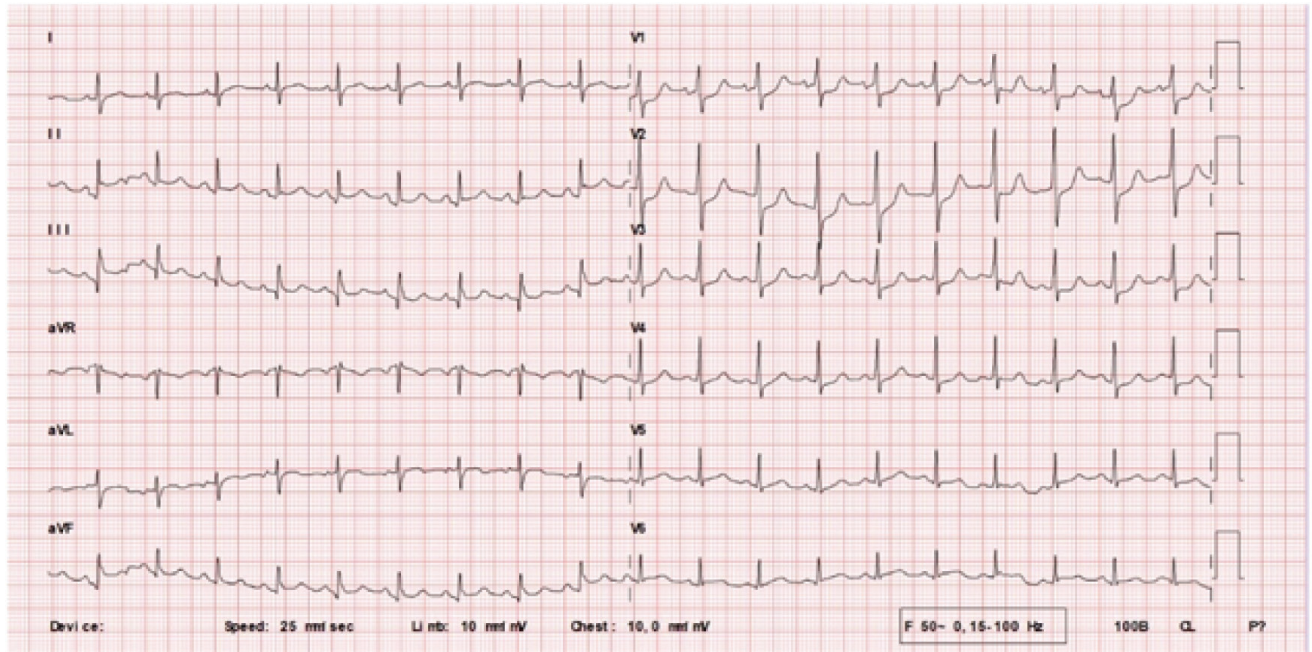


FIGURE 2. In-hospital electrocardiogram showing ST-segment depression in the precordial leads V1-V3.

preostali je nalaz bio bez značajnih odstupanja. U laboratorijskim se nalazima bilježi anemija (hemoglobin 99 g/L, MCV 99 fL) uz povišene vrijednosti upalnih parametara (leukociti $17,7 \times 10^9/L$; C-reaktivni protein 107 mg/L) te bilježa oštećenja srčanog mišića (troponin T 1816 ng/L; NT-proBNP 1255 ng/L). Sediment urina bio je uredan. U acidobaznom statusu registrirana je parcijalna respiratorna insuficijencija.

Uz parenteralnu nadoknadu volumena nastupa djelomično poboljšanje bolesnikova općeg stanja, ali uz i dalje perzistirajuću hipotenziju. Subjektivno, a na višestruke upite, bolesnik negira boli u prsima i dispneju te od simptoma navodi isključivo povišene vrijednosti tjelesne temperature uz nadutost u gornjem dijelu abdomena.

U korelaciji s kliničkom slikom postavljena je sumnja na disekciju aorte te se inicijalno konzultiraju anesteziolog i kardijalni kirurg. Učinjenom CT aortografijom isključen je akutni aortalni sindrom, kao i aktivna ekstrasvazacija kontrasta, a potvrđen je velik cirkumferentni perikardijalni izljev (**slika 3**).

Bolesnik je zaprimljen na Zavod za intenzivno kardiološko liječenje Klinike za bolesti srca i krvnih žila. Odmah nakon prijema nastavljeno je s kontinuiranom parenteralnom nadoknadom volumena (0,9 % fiziološke otopine) uz medikamentnu terapiju – furosemidom, ceftriaksonom, enoksaparinom uz tramadol i pantoprazol. Uskoro se bolesnik žali na grčevite boli u trbuhu koje se smiruju nakon obilnih proljevastih stolica. Do jutra je bolesnik subjektivno bez tegoba, poboljšana općega stanja, održane satne diureze (oko 100 mL/sat), ali uz perzistirajuće niske vrijednosti AT-a. Jutro nakon prijema obavljen je kontrolni ehokardiografski pregled uz bolesnikov krevet, kojim je verificiran perikardijalni izljev gušće konzistencije uz prateće kliničke znakove hemodinamske nestabilnosti (**slika 4**). Dimenzije srčanih šupljina bile su u granicama normale, valvularni je aparat bio bez značajnih odstupanja. Sistolička funkcija lijeve klijetke bila je blago re-

Sonography for Trauma and Focus-Assessed Transthoracic Echocardiography protocols. Other than the circumferential pericardial effusion with a thicker consistency, the rest of the findings were without significant deviations from normal values. Laboratory tests found anemia (hemoglobin 99 g/L, MCV 99 fL) with elevated inflammatory parameter values (leukocytes $17,7 \times 10^9/L$; C-reactive protein 107 mg/L), and markers of heart muscle damage (troponin T 1816 ng/L; NT-proBNP 1255 ng/L). Urine sediment values were normal. Acid-base status indicated partial respiratory insufficiency.

Parenteral volume support led to partial improvement of the patient's general state, but with persistent hypotension. Subjectively, upon repeated queries, the patient denied chest pain and dyspnea, and the only symptoms he reported were elevated body temperature and upper abdominal bloating.

Aortic dissection was suspected based on the clinical picture, and an anesthesiologist and cardiac surgeon were consulted. CT aortography excluded acute aortic syndrome and active contrast extravasation, and a large circumferential pericardial effusion was confirmed (**Figure 3**).

The patient was admitted to the Intensive Cardiological Treatment Ward at the Department of Cardiovascular Diseases. Immediately upon admission, we proceeded with continuous parenteral volume support (0.9% saline) with the addition of medication therapy – furosemide, ceftriaxone, and enoxaparin with tramadol and pantoprazole. Presently, the patient started complaining of stomach pain that abated only after passing loose and abundant stools. By morning, the patient was subjectively without complaints, with an improved general state, and with hourly diuresis (approximately 100 mL/hour), but with still persistent low AP values. A control echocardiographic bedside examination was performed on the morning after admission, which verified pericardial effusion with a thicker consistency as well as accompanying signs of hemodynamic instability (**Figure 4**). The dimensions of the heart chambers were within

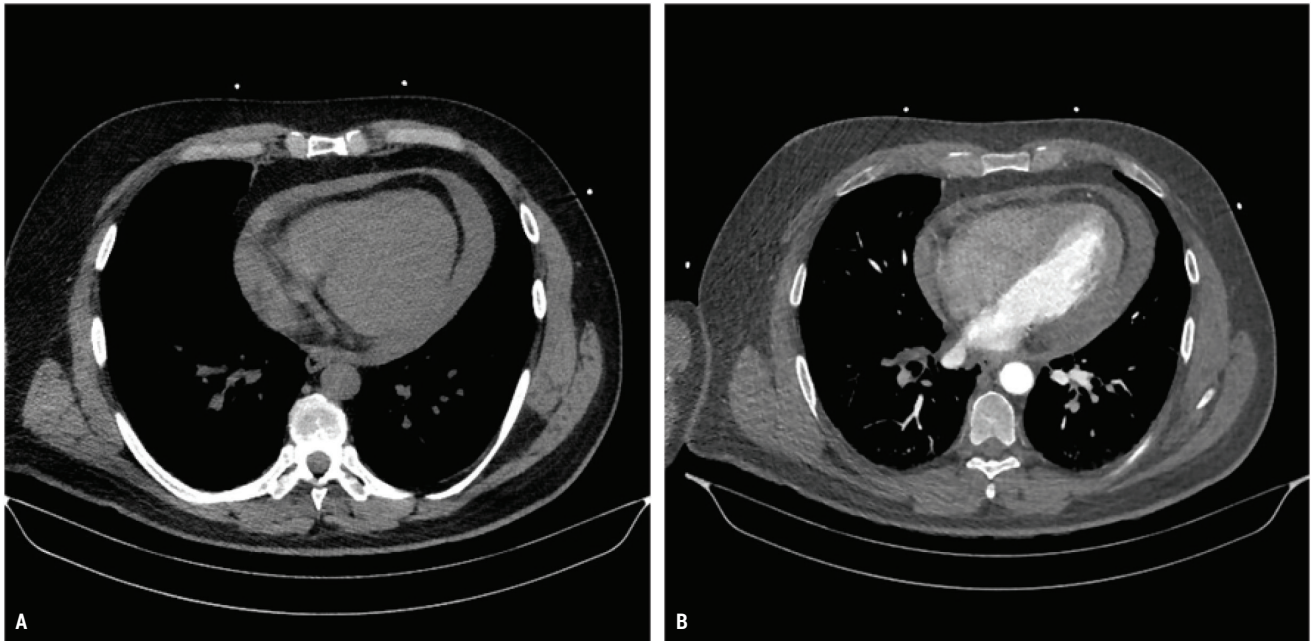


FIGURE 3. CT examination of acute aortic syndrome upon clinical request. A) axial non-contrast CT scan with hyperdense fluid in the pericardium; B) CT aortography, axial scan with contrast in the left atrium and ventricle and with pericardial effusion.

ducirana (EF 45 – 50 %), uz akineziju inferiorne, inferolateralne i anterolateralne stijenke. Postavljena je sumnja na zadržanu rupturu stijenke lijeve klijetke. Slučaj bolesnika prikazan je na hitnom internom konziliju kardiologa i kardijalnih kirurga te je pristupljeno koronarografiji. Verificirana je aterosklerotska bolest lijeve i desne koronarne arterije sa subakutnom okluzijom prve marginalne grane (OM1) i granično značajnim lezijama prednje silazne grane (LAD) lijeve koronarne arterije (**slika 5**). U istom je aktu učinjena balonska dilatacija OM1 balonskim kateterom SC (2,0 × 20 mm) uz postizanje TIMI 3 protoka. Tijekom intervencije učinjena je i perikardiocenteza i postavljen je dren u perikardijalnu šupljinu, a do kraja zahvata evakuirano je 450 mL makroskopski sukrvavog sadržaja. Uzorak je poslan na citološku analizu te je mikroskopskim pregledom u sedimentima

normal ranges, and the valvular apparatus was without significant deviations. Systolic function of the left ventricle was mildly reduced (EF 45-50%), with akinesis of the inferior, inferolateral, and anterolateral wall. Contained rupture of the left ventricular wall was suspected. The patient's case was presented at an internal emergency meeting of cardiologists and cardiac surgeons, and coronarography was subsequently performed. It verified atherosclerotic disease of the left and right coronary artery with subacute occlusion of the first marginal branch (OM1) and borderline significant lesions of the left anterior descending branch (LAD) of the left coronary artery (**Figure 5**). At the same time, balloon dilatation of the OM1 was performed using a SC balloon catheter (2.0×20.0 mm) that achieved TIMI 3 flow. Pericardiocentesis was also performed

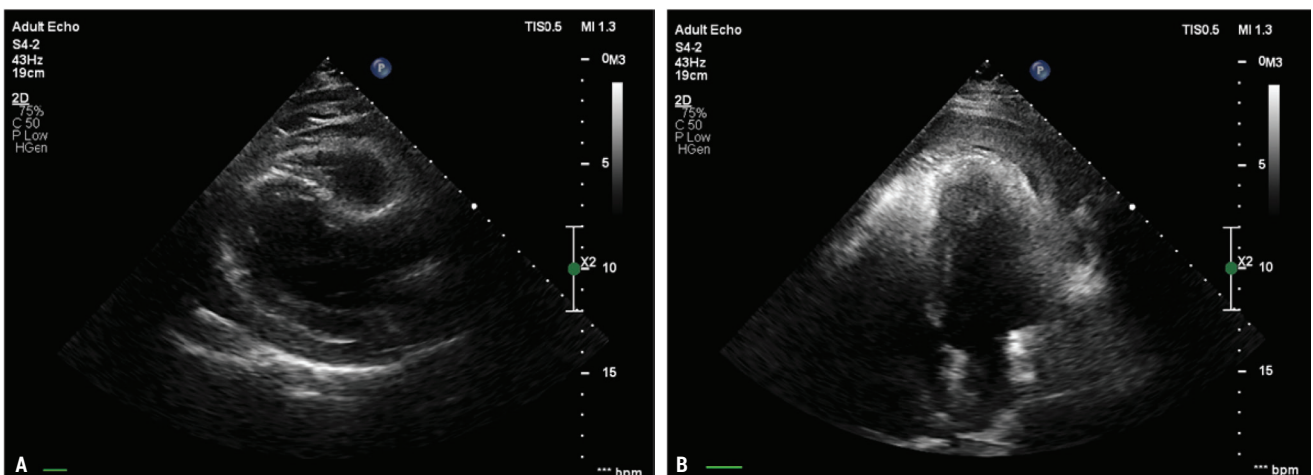


FIGURE 4. Echocardiography – large circumferential hemorrhagic pericardial effusion. A) Parasternal long axis view. B) Apical four chamber view.

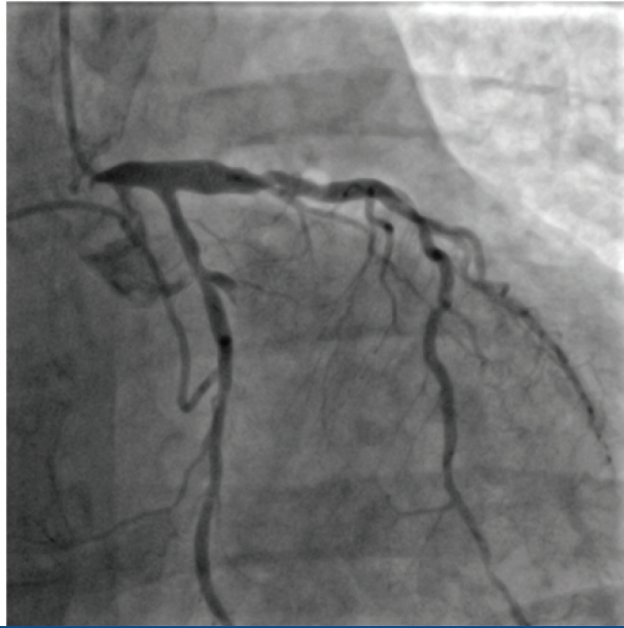


FIGURE 5. Coronary angiography showing borderline left anterior descending artery stenosis and subacute occlusion of the first marginal branch of the left coronary artery.

nađeno dosta neutrofila, nešto limfocita i obilno eritrocita, što govori u prilog miješanom tipu izljeva.

U sklopu daljnje dijagnostičke obrade, a radi isključivanja eventualne ruptуре miokarda, provedena je dodatna slikovna obrada – kontrastna ehokardiografija kojom nije prikazana jasna ekstrasvazacija kontrasta iz srčanih šupljina – te CT srca kojim je prikazan perikardijalni izljev i naglašeno izravan interventrikularni septum, ali bez ekstraluminacije kontrasta iz srčanih šupljina (slika 6). Kao usputni nalaz verificirani su i

during the intervention, and a drainage catheter was placed in the pericardial cavity, evacuating 450 mL of macroscopically sanies-like contents during the procedure. A sample was sent for cytological analysis, and microscopy of the sediments found a significant number of neutrophils, some lymphocytes, and abundant erythrocytes, indicating a mixed effusion type.

During further diagnostics, with the goal of eliminating possible myocardial rupture, we performed additional imaging – contrast echocardiography, which did not show clear contrast

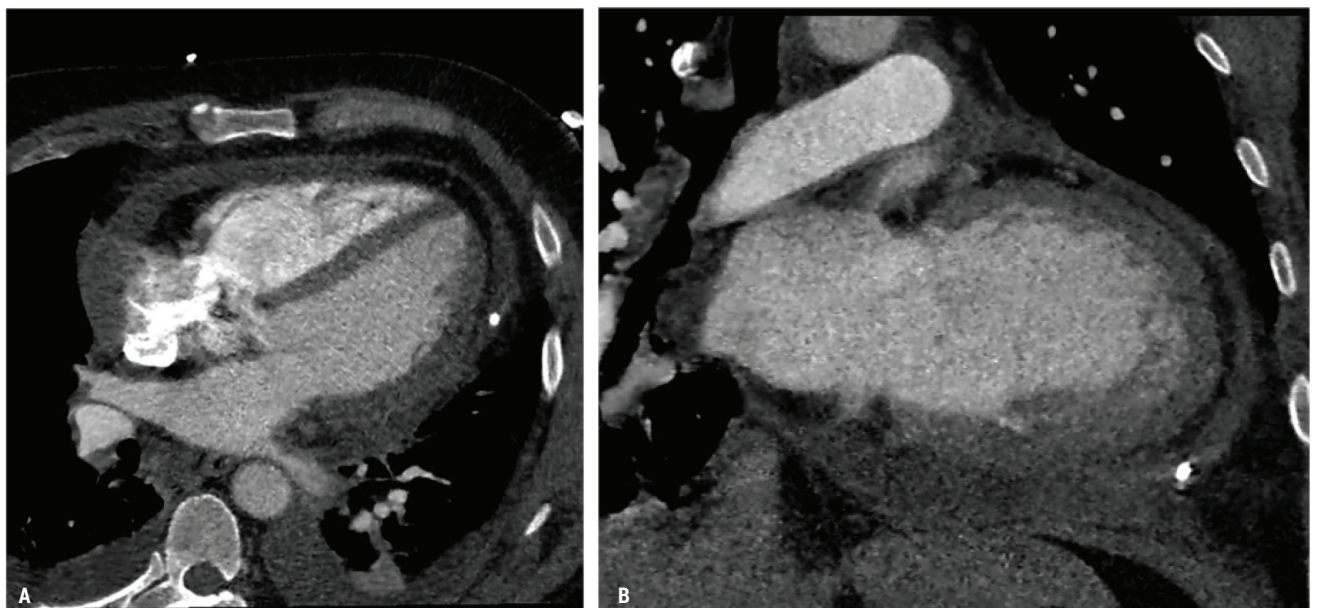


FIGURE 6. Cardiac CT with flattened septum and pericardial effusion. A) Four chamber view, B) long axis; *drainage catheter in the pericardium.

obostrani pleuralni izljevi, zbog čega je intenzivirana diuretska terapija. Obavljen je i MR srca kojim su, uz perikardijalni i pleuralne izljeve, prikazani transmuralna fibroza te zone mikrovaskularne opstrukcije lateralne i inferolateralne stijenke lijeve klijetke (slika 7). Opisana je i umjereno reducirana sistolička funkcija lijeve klijetke (EF 44 %).

Kardijalni kirurg preporučuje daljnje praćenje dinamike perikardijalnog izljeva uz mogućnost operativnog zahvata u slučaju njegove progresije.

media extravasation from the heart chambers, as well as CT imaging of the heart that showed pericardial effusion and pronounced flattening of the interventricular septum, but also without extraluminal contrast in the heart chambers (Figure 6). As an additional finding, we verified bilateral pleural effusion, which led to intensification of diuretic therapy. A heart MR was performed as well, which, in addition to pericardial and pleural effusions, showed transmural fibrosis and zones of microvascular obstruction of the lateral and inferolateral wall of the left ventricle (Figure 7). It also showed moderately reduced systolic function of the left ventricle (EF 44%).

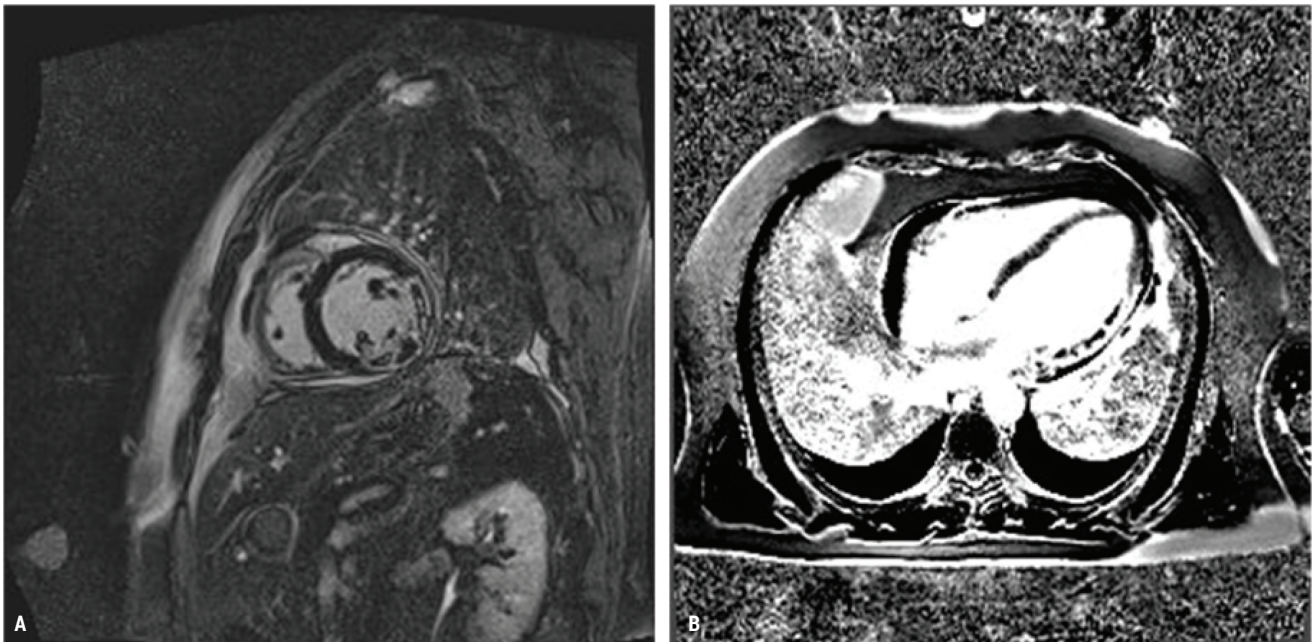


FIGURE 7. Cardiac MRI short axis view (A) and four chamber view (B) with transmural fibrosis and an area of microvascular obstruction in the lateral and inferolateral wall of the left ventricle.

Bolesnik je u daljnjem tijeku liječenja hemodinamski stabilan, produljeno monitoriran bez zabilježenih poremećaja srčanog ritma, a u više je navrata ponovljen ultrazvuk perikarda kojim je verificirana stacionarna količina perikardijalnog izljeva. Sa svrhom utvrđivanja etiologije izljeva uzorkovana je krv na tumorske markere, a rezultati su bili negativni. Također je konzilijarno zatraženo i mišljenje imunologa te infektologa, a sukladno njihovim nalazima uzorci krvi poslani su na dodatne analize. Postupno je u laboratorijskim nalazima praćen pad vrijednosti upalnih parametara, a rezultati imunoloških analiza krvi (reumatoidni faktor i anti-CCP), kao i analiza na infektivne uzročnike (HIV antigen/protutijelo, *Treponema pallidum* hemaglutininski test, Rapid plasma reagin test) bili su negativni. Nalazi višestruko uzorkovanih hemokultura i urinokultura također su pokazali sterilnost uzoraka.

Nakon dodatne stabilizacije bolesnikova stanja te optimizacije medikamentne terapije bolesnik je dogovorno premješten u ustanovu za stacionarnu kardiološku rehabilitaciju radi daljnjeg liječenja i rehabilitacije. Otpusna je terapija uključivala standardnu dvojni antitrombotsku terapiju (acetilsalicilna kiselina 100 mg te klopidogrel 75 mg), gastroprotekciju

A cardiac surgeon recommended monitoring of the dynamics of the pericardial effusion, with the option of performing a surgical intervention in case of further progression.

During subsequent treatment, the patient was hemodynamically stable, underwent prolonged monitoring with no recorded disorders in heart rhythm, and repeated pericardial ultrasounds verified a stationary volume of pericardial effusion. The patient's blood was tested for tumor markers in order to determine the etiology of the effusion, with negative results. We also requested consultation from an immunologist and infectologist, and the blood samples were sent for additional analysis based on their findings. Laboratory findings showed a gradual reduction in inflammatory parameter values, and the results of immunological analysis (rheumatoid factors and anti-CCP) as well as tests for infectious agents (HIV antigen/antibodies, *Treponema pallidum* hemagglutination test, rapid plasma reagin test) were all negative. The results of blood culture and urine culture tests from multiple samples were also sterile.

After further stabilization of the patient's state, optimization of medication treatment it was agreed that the patient

pantoprazolom 40 mg, bisoprolol 5 mg, ramipril 1,25 mg, rosuvastatin 40 mg, te kolhicin 2 x 0,5 mg. Također mu je preporučena terapija amoksicilinom s klavulonskom kiselinom 2 x 1 tbl. još dva tjedna nakon otpusta uz probiotik. Kontrolnim ultrazvukom perikarda prikazano je tek razdvajanje listova perikarda uz lateralnu stijenkicu te obostrani manji pleuralni izljevi. Bolesnik je nakon provedene stacionarne kardiološke rehabilitacije dobrog općeg stanja, kardijalno kompenziran i bez subjektivnih smetnji te je otpušten na kućno liječenje.

Kontrolnim ultrazvukom perikarda dva tjedna nakon otpusta vidi se potpuna regresija perikardijalnog izljeva. Mjesec dana poslije otpusta učinjena je planirana rekonarografija kojom se verificira značajna stenozna LAD-a te okluzija OMI od ishodišta. U istom se aktu učini *ad hoc* PCI na LAD-u primjenom dvaju stentova obloženih lijekovima (Orsiro 2,75 x 15 mm u srednji segment; Orsiro 4,0 x 18 mm u proksimalni segment), čime je postignut optimalan protok.

Rasprava

U prikazanog je bolesnika provedenom dijagnostičkom obradom utvrđeno da je bila riječ o subakutnom infarktu miokarda inferoposteriorne stijenke sa ST elevacijom kompliciranim postinfarktним hemoragičnim perikardijalnim izljevom uz kliničke znakove tamponade srca.

Zahvaćenost perikarda u infarktu miokarda je česta. Trećina bolesnika ima perikardijalni izljev, međutim, rijetki su slučajevi hematoperikarda koji dovode do tamponade srca.⁴ Bilo je nužno isključiti postojanje mehaničke komplikacije infarkta miokarda – rupturu slobodne stijenke lijeve klijetke. Isto je učinjeno ekstenzivnom slikovnom obradom.

S obzirom na anamnezu vrućice te povišene upalne parametre, diferencijalnodijagnostički, potrebno je razmotriti infektivni perikarditis. Prema postojećim smjernicama za definiciju i dijagnostičke kriterije Europskoga kardiološkog društva, u ovog je bolesnika bio zadovoljen samo kriterij perikardijalnog izljeva, što je nedovoljno za dijagnozu.⁵ Napominjemo da je auskultacija bolesnika bila znatno otežana zbog njegova općeg stanja (u kontekstu eventualne prisutnosti perikardijalnog trenja). Zbog žurnosti postupaka i bolesnikova općeg stanja uzorak perikardijalnog izljeva za hematološku analizu, kao i za mikrobiološku, nije testiran, što smatramo nedostatkom.

Jednom kad se utvrdi postojanje perikardijalnog izljeva nužna je procjena njegove hemodinamske značajnosti. Tamponada srca prije svega je klinička dijagnoza čiji tipični simptomi uključuju Beckov trijas – hipotenziju, distenziju jugularnih vena, utišane srčane tonove. Često je praćena i tahikardijom te mikrovoltadžom i električnim alternansom u EKG zapisu. Transtorakalna ehokardiografija neinvazivna je metoda izbora za potvrdu dijagnoze, a mogući znakovi uključuju: rani dijastolički kolaps slobodne stijenke desne klijetke, kasni dijastolički kolaps desne pretklijetke, „ljudanje“ srca u perikardijalnoj šupljini, dilatiranu donju šuplju venu bez inspiratornog kolapsa, >40 % inspiratorne varijabilnosti u transtricuspidnom protoku, >25 % inspiratorne varijabilnosti u transmitralnom protoku.^{5,6}

U uvodnome su dijelu teksta naglašeni najčešći uzroci tamponade srca u postinfarktnom tijeku. Poznavanje etiologije nužno je radi daljnje optimalnog pristupa u liječenju. Ako je riječ o mehaničkoj komplikaciji infarkta miokarda (ruptura slobodne stijenke), hitan operativni zahvat jedina je mogućnost preživljenja bolesnika. Ako se mehanička komplikacija

would be transferred to in-hospital cardiological rehabilitation institution for further treatment and rehabilitation. Therapy upon discharge included standard dual antiplatelet therapy (aspirin 100 mg and clopidogrel 75 mg), pantoprazole 40 mg as gastroprotection, bisoprolol 5 mg, ramipril 1.25 mg, rosuvastatin 40 mg, and colchicine 2x0.5 mg. Amoxicillin with clavulanic acid 2x1 was also recommended for two more weeks after hospital discharge, to be taken along with a probiotic.

Control pericardial ultrasound only showed separation of pericardial layers at the lateral wall and smaller bilateral pleural effusions. After in-hospital cardiological rehabilitation, the patient was discharged to home care in a good general state, compensated, and without subjective complaints.

Control pericardial ultrasound two weeks after discharge showed complete regression of the pericardial effusion. One month after discharge, a planned rekonarography we performed, which verified significant LAD stenosis and occlusion from the origin of the OMI. Simultaneously, we performed *ad hoc* PCI of the LAD using two drug-eluting stents (Orsiro 2.75x15.0 mm in the middle segment; Orsiro 4.0x18.0 mm in the proximal segment), achieving optimal blood flow.

Discussion

In our patient, diagnostic tests demonstrated subacute myocardial infarction of the lower posterior wall with ST-segment elevation, complicated by postinfarction hemorrhagic pericardial effusion with clinical signs of cardiac tamponade.

Pericardial involvement is common in myocardial infarction. A third of the patients present with pericardial effusion, but there are rare cases of hemopericardium that lead to cardiac tamponade.⁴ We had to eliminate the presence of a mechanical complication of myocardial infarction – left ventricular free wall rupture. This was achieved using extensive medical imaging.

Given the medical history of fever and elevated inflammatory parameters, infective pericarditis had to be considered in the differential diagnosis. Based on the current guidelines of the European Society of Cardiology on definitions and diagnostic criteria, our patient satisfied only the criterion of pericardial effusion, which is insufficient for diagnosis.⁵ Notably, auscultation of the patient was significantly impaired by his general state (in the context of the possible presence of pericardial friction rub). Due to the urgency of the procedure and the general state of the patient, a sample of the pericardial effusion was not sent for hematological and microbiological analysis, which we consider a shortcoming.

Once the presence of pericardial effusion is demonstrated, it is necessary to assess its hemodynamical significance. Cardiac tamponade is a primarily clinical diagnosis, with the typical symptoms including Beck's triad – hypotension, jugular venous distension, and muffled heart sounds. It is often also accompanied by tachycardia as well as microvolt and electric alternans in the ECG results. Transthoracic echocardiography is the noninvasive method of choice for confirming the diagnosis, and possible signs include: early diastolic collapse of the right ventricular free wall, late diastolic collapse of the right atrium, "swinging" of the heart in the pericardial cavity, dilation of the inferior vena cava without inspiratory collapse, >40% inspiratory variability in transtricuspid flow, and >25% inspiratory variability in transmitral flow.^{5,6}

isključiti, inicijalni terapijski pristup uključuje perikardiocentezu radi postizanja hemodinamske stabilnosti³. Slučaj ovog bolesnika prikazan je na multidisciplinarnom konziliju te je donesena odluka o perkutanoj koronarnoj intervenciji koja je bila ispravna, što je potvrđeno daljnjim povoljnim tijekom i oporavkom bolesnika te dopunjenom širokom obradom. Dodatna infektološka i imunološka obrada učinjena je zbog dramatične i neobične kliničke slike kojom se bolesnik prezentirao. Postinfarktni perikardijalni izljevi sporo se resorbiraju, a poneki zaostaju i nakon 12 mjeseci.³

Zaključak

Slučaj prikazuje važnost brze dijagnostike, diferencijalnodijagnostičkog promišljanja i pravodobnog liječenja bolesnika s atipičnim manifestacijama infarkta miokarda. U bolesnika koji se prezentiraju kliničkom slikom šoka važno je razmišljati o mogućim mehaničkim komplikacijama infarkta miokarda, a u slučaju njihova isključivanja nužno je provođenje dodatne dijagnostičke obrade radi identifikacije etiologije šoka, što omogućuje njegovo adekvatno liječenje.

In the introduction, we emphasized the most common causes of cardiac tamponade in postinfarction progression. Knowing the etiology is necessary for implementing the optimal treatment approach. If the cause is a mechanical complication of myocardial infarction (free wall rupture), an emergency surgical procedure represents the only chance of patient survival. If mechanical complications are eliminated, the initial treatment approach includes pericardiocentesis with the goal of achieving hemodynamic stability³. This case was presented at a multidisciplinary consultation meeting at the hospital, and the decision to employ percutaneous coronary intervention was correct, as was confirmed by the subsequent favorable clinical course and recovery of the patient, as well as the subsequently performed broader medical tests. Additional infectological and immunological tests were performed due to the dramatic and unusual clinical picture that the patient presented. Postinfarction pericardial effusions are slow to resorb, sometimes remaining for as long as 12 months³.

Conclusion

This case highlights the importance of rapid diagnostics, differential diagnostic analysis, and timely treatment in patients with atypical manifestations of myocardial infarction. In patients who present with a clinical picture of shock, it is important to consider possible mechanical complications of myocardial infarction, and if these have been eliminated it is necessary to perform additional diagnostic tests in order to identify the etiology of the state of shock, thus enabling the application of appropriate treatment.

LITERATURE

1. Nemeth MA, Coulter S, Flamm SD. Pericarditis after myocardial infarction. *Tex Heart Inst J*. 2003;30(3):246-7. **PubMed:** <https://pubmed.ncbi.nlm.nih.gov/12959214/>
2. Hafiz-Ur-Rehman, Khan SB, Hadi A, Nawaz T, Shah ST, Hameedullah, et al. Frequency of pericardial effusion in patients with first myocardial infarction and its effects on in-hospital morbidity and mortality. *J Ayub Med Coll Abbottabad*. 2010 Apr-Jun;22(2):184-6. **PubMed:** <https://pubmed.ncbi.nlm.nih.gov/21702299/>
3. LeWinter MM. Pericardial complications of myocardial infarction [Internet]. Available at: <https://www.uptodate.com/contents/pericardial-complications-of-myocardial-infarction>
4. Jensen JK, Hvitfeld Poulsen S, Mølgaard H. Cardiac tamponade: A clinical challenge [Internet]. Available at: <https://www.escardio.org/Journals/E-Journal-of-Cardiology-Practice/Volume-15/Cardiac-tamponade-a-clinical-challenge>
5. Adler Y, Charron P, Imazio M, Badano L, Barón-Esquivias G, Bogaert J, et al. 2015 ESC Guidelines for the diagnosis and management of pericardial diseases: The Task Force for the Diagnosis and Management of Pericardial Diseases of the European Society of Cardiology (ESC). *Eur Heart J*. 2015 Nov 7;36(42):2921-2964. <https://doi.org/10.1093/eurheartj/ehv318>
6. Correale E, Maggioni AP, Romano S, Ricciardiello V, Battista R, Santoro E. Pericardial involvement in acute myocardial infarction in the post-thrombolytic era: clinical meaning and value. *Clin Cardiol*. 1997 Apr;20(4):327-31. <https://doi.org/10.1002/clc.4960200405>