PRIKAZ SLUČAJA
CASE REPORT

Hrvat. Športskomed. Vjesn. 2024; 39:40-45

SIMULTANEOUS AUTOLOGOUS MINCED CARTILAGE IMPLANTATION AND OPEN WEDGE HIGH TIBIAL OSTEOTOMY IN THE TREATMENT OF KNEE CARTILAGE DEFECT

ISTOVREMENA AUTOLOGNA TRANSPLANTACIJA USITNJENE ZGLOBNE HRSKAVICE I KLINASTA OSTEOTOMIJA PROKSIMALNE TIBIJE U LIJEČENJU DEFEKTA HRSKAVICE KOLJENA

Alan Ivković[1,2,3], Matej Črep[2], Marko Pećina[2,3]
[1]Department of Orthopedics and Traumatology, University Hospital „Sveti Duh“, Zagreb, Croatia
[2] School of Medicine, University of Zagreb, Zagreb, Croatia
[3]Department of Medical Sciences, Croatian Academy of Sciences and Arts, Zagreb, Croatia
Correspondence:Alan Ivković, alan.ivkovic@gmail.com
DOI 10.69589/hsv.39.1.6

SUMMARY

Autologous Minced Cartilage Implantation (AMCI) presents a new approach to treating cartilage damage in the knee. Correcting any underlying lower extremity malalignment is essential for this treatment to succeed. We present a 50-year-old patient with pain in the left knee without a history of trauma. Radiological findings revealed a varus deformation of the knee, and a magnetic resonance imaging (MR) showed a cartilage lesion of the medial femoral condyle measuring 3 cm^2. The patient first underwent open wedge osteotomy of the proximal left tibia, which corrected the varus deformity that caused cartilage damage due to increased mechanical load. Afterward, arthroscopy was performed while the healthy cartilage from the edge of the damage was taken and finely minced. The obtained cartilage mass was mixed with the patient's platelet-rich plasma (PRP). Part of the PRP is additionally processed to produce autologous thrombin. An autologous implant in the form of a paste from minced cartilage and PRP is placed over the defect on the femoral condyle and infused with autologous thrombin to activate the coagulation cascade and fix the transplant in the defect. In a final step, autologous fibrin is then instilled over the implant, which additionally stabilizes it. Radiological findings showed postoperative healing of the proximal tibia, and the MRI revealed the filling of the femoral condyle defect. The patient was without complaints in daily activities, and postoperative subjective and objective findings significantly improved. Autologous minced cartilage implantation in combination

SAŽETAK

Autologna transplantacija usitnjene zglobne hrskavice (engl. AMCI) predstavlja novi pristup liječenju hrskavičnih oštećenja u koljenu. Da bi ovaj postupak uspio, neophodno je ispraviti poremećaje usmjerenja donjih ekstremiteta. Prikazujemo 50-godišnjeg pacijenta s bolovima u lijevom koljenu bez prethodne anamneze traume. Radiološki je utvrđena varusna deformacija koljena, a magnetskom rezonancijom (MR) oštećenje hrskavice medijalnog femoralnog kondila veličine 3 cm^2. Bolesniku je prvo učinjena korektivna osteotomija proksimalnog dijela lijeve tibije, kojom je korigiran varusni deformitet koji je uzrokovao oštećenje hrskavice uslijed povećanog mehaničkog opterećenja. Nakon toga, učinjena je artroskopija pri čemu je uzeta zdrava hrskavica s ruba oštećenja te potom usitnjena. Dobiveni komadići hrskavice pomiješani su s pacijentovom plazmom bogatom trombocitima (PRP). Dio PRP-a dodatno se obrađuje kako bi se proizveo autologni trombin. U oštećenje na femoralnom kondilu postavlja se autologni implantat u obliku paste od mljevene hrskavice i PRP-a, a potom se u njega injektira autologni trombin kako bi se pokrenula koagulacijska kaskada i kako bi se transplantat dodatno stabilizirao Konačno, preko transplantata se injektira i autologni fibrin koji ga dodatno stabilizira. Radiološki je nalaz pokazao postoperativno cijeljenje proksimalne tibije, a magnetskom rezonancom ispunu defekta femoralnog kondila. Bolesnik je bez tegoba u svakodnevnim aktivnostima, a postoperativni subjektivni i objektivni nalaz značajno se poboljšao.

with correction of the direction of the lower extremities has shown promising results in treating cartilage damage.

Autologna transplantacija usitnjene hrskavice u kombinaciji s korekcijom usmjerenja donjih ekstremiteta pokazuje obećavajuće rezultate u liječenju oštećenja hrskavice koljena.

Keywords: Transplantation, Autologous, Cartilage, Genu Varum, Orthopedics, Osteotomy

Ključne riječi: autologna transplantacija, hrskavica, genu varum, ortopedija, osteotomija

INTRODUCTION

Chondral and osteochondral lesions of the knee are being detected with increasing frequency nowadays and pose an increasing challenge in knee surgery (11,14). These defects, often resulting from trauma, degenerative processes, or underlying pathological conditions, can lead to significant symptoms, such as chronic pain and functional impairment. Management strategies for these lesions have varied, including fixation of the surgical fragment, chondroplasty, microfractures, autologous matrix-induced chondrogenesis (AMIC), osteochondral allografts, and autologous chondrocyte implantation (ACI) (5,7,8). Autologous minced cartilage implantation (AMCI) represents a novel, single-step surgical procedure in which autologous cartilage is initially collected from the defect edge, minced into very small cartilage fragments, and then re-implanted for coverage of the defective area. (7,9,12). Fixation of the fragments can include PRP (platelet-rich plasma), fibrin glue, or a combination of those methods. Our aim of this case report is to present the combined surgical approach of autologous minced cartilage implantation and high tibial osteotomy in treating cartilage defects of the knee caused by anatomical knee alignment disorders. By describing the surgical technique, postoperative management, and clinical outcomes, this report seeks to highlight the potential effectiveness and advantages of this treatment in restoring knee function in patients with osteochondral lesions.

CASE PRESENTATION

We present a 50-year-old male patient, a recreational sportsman, previously complaining of pain in the left knee without a positive history of trauma event. Due to knee pain, the patient stopped recreational sports activities of playing tennis and basketball. The physical examination showed no signs of fluid effusion in the knee joint, the knee had a full range of motion and the patient reported pain on palpation in the area of the left medial condyle of the left

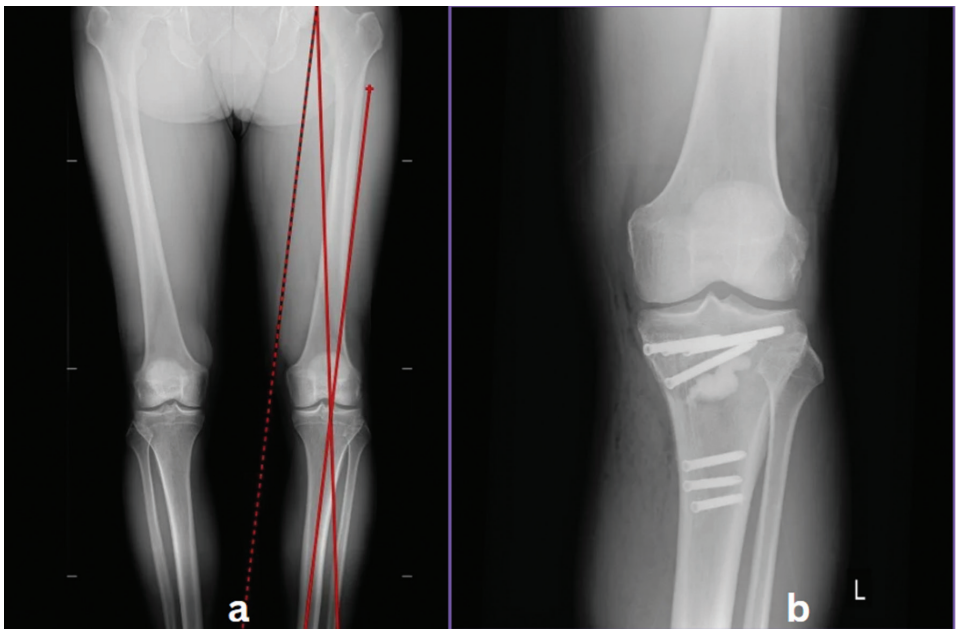

Figure 1. a - Preoperative radiograph reveals varus deformity of the left knee measuring 8.5 degrees, b - 1 year postoperative radiograph reveals healed site of the osteotomy

Slika 1. a - Preoperativna konvencionalna radiografija otkriva varusni deformitet lijevog koljena od 8,5 stupnjeva, b - 1 godinu poslije postoperativna konvencionalna radiografija otkriva zacijeljeno mjesto osteotomije

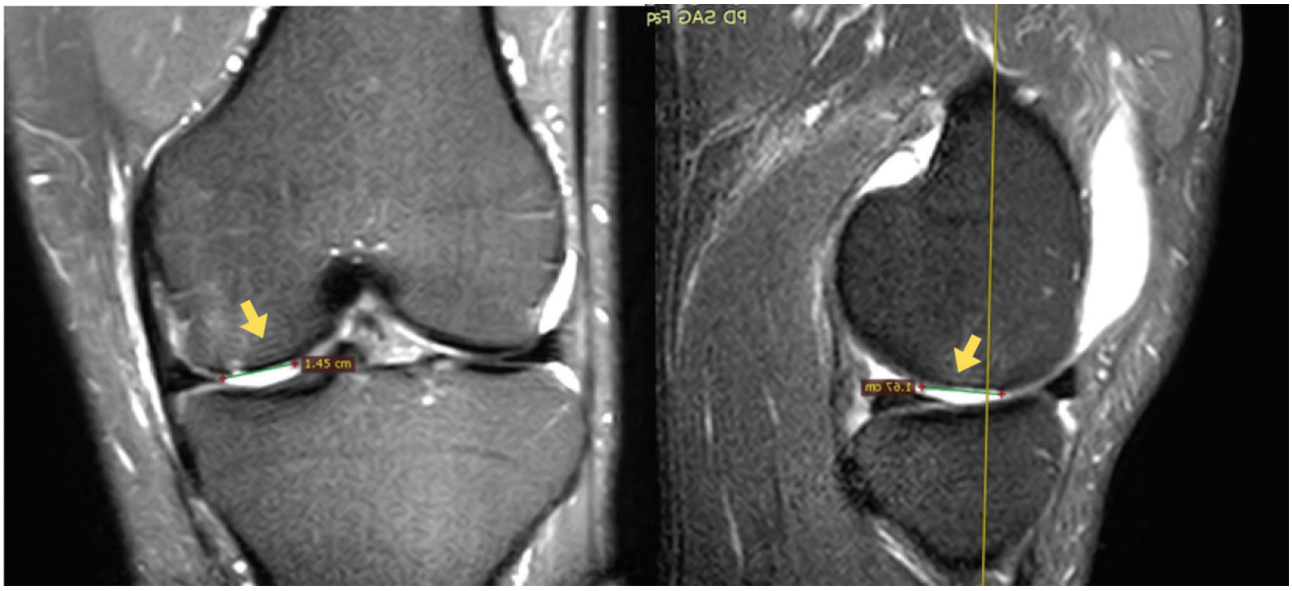

Figure 2. Preoperative magnetic resonance imaging showing full-thickness cartilage defect on the medial femoral condyle
Slika 2. Preoperativna magnetska rezonancija koja pokazuje defekt hrskavice pune debljine na medijalnom femoralnom kondilu

knee. A preoperative X-ray indicated a varus deformity of 8.5 degrees (figure 1a). The magnetic resonance imaging (MRI) confirmed a full-thickness cartilage lesion of the medial femoral condyle measuring 3 cm^2 (figure 2).

After the preoperative assessment, the surgeon indicated a simultaneous high tibial osteotomy and an AMCI procedure. Surgery was performed with spinal anaesthesia. After preparing the operating field, a standard arthroscopic approach was performed and the knee joint was inspected. During the examination, chondromalacia was observed on the medial condyle of the femur measuring 2x1.5 cm, which coincided with the preoperative magnetic resonance findings (figure 3a). The AMCI procedure was performed according to the technique described by Lorenz et al. (10). In brief, PRP is collected at the beginning of the surgery. The edges of the defect were debrided with the use of an arthroscopic shaver (3-mm Sabre; Arthrex GmBH, Munich, Germany) and collected with a specially-designed container (GraftNet; Arthrex, GmBH, Munich, Germany) that was interposed in the standard suction of the shaver for the withdrawal of shaver-minced cartilage tissue. Minced cartilage was mixed with PRP and fixed with thrombin and fibrin (figure 3b) according to the guidelines for the procedure (AutoCart, Arthrex GmBH, Munich, Germany)

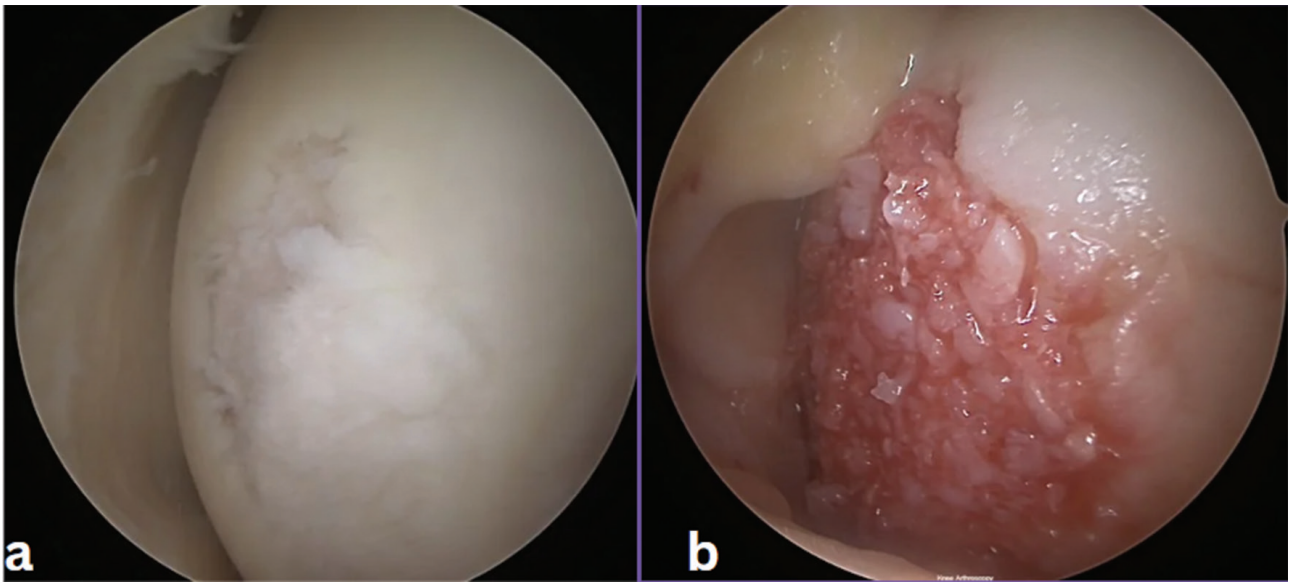

Figure 3. a - Arthroscopic view of the chondral damage on the medial condyle of the left knee b - Minced cartilage chips after fibrin glue fixation within the defect
Slika 3. a - Artroskopski prikaz hondralnog oštećenja na medijalnom kondilu lijevog koljena b - Mljeveni komadići hrskavice nakon fiksacije fibrinskim ljepilom unutar defekta

(6,9). Afterward, according to the preoperative plan, open wedge high tibial osteotomy was performed with 9 degrees of correction to achieve neutral alignment. The osteotomy was fixed with a plate and screws (PEEKPower HTO Plate, Arthrex GmBH, Munich, Germany), and the bone void was filled with bone paste (INNOTERE Paste-CPC, Arthrex GmBH, Munich, Germany).

The postoperative period was uneventful, and the patient was moved to the orthopaedic ward where early active and passive physical rehabilitation of the knee was started under the supervision of a physiotherapist. Postoperative rehabilitation protocol included initial bed rest in a straight knee brace for 24 hours. For the first six weeks, partial weight-bearing was permitted with crutches and range of motion was limited to 0 to 90 degrees. After six weeks, a gradual increase in weight-bearing and range of motion was permitted, with full weight-bearing and unrestricted range of motion achieved at approximately nine weeks postoperatively. On the last examination after the rehabilitation, the patient was without complaints in daily activities. The patients was very pleased with the operative treatment, and postoperative subjective and objective findings of the knee improved significantly (figure 4). A year after the procedure the patient returned to playing court tennis.

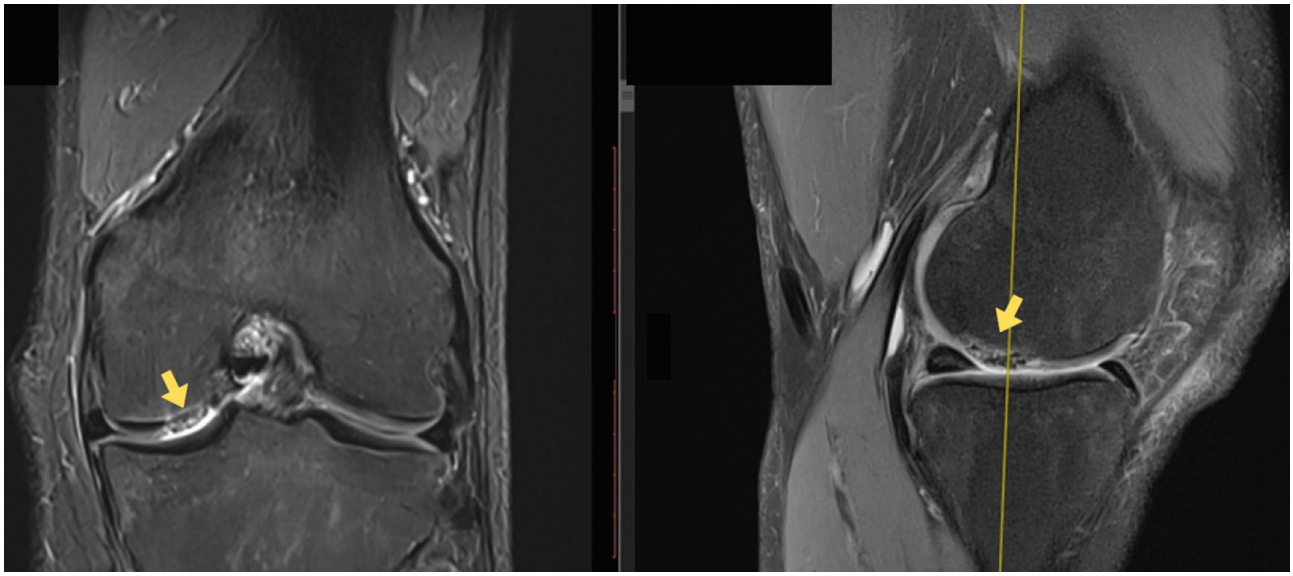

Figure 4. 1 year postoperative magnetic resonance imaging showing complete fill of the cartilage defect (arrows) with good integration, no subchondral bone defect and no subchondral oedema

Slika 4. Postoperativna magnetska rezonancija nakon godine dana pokazuje potpuno ispunjenje defekta hrskavice (strelice) s dobrom integracijom, bez defekta subhondralne kosti i bez subhondralnog edema

DISCUSSION

There are two types of cartilage lesions, focal defects that are well-circumscribed lesions, usually caused by traumatic events, osteochondritis dissecans, or osteonecrosis. On the other side, degenerative defects are more likely to be poorly confined, and they arise as a result of osteoarthritis, meniscal injuries, or malalignments as indicated by our patient. Trauma is the most common cause of osteochondral lesions, usually caused by a sports injury. A stress fracture through the cartilage matrix is produced, which leads to a free osteochondral fragment if the subchondral bone is affected. This etiology is responsible for approximately 40 – 50% of osteochondral lesions and affects young athletes aged between 20 and 40 (4). Osteochondritis dissecans is a disease caused by repetitive microtrauma at a younger age. It manifests itself as pain and swelling in the affected joint, restricted movement, and a 'locking' sensation of the joint. The clinical exam indicative of osteochondritis dissecans is called Wilson's test. Osteonecrosis can be primary, avascular, or secondary due to several factors, including alcohol abuse, steroid therapy, previous knee surgery, etc. Osteoarthritis is the most common cause of chondral lesions after the age of 40. These lesions are different in size, shape, and depth. Sclerosing of the subchondral bone results in less shock absorption and thus cartilage matrix breakage. Eventually, the lesion enlarges due to weight bearing and the subchondral bone erodes over time. Radiological assessment of articular cartilage injuries accompanies physical examination of the joint. Routine panoramic radiographs and AP and LL projections can reveal numerous findings, such as joint space narrowing, subchondral sclerosis, or cysts indicative of osteoarthritis. Osteochondritis dissecans of higher grades can reveal loose cartilage body in joint space. Nevertheless, MRI accompanied by arthroscopy remains the standard procedure for diagnosing articular cartilage lesions to reveal "lesion personality" which includes age of the patient, anatomical localization, size of the lesion, and the subchondral bone

characteristics. (6,7). Classification systems for chondral lesions include Outerbridge Classification and ICRS (International Cartilage Repair Society) classification. There are several known methods of treating such lesions, including conservative or operative treatment. The conservative approach has for goal of reducing symptoms and is considered in mild symptomatic patients. It consists of prescribing analgesics, physical therapy, intraarticular hyaluronic acid, growth factors, or PRP injections. Operative treatment includes different strategies; arthroscopic lavage and debridement, subchondral drilling, microfractures, osteochondral allografting or autografting, scaffolds, and autologous chondrocyte implantation (ACI) (6). The harvesting of autologous cartilage and transplanting focal defects in the knee dates back to Albrecht in the 1980s who first described the closing of small 4 mm2 osteochondral lesions with cartilage fragments and fibrin glue in rabbits (1). This method has advanced throughout the years with advancing arthroscopic harvest and mincing techniques. AMCI represents the fourth-generation ACI in which cartilage fragments are the source of migrating chondrocytes. The main role of this technique is to get the cells out of their domain to repopulate new areas bridging defective cartilage areas with new matrix (2,3). Cartilage fragmentation induces a reparation process by activation of chondrocytes in migration, proliferation, and differentiation (12). Chondral fragments must be as small as possible (<1 mm3) to form a paste-like mass for the greatest proliferation potential and biological activity (12). Chondrocytes migrate to the site of the lesion and repair the injury by synthesizing a new extracellular matrix (2,3,15). The technique is complemented by fibrin glue, PRP or bone marrow aspirate concentrate (BMAC) for additional stabilization and healing (6). Postoperatively, patients treated with the described technique show significant improvement in pain and knee function, radiological findings, and overall health (11). It is considered a safe surgical procedure that does not require manipulation of the specimen in the laboratory or the use of allografts which makes it economically attractive (6,9,14).

CONCLUSION

In conclusion, this case report highlighted the successful management of a cartilage defect in the knee using a combined approach of autologous minced cartilage implantation and high tibial osteotomy. Our patient experienced substantial improvements in pain, knee function, and quality of life following the procedure. This approach demonstrates the potential for AMCI to be a feasible and cost-effective treatment option for patients with similar osteochondral lesions, offering a single-stage procedure that promotes natural cartilage repair and avoids complications associated with more invasive techniques.

References

1. Albrecht FH. Closure of joint cartilage defects using cartilage fragments and fibrin glue. Fortschr Med. 1983;101(37):1650–2.
2. Brittberg M. Treatment of knee cartilage lesions in 2024: From hyaluronic acid to regenerative medicine. J Exp Orthop. 2024;11(2):e12016.
3. Brittberg M, Lindahl A, Nilsson A, Ohlsson C, Isaksson O, Peterson L. Treatment of deep cartilage defects in the knee with autologous chondrocyte transplantation. N Engl J Med. 1994;331(14):889–95.
4. Falah M, Nierenberg G, Soudry M, Hayden M, Volpin G. Treatment of articular cartilage lesions of the knee. Int Orthop. 2010;34(5):621–30.
5. Howell M, Liao Q, Gee CW. Surgical management of osteochondral defects of the knee: An educational review. Curr Rev Musculoskelet Med. 2021;14(1):60–6.
6. Ivković A. Mogućnosti liječenja oštećenja zglobne hrskavice u sportaša.U: Pećina M. i sur. Sportska medicina. 2. dopunjeno izdanje. Zagreb: Medicinska naklada, 2024.
7. Ivković A. Regeneracijska ortopedija i tkivni inženjering. In.Pećina M;Franić M i sur. Kompendij ortopedije, Zagreb:ZVU, 2021; 179-86.
8. Ivkovic A, Marijanovic I, Hudetz D, Porter RM, Pecina M, Evans CH. Regenerative medicine and tissue engineering in orthopedic surgery. Front Biosci Elite Ed. 2011; 3(3):923–44.
9. Ivković A, Vuletić F. Regenerativna medicina u liječenju sportskih ozljeda. U. Pećina M. i sur. Sportska medicina, drugo dopunjeno izdanje, Zagreb : Medicinska naklada, 2024.
10. Lorenz CJ, Freislederer F, Salzmann GM, Scheibel M. Minced cartilage procedure for one-stage arthroscopic repair of chondral defects at the glenohumeral joint. Arthrosc Tech. 2021;10(7):e1677–84.
11. Massen FK, Inauen CR, Harder LP, Runer A, Preiss S, Salzmann GM. One-step autologous minced cartilage procedure for the treatment of knee joint chondral and osteochondral lesions: A series of 27 patients with 2-year follow-up. Orthop J Sports Med. 2019; 7(6):2325967119853773.
12. Ossendorff R, Grede L, Scheidt S, Strauss AC, Burger C, Wirtz DC, et al. Comparison of minced cartilage implantation with autologous chondrocyte transplantation in an in vitro inflammation model. Cells. 2024;13(6):546.
13. Ossendorff R, Walter SG, Schildberg FA, Spang J, Obudzinski S, Preiss S, et al. Biologic principles of minced cartilage implantation: a narrative review. Arch Orthop Trauma Surg. 2023 ;143(6):3259–69.
14. Salzmann GM, Ossendorff R, Gilat R, Cole BJ. Autologous Minced Cartilage Implantation for treatment of chondral and osteochondral lesions in the knee joint: An overview. Cartilage 2021; 13(1suppl):1124S-36S.
15. Urlić I, Ivković A. Cell sources for cartilage repair-biological and clinical perspective. Cells. 2021;10(9):2496.