

UDK 902  
ISSN 1330-0644  
Vol. 41/2  
ZAGREB, 2024.

# PRILOZI

Instituta za arheologiju u Zagrebu

Pril. Inst. arheol. Zagrebu  
Str./Pages 1–204, Zagreb, 2024.

**PRILOZI INSTITUTA ZA ARHEOLOGIJU  
U ZAGREBU, 41/2/2024  
STR./PAGES 1–204, ZAGREB, 2024.**

Izdavač / Publisher  
INSTITUT ZA ARHEOLOGIJU  
INSTITUTE OF ARCHAEOLOGY

Adresa uredništva /  
Address of the editor's office  
Institut za arheologiju / Institute of archaeology  
HR-10000 Zagreb, Jurjevska ulica 15  
Hrvatska / Croatia  
Telefon / Phone ++385 / (0)1 61 50 250  
Fax ++385(0)1 60 55 806  
e-mail: urednistvo.priloz@iarh.hr  
<http://www.iarh.hr>

Glavni i odgovorni urednik / Editor in chief  
Marko DIZDAR

Tehnički urednici / Technical editors  
Marko DIZDAR  
Katarina BOTIĆ

Uredništvo / Editorial board  
Prapovijest / Prehistory:  
Marko DIZDAR, Institut za arheologiju, Zagreb,  
Hrvatska  
Snježana VRDOLJAK, Institut za arheologiju, Zagreb,  
Hrvatska  
Viktória KISS, Hungarian Academy of Sciences,  
Institute of Archaeology, Budapest, Hungary  
Antika / Antiquities:  
Goranka LIPOVAC VRKLJAN, Institut za arheologiju,  
Zagreb, Hrvatska  
Ivan RADMAN-LIVAJA, Arheološki muzej u Zagrebu,  
Zagreb, Hrvatska  
Srednji vijek i novi vijek / Middle Ages and Modern era:  
Tajana SEKELJ IVANČAN, Institut za arheologiju,  
Zagreb, Hrvatska  
Katarina Katja PREDOVNIK, University of Ljubljana,  
Faculty of Arts, Ljubljana, Slovenia  
Natascha MEHLER, Eberhard Karls University of  
Tübingen, Tübingen, Germany  
Tatjana TKALČEC, Institut za arheologiju, Zagreb,  
Hrvatska  
Juraj BELAJ, Institut za arheologiju, Zagreb, Hrvatska  
Metodologija / Methodology  
Predrag NOVAKOVIĆ, University of Ljubljana, Faculty  
of Arts, Ljubljana, Slovenia

Izdavački savjet / Editorial advisory board  
Dunja GLOGOVIĆ, Zagreb, Hrvatska  
Ivor KARAVANIĆ, Sveučilište u Zagrebu, Filozofski  
fakultet, Odsjek za arheologiju, Zagreb, Hrvatska  
Kornelija MINICHREITER, Zagreb, Hrvatska  
Alexander T. RUTTKAY, Nitra, Slovakia  
Ivančica SCHRUNK, University of St. Thomas, St. Paul,  
Minnesota, USA  
Željko TOMIČIĆ, Hrvatska Akademija znanosti i  
umjetnosti, Zagreb, Hrvatska  
Ante UGLEŠIĆ, Sveučilište u Zadru, Odjel za  
arheologiju, Zadar, Hrvatska

Prijevod na engleski / English translation  
Zdravka HINCAK DARIS, Tea KOKOTOVIĆ,  
Ana KONESTRA, Martina KORIĆ, Marko MARAS,  
Porin ŠČUKANEC REZNIČEK, Nikola VUKOSAVLJEVIĆ

Lektura / Language editor  
Marko DIZDAR (hrvatski jezik / Croatian)  
Marko MARAS, Katarina BOTIĆ (engleski jezik / English)

Korektura / Proofreads  
Katarina BOTIĆ

Grafičko oblikovanje / Graphic design  
Umjetnička organizacija OAZA

Računalni slog / Layout  
Hrvoje JAMBREK

Tisak / Printed by  
Tiskara Zelina d.d., Sv. I. Zelina

Naklada / Issued  
400 primjeraka / 400 copies

Prilozi Instituta za arheologiju u Zagrebu indeksirani su u /  
Prilozi Instituta za arheologiju u Zagrebu are indexed by:  
DYABOLA – Sachkatalog der Bibliothek – Römisch-  
Germanische Kommission des Deutschen  
Archaeologischen Instituts, Frankfurt a. Main  
Clarivate Analytics services – Web of Science Core  
Collection  
CNRS / INIST – Centre National de la Recherche  
Scientifique que / L'Institut de l'Information Scientifique et  
Technique, Vandoeuvre-lès-Nancy  
EBSCO – Information services, Ipswich  
ERIH PLUS – European Reference Index for the  
Humanities and Social Sciences, Norwegian  
Directorate for Higher Education and Skills, Bergen  
SciVerse Scopus – Elsevier, Amsterdam

E-izdanja. Publikacija je dostupna u digitalnom obliku i  
otvorenom pristupu na  
<https://hrcak.srce.hr/prilozi-iaz>  
E-edition. The publication is available in digital and  
open access form at  
<https://hrcak.srce.hr/prilozi-iaz?lang=en>

DOI 10.33254

Ovaj rad licenciran je pod Creative Commons  
Attribution By 4.0 međunarodnom licencom /  
This work is licenced under a Creative Commons  
attribution By 4.0 international licence  
<https://creativecommons.org/licenses/by/4.0/>



# SADRŽAJ

## CONTENTS

### Izvorni znanstveni radovi

5

VIRGINIA BARCIELA GONZÁLEZ  
AITOR RUIZ-REDONDO  
ANTE VUJNOVIĆ  
NIKOLA VUKOSAVLJEVIĆ

**Prehistoric Schematic Rock Art in the Eastern Adriatic: the discovery of Rock Art at the Badanj II rock shelter (Bosnia and Herzegovina) viewed from the Western Mediterranean**

27

DARIA LOŽNJAK DIZDAR  
SNJEŽANA VRDOLJAK  
IVAN DRNIĆ

**Tragovi igre djece tijekom kasnoga brončanog doba na jugu Karpatske kotline**

59

MARTINA KORIĆ  
**Grčki keramički utezi za tkalački stan iz Fara na otoku Hvaru**

87

NIVES DONEUS  
MICHAEL DONEUS  
TIM KINNAIRD  
SAM TURNER  
MARTIN FERA  
DORIS JETZINGER  
GEERT J. VERHOEVEN

**Lost and found: Roman surveying of municipal territories on the northern Adriatic islands, Croatia**

### Original scientific papers

VIRGINIA BARCIELA GONZÁLEZ  
AITOR RUIZ-REDONDO  
ANTE VUJNOVIĆ  
NIKOLA VUKOSAVLJEVIĆ

Prapovijesna shematska stijenska umjetnost istočnog Jadrana: otkriće stijenske umjetnosti u pripećku Badanj II (Bosna i Hercegovina) iz perspektive zapadnog Mediterana

DARIA LOŽNJAK DIZDAR  
SNJEŽANA VRDOLJAK  
IVAN DRNIĆ

Traces of children's play during the Late Bronze Age in the southern Carpathian Basin

MARTINA KORIĆ

Greek ceramic loom weights from Pharos on the island of Hvar

NIVES DONEUS  
MICHAEL DONEUS  
TIM KINNAIRD  
SAM TURNER  
MARTIN FERA  
DORIS JETZINGER  
GEERT J. VERHOEVEN

Izgubljeno-nađeno: rimsko mjerenje municipalnih zemljišta na sjevernim otocima hrvatskog Jadrana

<b>119</b>	<b>ANA KONESTRA</b> <b>(Peri)urbano vrtlarstvo</b> <b>u Saloni? O nalazu <i>ollae</i></b> <b><i>perforatae</i> u salonitanskome</b> <b><i>urbs orientalis</i> u kontekstu</b> <b>vrtlarstva na istočnome</b> <b>Jadranu u rimskome razdoblju</b>	<b>ANA KONESTRA</b> <b>(Peri)urban gardening in</b> <b>Salona? On the discovery of</b> <b><i>ollae perforatae</i> in Salonitan</b> <b><i>urbs orientalis</i> in the context</b> <b>of gardening on the eastern</b> <b>Adriatic in the Roman period</b>
<b>145</b>	<b>TEA KOKOTOVIĆ</b> <b>Razvojni poremećaj kuka: primjer</b> <b>iz kasnosrednjovjekovne Novske</b>	<b>TEA KOKOTOVIĆ</b> <b>Developmental dysplasia of</b> <b>the hip: an example from late</b> <b>medieval Novska</b>
<b>175</b>	<b>IRENA ĆIRIĆ</b> <b>ANA MIKULKA</b> <b>ZDRAVKA HINČAK DARIS</b> <b>Forenzična rekonstrukcija</b> <b>lica pomoću 3D računalne</b> <b>tehnologije</b>	<b>IRENA ĆIRIĆ</b> <b>ANA MIKULKA</b> <b>ZDRAVKA HINČAK DARIS</b> <b>Forensic facial reconstruction</b> <b>using 3D computerized</b> <b>technology</b>
<b>197</b>	<b>Upute autorima</b>	<b>Guidelines for contributors</b>

# FORENZIČNA REKONSTRUKCIJA LICA POMOĆU 3D RAČUNALNE TEHNOLOGIJE FORENSIC FACIAL RECONSTRUCTION USING 3-D COMPUTER TECHNOLOGY

Izvorni znanstveni rad / forenzična antropologija

Original scientific paper / Forensic anthropology

UDK UDC 340.6:572:004.4

Primljeno / Received: 06. 05. 2024. Prihvaćeno / Accepted: 30. 09. 2024.

[doi.org/10.33254/piaz.41.2.7](https://doi.org/10.33254/piaz.41.2.7)

## IRENA ĆIRIĆ

Sveučilište u Zagrebu

Ured za forenzične znanosti

Ulica Radoslava Cimermana 88

HR-10000 Zagreb

[irenaciric5@gmail.com](mailto:irenaciric5@gmail.com)

## ANA MIKULKA

Ministarstvo hrvatskih branitelja

Uprava za zatočene i nestale

Trg Nevenke Topalušić 1

HR-10000 Zagreb

[ana.mikulka@branitelj.hr](mailto:ana.mikulka@branitelj.hr)

Sveučilište u Zagrebu

Ured za forenzične znanosti

Ulica Radoslava Cimermana 88

HR-10000 Zagreb

## ZDRAVKA HINCAK DARIS

Sveučilište u Zagrebu

Filozofski fakultet

Odsjek za arheologiju

Ivana Lučića 3

HR-10000 Zagreb

[zhincak@ffzg.hr](mailto:zhincak@ffzg.hr)

Sveučilište u Zagrebu

Ured za forenzične znanosti

Ulica Radoslava Cimermana 88

HR-10000 Zagreb

U radu je prikazan proces forenzične rekonstrukcije mekih tkiva lica kako bi se ispitala uspješnost primjene 3D računalnih metoda na lubanji osobe ekshumiranoj iz masovne grobnice iz Drugog svjetskog rata i poslijeratnog razdoblja. Lubanja neidentificirane osobe pripada jednoj od ukupno 294 ekshumirane žrtve sa sedam lokacija istraženih 2018. godine na području Gračana u Zagrebu. Nakon antropološke analize, koja obuhvaća kraniofacijalnu antropometriju i 3D skeniranje lubanje, proces rekonstrukcije lica izveden je u standardnim programima za 3D oblikovanje: Blender, MakeHuman i OrtogOnBlender. Postupak osjenčavanja 3D modela pri računalnoj obradi omogućio je pretvaranje digitalne rekonstrukcije lubanje u trodimenzionalni prikaz lica, što predstavlja završnu fazu procesa. Rekonstrukcijom je prikazano kako se i iz izazovnog koštanog materijala može pružiti mnoštvo podataka korisnih u procesu identifikacije osoba. Daljnji razvoj forenzične rekonstrukcije lica ovisi o stvaranju opsežnih baza podataka i daljnjem istraživanju novih metoda.

**KLJUČNE RIJEČI:** 3D facijalna rekonstrukcija, masovne grobnice, 3D skeniranje, identifikacija, forenzična antropologija, Drugi svjetski rat i poslijeratno razdoblje, Gračani, Hrvatska

The paper presents the process of forensic facial soft tissue reconstruction to investigate the efficiency of applying craniofacial anthropometry and 3D computer methods on a skull exhumed from the context of a commingled mass grave from World War II and the post-war period. The skull of an unidentified person belongs to one of a total of 294 exhumed victims from seven locations investigated during 2018 in the area of Gračani at City of Zagreb. After anthropological analysis and 3D scanning of the skull, the facial reconstruction process was performed using 3D modelling software Blender, MakeHuman, and OrtogOnBlender. The 3D model was rendered to obtain a 3D visualization of the reconstructed facial features of the skull, representing the final step in creating an approximation of the person's appearance before death. The reconstruction showed that even from such a challenging context, a multitude of data can be obtained that can be used in the identification process of skeletal remains of unidentified persons. Further development of forensic facial reconstruction depends on creating extensive databases and continuous research into new methods.

**KEY WORDS:** facial reconstruction, mass graves, 3D scanning, 3D reconstruction, identification, forensic anthropology, World War II and the post-war period, Gračani Croatia



Copyright © Autor(i)  
The Author(s) 2024

Open Access This work is distributed under the terms and conditions of the Creative Commons Attribution 4.0 International license (<https://creativecommons.org/licenses/by/4.0/>) which permits unrestricted re-use, distribution, and reproduction in any medium, provided the original work is properly cited.

Open Access Ovaj rad dijeli se prema odredbama i uvjetima licence Creative Commons Attribution 4.0 International license (<https://creativecommons.org/licenses/by/4.0/>), koja dopušta neograničenu ponovnu upotrebu, dijeljenje i reprodukciju u bilo kojem mediju, pod uvjetom da je izvorno djelo ispravno citirano.

## UVOD

Lice, kao osobitost svakog pojedinog čovjeka, ima ključnu ulogu u forenzičnim istraživanjima. Mogućnost rekonstrukcije lica iz koštanih ostataka od iznimne je važnosti u slučajevima kada je potrebno izvesti identifikaciju žrtava zločina ili nestalih osoba. Rekonstruirano lice može poslužiti i kao važan alat u komunikaciji s javnošću tijekom istrage, pomažući u prikupljanju informacija svjedoka. Forenzična ili sudska antropologija izrasla je iz osnova biološke antropologije. Forenzični antropolozi prolaze stručna usavršavanja i pomažu specijalistima sudske medicine identificirati ljudske koštane ostatke, a dio su tima stručnjaka uključenih u istrage masovnih katastrofa, zona sukoba i terorističkih napada (Haviland 2004; Jurmain 2017). Ukoliko je nemoguće utvrditi identitet pojedinca klasičnim sudsko-medicinskim metodama, forenzična rekonstrukcija lica prema ostatcima kosti lubanje može biti odlučujuća (AAFS 2020).

U području forenzike, rekonstrukcija koja pruža približan izgled lica osobe i njegovo prepoznavanje imaju iznimno važnu ulogu. No u forenzičnim istraživanjima svi rezultati i odgovori moraju biti provjereni i točni, sve metode i tehnike prihvaćene i vrednovane jer samo tako vode do rješavanja kaznenih događaja te kao pomoć pravosudnim tijelima u pronalasku počinitelja kaznenih djela (Banić et al. 2017). Kada se traga za osumnjičenom osobom, često se koriste programi za prepoznavanje lica kako bi se ubrzao proces identifikacije. Uspoređujući ključne točke na licu, ti programi pokušavaju pronaći podudaranja s postojećim bazama podataka osumnjičenih (Bowen 2022). Tehnika rekonstrukcije predstavlja složeniji proces u kojem se primjenjuju umjetničke vještine uz znanstvena pravila kako bi se stvorila meka tkiva na lubanjskoj osnovi i konačno približan izgled lica koje može pomoći u procesu identifikacije pojedinca (Wilkinson 2004).

Rekonstrukcija mekih tkiva lica razvija se iz nekoliko različitih područja. Ipak, glavni poticaji za daljnja znanstvena istraživanja proizlaze iz potrebe za identificiranjem žrtava. U drugim područjima, poput medicine, u kraniofacijalnoj ortopediji upotrebljava se i razvija zbog točnije predoperativne faze samog postupka i planiranja. No, rezultati za svako spomenuto područje moraju pokazati visoku točnost (Clement, Marks 2005). Tehnika se može upotrijebiti u kulturnim i obrazovnim ustanovama, primjerice

## INTRODUCTION

As a characteristic of every individual, the face plays a key role in forensic research. The possibility of facial reconstruction from bone remains is extremely important in cases where it is necessary to perform the identification of crime victims or missing persons. The reconstructed face can also be an essential tool in communication with the public during the investigation, helping gather witness information. Forensic or judicial anthropology grew out of the foundations of biological anthropology. Forensic anthropologists undergo professional training and help forensic medicine specialists identify human skeletal remains and are part of a team of experts involved in the investigation of mass disasters, conflict zones and terrorist attacks (Haviland 2004; Jurmain 2017). If it is impossible to determine an individual's identity using classic forensic methods, a forensic facial reconstruction based on the remains of the skull bone can be decisive (AAFS 2020).

In forensics, a reconstruction that provides an approximate appearance of a person's face and its recognition plays a vital role. However, in forensic research, all results and answers must be checked and precise, and all methods and techniques must be accepted and evaluated. This is the only way to solve criminal events and help judicial authorities find perpetrators of criminal offences (Banić et al. 2017). Facial recognition programs are often used to speed up the identification process when searching for a suspect. By comparing key points on the face, these programs try to find matches with existing databases of suspects (Bowen 2022). The reconstruction technique is a more complex process in which artistic skills are applied along with scientific rules to create the soft tissues at the cranial base and, ultimately, an approximate appearance of the face that can aid in the process of identifying an individual (Wilkinson 2004).

Face soft tissue reconstruction is developed from several different areas. Nevertheless, the main incentives for further scientific research stem from the need to identify the victims. In other fields, such as medicine, and craniofacial orthopaedics, it is used and developed due to the more accurate pre-operative phase of the procedure and planning. However, each area's results must be highly accurate (Clement, Marks 2005). The technique can be used in cultural and educational institutions like museums (Moraes et al. 2014). In archaeology, it can be used to create approximate



muzejima (Moraes et al. 2014). U arheologiji se može koristiti za stvaranje približnih crta lica mumificiranih i balzamiranih tijela te stvaranje lica iz prošlosti prema očuvanim kostima lubanje (Gupta et al. 2015).

Prvu facijalnu rekonstrukciju izveo je njemački anatom Wilhelm His daleke 1895. godine, rekonstruiravši lice Johana Sebastiana Bacha (Lee et al. 2012).

Forenzična rekonstrukcija lica jedna je od tehnika identifikacije koja stvara približan izgled lica osobe koji će poslužiti kod prepoznavanja osobe, ali i pružanja dodatnih podataka potrebnih za razvoj metoda identifikacije (Vanezis, Vanezis 2000; Verzé 2009; Guleria et al. 2023).

Identifikacija je važna jer svi posmrtni ostatci trebaju biti identificirani, bez obzira je li riječ o potpuno ili djelomice očuvanim tijelima ili koštanim ostacima osoba. Nekoliko je standardnih metoda za pozitivnu identifikaciju, poput usporedbe DNA, usporedbe otisaka prstiju, odontološke usporedbe, dok su ostale metode manje sigurne i zasnovane su na skupini sekundarnih identifikacijskih značajki (Interpol 2023). Istraživač identiteta uobičajeno započinje temeljitim pregledom tijela i prikupljanjem dostupnih podataka. Forenzična antropologija igra ključnu ulogu u ovom procesu, omogućavajući procjenu biološkog profila pojedinca, poput procjene dobi, spola, visine i populacijske pripadnosti. Kako bi se dobio vizualni prikaz često se provodi i rekonstrukcija lica, koja uključuje stvaranje trodimenzionalnog modela lica na temelju anatomskih karakteristika lubanje (Subsol, Quatrehomme 2005). Dvije su osnovne tehnike facijalne rekonstrukcije: dvodimenzionalna (2D) i trodimenzionalna (3D). Obje mogu biti manualne ili računalne u kojima se koristi određena programska podrška za stvaranje mekih tkiva lica. Danas se većinom koriste 3D tehnike od kojih se u manualnoj metodi izdvojilo nekoliko pristupa: anatomski, antropometrijski i Metoda Manchester, koja uklapa oba pristupa. Anatomsku manualnu metodu nazvanu ruskom metodom razvio je Mihail Mihajlovič Gerasimov, a najopsežniji prikaz metode objavio je u svom najpoznatijem djelu „Vosstanovlenie lica po cerepu“ iz 1955. godine (Герасимов 1955). Metoda uključuje sveobuhvatnu konstrukciju mišića lica uz upotrebu vrijednosti debljine mekog tkiva i kože. Dovoljno je spomenuti kako je i danas Gerasimova metoda predviđanja projekcije nosa točnija od mnogih drugih suvremenih metoda koje se koriste u medicini.

facial features of mummified and embalmed bodies and to create faces from the past based on preserved skull bones (Gupta et al. 2015). The first facial reconstruction was performed by the German anatomist Wilhelm His way back in 1895, reconstructing the face of Johan Sebastian Bach (Lee et al. 2012).

Forensic facial reconstruction is one of the identification techniques that creates an approximate appearance of a person's face that will be used to identify a person but also to provide additional data necessary for the development of identification methods (Vanezis, Vanezis 2000; Verzé 2009; Guleria et al. 2023).

Identification is important because all remains should be identified, regardless of whether they are entirely or partially preserved bodies or skeletal remains of persons. There are several standard methods for positive identification, such as DNA comparison, fingerprint comparison, and dental comparison. In contrast, other methods are less secure and are based on a group of secondary identification features (Interpol 2023). The identity investigation usually begins with a thorough examination of the body and the collection of available data. Forensic anthropology plays a key role in this process, enabling the assessment of an individual's biological profile, including estimation of age at death, sex, stature, and demographics. In order to obtain a visual representation, facial reconstruction is often performed, which includes creating a three-dimensional model of the face based on the anatomical characteristics of the cranium (Subsol, Quatrehomme 2005). Two basic facial reconstruction techniques exist: two-dimensional (2D) and three-dimensional (3D). Both can be manual or computer-based, and specific software is used to create the soft tissues of the face.

Today, 3D techniques are mainly used, and several approaches have been distinguished in the manual method: the anatomical, anthropometric, and the Manchester Method, which combines both approaches. Mihail Mihajlovič Gerasimov developed the anatomical manual method called the Russian method, and he published the most extensive description of the method in his most famous article, „Vosstanovlenie lica po cerepu“ from 1955 (Gerasimov 1955). The method comprehensively constructs facial muscles using soft tissue and skin thickness values. Suffice it to mention that even today, Gerasim's method of predicting the projection of the nose is more accurate than many other modern methods used in medicine.

Antropometrijsku ili američku manualnu metodu razvila je američka antropološka škola pod vodstvom Wiltona Mariona Krogmana četrdesetih godina prošlog stoljeća. Metoda se zasniva na debljini mekog tkiva koja se s velikom točnošću dobivala uz upotrebu igala, rendgenskih i ultrazvučnih snimanja (Kreutz, Verhoff 2007). Iako uspješna, ova metoda danas se rijetko koristi jer zahtijeva vrhunski obučene stručnjake za uzimanje mjera i snimanja na pravilan, anatomski način.

Britanska ili Manchester metoda najmlađa je od navedenih i objedinjuje obje tehnike, anatomsku i antropometrijsku, razvijajući se krajem sedamdesetih godina pod vodstvom Richarda Neavea (Quatrehomme et al. 1997; Lee et al. 2012; Short et al. 2014). Najzastupljenija od navedenih je 3D manualna metoda koja uvodi u rekonstrukciju malene klinove koji predstavljaju srednju dubinu tkiva na određenoj anatomske točki. O zahtjevnosti takvog posla dovoljno govori podatak kako je dubina tkiva lica određena spolom, starosnom dobi, građom pojedinca te djelomice populacijskom pripadnošću (Kreutz et al. 2007).

U klasičnoj, manualnoj metodi u procesu rekonstrukcije lica pričvršćuje se materijal za modeliranje na odljev lubanje, kao zamjena za meka tkiva i kožu do stvaranja približnog izgleda osobe. Identifikacija pojedinca prema sličnosti rekonstruiranog lica ovisi o dostupnosti podataka. Metode se kreću od jednostavne usporedbe s postojećim fotografijama ili videom, preko superpozicije digitalne slike lica na 3D model lubanje, do složenijih postupaka restauracije ili rekonstrukcije lica. Restauracija lica provodi se kada su očuvani dijelovi mekih tkiva, dok se rekonstrukcija lica temelji na anatomskim znanjima i 3D oblikovanju kada ne postoje ostatci mekih tkiva (Sauer et al. 2012).

Lubanja predstavlja jednu od najsloženijih struktura ljudskog kostura, a sastoji se od četrnaest kosti lica (*splanchnocranium*) i osam kosti neurokranija (*neurocranium*) (Krpmotić-Nemanić, Marušić 2007). Kosti lubanje štite mozak i središnji živčani sustav te oblikuju otvorene zavijene površine s čvrstim stijenkama za prolaz zraka u procesu disanja, za usitnjavanje i uzimanje hrane. Također, na oblik lubanje utječe razvijenost mišića.

Antropometrijska mjerenja i opisne karakteristike, primjerice tip nosa, obrva, boje očiju temelj su Bertillonovog sustava koji je

The American School of Anthropology developed the anthropometric or American manual method under Wilton Marion Krogman's leadership in the last century's forties. The method is based on the thickness of the soft tissue, which was obtained with great accuracy using needles, X-ray and ultrasound imaging (Kreutz, Verhoff 2007). Although successful, this method is rarely used today because it requires highly trained specialists to take measurements and record them in a correct, anatomical way.

The British or Manchester method, the most recent of the three combines anatomical and anthropometric techniques developed at the end of the seventies under the leadership of Richard Neave (Quatrehomme et al. 1997; Lee et al. 2012; Short et al. 2014). The most common of the above is the 3D manual method, which introduces small wedges into the reconstruction, representing the mean tissue depth at a certain anatomical point. The fact that the depth of the facial tissue is determined by the sex, age, and build of the individual and partly by the population membership speaks volumes about the demanding nature of such work (Kreutz et al. 2007).

In the classic manual method of face reconstruction, the modelling material is attached to the skull cast as a substitute for soft tissues and skin until the approximate appearance of the person is created. The identification of an individual based on the reconstructed face's similarity depends on the availability of data. The methods range from a simple comparison with existing photographs or video through the superposition of a digital face image on a 3D model of the skull to more complex facial restoration or reconstruction procedures. It is important to note that facial restoration is performed when parts of soft tissues are preserved, while the facial reconstruction is based on anatomical knowledge and 3D modelling when no soft tissue remains (Sauer et al. 2012).

The skull represents one of the most complex structures of the human skeleton, and consists of fourteen facial bones (*splanchnocranium*) and eight *neurocranium* bones (Krpmotić-Nemanić, Marušić 2007). The bones of the skull protect the brain and the central nervous system and form open curved surfaces with solid walls for the passage of air in the process of breathing, for crushing and taking in food. Also, the shape of the skull is affected by muscle development.

Anthropometric measurements and descriptive characteristics, such as the type of nose, eyebrows, eye colour, are the basis of Bertillon's



proizašao iz forenzične antropometrije. Kra- niometrija, kao grana antropometrije, opi- suje se kao proces mjerenja opsega i oblika lubanje zbog određivanja fizičkih značajki i populacijske pripadnosti (Bender, Margaritoni 2015). Forenzična facijalna rekonstrukcija predstavlja složen proces koji se koristi ka- da druge metode identifikacije ne uspiju. Za njom se poseže ukoliko ne postoji podudara- nje s bazama nestalih osoba, zubnih kartona niti tragova na mjestu pronalaska posmrtnih ostataka, koji mogu voditi k otkrivanju iden- titeta. Prema anatomskim značajkama luba- nje stvara se približan izgled lica kako bi se olakšala prepoznatljivost. Iako je ova metoda korisna, postoje određena ograničenja. Od- nos između kosti lubanje i mekih tkiva nije uvijek precizan, te rekonstrukcija nudi samo približnu sliku izvornog izgleda (Subsol, Qu- atrehomme 2005). Također, promjene koje se događaju tijekom starenja, posebno kod dje- ce, mogu utjecati na točnost rekonstrukcije (Wilkinson 2004).

Cilj ovog rada je prikazati postupak rekon- strukcije mekih tkiva lica na modelu lubanje osobe usmrćene krajem Drugog svjetskog ra- ta ili početkom poraća na području Gračana u Zagrebu te stvoriti njezin približan zaživot- ni izgled korištenjem programa Blender za 3D oblikovanje.

## MATERIJAL I METODE

Izdvojena lubanja s donjom čeljusti označena brojem 9 dio je koštanih ostataka najmanje de- vedeset pet osoba otkrivenih u masovnoj grob- nici na mikrolokaciji Peščenka u Gračanima, najsjevernijem dijelu grada Zagreba. Terensko istraživanje masovnih grobnica na navedenom području provedeno je 2018. godine, tijekom kojeg je potvrđeno sedam lokacija s ostatcima najmanje dvjesto devedeset četiri osobe (MHB 2018). Cijeli postupak, koji uključuje otkriva- nje, terensko istraživanje masovnih grobnica, ekshumaciju koštanih ostataka i analizu u smi- slu identifikacije u nadležnosti je i organizaciji Uprave za zatočene i nestale Ministarstva hr- vatskih branitelja (Petaros et al. 2021). U teren- skom laboratoriju lubanja je stabilizirana i oči- šćena te djelomice rekonstruirana. Antropološ- ka analiza lubanje s donjom čeljusti broj 9, kao i svih koštanih ostataka s navedenog lokalite- ta izvedena je u mrtvačnici Zavoda za sudsku medicinu i kriminalistiku Medicinskog fakulte-

system, which arose from forensic anthropom- etry. Craniometry, as a branch of anthropom- etry, is defined as the process of measuring the extent and shape of the skull for the purpose of deter- mining its physical characteristics and its popu- lation affiliation (Bender, Margaritoni 2015). Fo- rensic facial reconstruction is a complex process used when other methods of identification fail. It is used if there is no match with the databases of missing persons dental records or traces at the place where the remains were found, which can lead to the discovery of identity. Based on the anatomical characteristics of the skull, the ap- proximate appearance of the face is created to fa- cilitate recognition. Although this method is use- ful, there are certain limitations. The relationship between the bones of the skull and the soft tis- sues is not always precise, which means that the reconstruction offers only an approximate picture of the original appearance (Subsol, Quatrehomme 2005). Also, changes that occur during ageing, especially in children, can affect the accuracy of the reconstruction (Wilkinson 2004).

This work aims to show the procedure for re- constructing the soft tissues of the face on a skull model of a person murdered at the end of the World War II or at the beginning of the post-war period in the area of Gračani in Zagreb and to cre- ate its approximate life-like appearance using the Blender program for 3D modeling.

## MATERIAL AND METHODS

The separated skull with the lower jaw marked with the number 9 is part of the bone remains of at least ninety-five people were uncovered in a mass grave at the Peščenka microsite in Gračani, the northernmost part of the city of Zagreb. A field survey of mass graves in the mentioned area was conducted in 2018, during which seven loca- tions with the remains of at least two hundred and ninety-four people were confirmed (MHB 2018). The entire procedure, which includes discovery, field research of mass graves, exhumation of bone remains and analysis in terms of identifica- tion, is under the jurisdiction of the Directorate for Detainees and Missing Persons of the Min- istry of Croatian Veterans (Petaros et al. 2021). The skull was stabilized, cleaned, and partially reconstructed in the field laboratory. The anthro- pological analysis of the skull with the lower jaw number 9, as well as all the bone remains from the mentioned microsite, was performed in the morgue of the Department of Forensic Medicine

ta Sveučilišta u Zagrebu (MHB 2019). Lubanja broj 9 odabrana je za facijalnu rekonstrukciju zbog visokog stupnja očuvanosti i cjelovitosti (sl. 1). Naime, 63 % lubanja s mikrolokacije Peščenka ima zabilježenu barem jednu strijelnu ranu (*vulnera sclopetaria*). Na izbor je utjecala i odsutnost većih tafonomskih promjena te postmortalnih oštećenja. Izvedba facijalne rekonstrukcije u svim fazama omogućena je suradnjom Ministarstva hrvatskih branitelja i Ureda za forenzične znanosti Sveučilišta u Zagrebu.

Za 3D računalnu rekonstrukciju lica lubanja s pričvršćenom donjom čeljusti snimljena je 3D laserskim skenerom Cyberware 3030 (Cyberware Inc., Monterey, California). Snimanje je izvedeno je u okviru aktivnosti Ureda za forenzične znanosti Sveučilišta u Zagrebu, na Zavodu za tehnologiju i Katedri za alatne strojeve Fakulteta strojarstva i brodogradnje Sveučilišta u Zagrebu. Nakon analize, lubanja je vraćena Ministarstvu hrvatskih branitelja na trajno zbrinjavanje.

## Antropološka analiza

Antropološke analitičke metode upotrijebljene u ovom radu obuhvatile su procjenu spola ispitujući makromorfološke značajke lubanje s donjom čeljusti te procjenu doživljene starosti prema stupnju srastanja šavova lubanje i nepčane kosti te atricije griznih površina kutnjaka. Uslijed nedostatka ostalih osteoloških elemenata kostura, odnosno samo na temelju značajki lubanje i donje čeljusti, u istraživanju su primijenjene i sekundarne metode procjene doživljene starosti, uz preporučeni oprez (Klepinger 2006). Obje navedene metode su upotrijebljene kako bi se postigao točniji rezultat.

Spol osobe utvrđen je prema morfološkim značajkama lubanje s donjom čeljusti i osteološkim strukturama uz bodovanje četrnaest spolnih znakova i izračuna stupnja seksualnosti (Krogman 1939; Acsádi, Nemeskéri 1970; Ferembach et al. 1980; Buikstra, Ubelaker 1994; Isçan, Steyn 2013).

Za prikaz raspona doživljene starosti koristila se Martinova podjela s osam faza: do sedme godine života (*infans I.*), od sedme do četrnaeste godine (*infans II.*), od četrnaeste do dvadeset prve (*juvenilis/juvenus*), od dvadeset prve do dvadeset devete (*adultus I.*), od tridesete do trideset devete (*adultus II.*), od četrdesete do četrdeset devete (*maturus I.*), od pedesete do pedeset devete godine (*maturus II.*) te više od

and Criminology, the Faculty of Medicine, University of Zagreb (MHB 2019). Skull number 9 was chosen for facial reconstruction due to its high degree of preservation and completeness (Fig. 1). Namely, 63% of the skulls from the Peščenka microsite have recorded at least one gunshot wound (*vulnera sclopetaria*). The absence of major taphonomic changes and postmortem damage also influenced the choice. The performance of facial reconstruction in all phases was made possible by the cooperation of the Ministry of Croatian Veterans and the Office of Forensic Sciences of the University of Zagreb.

For 3D computer reconstruction of the face, the skull with the attached lower jaw was scanned with a 3D laser scanner Cyberware 3030 (Cyberware Inc., Monterey, California). The scanning was carried out as part of the activities of the Forensic Sciences Office of the University of Zagreb, at the Department of Technology and the Department of Machine Tools, Faculty of Mechanical Engineering and Shipbuilding, University of Zagreb. After the analysis, the skull was returned to the Ministry of Croatian Veterans for permanent care.

## Anthropological analysis

The anthropological analytical methods used in this work included the evaluation of sex by examining the macromorphological features of the skull with the lower jaw and the assessment of the age at death according to the degree of the skull and palatal bone sutures closing and attrition degree of the molars biting surfaces. Due to the lack of other osteological elements of the skeleton, i.e. based only on the features of the skull and lower jaw, secondary methods of age at death evaluation were also applied in the research, with recommended caution (Klepinger 2006). Both methods are used in order to achieve a more accurate result.

A person's sex was determined according to the morphological features of the skull and the lower jaw and osteological structures with the fourteen sexual signs scoring and the sexuality degree calculation (Krogman 1939; Acsádi, Nemeskéri 1970; Ferembach et al. 1980; Buikstra, Ubelaker 1994; Isçan, Steyn 2013).

To show the age at death range, Martin's division with eight stages was used: up to the seventh year of life (*infans I*), from the seventh to the fourteenth year (*infans II*), from the fourteenth to the twenty-first (*juvenilis/juvenus*), from the twenty-first to the twenty-nine (*adultus I*), from thirty to

šezdeset godina (*senilis*) (Martin, Saller 1957).

Starost osobe procijenjena je prema sekundarnoj metodi stupnja sraštanja lubanjskih šavova, uključujući i šavove na bazi lubanje (Krogman, Isčan 1986; Mann 1987; Nawrocki 1998), sraštanja nepčanih šavova (Mann 1987; Mann et al. 1987; 1991; Beauthier et al. 2010) te stupnja trošenja okluzalnih površina kutnjaka (Brothwell 1981). Sagitalni šav prvi počinje sraštati u ranim tridesetima, treći dio sagitalnog šava ( $S_3$  – *pars obelica*) u potpunosti srašta u ranim tridesetim godinama, dok cijeli šav potpuno srašta između šezdeset prve i šezdeset pete godine života. Vjenačni šav u potpunosti srašta između pedeset šeste i šezdesete godine života. Poput ostalih glavnih šavova, lambdoidni šav u dijelu  $L_1$  započinje se zatvarati u kasnim dvadesetima, dok će u potpunosti sraštati između šezdeset šeste i sedamdesete godine starosti (Khandare et al. 2015). Mann je na temelju istraživanja nepčane kosti, odnosno šavova nepčane kosti zaključio da sraštanje sjekutičnog šava, ukoliko se razvije, započinje oko dvadeset pete godine života, dok se poprečni šav (*sutura palatina transversa*) zatvara između tridesete i četrdesete godine, a medijani (*sutura palatina mediana*) oko pedesete godine života (Mann et al. 1987).

Podrijetlo osobe, odnosno populacijska pripadnost određena je prema nekoliko makromorfoloških značajki na lubanji (Rhine 1990; Hincak Daris 2024).

## Proces rekonstrukcije lica

Proces rekonstrukcije lica zasniva se na metodi opisanoj u priručniku „Manual de Reconstrução Facial 3D Digital: Aplicações com Código Aberto e Software Livre“. Rekonstrukcija lica izvedena je pomoću programa otvorenog koda i sastoji se od nekoliko faza. Na početku se stvara trodimenzionalni model lubanje, a zatim se na njega dodaju virtualne oznake koje predstavljaju debljinu mekog tkiva. Sljedeći korak uključuje oblikovanje profila lica te dodavanje kože. Nakon postupka osjenčavanja pri računalnoj obradi dobiva se vizual rekonstruiranog lica (Moraes, Miamoto 2015). Pri izradi ove rekonstrukcije korištene su dvije metode, Metoda Lebedinskaya (Lebedinskaya et al. 1993) i Manchesterska metoda (Prag, Neave 1997). Obje se mogu koristiti u kombinaciji kako bi se postigla što preciznija i vjerodostojnija forenzična aproksimacija lica. Njihova kombi-

thirty-nine (*adultus II*), from forty to forty-nine (*maturus I*), from fifty to fifty-ninth (*maturus II*) and over sixty years (*senilis*) (Martin, Saller 1957).

A person's age at death was estimated according to the secondary method, skull sutures fusion degree, including sutures at the base of the skull (Krogman, Isčan 1986; Mann 1987; Nawrocki 1998) and palatal sutures (Mann 1987; Mann et al. 1987; 1991; Beauthier et al. 2010) and the degree of wear of the occlusal surfaces of the molars (Brothwell 1981). The sagittal suture first begins to fuse in the early thirties, with the third part of the sagittal suture ( $S_3$  – *pars obelica*) completely fuses in the early thirties, while the entire suture completely fuses between the ages of sixty-one and sixty-five. The coronal suture completely fuses between the ages of fifty-six and sixty. Like other major sutures, the lambdoid suture in the  $L_1$  segment begins to close in the late twenties, while it will fully fuse between the ages of sixty-six and seventy (Khandare et al. 2015). Based on the research of the palatine bone, that is, the sutures of the palatine bone, Mann concluded that the fusion of the incisor suture, if it develops, begins around the age of twenty-five, while the transverse suture (*sutura palatine transversa*) closes between the ages of thirty and forty, and the median (*sutura palatine median*) around the age of fifty (Mann et al. 1987).

A population affiliation of a person is determined according to several macromorphological features on the skull (Rhine 1990; Hincak Daris 2024).

## Facial reconstruction process

The facial reconstruction process is based on the method described in the manual “Manual de Reconstrução Facial 3D Digital: Aplicações com Código Aberto e Software Livre“. Facial reconstruction was performed using an open-source program that consisted of several stages. In the beginning, a three-dimensional model of the skull is created, and then virtual markers representing the thickness of the soft tissue are added to it. The next step involves shaping the face profile and adding skin. After the shading procedure during computer processing, a visual of the reconstructed face is obtained (Moraes, Miamoto 2015). Two methods were used when making this reconstruction: the Lebedinskaya method (Lebedinskaya et al. 1993) and the Manchester method (Prague, Neave 1997). Both can be used in combination to achieve the most accurate and



nacija omogućuje ravnotežu između znanosti i umjetnosti gdje Manchesterska metoda donosi umjetnički pristup, dok se metoda Lebedinskaya oslanja na točne antropološke mjere. Tako se osigurava etnički i demografski točna rekonstrukcija lica obogaćena digitalnim tehnikama. Također, pruža fleksibilnost u slučajevima s malo podataka jer metoda Lebedinskaya daje smjernice prema etničkim značajkama, dok Manchesterska metoda omogućuje prilagodbu lica prema dostupnim podatcima.

Proces rekonstrukcije lica izveden je u specijaliziranim 3D programima: Blender (Blender Foundation®, Ton Roosendaal), MakeHuman (MakeHuman Team®) i OrtogOnBlender (Cícero Moraes, dr. Everton da Rosa, dr. Rodrigo Dornelles). MakeHuman omogućuje brzo definiranje osnovnog oblika lica, čime se štedi vrijeme i omogućuje posvećivanje veće pažnje detaljima u kasnijim fazama procesa. Proces je bio strukturiran u nekoliko međusobno povezanih faza.

U procesu digitalizacije lubanje primijenjen je 3D skener Cyberware 3030 (Cyberware Inc., Monterey, California). Ovaj uređaj koristi posebnu strukturu laserskog snopa koja omogućuje visokorezolucijske 3D podatke o objektu. Laserska zraka se projicira na lubanju, a reflektirana svjetlost se hvata pomoću niza kamera. Dobiveni podaci, koji uključuju x, y, z koordinate za geometriju i RGB vrijednosti za boju, obrađeni su kako bi se stvorio detaljan 3D model. Model je pohranjen u digitalnom formatu i može se obrađivati u programu za 3D oblikovanje. Na taj način stvorena je virtualna kopija lubanje, koja omogućuje detaljno proučavanje njezinih morfoloških značajki, bez potrebe za direktnim kontaktom s izvornim primjerkom (Ćirić 2019).

## REZULTAT

### Antropološka analiza

Antropološka analiza provedena je kako bi se utvrdio biološki profil osobe. Ispitivana lubanja očuvana je u svim elementima kosti glave s donjom čeljusti. U pogledu straga (*norma occipitalis*) lubanja je oblika kuće, dok je njezin oblik u pogledu odozgo (*norma verticalis*) pentagoidan.

Izabrana lubanja za facijalnu rekonstrukciju, lubanja s donjom čeljusti broj 9 (sl. 1), pripadala je muškoj osobi. Bodovano je četrnaest spolnih znakova i antropoloških točaka na lubanji: *glabella* +1, *relief planum nuchale* +2, *tuber frontale et parietale* 0, *forma orbitae* +1, *arcus su-*

credible forensic approximation of the face. Their combination allows for a balance between science and art, where the Manchester method brings an artistic approach, while the Lebedinskaya method relies on accurate anthropological measurements. This ensures ethnically and demographically accurate facial reconstruction enriched with digital techniques. Also, it provides flexibility in cases with little data, as the Lebedinskaya method provides guidelines according to ethnic characteristics, while the Manchester method allows face adjustment according to available data.

The facial reconstruction process was performed in specialized 3D programs: Blender (Blender Foundation®, Ton Roosendaal), MakeHuman (MakeHuman Team®) and OrtogOnBlender (Cícero Moraes, Dr. Everton da Rosa, Dr. Rodrigo Dornelles). MakeHuman allows to quickly define the face's basic shape, saving time and allowing to pay more attention to details in the later stages of the process. The process was structured in several interconnected phases.

A 3D scanner Cyberware 3030 (Cyberware Inc., Monterey, California) was used in the skull digitization process. This device uses a special laser beam structure, enabling high-resolution 3D data about the object. A laser beam is projected onto the skull, and cameras capture the reflected light. The resulting data, which includes x, y, and z coordinates for geometry and RGB values for colour, is processed to create a detailed 3D model. The model is stored in digital format and can be processed in a 3D design program. In this way, a virtual copy of the skull was created, which enables a detailed study of its morphological features, without the need for direct contact with the original specimen (Ćirić 2019).

## RESULTS

### Anthropological analysis

Anthropological analysis was carried out to determine a person's biological profile. The examined skull is preserved in all elements of the head bone and the lower jaw. When viewed from behind (*norma occipitalis*), the skull is house-shaped, while its shape from above (*norma verticalis*) is pentagoid.

The skull chosen for facial reconstruction, a skull with lower jaw number 9 (Fig. 1), belonged to a male person. Fourteen sexual signs and anthropological points on the skull were scored: *glabella* +1, *relief planum nuchale* +2, *tuber fron-*

*pracilliaris* +1, *inclinatio os frontale* +1, *processus mastoideus* +1, *margo inferior mandibulae* +1, *angulus mandibulae* +1, *processus zygomaticus* +2, *trigonum mentale* +1, *protuberantia occipitalis externa* +2, *corpus mandibulae* +1, *os zygomaticum* +2. Stupanj seksualizacije prema bodovanju spolnih znakova na lubanji iznosi + 1,28 te osoba pokazuje makromorfološke značajke muškog spola tipa *masculinum*.

Sekundarni pokazatelji doživljene starost, šavovi na lubanji, upućuju na mlađu osobu čija starost u trenutku smrti nije prelazila trideset pet godina. Dva šava na ektokraniju i endokraniju lubanje, vjenačni i lambdoidni su otvoreni, dok je početak srastanja vidljiv na S<sub>3</sub> dijelu sagitalnog šava u obje projekcije. Stupanj srastanja nepčanih šavova (*sutura palatina mediana* et *sutura palatina transversa*) također je uključen u analizu. Oba, medijalni i transverzalni nepčani šav u potpunosti su otvoreni. Prema navedenoj analizi, starost osobe u trenutku smrti procijenjena je u rasponu od kraja dvadesetih do tridesetak godina (*adultus I*).

Sljedeći ispitani parametar bio je stupanj srastanja šavova nepčane kosti. Medijana nepčana kost i transverzalna kost (*sutura palatina mediana* et *sutura palatina transversa*) u potpunosti su otvorene.

Dvije su nemetričke epigenetičke varijacije lubanjskih šavova vidljive na lubanji broj 9. Na zatiljnom području lubanje opaža se poprečni šav koji dijeli zatiljnu ljusku u dijelu najviše šižine linije (*linea nuchales*) i u dvije točke dodiruje lambdoidni šav (*sutura lambdoidea*), tvoreći novu kost ili koštani otok (*os interparietale*). U pogledu sprijeda, u medijanoj liniji na čeonj kosti jasno je vidljiva anatomska varijacija – metopični šav u punoj dužini čeone kosti (sl. 1).

Zubni niz u donjoj i gornjoj čeljusti (*mandibula* et *maxilla*) dobro su očuvani u neoštećenim alveolama. U lijevoj gornjoj čeljusti nije očuvan potpuni zubni niz, već su utvrđeni zubi na pozicijama: I<sup>2</sup>, C, P<sup>1</sup>, P<sup>2</sup> i M<sup>3</sup>. Opažaju se neoštećene, prazne alveole na pozicijama I<sup>1</sup>, M<sup>1</sup> i M<sup>2</sup>, uslijed postmortalnog gubitka zuba. U desnoj gornjoj čeljusti prisutni su zubi u alveolama na pozicijama: I<sup>2</sup>, C, P<sup>1</sup>, P<sup>2</sup>, M<sup>1</sup>. Zamjećuje se postmortalno prazna alveole na poziciji I<sup>1</sup>. Donja čeljust je općenito bolje očuvana. Zubni niz lijeve strane donje čeljusti gotovo je u potpunosti očuvan: I<sub>2</sub>, C, P<sub>1</sub>, P<sub>2</sub>, M<sub>1</sub>, M<sub>2</sub> i M<sub>3</sub>. Prazna je tek alveola na poziciji I<sub>1</sub> uslijed postmortalnog gubitka zuba. Desna strana donje čeljusti očuvana je u kraćem nizu na pozicijama: I<sub>1</sub>, I<sub>2</sub>, C, M<sub>1</sub>, M<sub>2</sub>, M<sub>3</sub>. Očuva-

*tale et parietale* 0, *forma orbitae* +1, *arcus supracilliaris* +1, *inclinatio os frontale* +1, *processus mastoideus* +1, *margo inferior mandibulae* +1, *angulus mandibulae* +1, *processus zygomaticus* +2, *trigonum mentale* +1, *protuberantia occipitalis externa* +2, *corpus mandibulae* +1, *axis zygomaticum* +2. The sexualization degree according to the scoring of the sexual signs on the skull is + 1.28, and the person shows the macro-morphological features of the masculinum type of male sex (*masculinum*).

Secondary indicators of age, such as skull sutures, point to a younger person whose age at the time of death did not exceed thirty-five years. Two sutures on the ectocranium and endocranium of the skull, coronal and lambdoid, are open. At the same time, the beginning of fusion is visible on the S3 part of the sagittal suture in both projections. The degree of the palatal sutures tenderness (*sutura palatina mediana* et *sutura palatina transversa*) was also included in the analysis. Both the medial and transverse palatal sutures are entirely open. According to the aforementioned analysis, the person's age at the time of death was estimated to be in the late twenties to about thirty years (*adultus I*).

The following parameter examined was the degree of fusion of the sutures of the palatal bone. Median palatine bone and transverse bone (*sutura palatina mediana* et *sutura palatina transversa*) are completely open.

Two non-metrical epigenetic variations of skull sutures are visible on skull number 9. On the occipital region of the skull, a transverse suture can be observed that divides the occipital scale in the part of the highest neckline (*linea nuchales*) and touches the lambdoid suture (*sutura lambdoidea*) at two points, forming a bone island (*os interparietale*). In the frontal view, in the median line on the frontal bone, an anatomical variation is visible – the metopic suture runs the entire length of the frontal bone (Fig. 1).

The dental row in the lower and upper jaw (*mandibula* et *maxilla*) are well preserved in undamaged alveoli. In the left upper jaw, the complete set of teeth has not been preserved, but the teeth in the positions I<sup>2</sup>, C, P<sup>1</sup>, P<sup>2</sup> and M<sup>3</sup> have been identified. Due to postmortem tooth loss, there are undamaged, empty alveoli at positions I<sup>1</sup>, M<sup>1</sup> and M<sup>2</sup>. In the right upper jaw, there are teeth in the alveoli at positions I<sup>2</sup>, C, P<sup>1</sup>, P<sup>2</sup>, and M<sup>1</sup>. Postmortem empty alveoli can be observed at position I<sup>1</sup>. The lower jaw is generally better preserved. The dental row of the left side of the





Sl. 1 – Lubanja 9, pogled sprijeda (*norma frontalis*), Gračani, Zagreb (prema Ćirić 2019: 53; snimila: I. Ćirić)  
 Fig. 1 – Skull 9, frontal view (*norma frontalis*), Gračani, Zagreb (after Ćirić 2019: 53; photo by: I. Ćirić)

ne su prazne alveole na pozicijama  $P_1$ ,  $P_2$  koje upućuju na postmortalni gubitak zuba. Treći kutnjaci donje i lijeve gornje čeljusti nalaze se u okluzalnoj ravnini. Vrlo slaba abrazija griznih površina potvrđuje mladost osobe.

Prema navedenim analizama, procijenjena starost osobe nalazi se u rasponu od dvadeset pet do trideset godina (*adultus I*). Na nepčanoj kosti (*os palatinum*) iz sjekutićnog otvora (*foramen incisivum*) opaža se meziodens, prekobrojni zub, koji je rotiran za 90 stupnjeva. Predstavlja varijaciju u razvoju zuba u čeljusti, a smješten je u medijanoj liniji između prva dva sjekutića gornje čeljusti.

Ukupno su otkrivene tri anomalije na lubanji, dvije kao nemetričke varijacije – os interparietale i metopizam, a na gornjoj čeljusti prekobrojni zub – meziodens.

Populacijska pripadnost određena je prema makromorfološkim značajkama na lubanji. Nosne kosti su u pogledu sprijeda postavljene kao mali tornjevi na blago spušten do udubljen korijen nosa, dok je nosni most izdignut. Nosni trn je jače izražen, kao i prag nosa. Grana donje

lower jaw is almost completely preserved:  $I_2$ , C,  $P_1$ ,  $P_2$ ,  $M_1$ ,  $M_2$  and  $M_3$ . Only the alveolus at position  $I_1$  is empty due to postmortem tooth loss. The right side of the lower jaw is preserved in a shorter sequence at positions  $I_1$ ,  $I_2$ , C,  $M_1$ ,  $M_2$ , and  $M_3$ . Empty alveoli have been preserved in positions  $P_1$  and  $P_2$ , which point to postmortem tooth loss. The third molars of the lower and left upper jaw are located in the occlusal plane. Very slight abrasion of the occlusal surfaces confirms the youth of the person.

According to the aforementioned analyses, the estimated age at death of the person is in the range of twenty-five to thirty years (*adultus I*). On the palatine bone (*os palatinum*) from the incisor opening (*foramen incisivum*) a mesiodens, supernumerary tooth, rotated by 90 degrees, is observed. It represents a variation in the development of teeth in the jaw and is located in the median line between the first two incisors of the upper jaw.

A total of three anomalies were discovered on the skull, two as non-metric variations – os interparietale and metopism, and on the upper jaw the supernumerary tooth – mesiodens.

Population affiliation is determined according to macromorphological features on the skull. In the anterior view, the nasal bones are placed like small towers on the slightly lowered to the sunken root of the nose, while the nasal bridge is elevated. The bridge of the nose is more pronounced, as is the nasal spine. The ramus of the lower jaw is slightly indented on the upper third of the bone. The bulging surface of the palatal bone and Carabelli's sign on the first molars of the upper jaw stand out. In the neck (*regio nuchales*), a well-developed attachment of the long muscle of the head is visible. The eye sockets (*orbitae*) are square, and the lateral part is placed downwards. The nostril is narrow. The metopic suture is preserved, and descendants of Europeans often preserve that variant or at least parts of the metopic suture in different lengths and phases on the frontal bone.

čeljusti je blago udubljena na gornjoj trećini kosti. Posebno se ističe ispupčena površina nepčane kosti i Carabellijev znak na prvim kutnjacima gornje čeljusti. Na šijinom području (*regio nuchales*) vidljivo je dobro razvijeno mjesto prihvata dugog mišića glave. Očnice (*orbitae*) su četvrtaste i lateralni dio je postavljen prema dolje. Nosni otvor je uzak. Očuvan je metopički šav, a potomci Europljana često očuvaju tu varijantu ili barem dijelove metopičnog šava u različitim dužinama i fazama na čeonj kosti.

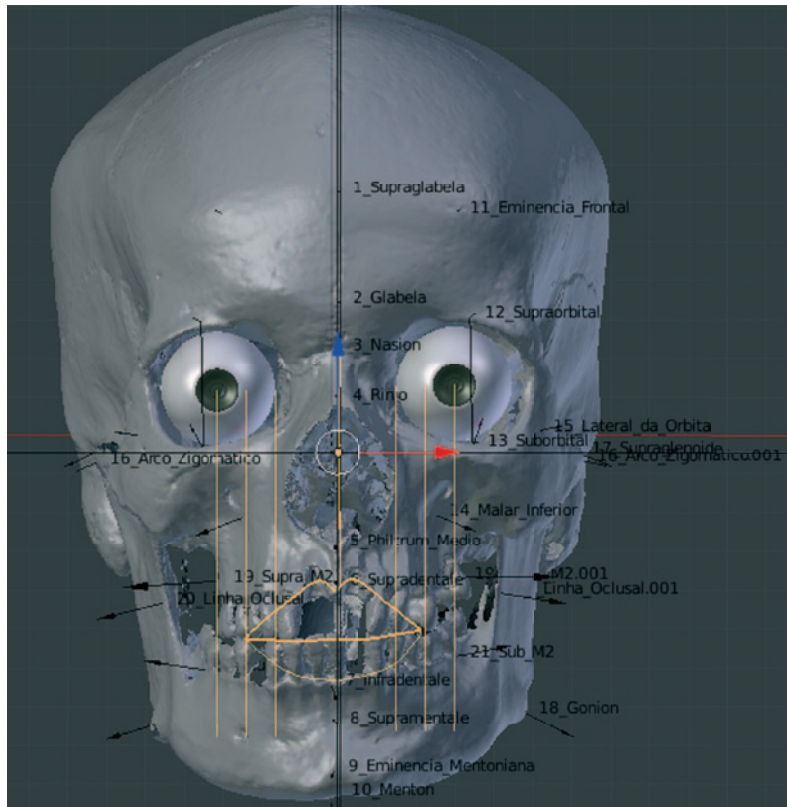
## Facijalna rekonstrukcija

Prvi korak u rekonstrukciji lica bio je uvoz 3D modela skenirane lubanje u STL formatu u program Blender. Skenirana lubanja je zatim precizno pozicionirana u položaj frankfurtske horizontale, odnosno u ravninu oko – uho, kako bi se osigurala anatomske točna orijentacija. U profilnom pogledu svodi se na jednu horizontalnu liniju, dok vertikalna linija služi kao temelj za stvaranje profila (Wilkinson 2004). Ovaj postupak ključan je za preciznu procjenu dubine mekih tkiva. Antropometrijski podaci o debljini mekih tkiva, za osobe u dobi od 18 do 29 godina, prikazani su oznakama s određenim vrijednostima debljine tkiva te je s pomoću njih izrađen približan obris lica (sl. 2–3). Pri odabiru tablice s podacima o debljini tkiva uzeti su u obzir su spol, podrijetlo i dob pojedin-

## Facial reconstruction

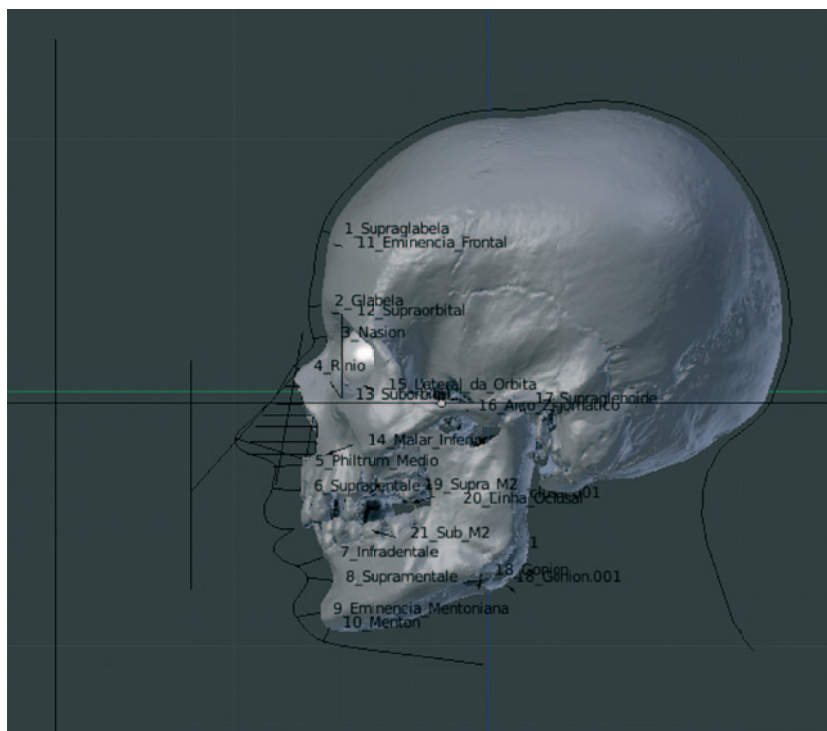
The first step in facial reconstruction was to import the 3D model of the scanned skull in STL format into the Blender program. The scanned skull is then precisely positioned in the Frankfurt horizontal position, i.e. in the eye-ear plane, to ensure anatomically correct orientation. In the lateral view, it is reduced to one horizontal line, while the vertical line serves as the basis for creating the profile (Wilkinson 2004). This procedure is crucial for the accurate assessment of soft tissue depth. Anthropometric data on the thickness of soft tissues for people aged 18 to 29 years are shown with markers with specific values of tissue thickness, and with their help, an approximate outline of the face is created (Figs. 2–3). When selecting the table with data on tissue thickness, the sex, origin and age of the individual were taken into account. Despite the databases typically used in the reconstruction process (measures according to Rhineau and Mooreau), in this case, more recent data from De Greef's research were used, which proved to be more appropriate (De Greef et al. 2006).

With the obtained high-resolution 3D skull model in STL format (without colour and texture data), the reconstruction process was started in the Blender program. The model consists of



Sl. 2 – Pomoćne linije korištene pri izradi usana i umetanju očnih jabučica. Norma frontalis, lubanja 9, Gračani (prema Čirić 2019: 53; izradila: I. Čirić)

Fig. 2 – Auxiliary lines are used when making lips and inserting eyeballs. Norma frontalis, skull 9, Gračani (after Čirić 2019: 53; made by: I. Čirić)



Sl. 3 – Rekonstruirani profil osobe. *Norma lateralis*, lubanja 9, Gračani (prema Ćirić 2019: 58; izradila: I. Ćirić)

Fig. 3 – Reconstructed profile of the person. *Norma lateralis*, skull 9, Gračani (after Ćirić 2019: 58; made by: I. Ćirić)

ca. Unatoč bazama podataka inače korištenim u procesu rekonstrukcije (mjere prema Rhineau i Mooreau), u ovom slučaju, korišteni su noviji podaci iz istraživanja De Greefa, koji su se pokazali prikladnijima (De Greef et al. 2006).

Dobivenim visokorezolucijskim 3D modelom lubanje u STL formatu (bez podataka o boji i teksturi) započet je proces rekonstrukcije u programu Blender. Model se sastoji od mnoštva poligona (*faceta*) što mu pruža precizniji i glađi oblik. Ovaj 3D model pruža preciznu geometrijsku osnovu za daljnje oblikovanje i postupno „oživljavanje“ lica. Detaljan pregled sljedećih koraka u procesu rekonstrukcije lica prikazan je u tab. 1 (Ćirić 2019).

U programu MakeHuman kreiran je univerzalni model ljudskog lica prilagođen antropometrijskim podacima dobivenim analizom lubanje. Na temelju dostupnih koštanih ostataka nije bilo moguće procijeniti visinu i masu osobe te su postavljene prosječne vrijednosti od 178 cm i 80 kg. Model, za kojeg je antropološkom analizom utvrđeno da je Europljanin u dobi od 25 godina, uvezen je u OrtoGOnBlender u OBJ formatu i precizno poravnat s 3D modelom lubanje. Koristeći alate za 3D oblikovanje stvarana je detaljna mreža lica, koja je usklađena s anatomskim karakteristikama lubanje (sl. 4) (Ćirić 2019).

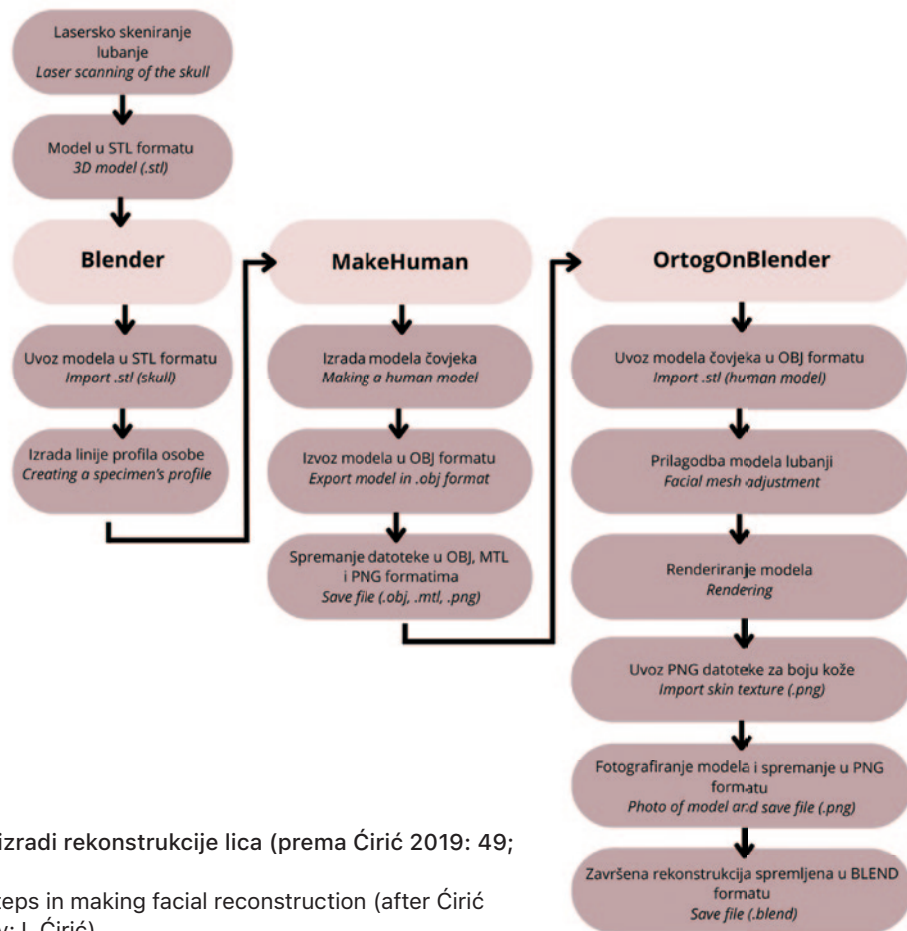
Za stvaranje kože korištena je kvalitetna PNG tekstura, koja je omogućila stvaranje točnijeg izgleda. Kako bi se povećala vizualna privlačnost modela primijenjen je niz modifikatora, primjerice subdivizija površine, što je rezultiralo povećanjem

many polygons (*faceta*), which gives it a more precise and smoother shape. This 3D model provides a precise geometric basis for further shaping and gradually “reviving” the face. A detailed overview of the next steps in the face reconstruction process is shown in Tab. 1 (Ćirić 2019).

In the program MakeHuman, a universal model of the human face was created and adapted according to the anthropometric data from the skull analysis. Estimating the person’s stature and mass was impossible based on the preserved osteological remains. Therefore, average values of 178 cm and 80 kg were set. The model, determined as a European male aged at death of 25 years, was imported into OrtoGOnBlender in OBJ format and precisely aligned with the 3D model of the skull. Using 3D modelling tools, a detailed facial network was created and coordinated with the anatomical characteristics of the skull (Fig. 4) (Ćirić 2019).

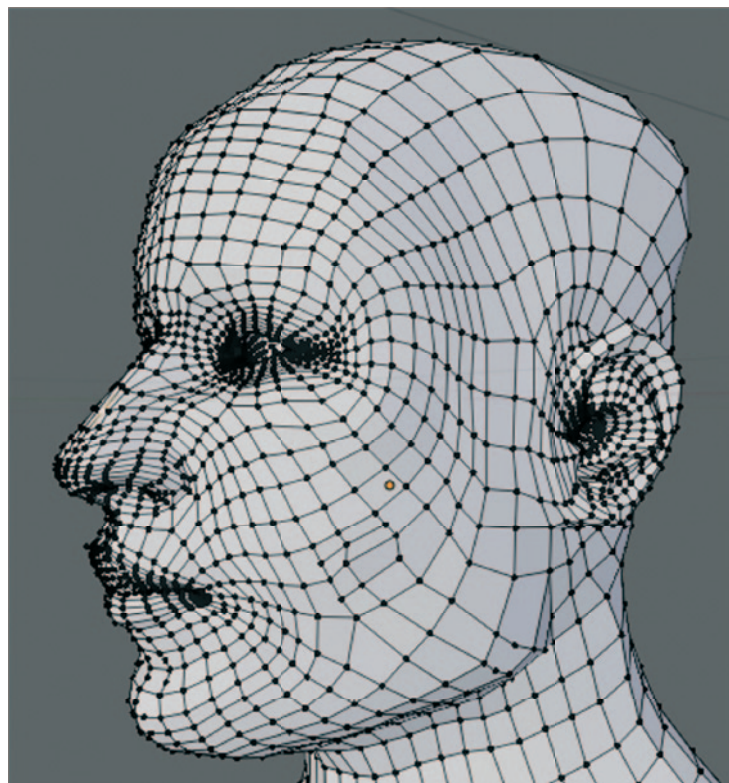
A high-quality PNG texture was used to create the skin, which made it possible to create a more accurate look. In order to increase the visual appeal of the model, several modifiers were applied, such as surface subdivision, which increased the number of polygons and created a smoother surface for the model. The final 3D model of the reconstructed face, shown in the Fig. 5, represents the best estimate of the person’s original appearance based on the available data (Ćirić 2019).



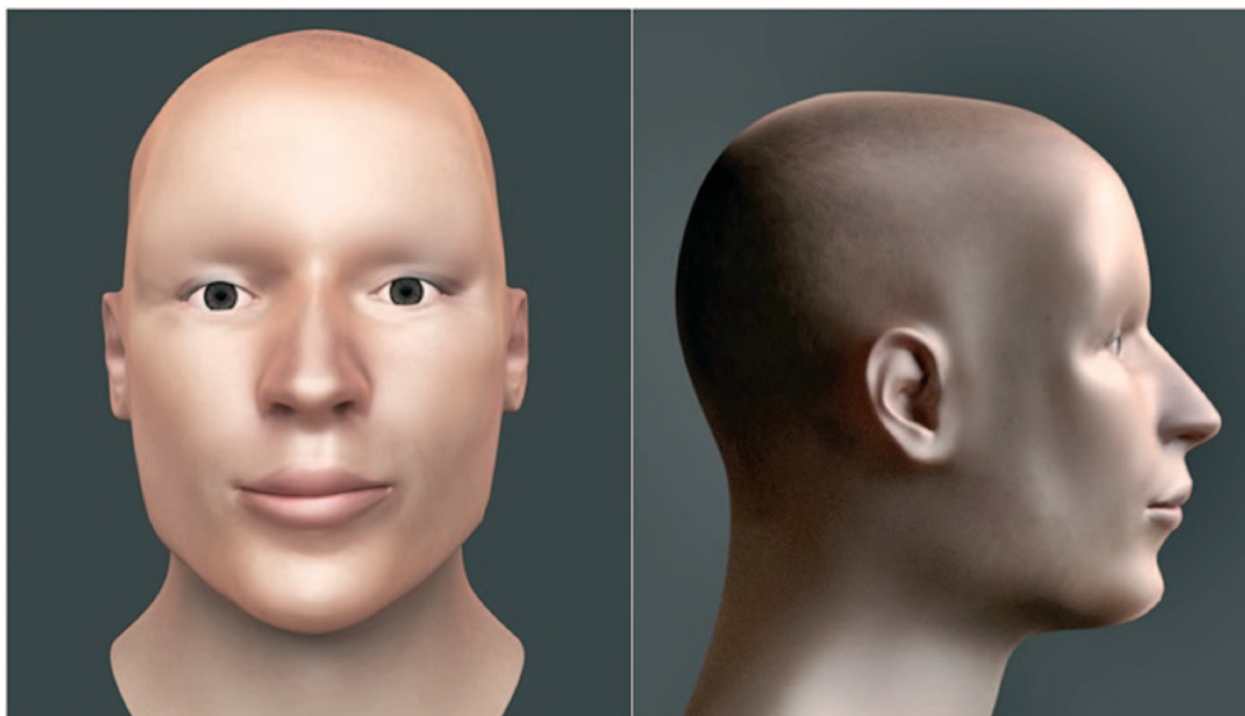

Tab. 1 – Koraci u izradi rekonstrukcije lica (prema Ćirić 2019: 49; izradila: I. Ćirić)

Tab. 1 – Several steps in making facial reconstruction (after Ćirić 2019: 49; made by: I. Ćirić)



Sl. 4 – Mreža modela lica, lubanja 9, Gračani (prema Ćirić 2019: 59; izradila: I. Ćirić)  
Fig. 4 – Face model network, skull 9, Gračani (after Ćirić 2019: 59; made by I. Ćirić)



Sl 5 – Rekonstruirano lice žrtve (*norma frontalis et norma lateralis*), lubanja 9, Gračani (prema Ćirić 2019: 60; izradila: I. Ćirić)

Fig. 5 – Reconstructed face of the victim (*norma frontalis et norma lateralis*), skull 9, Gračani (after Ćirić 2019: 60; made by: I. Ćirić)

broja poligona i glađom površinom modela. Završni 3D model rekonstruiranog lica, prikazan na sl. 5, predstavlja najbolju procjenu izvornog izgleda osobe na temelju dostupnih podataka (Ćirić 2019).

## RASPRAVA

Ljudska sposobnost prepoznavanja lica je složena i temelji se na međusobnom djelovanju brojnih čimbenika. Iako je lice ključno za društvenu interakciju, proces njegovog prepoznavanja i pohranjivanja u memoriji još uvijek nije u potpunosti razjašnjen. Rekonstrukcija lica predstavlja dodatni izazov, s obzirom da se suočavamo s brojnim varijablama koje utječu na izgled lica poput starosne dobi, spola, etničke pripadnosti i individualnih karakteristika koje se teško mogu odrediti na osnovu samog kostura. Prema Bruceu i Youngu, opažaj lica više je od zbroya njegovih dijelova te se lice prepoznaje kao cjelovita struktura, a ne kao skup izoliranih značajki (Bruce, Young 1986). Nedostatak točnosti u rekonstrukciji, koji je često posljedica oslanjanja na prosječne vrijednosti tkiva, može dovesti do gubitka važnih individualnih detalja i otežati usporedbu rekonstruiranog lica s drugim dokazima (Subsol, Quatrehomme

## DISCUSSION

The human ability to recognize faces is complex and based on the interaction of numerous factors. Although the face is crucial for social interaction, the process of its recognition and memory storage still needs to be fully understood. Facial reconstruction represents an additional challenge, given that we are faced with numerous variables that affect the appearance of the face, such as age, gender, ethnicity, and individual characteristics, which can hardly be determined based on the skeleton itself. According to Bruce and Young, the perception of a face is more than the sum of its parts, and the face is recognized as a complete structure, not as a set of isolated features (Bruce, Young 1986). The need for more accuracy in reconstruction, often a consequence of relying on tissue averages, can lead to the loss of important individual details and make it difficult to compare the reconstructed face with other evidence (Subsol, Quatrehomme 2005). Anthropological analysis of skull number 9 revealed the presence of metopism, that is, incomplete fusion of the frontal bone. Although the suture is usually expected to close in early childhood, between four and six years of age (Mann, Hunt 2005), it may



2005). Antropološka analiza lubanje broj 9 otkrila je prisutnost metopizma, odnosno nepotpunog srastanja čeonih kosti. Premda se obično očekuje da se šav zatvori u ranom djetinjstvu, između četvrte i šeste godine života (Mann, Hunt 2005), kod nekih pojedinaca on može biti prisutan i u odrasloj dobi. Iako je metopizam relativno česta pojava, s učestalošću koja prema nekim procjenama ne prelazi 12 % (Krogman 1986), njegova klinička važnost sve se više uočava. Novija istraživanja su pokazala da se nesrasli čeonni šav (*sutura metopica*) može povezati s različitim anatomskim varijacijama i potencijalnim zdravstvenim problemima, poput anomalija čeonih sinusa ili nastanka rascjepa usne (Zdilla et al. 2018).

Utvrđena anomalija, prekobrojni zub, odnosno meziodens, rotiran je za devedeset stupnjeva u sjekutićnom otvoru (*foramen incisivum*) nepčane kosti. Nalazi se na medijanoj ravni, između prvih dva sjekutića gornje čeljusti. Ovakav poremećaj javlja se u početnom stadiju razvoja zubnog zametka (Šutalo et al. 1994). Riječ je o najčešćem tipu prekobrojnog zuba koji se uobičajeno razvija u gornjoj čeljusti, jednostrano ili obostrano, dok je u donjoj čeljusti rijetka (Alberti et al. 2006). Češća je anomalija u stalnoj denticiji ženskih osoba, dok je u mliječnoj denticiji rjeđa. Znanstvena istraživanja dokazuju da se učestalost u općoj populaciji nalazi u rasponu od 0,15 % do 1,9 % (Russell, Folwarczna 2003; Van Buggenhout, Bailleul-Forestier 2008), odnosno 0,15 % do 3,9 % (Meighani et al. 2010; Qamar et al. 2013).

Na mjestu spoja lambdoidnog i sagitalnog šava, na zatiljnom dijelu lubanje vidljiva je epigenetička varijacija oblika trokuta – *os interparietale* ili *os inca (os epactale proprium)*. Iako uobičajeno srasta u prvim mjesecima života novorođenčeta, na lubanji je očuvan je šav (*sutura mendosa*) u punoj dužini, koji čini osnovu trokuta i proteže se poprečno na lubanji od asteriona do asteriona, odjeljujući kost od donjeg dijela zatiljne kosti. Šav prolazi malo iznad ravnine poprečnog sinusa. Lateralne strane ove trokutaste kosti tvori lambdoidni šav, čija se lijeva i desna strana spajaju sa sagitalnim šavom u vrhu, antropološkoj točki lambda. Treba naglasiti da je najčešći oblik ove kosti trokutast, ali da su moguće brojne varijacije i različiti kutovi spajanja navedenih šavova te kost poprima oblik, primjerice, romba ili polukruga (Matsamura et al. 1993). Vjerojatno je najistraživanija prekobrojna kost zatiljne regije lubanje u svim

be present well into adulthood in some individuals. Although metopism is a relatively common phenomenon, with a frequency that, according to some estimates does not exceed 12% (Krogman 1986), its clinical importance is increasingly being observed. Recent research has shown that an unfused frontal suture (*sutura metopica*) can be associated with several anatomical variations and potential health problems, such as frontal sinus anomalies or cleft lip (Zdilla et al. 2018).

The established anomaly, the premolar tooth, or mesiodens is rotated by ninety degrees in the incisor opening (*foramen incisivum*) of the palatine bone. It is located on the median plane, between the first two incisors of the upper jaw. This kind of disorder occurs in the initial stage of tooth embryo development (Šutalo et al. 1994). It is the most common type of supernumerary tooth that usually develops in the upper jaw, unilaterally or bilaterally, while it is rare in the lower jaw (Alberti et al. 2006). The anomaly is more common in the permanent dentition of women, while it is less common in the deciduous dentition. Scientific research proves that the frequency in the general population is in the range of 0.15% to 1.9% (Russell, Folwarczna 2003; Van Buggenhout, Bailleul-Forestier 2008), or 0.15% to 3.9% (Meighani et al. 2010; Qamar et al. 2013).

At the junction of the lambdoid and sagittal sutures, on the occipital part of the skull, an epigenetic shape variation of a triangle is visible – *os interparietale* or *os inca (os epactale proprium)*. Although it usually grows in the first months of a newborn's life, a full-length seam (*sutura mendosa*) is preserved on the skull, which forms the base of the triangle and extends across the skull from asterion to asterion, separating the bone from the lower part of the occipital bone. The suture passes slightly above the plane of the transverse sinus. The lateral sides of this triangular bone are formed by the lambdoid suture, whose left and right sides join the sagittal suture at the top, the anthropological lambda point. It should be emphasized that the most common shape of this bone is triangular. However, numerous variations and different joining angles of the mentioned seams are possible, and the bone takes the shape of, for example, a rhombus or a semi-circle (Matsamura et al. 1993). The supernumerary bone of the occipital region of the skull is the most researched in all world populations. However, although it is often emphasized that this variation has no unique role in anthropology, it is cited as an epigenetic trait that occurs in a higher per-

populacijama svijeta, no iako se često naglašava kako ova varijacija nema neku posebnu ulogu, u antropologiji se navodi kao epigenetska osobina koja se kod određenih populacija javlja u većem postotku (Hanihara, Ishida 2001). U većem postotku javlja se kod muškaraca (Hauser, De Stefano 1989). Učestalost klasičnog tipa ove prekobrojne kosti (*os inca*) oblika pravilnog trokuta u općoj populaciji ne prelazi 2,8% (Kadanoff, Mutafov 1968; Hauser, De Stefano 1989). Torgesen tvrdi da je pojava ove kosti genetički uvjetovana te da se prenosi autosomno dominantnim načinom (Torgersen 1951; Berry 1975). Treba spomenuti mogućnost povezanosti ove varijacije s drugim šavnim, prekobrojnim kostima (*ossa suturalia*) te s pojavom određenih deformacija na kostima lubanje (Ossenberg 1969). Utvrđena je povezanost pojave ovakvih kosti s mehaničkim stresom u fazi ranog, ontogenetskog razvoja (Das et al. 2005).

Prilikom određivanja debljine mekih tkiva pojavile su se određene poteškoće zbog oštećenja lubanje na području goniona i malar inferior točke. Stoga su ove točke postavljene pod približnim kutom i na približna mjesta na lubanji. Za određivanje debljine mekih tkiva korišteni su podaci iz istraživanja De Greefa (De Greef 2006). U ovom su istraživanju, tijekom dvije godine, analizirani podaci od gotovo tisuću Europljana različitih karakteristika. Prednost ovih podataka je što su prikupljeni od živih osoba, čime su smanjeni utjecaji postmortalnih promjena i drugih čimbenika koji bi mogli utjecati na točnost mjerenja. Iako je metoda vrlo napredna, točnost metode može biti ograničena dostupnošću i kvalitetom podataka. Regresijski modeli ovise o bazama podataka o debljini mekog tkiva te zbog toga rekonstrukcija može biti manje precizna, ako podaci nisu dovoljno reprezentativni za određenu populaciju. Također, deformacije ulaznih podataka mogu utjecati na točnost rezultata. Unatoč korištenju složenih statističkih modela, individualna varijabilnost u debljini mekog tkiva predstavlja izazov za ovu metodu. Ograničenja se mogu prevladati uzimanjem u obzir specifičnosti svakog slučaja i kombinacijom s drugim metodama.

Rekonstrukcija gornje usne i Kupidovog luka predstavljala je poseban izazov zbog oštećenja alveolarnog zida i gornjih sjekutića. Slično tome, asimetrija donje čeljusti i oštećenja u području zgloba donje čeljusti otežali su precizno određivanje oblika lica. Nedostaci su nadoknađeni prilagođavanjem mekih tkiva i kori-

centage of specific populations (Hanihara, Ishida 2001). It occurs more in men (Hauser, De Stefano 1989). The frequency of the classic type of this supernumerary bone (*os inca*) in the shape of a regular triangle in the general population does not exceed 2.8% (Kadanoff, Mutafov 1968; Hauser, De Stefano 1989). Torgesen claims that the appearance of this bone is genetically determined and transmitted in an autosomal dominant manner (Torgersen 1951; Berry 1975). The possibility of this variation being connected with other sutured, supernumerary bones (*ossa suturalia*) and the appearance of certain deformations on the bones of the skull should be mentioned (Ossenberg 1969). The connection between such bones' appearance and mechanical stress in the phase of early ontogenetic development has been established (Das et al. 2005).

When determining the thickness of the soft tissues, specific difficulties arose due to damage to the skull in the area of the gonion and malar inferior point. Therefore, these points are placed at an approximate angle and approximate locations on the skull. Data from De Greef's research (De Greef 2006) were used to determine the thickness of soft tissues. In this research, data from almost a thousand Europeans with different characteristics were analysed over two years. The advantage of these data is that they were collected from living persons, thus reducing the influence of postmortem changes and other factors that could affect the accuracy of measurements. Although the method is very advanced, its accuracy may be limited by the availability and quality of the data. Regression models depend on soft tissue thickness databases, and therefore, the reconstruction may be less precise if the data are not representative enough for a specific population. Also, deformations of the input data can affect the accuracy of the results. Despite the use of complex statistical models, individual variability in soft tissue thickness is a challenge for this method. Limitations can be overcome by taking into account the specifics of each case and by combining them with other methods.

Reconstruction of the upper lip and Cupid's bow was a unique challenge due to damage to the alveolar wall and upper incisors. Similarly, the asymmetry of the lower jaw and damage in the area of the lower jaw joint made it challenging to determine the face's shape accurately. Deficiencies were compensated for by adapting soft tissues and using mirror symmetry. The remaining profile part was reconstructed by gra-

štenjem zrcalne simetrije. Preostali dio profila rekonstruiran je postupnim produživanjem postojećih linija i njihovim prilagođavanjem oznakama, kako je prikazano na sl. 3. Korištenjem programa MakeHuman prilagođen je opći oblik lica kako bi odgovarao specifičnim značajkama lubanje. Zbog izraženog prednjeg izdanka grane donje čeljusti (*processus coronoideus*) i manjeg gonijalnog kuta opći oblik lica je preoblikovan kako bi odgovarao širem i robusnijem izgledu. Asimetrija čeone kosti uzrokovala je određene poteškoće u rekonstrukciji simetričnog lica. Nos je oblikovan prema karakteristikama kao što su nježnija *glabella*, uzak i produžen kruškasti otvor nosa (*apertura piriformis*) te visok i uzak nosni most i nosni trn (*spina nasalis*), kako bi se postigla željena morfologija. Oblik ušiju rekonstruiran je na temelju izraženih sisastih izdanaka (*processus mastoideus*), što podrazumijeva povećane i šire uške, te njihove izbočene pozicije koja ukazuje na slobodniji položaj ušne školjke. Rekonstrukcija lica može se promatrati i kao umjetnička disciplina za čiju je izradu potrebno iskustvo, ali i stručnost osobe koja ju izvodi. Uz antropološko znanje rijetko tko posjeduje i potrebne umjetničke vještine, stoga je suradnja tih dvaju područja nužna za postizanje najboljih rezultata u rekonstrukciji lica. Dok antropolog pruža anatomske osnovu, umjetnik unosi umjetničku viziju kako bi se stvorio što realističniji prikaz. Međutim, neophodno je održati ravnotežu između znanstvene preciznosti i umjetničke slobode kako bi se izbjegli subjektivni utjecaji na konačni rezultat.

Utjecaj kose na prepoznavanje rekonstruiranog lica predmet je brojnih istraživanja. Iako kosa može značajno utjecati na individualnost, rezultati studije Fernandes (Fernandes et al. 2013) prikazuju da dodavanje kose rekonstrukciji može otežati prepoznavanje. Stoga se u sudskim slučajevima, u odsustvu podataka o kosi, preporučuje izrada rekonstrukcije bez kose kako bi se povećale šanse za uspješnu identifikaciju. Kod računalne metode rekonstrukcije lica ključni izazov predstavlja potvrda valjanosti dobivenih rezultata. Bez pouzdane validacije, čak i najsloženiji algoritmi ne mogu se koristiti u stvarnim istragama. Kao što su Claes i suradnici (2010) istaknuli, funkcionalnost metode nije dovoljna, potrebno je dokazati njezinu pouzdanost i preciznost. U usporedbi s tradicionalnim metodama računalna rekonstrukcija lica nudi brojne prednosti poput smanjenja rizika od oštećenja izvornog

dually extending the existing lines and adjusting them to the markings, as shown in Fig. 3. Using the MakeHuman program, the general shape of the face was adjusted to match the specific characteristics of the skull. Due to the pronounced anterior outgrowth of the branch of the lower jaw (*processus coronoideus*) and the smaller gonial angle, the general shape of the face has been reshaped to correspond to a broader and more robust appearance. The asymmetry of the frontal bone caused specific difficulties in reconstructing a symmetrical face. The nose is shaped according to characteristics such as a softer *glabella*, a narrow and elongated pear-shaped nasal opening (*apertura piriformis*) and a high and narrow nasal bridge and nasal spine (*spina nasalis*) to achieve the desired morphology. The ear's shape was reconstructed based on pronounced mammary processes (*processus mastoideus*), which implies enlarged and wider ears, and their protruding position, which indicates a more complementary position of the auricle. Facial reconstruction can also be seen as an artistic discipline, the creation of which requires experience and the expertise of the person performing it. In addition to anthropological knowledge, only some people possess artistic skills, so the cooperation of these two areas is necessary to achieve the best results in facial reconstruction. While the anthropologist provides the anatomical basis, the artist brings an artistic vision to create the most realistic representation possible. However, it is necessary to balance scientific precision and artistic freedom, a delicate task that requires careful consideration to avoid subjective influences on the final result.

The influence of hair on recognising a reconstructed face is the subject of numerous studies. Although hair can significantly affect individuality, the results of the Fernandes study (Fernandes et al. 2013) show that adding hair to the reconstruction can make recognition more difficult. Therefore, in court cases, in the absence of hair data, it is recommended to reconstruct without hair to increase the chances of a successful identification. With the computer method of facial reconstruction, the key challenge is the confirmation of the validity of the obtained results. Even the most complex algorithms can only be used in actual investigations with reliable validation, underscoring the crucial role of this step in the process. As Claes pointed out, more than the method's functionality is needed; it is necessary to prove its reliability and precision (Claes et al. 2010). Compared to traditional methods, computer face reconstruction offers numerous advantages,



materijala te smanjenog utrošenog vremena i troškova izrade. Digitalne tehnike omogućuju stvaranje više verzija rekonstrukcije na temelju istog skupa podataka, čime se smanjuje utjecaj subjektivnosti pojedinog kipara (Davy et al. 2005). Unatoč tome, i dalje postoji potreba za razvojem objektivnih metoda za procjenu točnosti i pouzdanosti računalnih rekonstrukcija.

## ZAKLJUČAK

Izvedena je računalna 3D facijalna rekonstrukcija mekih tkiva lica prema u potpunosti očuvanoj lubanji s donjom čeljusti broj 9. Ostatci žrtve ekshumirani su iz masovne grobnice u Gračanima, na mikrolokaciji Peščenka na sjevernim padinama grada Zagreba. Vrijeme smrti osobe nije moguće utvrditi, okvirni raspon je završetak Drugog svjetskog rata i početak poslijeratnog razdoblja. U masovnoj grobnici su, osim dijela kostura osobe, otkriveni koštani ostatci devedeset pet osoba, čije su oštećene lubanje većim dijelom ukazivale na način usmrćivanja i utjecaj tafonomskih procesa.

Provedena je makromorfološka antropološka analiza, kako bi se utvrdio osnovni biološki profil osobe. Prema bodovanju četrnaest spolnih znakova utvrđen je muški spol osobe tipa *masculinum*, stupnja seksualizacije + 1,28. Procijenjeni raspon starosti osobe u trenutku smrti iznosi od dvadeset pet do trideset godina. Utvrđeno je nekoliko anomalija, pojava meziodensa između prva dva sjekutića na gornjoj čeljusti te metopični šav na čeonj kosti i prekobrojna šavna kost (*os inca*) klasičnog trokutastog oblika.

Istaknuta je prednost upotrebe objektivnije metode 3D računalne tehnologije naspram klasične metode facijalne rekonstrukcije. Opisanim metodom brže se dobivaju rezultati, a prepravljavanje i dopunjavanje modela je jednostavnije bez oštećenja uzorka lubanje. Uslijed mogućnosti točnijeg mjerenja, primjerice upotrebom slikovne radiološke metode, računalne tomografije (CT), 3D laserskih skenera, povećava se mogućnost postizanja veće sličnosti lica sa stvarnom osobom. Navedeni su nedostaci ove metode, poput problema pri oblikovanju uški i usana. Poseban problem, koji postoji kod klasične i računalne metode facijalne rekonstrukcije je utvrđivanje odnosa između oblika lubanje i mekih tkiva lica, odno-

such as reducing the risk of damage to the original material and reducing the time spent and production costs. Digital techniques make it possible to create multiple versions of the reconstruction based on the same data set, thus reducing the influence of individual sculptor's subjectivity (Davy et al. 2005). Despite this, there is still a need to develop objective methods for assessing the accuracy and reliability of computer reconstructions.

## CONCLUSION

A computerized 3D facial reconstruction of the soft tissues of the face was performed according to the fully preserved skull with lower jaw number 9. The remains of the victim were exhumed from a mass grave in Gračani, at the Peščenko microlocation, on the northern slopes of Zagreb. The time of the person's death cannot be determined; the approximate range is the end of the Second World War and the beginning of the post-war period. In the mass grave, in addition to a part of a person's skeleton, the bone remains of twenty-five people were discovered, whose damaged skulls mainly indicated the execution method and the influence of taphonomic processes.

A macromorphological anthropological analysis was carried out to determine a person's basic biological profile. According to the fourteen sexual signs scoring, the sex of a person was a male of the masculine, non-robust type with a degree of sexualization + 1.28 was determined. The estimated age range of a person at the time of death is from twenty-five to thirty years. Several anomalies were identified: the appearance of mesiodens between the first two incisors on the upper jaw, a metopic suture on the frontal bone and a supernumerary suture bone (*os inca*) of the classic triangular shape.

The advantage of using a more objective method of 3D computer technology compared to the classic facial reconstruction method is highlighted. With the described method, results are obtained faster, and it is more straightforward to modify and supplement the model without damaging the skull sample. Due to the possibility of more accurate measurements, for example, using radiological imaging methods and computed tomography (CT) 3D laser scanners increase the possibility of achieving a more remarkable of the face with the real person. Disadvantages of this method are listed, such as problems with shaping ears and lips. A noteworthy problem that exists with classical and computerized methods of facial reconstruction is determining the relationship between the shape of the skull and the soft tissues of

sno njihove dubine uslijed velike promjenjivosti u strukturi mišića, pogotovo onih koji se ne pričvršćuju izravno na kosti lubanje. Razvojem tehnologije, metode i programskih podrški, postići će se veća točnost izvedbe.

Istaknute su prednosti upotrebe metode u forenzičnim istraživanjima i općenito u antropološkim studijama. Upravo bi u istraživanjima masovnih grobnica, u kojima su česti slučajevi izmiješanih koštanih elemenata uvelike pomogla upotreba ove metode, pogotovo ako niti jedna druga metoda niti tehnika nisu dale odgovarajući rezultat. Rezultat, približni izgled osobe potom se može usporediti s bazama podataka o nestalim osobama, ukoliko postoje, ili se provodi strategija javnog oglašavanja. U antropološkim i arheološkim istraživanjima, često kao izložak u postavu muzeja, facijalna rekonstrukcija koristi se za otkrivanja lica iz prošlosti.

## Zahvale

Autori zahvaljuju profesoru Tomislavu Staroveškom, koji je proveo skeniranje lubanje s 3D laserskim skenerom na Zavodu za tehnologiju i Katedri za alatne strojeve Fakulteta strojarstva i brodogradnje Sveučilišta u Zagrebu.

the face, i.e. their depth due to the significant variability in the structure of the muscles, especially those that are not attached directly to the bones of the skull. With the development of technology, methods and program support, greater performance accuracy will be achieved.

The unique advantages of employing this method in forensic research and anthropological studies are underscored. Particularly in the investigation of mass graves, where the presence of commingled bone elements is a common challenge, this method stands out as a valuable tool, especially when other methods or techniques have not yielded satisfactory results. The outcome, an approximate depiction of the individual, can then be cross-referenced with databases of missing persons, if available, or a public outreach campaign can be initiated. In anthropological and archaeological research, it is often showcased in museums because facial reconstruction is a captivating means to unveil the faces from the past.

## Acknowledgements

The authors thank Professor Tomislav Staroveški, who performed the 3D skull scanning at the Institute of Technology and the Department of Machine Tools, Faculty of Mechanical Engineering and Naval Architecture, University of Zagreb.

**Prijevod** Translation **ZDRAVKA HINCAK DARIS**  
**Lektura** Proofreading **MARKO MARAS**



## INTERNETSKI IZVORI INTERNET SOURCES

- American Academy of Forensic Sciences (AAFS).** 2020, *Best Practice Recommendation for Facial Approximation in Forensic Anthropology*. <https://www.aafs.org/asb-standard/best-practice-recommendation-facial-approximation-forensic-anthropology>
- Blender – Community, B.O.,** 2018. *Blender – a 3D modelling and rendering package*, Stichting Blender Foundation, Amsterdam (Blender Foundation®, Ton Roosendaal), <http://www.blender.org>
- Chakravorty, D.** 2019, *STL File Format (3D Printing) – Simply Explained*. URL: <https://all3dp.com/what-is-stl-file-format-extension-3d-printing/#pointthree>
- Interpol 2023 – International Police Organization. 2023, Interpol Disaster Victim Identification Guide, Annexure 8 – Methods of identification. URL: <https://www.interpol.int/en/How-we-work/Forensics/Disaster-Victim-Identification-DVI>
- MakeHuman – MakeHuman Team®, <https://static.makehumancommunity.org/>
- OrtogOnBlender** – Cícero Moraes, dr. Everton da Rosa, dr. Rodrigo Dornelles, [https://www.cicermoraes.com.br/doc/pt\\_br/OrtogOnBlender/index.html](https://www.cicermoraes.com.br/doc/pt_br/OrtogOnBlender/index.html)

## IZVORI SOURCES

- MHB 2018** – Ministarstvo hrvatskih branitelja, Uprava za zatočene i nestale: Izveštje o provedenoj aktivnosti 14-GZ-2SR-18 (6.5.2018.), Zagreb.
- MHB 2019** – Ministarstvo hrvatskih branitelja, Uprava za zatočene i nestale: 14-GZ-2SR-18 Zapisnik o obradi (11.08.2019.) Zagreb.

## LITERATURA BIBLIOGRAPHY

- Acsádi, Gy., Nemeskéri, J.** 1970, *History of human life span and mortality*, Akadémiai Kiadó, Budapest.
- Alberti, G, Mondani, P. M., Parodi, V.** 2006, Eruption of supernumerary permanent teeth in a sample of urban primary school population in Genoa, Italy, *European Journal of Paediatric Dentistry*, Vol. 7(2), 89–92.
- Banić, M., Bašić, Ž., Anđelinović, Š.** 2017, Vrednovanje morfoloških metoda za određivanje spola na lubanji, *Policija i sigurnost*, Vol. 26(1), 1–19.
- Beauthier, J. P., Lefevre, P., Meunier, M., Orban, R., Polet, C., Werquin, P., Quatrehomme, G.** 2010, Palatine sutures as age indicator: a controlled study in the elderly, *Journal of Forensic Sciences*, Vol. 55(1), 153–158. <https://doi.org/10.1111/j.1556-4029.2009.01237.x>
- Bender, R., Margaritoni, M.** 2015, Antropometrijske karakteristike šake / Anthropometric characteristics of the hand, *Sestrinski glasnik*, Vol. 20(1), 53–59. <https://doi.org/10.11608/sgnj.2015.20.011>
- Berry, A. C.** 1975, Factors affecting the incidence of nonmetric skeletal variants, *Journal of Anatomy*, Vol. 120(3), 519–535.
- Bowen, S. M.** 2022, Man vs. Machine: Facial Recognition Technology Replacing Eyewitness Identifications, *Lincoln Memorial University Law Review*, Vol. 10(1), 21–69.
- Brothwell, D. R.** 1981, *Digging Up Bones*, Cornell University Press, Ithaca.
- Bruce, V., Young, A.** 1986, Understanding face recognition, *British Journal of Psychology*, Vol. 77(3), 305–327. <https://doi.org/10.1111/j.2044-8295.1986.tb02199.x>
- Buikstra, J. E., Ubelaker, D. H.** (eds.) 1994, *Standards for Data Collection from Human Skeletal Remains*, Research Seminar Series 44, Arkansas Archaeological Survey, Fayetteville.
- Claes, P., Vandermeulen, D., De Greef, S., Willems, G., Clement, J. G., Suetens, P.** 2010, Computerized craniofacial reconstruction: conceptual framework and review, *Forensic Science International*, Vol. 201(1–3), 138–145. <https://doi.org/10.1016/j.forsciint.2010.03.008>
- Clement, J. G., Marks, M. K.** 2005, *Computer-Graphic Facial Reconstruction*, Elsevier Academic Press, Boston – Heidelberg.
- Ćirić, I.** 2019, Forenzična rekonstrukcija mekih tkiva lica pomoću kraniofacijalne antropometrije i 3D računalnih metoda, Unpublished MA Thesis, Sveučilište u Zagrebu, Zagreb.
- Das, S., Suri, R., Kapur, V.** 2005, Anatomical observations on *os inca* and associated cranial deformities, *Folia Morphologica*, Vol. 64(2), 118–121.
- Davy, S., Gilbert, T., Schofield, D., Evison, M.** 2005, Forensic facial reconstruction using computer modeling software, in: *Computer-Graphic Facial Reconstruction*, Clement J., Marks M. (eds.), Elsevier Academic Press, Boston – Heidelberg, 183–196.
- De Greef, S., Claes, P., Vandermeulen, D., Mollemans, W., Suetens, P., Willems, G.** 2006, Large-scale in-vivo Caucasian facial soft tissue thickness database for craniofacial reconstruction, *Forensic Science International*, Vol. 159 (Supplement), 126–146. <https://doi.org/10.1016/j.forsciint.2006.02.034>
- Ferembach, D., Schwidetzky, I., Stloukal, M.** 1980, Recommendations for age and sex diagnoses of skeletons, Workshop of European anthropologists, *Journal of Human Evolution*, Vol. 9(7), 517–549. [https://doi.org/10.1016/0047-2484\(80\)90061-5](https://doi.org/10.1016/0047-2484(80)90061-5)
- Fernandes, C. M. S., Alencar de Sena Pereira, F. D., Lopes da Silva, J. V., da Costa Serra, M.** 2013, Is characterizing the digital forensic facial reconstruction with hair necessary? A familiar assessors' analysis, *Forensic Science International*, Vol. 229(1–3), 164.e1–164.e5. <https://doi.org/10.1016/j.forsciint.2013.03.036>
- Герасимов, М. М.** 1955, *Восстановление лица по черепу*, Издательство Академии Наук СССР, Москва. [Gerasimov, M. M. 1955, *Vosstanovlenie lica po cerepu*, Akademii Nauk SSSR, Moskva.]
- Guleria, A., Krishan, K., Sharma, V., Kanchan, T.** 2023, Methods of forensic facial reconstruction and human identification: historical background, significance, and limitations, *The Science of Nature*, Vol. 110(2), 8. <https://doi.org/10.1007/s00114-023-01838-9>
- Gupta, S., Gupta, V., Vij, H., Vij, R., Tyagi, N.** 2015, Forensic facial reconstruction: The final frontier, *Journal of clinical and diagnostic research*, Vol. 9(9), ZE26–ZE28. <https://doi.org/10.7860/jcdr/2015/14621.6568>

- Hanihara T., Ishida H.** 2001, Os incae: variation in frequency in major human population groups. *Journal of Anatomy*, 198:137-152.
- Hauser G., De Stefano G. F.** 1989, *Epigenetic Variants of the Human Skull*, Schweizerbart'sche Verlagsbuchhandlung, Stuttgart.
- Haviland, W. A.** 2004, *Kulturna antropologija*, Naklada Slap, Jastrebarsko.
- Hincak Daris, Z.** 2024, *Uvod u biološku antropologiju*, Edizioni del Faro, Trento.
- Işcan, M. Y., Steyn, M.** 2013, The human skeleton in forensic medicine, 3<sup>rd</sup> ed., Charles C. Thomas Publisher Ltd., Springfield (IL).
- Jurmain, R., Kilgore, L., Trevathan, W. Ciochon, R., Bartelink, E.** 2017, *Introduction to Physical Anthropology*, 15<sup>th</sup> ed, Cengage Learning Inc., Boston.
- Kadanoff, D., Mutafov, S.** 1968, Über die Variationen der typisch lokalisierten überzahligen Knochen und Knochenfortsätze des Hirnschädles beim Menschen, *Anthropologischer Anzeiger*, Vol. 31(1-2), 28–39.
- Khandare, S. V., Bhise, S. S., Shinde, A. B.** 2015, Age estimation from cranial sutures – a postmortem study, *International Journal of Healthcare and Biomedical Research*, Vol. 3(3), 192–202. – problematičan rad, ne izgleda pravi, ne može mu se ući u trag jer u časopisu koji navodi + vol./issue ne postoji (iako je citiran preko 20 puta!)
- Klepinger, L.** 2006, *Fundamentals of Forensic Anthropology*, John Wiley & Sons Inc., Illinois.
- Kreutz, K., Verhoff, M. A.** 2007, Forensic Facial Reconstruction-Identification based on skeletal finding, *Deutsches Ärzteblatt international*, Vol. 104(17), A1160–1165.
- Krmpotić-Nemanić, J., Marušić, A.** 2007, *Anatomija čovjeka*, Medicinska naklada, Zagreb.
- Krogman, W. M.** 1939, Facing facts of face growth, *American Journal of Orthodontics and Oral Surgery*, Vol. 25(8), 724–731.
- Krogman, W. M.** 1986, *The Human Skeleton in Forensic Medicine*, Charles C. Thomas Publisher Ltd., Springfield (IL).
- Krogman, W. M., Işcan, M. Y.** 1986, *The Human skeleton in Forensic Medicine*, 2nd edition, Charles C. Thomas Publisher Ltd., Springfield (IL).
- Lebedinskaya, G. U., Balueva, T. S., Veselovskaya, E. B.** 1993, Development of methodological principles for reconstruction of the face on the basis of skull material, in: *Forensic analysis of the Skull*, Işcan M. Y., Helmer R. P. (eds.), Wiley-Liss Inc., New York, 183–198.
- Lee, W. J., Wilkinson, C. M., Hwang, H.** 2012, An Accuracy assessment of forensic computerized facial reconstruction employing cone-beam computed tomography from live subjects, *Journal of Forensic Sciences*, Vol. 57(2), 318–27.
- Mann, R. W., Symes, S. A., Bass, W. M.** 1987, Maxillary suture obliteration: aging the human skeleton based on intact or fragmentary maxilla, *Journal of Forensic Sciences*, Vol. 32(1), 148–157.
- Mann, R. W.** 1987, *Maxillary suture obliteration: A method for estimating skeletal age*, Unpublished MA Thesis, University of Tennessee, Knoxville.
- Mann, R. W., Jantz, R. L., Bass, W. M., Willey, P. S.** 1991, Maxillary suture obliteration: a visual method for estimating skeletal age, *Journal of Forensic Sciences*, Vol. 36(3), 781–791.
- Mann, R. W., Hunt, D. R.** 2005, *Photographic Regional Atlas of Bone Disease: A Guide to Pathologic and Normal Variation in the Human Skeleton*, Charles C. Thomas Publisher Ltd., Springfield (IL).
- Martin, R., Saller, K.** 1957, *Lehrbuch der Anthropologie: in systematischer darstellung mit besonderer berücksichtigung der Anthropologischen Methoden*, Gustav Fischer Verlag, Stuttgart.
- Matsumura, G., Uchiumi, T., Kida, K., Ichikawa, R., Kodama, G.** 1993, Developmental studies on the interparietal part of the human occipital squama, *Journal of Anatomy*, Vol. 182(2), 197–204.
- Meighani, G., Pakdaman, A.** 2010, Diagnosis and Management of Supranumerary (Mesiodens): A Review of the Literature, *Journal of Dentistry (Teheran)*, Vol. 7(1), 41–49.
- Moraes, C., Dias, P., Melani, R.** 2014, Demonstration of protocol for computer-aided forensic facial reconstruction with free software and photogrammetry, *Journal of Research in Dentistry*, Vol. 2(1), 77–90.
- Moraes, C., Miamoto, P.** 2015, *Manual de Reconstrução Facial 3D Digital. Aplicações com Código Aberto e Software Livre*, Sinop-MT: EXPRESSÃO GRÁFICA, Brasil.
- Nawrocki, S. P.** 1998, Regression formulae for estimating age at death from cranial suture closure, in: *Forensic Osteology: Advances in Identification of Human Remains*, Reichs K. J. (ed.), Charles C. Thomas Publisher Ltd., Springfield (IL), 276–292.
- Ossenberg, N. S.** 1969, *Discontinuous morphological variation in the human cranium*, Unpublished PhD Thesis, University of Toronto, Toronto.
- Petaros, A., Mikulka, A., Baković, M., Definis-Gojanić, M., Stemberga, V.** 2021, Investigation of WWII/postwar mass burials in Croatia—The implementation of the Croatian model of searching for the imprisoned and missing persons, *Forensic Science International*, Vol. 318, 110609. <https://doi.org/10.1016/j.forsciint.2020.110609>
- Prag, J., Neave, R. A. H.** 1997, *Making Faces*, British Museum Press, London.
- Qamara, Ch. R., Bajwab, J. I., Rahbarc, M. I.** 2013, Mesiodens – etiology, prevalence, diagnosis and management, *Pakistan Orthodontic Journal*, Vol. 5(2), 73–76.
- Quatrehomme, G.** 1997, A fully three-dimensional method for facial reconstruction based on deformable models, *Journal of Forensic Science*, Vol. 42(4), 649–652. – citirano
- Rhine, S.** 1990, Non – metric skull racing, in: *Skeletal Attribution to Race*, Gill G. W., Rhine S. (eds.), Anthropological Papers No. 4, Maxwell Museum of Anthropology, University of New Mexico, 9–20.
- Sauer, N. J., Michael, A. R., Fenton, T. W.** 2012, Human identification using skull-photo superimposition and forensic image comparison, in: *A companion to forensic anthropology*, Dirkmaat D. (ed.), Wiley Blackwell Publishing, Oxford, 432–446.

- Short, L.J., Khambay, B., Ayoub, A., Erolin, C., Rynn, C., Wilkinson, C.** 2014, Validation of a computer modelled forensic facial reconstruction technique using CT data from live subjects: a pilot study, *Forensic Science International*, Vol. 237, 147.e1–147.e8.  
<https://doi.org/10.1016/j.forsciint.2013.12.042>
- Subsol, G., Quatrehomme, G.** 2005, Automatic 3D facial reconstruction by feature-based registration of a reference head, in: *Computer-Graphic Facial Reconstruction*, Clement J. G., Marks M. K. (eds.), Elsevier – Academic Press, Burlington, 79–101.
- Šutalo, J., Mervar, M., Petolas, D.** 1994, *Patologija i terapija tvrdih zubnih tkiva*, Naklada Zadro, Zagreb.
- Torgersen, J.** 1951, Hereditary Factors in the Sutural Pattern of the Skull, *Acta Radiologica (Stockholm)*, Vol. 36(5), 374–382.  
<https://doi.org/10.3109/00016925109176987>
- Van Buggenhout, G., Bailleul-Forestier, I.** 2008, Mesiodens, *European journal of medical genetics*, Vol. 51(2), 178–181.
- Vanezis, M., Vanezis, P.** 2000, Cranio-facial reconstruction in forensic identification—historical development and a review of current practice, *Medicine, Science and the Law*, Vol. 40(3), 197–205.
- Verzé, L.** 2009, History of facial reconstruction, *Acta Biomedica*, Vol. 80(1), 5–12.
- Wilkinson, C.** 2004, *Forensic Facial Reconstruction*, Cambridge University Press, Cambridge.
- Zdilla, M. J., Russell, M. L., Koons, A. W., Bliss, K. N., Mangus, K. R.** 2018, Metopism: a study of the persistent metopic suture, *Journal of Craniofacial Surgery*, Vol. 29(1), 204–208.