

Case report



Pyometra in Croatian cats - a rare cause of death, with the first report of concurrent pyometra and pneumonia in a cat

Doroteja Huber, Lidija Medven Zagradišnik*, Ivana Mihoković Buhin, Ivan-Conrado Šoštarić-Zuckermann, Andrea Gudan Kurilj, Marko Hohšteter and Branka Artuković

Department of Veterinary Pathology, Faculty of Veterinary Medicine, University of Zagreb, Zagreb, Croatia

HUBER, D., L. MEDVEN ZAGRADIŠNIK, I. MIHOKOVIĆ BUHIN, I.-C. ŠOŠTARIĆ-ZUCKERMANN, A. GUDAN KURILJ, M. HOHŠTETER, B. ARTUKOVIĆ: Pyometra in Croatian cats - a rare cause of death, with the first report of concurrent pyometra and pneumonia in a cat. *Vet. arhiv* 95, 113-120, 2025.

ABSTRACT

Pyometra is a severe infection of the uterus with accumulation of pus within the uterine lumen, and is a relevant clinical problem that can be lethal. Mortality of cats from pyometra has rarely been investigated in the world, and there is no such research from Croatia. The aim of the study was to perform retrospective pathological research on pyometra-deceased cats from Croatia. Further, the study describes concurrent pyometra and pneumonia causing death in a single cat, which has, to the authors' knowledge, not been reported before. The study included cats that died from pyometra from 2009 to 2022. The necropsy reports and histological slides of these cats were reviewed. From the investigated population of 2152 deceased cats, including 908 female cats, four cats died due to pyometra, corresponding to mortality of 0.19% (of the entire investigated population), and 0.44% (of the population of female cats). All the cats were non-pedigree, with an average age of 10.2 years. Apart from pyometra, a one-year-old cat was affected by pyothorax and multifocal to coalescing abscesses in the uterine wall and left lung, with intra-lesional Gram-positive cocci. The current study reports low mortality from pyometra, mostly affecting older cats, which corresponds to the literature data. The study also reports the first case of pyometra and pneumonia caused by Gram-positive bacteria as the coinciding causes of the death in a single cat, which differs from the literature data stating that the most frequent cause of feline pyometra is the Gram-negative *Escherichia coli*. This study presents valuable information for future disease prevention, health preservation, and the welfare of cats, while also demonstrating that uncommon bacteria may cause pyometra, and may affect organs other than the uterus.

Key words: pyometra; cat; pneumonia; pathology; necropsy; histology

* Corresponding author:

Assist. Prof. Lidija Medven Zagradišnik, PhD, DVM, Univ. Mag. Med. Vet., Department of Veterinary Pathology, Faculty of Veterinary Medicine, University of Zagreb, Heinzelova 55, 10000 Zagreb, Croatia, phone: +385 1 2390 310, email: lmedven@vef.unizg.hr

Introduction

Pyometra is an acute or chronic suppurative infection of the uterus with accumulation of pus in the uterine lumen (SCHLAFER and FOSTER, 2016). It is an uncommon pathology in cats, with a reported prevalence of 0.4% in adult, free-roaming queens, and 2.2% in intact queens up to the age of 13 years (SCOTT et al., 2002; HOLLINSHEAD and KREKELER, 2016; KACPRZAK et al., 2016; SCHLAFER and FOSTER, 2016; THOREN et al., 2022). However, it is still a relevant clinical problem of female feline patients, as it can lead to loss of breeding potential and, in some cases, can be life-threatening with a lethal outcome (HOLLINSHEAD and KREKELER, 2016). It is mostly a disease of middle-aged or older, nulliparous animals, due to cystic endometrial hyperplasia (NOAKES et al., 2001; HAGMAN et al., 2014; HOLLINSHEAD and KREKELER, 2016; KACPRZAK et al., 2016). However, it can also be encountered in young queens, especially those treated with exogenous steroid hormones, or cats of Oriental breed lineage, such as Sphynx, Siberian, Ocicat, Korat, Siamese, Ragdoll, Maine Coon, and Bengal (NOAKES et al., 2001; HAGMAN et al., 2014; HOLLINSHEAD and KREKELER, 2016; KACPRZAK et al., 2016). Pyometra can also affect spayed cats as it can develop in the uterine stump, especially in cats with ovarian remnant syndrome. Relatively little data have been published on pyometra in queens compared to bitches, and most of the current knowledge on this topic has been extrapolated from studies carried out in bitches. However, as queens and bitches have different reproductive physiology, further research into the disease process and pathology in queens is warranted (HOLLINSHEAD and KREKELER, 2016).

The etiology of pyometra in queens is still not clear, where the disease is caused by bacterial infection of a progesterone-sensitized uterus, although recent studies suggest that estrogen may also be involved (HAGMAN et al., 2014; HOLLINSHEAD and KREKELER, 2016). The most frequent causative agent is *Escherichia coli*, but other bacteria, mostly normal vaginal commensals, such as *Staphylococcus aureus*, *Klebsiella* spp., *Proteus* spp., and *Streptococcus* spp., have also been reported (HOLLINSHEAD and KREKELER, 2016).

Clinical presentation in queens includes anorexia, vomiting, lethargy, weight loss, unkempt appearance, dehydration, pyrexia, and mucopurulent to hemorrhagic vaginal discharge (NAK et al., 2005; HAGMAN et al., 2014; HAYATI et al., 2016; HOLLINSHEAD and KREKELER, 2016; SCHLAFER and FOSTER, 2016; FOSTER and PREMANANDAN, 2022). Vaginal discharge might be absent as a consequence of the careful cleaning habits of queens, or in cases of closed-cervix pyometra (NAK et al., 2005; HOLLINSHEAD and KREKELER, 2016). Abdominal distention may or may not be present (NAK et al., 2005; FOSTER and PREMANANDAN, 2022). During clinical examination, the enlarged uterus may be palpated through the abdominal wall, although in obese queens this might be difficult (HOLLINSHEAD and KREKELER, 2016). Also, care should be taken during abdominal palpation, as the friable uterus might rupture, especially in cases of closed-cervix pyometra (HOLLINSHEAD and KREKELER, 2016). In open-cervix pyometra, the uterus might not be enlarged, and only the thickened uterine wall may be appreciated on palpation (HOLLINSHEAD and KREKELER, 2016). Laboratory findings are nonspecific and few, including neutrophilia with left shift, hyperproteinemia, hypokalemia, azotemia, as well as elevated liver enzymes, blood urea and creatinine, but the results might also be within the reference numbers (HOLLINSHEAD and KREKELER, 2016). Progesterone concentration is usually elevated, but might also be low (HOLLINSHEAD and KREKELER, 2016). Cytological examination of the vaginal discharge usually reveals degenerated neutrophils and phagocytosed bacteria (HOLLINSHEAD and KREKELER, 2016). Abdominal radiography can show a distended uterus with displacement of adjacent organs, but this finding cannot be differentiated from other causes of uterine enlargement, such as early pregnancy prior to skeletal ossification, mucometra, hydrometra, hemometra, and uterine tumors (HOLLINSHEAD and KREKELER, 2016). Abdominal ultrasound is the most important diagnostic tool for pyometra, and may reveal a fluid-filled uterus, with a thick-

ened wall (NAK et al., 2005; HOLLINSHEAD and KREKELER, 2016).

The reported fatality due to pyometra, that is, the proportion of cats that die due to pyometra among all the individuals diagnosed with this disease, has only been reported in few studies and amounts to 4.4% - 8%, (KENNEY et al., 1987; HAGMAN et al., 2014; THOREN et al., 2022). The mortality, i.e. the percentage of cats that die because of pyometra within a defined, investigated cat population, has been reported in only two studies (WITHOEFT et al., 2019; KENT et al., 2022). The reported mortality was 0.10 and 0.46% in the whole cat population, and 0.21 and 1.18% in populations of female cats from the USA and Brazil (WITHOEFT et al., 2019; KENT et al., 2022).

Pyometra accompanied by additional pathologies in the uterus or in other organs is rarely encountered. Few papers report pathologies concurrent with pyometra, such as septic pericarditis (MAJOY et al., 2013), pregnancy and fetal mummification (BONECKA et al., 2017), and calcification of the uterus (HAYATI et al., 2016). To the authors' knowledge, pyometra accompanied by purulent pneumonia as a cause of death has not been reported before.

Due to the scarce data on mortality from pyometra and the lack of studies on feline pyometra in Croatia, this retrospective study was performed with the aim of describing the mortality and pathological findings in cats affected by lethal pyometra. We also report in great detail the first case of pyometra and pneumonia which concurrently led to the demise of a single cat.

Materials and methods

The study included all cats necropsied at the Department of Veterinary Pathology, Faculty of Veteri-

nary Medicine, University of Zagreb, from 1.1.2009 to 31.12.2022 that were diagnosed with pyometra during necropsy. This criterion was met by four cats, which were included in the study. The necropsy report of these cats was reviewed. Data on breed, age, and cause of demise were collected. In one cat, histological slides were available and were re-examined. The histological slides from this cat included representative parts of the uterus, myocardium, lungs, liver, spleen, and kidney which were sampled at the time of necropsy and fixed in 10% buffered, neutral formalin for 24 h, routinely dehydrated, embedded in paraffin, cut to a thickness of 5 μ m, and stained with hematoxylin and eosin (HE). Slides of the uterus and lungs, with microscopically visible bacterial colonies, were additionally stained with Gram stain. After staining, the histological slides were analyzed with a Digicyte DX50 light microscope (Digicyte digitalne tehnologije d.o.o., Zagreb, Croatia), using objective magnification from 4x to 40x. Microphotographs were taken using a BigEye Camera (Digicyte digitalne tehnologije d.o.o., Zagreb, Croatia) and Digicyte Capture software (Digicyte digitalne tehnologije d.o.o., Zagreb, Croatia) using lens magnification of 10x to 100x.

Results

In the period in question, 2152 cats were dissected, of which 908 were female, and of these four cats were diagnosed with pyometra (Table 1). All four cats died because of pyometra, corresponding to mortality of 0.19% in the whole investigated population, and 0.44% when considering only female cats. All the cats were non-pedigree (100%), with a mean age of 10.2 years (range 1 – 18 years).

Pathological findings from the necropsy of all these cats included a distended uterus filled with pu-

Table 1. Cats diagnosed with pyometra at necropsy

Case number	Breed	Age (years)	Cause of death
1.	Non-pedigree	18	pyometra
2.	Non-pedigree	10	pyometra, sepsis
3.	Non-pedigree	12	pyometra
4.	Non-pedigree	1	pyometra, pneumonia, sepsis

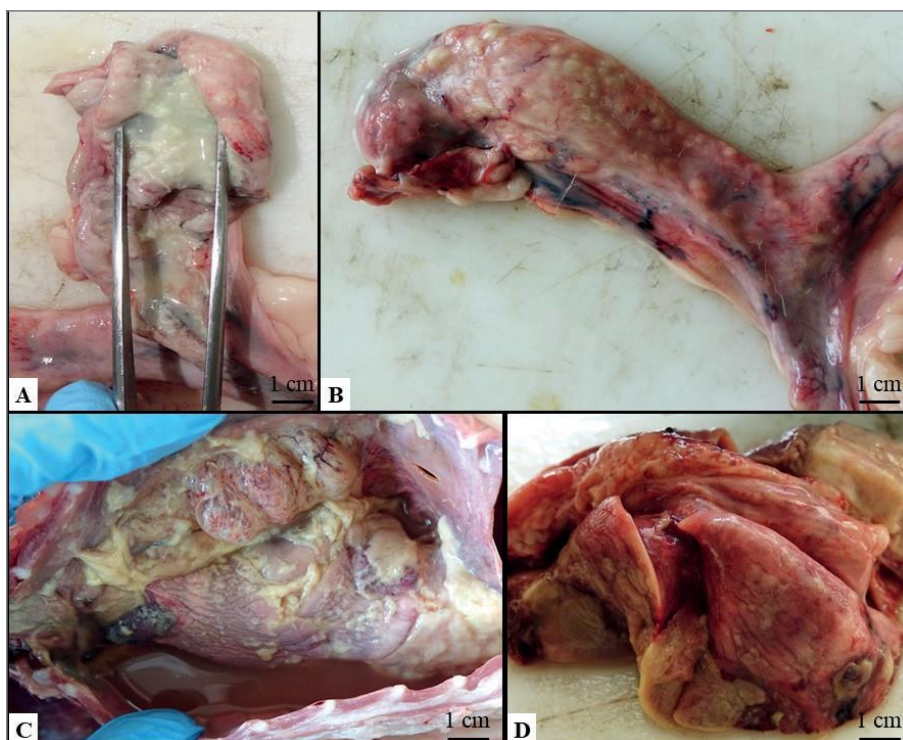


Fig. 1. A. The endometrial surface of the right uterine horn is covered by a thick, yellow, mucopurulent exudate, case 4. B. Multifocal to coalescing abscesses in the wall of the left uterine horn, case 4. C. The thoracic cavity is filled with 100 ml of purulent exudate. Additionally, the pleura costalis, pleura pulmonalis, and pericardium are reddened (hyperemia) and covered by pus, case 4. D. The lung lobes on the left side are mildly enlarged, with multiple to coalescing abscesses within the parenchyma, case 4.

ulent exudate. The content of the uterine lumen was described in two cats (cases 3 and 4); in both cats it was thick, creamy, and yellow corresponding to mucopurulent exudate (Fig. 1A). In a one-year-old cat (case 4), the uterus also showed multifocal to coalescing, yellow nodules, filled with the same content as the uterine lumen, corresponding to abscesses (Fig. 1B). The thoracic cavity of the cat was filled with 100 ml of red-yellow, moderately viscous and thick content, corresponding to pyothorax (Fig. 1C), while the serous membranes of the thoracic cavity (including the pleura costalis, pleura pulmonalis, and pericardium) were covered in thick, yellow, viscous content corresponding to pus (Fig. 1C and 1D). The ventral parts of the left lung lobes were mildly enlarged, with irregular, multiple to coalescing areas of harder consistency, filled with pus, corresponding to abscesses (Fig. 1D). Other gross findings included non-congestive enlargement of the spleen

and friable myocardium. Other organs did not show any gross lesions. Histological findings from the uterus included acute to subacute, diffuse, necrotic endometritis, and pyometra (Fig. 2A) with a strong suppurative inflammatory response (Fig. 2A-D), and innumerable, round, intralesional Gram-positive, 1 to 2 μm bacteria (Fig. 2B). The inflammatory response was composed of mostly degenerate neutrophils, with a small number of non-degenerate neutrophils and single macrophages showing signs of phagocytosis. Within the uterine wall, including the endometrium and the myometrium, there were multifocal to coalescing abscesses filled with necrotic debris, neutrophils, and the innumerable bacteria already mentioned (Fig. 2C). Due to the severe necrosis, evaluation of the endometrium regarding cystic endometrial hyperplasia was not possible. The lungs were affected by acute to subacute, multifocal to coalescing, purulent and necrotic pneumonia

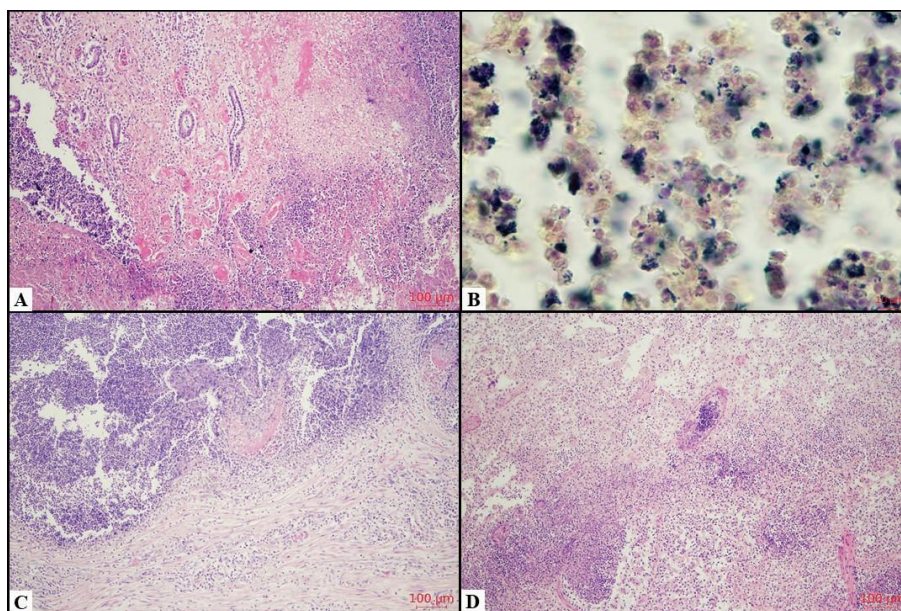


Fig. 2. Case 4, histology. 2. A. Necrotic and purulent endometritis, with dense infiltration of neutrophils on and under the surface of the endometrium. HE, objective magnification 10x. B. Numerous Gram-positive round cocci in the purulent content of the uterus. Gram stain, 100x. C. Abscess within the myometrium. HE, 10x. D. Necrotic and purulent pneumonia. HE, 10x.

(Fig. 2D), with innumerable Gram-positive bacteria, which corresponded to the bacteria seen in the uterus. The inflammatory response was severe and composed of the same cell population as in the uterus, with a slightly larger number of macrophages, which were mostly located within the alveoli. Many blood vessels in the lungs were filled with neutrophils and bacteria. The pleura and the intercostal muscles were affected by purulent bacterial inflammation. The spleen showed severe histiocytosis of the red pulp, reactive hyperplasia of the white pulp, and numerous bacterial colonies within the parenchyma. Multifocal bacterial colonies and a mild neutrophilic perivascular infiltrate were seen in the kidneys, myocardium, and liver. Due to lack of evidence of trauma, the absence of a foreign body, and the lack of infection elsewhere in the body, the cause of death was determined as sepsis due to pyometra and concurrent bacterial pneumonia. As morphology of the lesion and the bacteria in all investigated organs were similar, it was presumed that the pneumonia and pyometra were interconnected, and probably caused by the same pathogen, which disseminated from one of those organs to the other. The point of

entry was presumed to be either ascension from the urogenital tract, with hematogenous spreading to the lungs, or inhalation, with hematogenous spread to the uterus.

Discussion

Pyometra is a life-threatening, pus-accumulating infection of the uterus with a potentially lethal outcome. This disease is a relevant clinical problem, but is not often seen in the necropsy room, as demonstrated by our results. Our study reported low mortality (0.19% in the whole population and 0.44% in the population of female cats) which corresponds to the reported mortality of 0.10 and 0.46% in the whole population, and 0.21 and 1.18% in the population of female cats from the USA and Brazil (WITHOEFT et al., 2019; KENT et al., 2022). The low mortality may be a consequence of spaying, as spaying of young cats, before the first heat, is a common practice in Croatia. Further, the spaying of cats before the first heat is protective for pyometra (HOLLINSHEAD and KREKELER, 2016; SCHLAFER and FOSTER, 2016). However, exact data on the

number of spayed animals which were dissected in the study was not available. In the study from the USA, the vast majority of female cats was spayed (87.56%), which makes the low mortality due to pyometra understandable (KENT et al., 2022).

The median age of the cats affected by pyometra in the current study was 10.25 years, which is slightly higher than the reported age in the literature. The literature reports an average age of 4-7.2 years, with a marked increase in cats older than 7 years (KENNEY et al., 1987; NAK et al., 2005; DONG et al., 2013; HAGMAN et al., 2014; HOLLINSHEAD and KREKELER, 2016; KACPRZAK et al., 2016). The difference in average age between studies can be explained by clear differences in breed and age in the investigated cat populations, but also in the investigated cat populations themselves. Namely, this research also included cats that did not die due to pyometra, while the current study only included cats that died of pyometra. Nevertheless, the results of the current study and literature data both suggest that pyometra is more frequently encountered in older cats, either as a disease (KENNEY et al., 1987; NAK et al., 2005; DONG et al., 2013; HAGMAN et al., 2014; HOLLINSHEAD and KREKELER, 2016; KACPRZAK et al., 2016) or the cause of death (the results of the current study).

The Sphynx, Siberian cat, Ocicat, Korat, Siamese, Ragdoll, Maine Coon, and Bengal show a higher risk of developing pyometra than other breeds of cats (HAGMAN et al., 2014). In the current study, all the affected cats were non-pedigree. Due to the low number of cases, conclusions on breed affection and predisposition cannot be made. Further, no cases in pedigree cats might be a consequence of the low mortality due to pyometra leading to the low number of cases available for investigation. Also, the owners of pure-bred cats may bring the animal in the earlier course of the disease for treatment, as most pure-bred cats are indoor cats, and spend a large amount of time with their owners, resulting in earlier detection of symptoms and earlier visits to the clinic. This may lead to treatment in the earlier phases of the disease with the resulting survival of the animal. Further, there may be a low prevalence of pedigree cats in

the general cat population in Croatia. Additionally, many non-pedigree cats in Croatia are outdoor cats where the owners (or caretakers) have no deep insight into the cats' health status, hence treatment may start later during the course of the disease, resulting in a lethal outcome for the affected cat.

Escherichia coli, an opportunistic bacterium that is a normal inhabitant of the genital tract, is the most frequently isolated cause of pyometra in queens (NOAKES et al., 2001; DAVIDSON, 2019). In the current study, only one cat had histological slides available for re-examination, as in the other cats the owners declined further testing. In this one cat, the exudate within the uterus was creamy yellow, with innumerable Gram-positive cocci visible on histology. Gram-positive bacteria have been reported as a possible cause of pyometra in queens, although much less often than Gram-negative bacteria (FOSTER and PREMANANDAN, 2022). As the owners declined microbiological analyses, the causative agent in the cat was not definitively determined.

Bacteria usually reach the uterus by ascension from the distal parts of the urogenital tract, and less often by hematogenous spread (DAVIDSON, 2019). In the current research, in one cat concurrent pyothorax with pneumonia and pyometra were described. Histology revealed similar looking bacteria in both organs. It is not clear whether the bacteria ascended from the lower parts of urogenital tract, caused pyometra and spread to the lungs, or if the bacteria first invaded the thorax, causing pyothorax and pneumonia, and then hematogenously spread to the uterus. Lesions in other organs were related to the septic course of the disease and bacteremia (MOSIER, 2022). Splenomegaly was a consequence of lymphoid and histiocytic hyperplasia, and extramedullary hematopoiesis secondary to the systemic nature of the infection (DURHAM and BOES, 2022). Although sepsis has been associated with pyometra (HOLLINSHEAD and KREKELER, 2016), septic diseases accompanying pyometra have rarely been described. In one 6-year-old Ragdoll cat, septic pericarditis was a sequela of hematogenous bacterial spread from the pyometra-affected uterus (MAJOY et al., 2013). We add to this knowledge by reporting the first case of septic

disease involving both the uterus and lungs, with visible bacteria in other parenchymal organs.

Apart from reporting the low mortality from pyometra in Croatian cats, this study is the only report in the current veterinary medical literature where pyometra and pneumonia were concurrent pathologies leading to death in a single cat. The results of this study show that, although pyometra is a rare cause of death in the Croatian cat population, it still needs to be included as a differential diagnosis when systemic bacterial infection is suspected. Further, clinical examination of the whole body of the cat should be performed in cats with pyometra, as concurrent secondary sites in other organs might be present.

Declaration of competing interest

All authors declare that they have no conflicts of interest

References

- BONECKA, J., F. PANKOWSKI, B. DEGORSKA, M. KALWAS-SLIWINSKA, P. JURKA (2017): A case of simultaneous pregnancy, pyometra and fetal mummification in a cat. Proceedings of the 21st Annual Conference of the European Society for Domestic Animal Reproduction (ESDAR), 24-26 August, Bern, Switzerland. *Reprod. Domest. Anim.* 52, p. 73. <https://doi.org/10.1111/rda.13026>
- DAVIDSON, A. P. (2019): Cystic Endometrial Hyperplasia/Pyometra Complex. In: *Small Animal Internal Medicine*, 6th ed. (Nelson, R. W., C. G. Couto, Eds.), Elsevier, St. Louis, Missouri, USA, pp. 985-989.
- DONG, W.-Y., C.-Y. JIANG, C.-Z. QIAN (2013): Histopathological Observations on the Uterus and Ovary of a Cat with Pyometra. *Pak. Vet. J.* 33, 395-397.
- DURHAM, A. C., K. M. BOES (2022): Lymphoid/Lymphatic System. In: *Pathologic Basis of Veterinary Disease*, 7th ed. (Zachary, J. F., Ed.), Elsevier, St. Louis, Missouri, USA, pp. 846-891.
- FOSTER, R. A., C. PREMANANDAN (2022): Female Reproductive System and Mammas. In: *Pathologic Basis of Veterinary Disease*, 7th ed. (Zachary, J. F., Ed.), Elsevier, St. Louis, Missouri, USA, pp. 1263-1307.
- HAGMAN, R., B. STRÖM HOLST, L. MÖLLER, A. EGENVALL (2014): Incidence of pyometra in Swedish insured cats. *Theriogenology* 82, 114-120. <https://doi.org/10.1016/j.theriogenology.2014.03.007>
- HAYATI, F., M. S. AHRARI-KHAFI, M. HASSANKHANI, M. MANSOURIAN, S. ASGHARI (2016): A rare radiographic appearance of a calcified uterus in a queen with pyometra: a case report. *Vet. Med. (Praha)*. 61, 357-360. <https://doi.org/10.17221/167/2015-VETMED>
- HOLLINSHEAD, F., N. KREKELER (2016): Pyometra in the queen. To spay or not to spay? *J. Feline. Med. Surg.* 18, 21-33. <https://doi.org/10.1177/1098612X15623114>
- KACPRZAK, K., I. DOLKA, M. RZEWUSKA, A. RUSZCZAK, S. KANAFKA, M. GALANTY, P. JURKA (2016): A case of pyometra in pregnant queen. Proceedings of the 20th Annual Conference of the European Society for Domestic Animal Reproduction (ESDAR) and the 13th Conference of the Spanish Association for Animal Reproduction (AERA), 27-29 October, Lisbon, Portugal. *Reprod. Domest. Anim.* 51, p. 102. <https://doi.org/10.1111/rda.12801>
- KENNEY, K. J., D. T. MATTHIESEN, N. O. BROWN, R. L. BRADLEY (1987): Pyometra in cats: 183 cases (1979-1984). *J. Am. Vet. Med. Assoc.* 191, 1130-1132.
- KENT, M. S., S. KARCHEMSKIY, W. T. N. CULP, A. T. LEJEUNE, P. A. PESAVENTO, C. TOEDEBUSCH, R. BRADY, R. REBHUN (2022): Longevity and mortality in cats: A single institution necropsy study of 3108 cases (1989–2019). *PLoS. ONE* 17, e0278199. <https://doi.org/10.1371/journal.pone.0278199>
- MAJOY, S. B., C. R. SHARP, A. E. DICKINSON, S. M. CUNNINGHAM (2013): Septic pericarditis in a cat with pyometra. *J. Vet. Emerg. Crit. Care.* 23, 68-76. <https://doi.org/10.1111/vec.12008>
- MOSIER, D. A. (2022): Vascular Disorders and Thrombosis. In: *Pathologic Basis of Veterinary Disease*, 7th ed. (Zachary, J. F., Ed.), Elsevier, St. Louis, Missouri, USA, pp. 74-104.
- NAK, D., D. MISIRLIOGLU, Y. NAK, A. KESKIN (2005): Clinical Laboratory Findings, Vaginal Cytology and Pathology in a Controlled Study of Pyometra in Cats. *Aust. Vet. Practit.* 35, 9-12.
- NOAKES, D. E., T. J. PARKINSON, G. C. W. ENGLAND (2001): Cystic endometrial hyperplasia and pyometra. In: *Arthur's Veterinary Reproduction and Obstetrics*, 8th ed. (Noakes, D. E., T. J. Parkinson, G. C. W. England, Eds.), Saunders, Philadelphia, USA, pp. 664-665.

- SCHLAFER, D. H., R. A. FOSTER (2016): Pyometra. In: Jubb, Kennedy, and Palmer's Pathology of Domestic Animals, Volume 3, 6th ed. (Grant Maxie, M., Ed.), Elsevier St. Louis, Missouri, USA, pp. 390-393.
- SCOTT, K. C., J. K. LEVY, P. C. CRAWFORD (2002): Characteristics of free-roaming cats evaluated in a trap-neuter-return program. *J. Am. Vet. Med. Assoc.* 221, 1136-1138.
<https://doi.org/10.2460/javma.2002.221.1136>
- THOREN, E., B. STRÖM, R. HAGMAN (2022): A retrospective study of 92 female cats with pyometra. *Proceedings of the 23rd European Veterinary Society for Small Animal Reproduction (EVSSAR) Congress*, 1-2 October 2021, Virtual Congress. *Reprod. Domest. Anim.* 57, p. 45.
<https://doi.org/10.1111/rda.14066>
- WITHOEFT, J. A., T. G. CRISTO, GIOVANA BIEZUS, L. S. COSTA, T. P. DAL PONT, A. C. FREITAS, S. D. TRAVERSO, R. A. CASAGRANDE (2019): Causes of death and euthanasia in domestic cats in the Santa Catarina plateau (1995-2015). *Pesq. Vet. Bras.* 39, 192-200.
<https://doi.org/10.1590/1678-5150-PVB-5814>

Received: 9 February 2024

Accepted: 8 April 2024

Online publication: 31 October 2024

HUBER, D., L. MEDVEN ZAGRADIŠNIK, I. MIHOKOVIĆ BUHIN, I.-C. ŠOŠTARIĆ-ZUCKERMANN, A. GUDAN KURILJ, M. HOHŠTETER, B. ARTUKOVIĆ: Piometra - rijedak uzrok smrti mačaka u Hrvatskoj i prvi prikaz slučaja istodobne piometre i pneumonije. *Vet. arhiv* 95, 113-120, 2025.

SAŽETAK

Piometra je teška infekcija maternice s nakupljanjem gnoja, i ujedno relevantan klinički problem koji može završiti uginućem životinje. Smrtnost mačaka od piometre u svijetu je rijetko istraživana, a u Hrvatskoj takvih istraživanja nema. Cilj rada bio je provesti retrospektivno patološko istraživanje na mačkama iz Hrvatske oboljelima od piometre. Istraživanje također opisuje istodobnu piometru i pneumoniju koje su uzrokovale smrt u jedne mačke što, prema saznanjima autora, dosad nije zabilježeno. Uzorak čine mačke koje su uginule od piometre od 2009. do 2022. Pregledani su razudbeni zapisnici i histološki preparati tih mačaka. Od ukupno 2152 uginule mačke među kojima je bilo 908 ženki, četiri su mačke uginule zbog piometre, što odgovara mortalitetu od 0,19 % (od svih uključenih mačaka), odnosno 0,44 % (od svih uključenih ženskih mačaka). Sve su mačke bile križanci različitih pasmina, prosječne starosti 10,2 godine. Jedna je jednogodišnja mačka, osim piometre, bila zahvaćena piotoraksom i multifokalnim do koalescirajućim apscesima u stijenci maternice i lijevom plućnom krilu, s intralezijskim gram-pozitivnim kokcima. Rezultati istraživanja pokazuju nisku smrtnost od piometre, uglavnom u starijih mačaka, što odgovara podacima iz literature. Važan dio rezultata je prvi slučaj piometre i pneumonije uzrokovane gram-pozitivnim bakterijama kao istodobnim uzrocima smrti u jedne mačke, što se razlikuje od literaturnih podataka prema kojima je najčešći uzrok piometre mačaka gram-negativna *Escherichia coli*. Ovo istraživanje sadržava vrijedne informacije za buduću prevenciju bolesti, očuvanje zdravlja i dobrobit mačaka, i također pokazuje da neuobičajene bakterije mogu uzrokovati piometru te istodobno zahvatiti i druge organske sustave.

Ključne riječi: piometra; mačka; pneumonija; patologija; obdukcija; histologija