Acta Clin Croat 2024; 63: 431-435
doi: 10.20471/acc.2024.63.02.21

Case Report

COCAINE-INDUCED MIDLINE DESTRUCTIVE LESIONS

Hanna Pašić[1], Branka Vidrih[1,2], Iva Šarac[3], Nina Rotim[3], Ana Hrkać Pustahija[4], Branko Malojčić[3,5], Ivana Karla Franić[5], Ivona Radmanović[6], Maja Živković[3,7], Stjepan Jurić[8,9], Jelena Šarić-Jurić[8,9] and Marija Bošnjak Pašić[5,9]

[1]Department of Psychiatry, Sestre milosrdnice University Hospital Center, Zagreb, Croatia;
[2]School of Medicine, Catholic University of Croatia, Zagreb, Croatia;
[3]School of Medicine, University of Zagreb, Zagreb, Croatia;
[4]Department of Neuroradiology, Zagreb University Hospital Center, Zagreb, Croatia;
[5]Department of Neurology, Zagreb University Hospital Center, Zagreb, Croatia;
[6]Department of Neurology, Sisak General Hospital, Sisak, Croatia;
[7]Department of Psychiatry, Zagreb University Hospital Center, Zagreb, Croatia;
[8]Department of Neurology, Osijek University Hospital Center, Osijek, Croatia;
[9]Faculty of Medicine, Josip Juraj Strossmayer University, Osijek, Croatia

SUMMARY – Prolonged cocaine inhalation can cause destruction of nasal mucosa and ethmoid sinuses and palate perforation, thus inducing cocaine-induced midline destructive lesions (CIMDL) that affect only a limited number of predisposed patients. CIMDL are an autoimmune necrotizing inflammatory phenomenon associated with the presence of atypical antineutrophil cytoplasmic antibody (ANCA). Patients complain of epistaxis, nasal obstruction, hyposmia, sinus infections, and facial pain. Protocol for the CIMDL diagnosis includes medical history, clinical examination, magnetic resonance imaging, laboratory tests, immunology and serology tests, and chest x-ray. A 68-year-old man presented with a brain extension mimicking an ischemic-like lesion with surrounding edema. A diagnosis of CIMDL was made in the light of the patient's medical history, imaging studies, and laboratory testing including pANCA positivity which seems to promote disease phenotype.

Key words: *Cocaine; Anti-neutrophil cytoplasmic antibodies; Cocaine-induced midline destructive lesions*

Introduction

Cocaine-induced midline destructive lesions (CIMDL) are a rare complication of prolonged cocaine abuse, representing a global public health concern due to the widespread usage of cocaine. Typically administered through snorting, prolonged abuse can result in severe destructive lesions affecting nasal mucosa, as well as bone and cartilage structures of the septum and palate, collectively known as CIMDL[1-5]. In rare cases, CIMDL can manifest systemically, impacting the central nervous system[6]. Destruction of midline facial structures opens the way for inflammation and ischemic necrosis of CIMDL to progress, extending through the cribriform palate and skull base, subsequently affecting cerebral tissue above, and causing various neurological symptoms[6]. We report an interesting and complex case of

Correspondence to: *Hanna Pašić, MD*, Department of Psychiatry, Sestre milosrdnice University Hospital Center, Vinogradska c. 29, HR-10000 Zagreb, Croatia
E-mail: hpasic96@gmail.com

Received June 13, 2024, accepted August 22, 2024

CIMDL which required a comprehensive approach, with multidisciplinary team consisting of a neurology, ear-nose-throat (ENT), psychiatry, immunology, and radiology specialists, all being involved in treatment of this patient.

Case Report

A 68-year-old male patient was admitted to the hospital in a state of confusion (delirium), associated with urine incontinence and mild weakness on the left side of the body, which manifested three days prior to the examination. His partner noticed days before that he was confused and had visual hallucinations, seeing people who were not there and talking about situations that his partner knew did not happen. Additionally, he experienced a pulsating headache accompanied by nausea that lasted for one month. It was later discovered that the patient had a history of cocaine abuse for an unknown period, likely through intranasal consumption due to the absence of puncture marks and 'tracks' on the patient's body. His physical appearance also supported cocaine abuse, as he had lost a significant amount of weight. Two days before hospitalization, he did not eat or drink anything, a common occurrence in chronic cocaine users due to decreased appetite. In the emergency department, computed tomography (CT) scan of the brain, along with blood, urine tests, and chest x-rays, was immediately performed. The CT scan showed bilateral frontal hypodensities with surrounding edema corresponding to ischemic lesions. Blood tests indicated normocytic anemia with elevated inflammation parameters (C-reactive protein and white blood cells), leading to the initiation of empiric antimicrobial therapy. During the second day of hospital stay, the patient's health condition deteriorated, and he developed more severe left hemiparesis and paresis of the right leg, resulting in triparesis. Changes in his personality and behavior became more prominent, with increased aggression, agitation, and delusions. Subsequent magnetic resonance imaging (MRI) scan of the brain with contrast, along with magnetic resonance angiography (MRA) revealed vasogenic edema in the medial area of both frontal lobes, indicating cerebritis. Severe inflammation of the paranasal sinuses was also observed, common in drug addicts using nasal insufflation (Fig. 1a and 1b).

For definitive diagnosis of meningitis, lumbar puncture was performed alongside other routine testing, including polymerase chain reaction panel for meningitis and encephalitis, human immunodeficiency virus serology testing, venereal disease research laboratory tests, hepatitis viral panel test, tumor markers with whole-body CT scan, erythrocyte sedimentation rate, antinuclear antibody test, rheumatoid factor, leishmaniasis and fungal serology, and antineutrophil cytoplasmic antibodies. Although there were no typical signs of central nervous system inflammation, infectious disease specialists suggested another combination of antimicrobial drugs to minimize the chance of fatal repercussions. Spinal tap was repeated, revealing a slight increase in leukocytes. Additional cerebrospinal fluid and serum tests (neuroimmunology tests, angiotensin converting enzyme, and serum chitotriosidase) returned within the reference values or were negative. The patient underwent pulse corticosteroid therapy for three days, resulting in a reduction of brain edema, although other pathological changes persisted (Fig. 2a and 2b).

The complexity of the case required a multidisciplinary approach. Otorhinolaryngologists did multiple ENT endoscopy inspections of the patient due to destruction of the nasal septum seen on imaging, recommending penicillin for bacterial infection, but the patient refused intranasal biopsy. Dysphagia and the contraindication for nasogastric tube placement due to nasal septum destruction necessitated parenteral nutrition. Two additional MRI + MRA scans of the brain showed further regression of edema in the frontal lobes without postcontrast imbibition and without restriction of diffusion. The patient's behavioral changes, attributed to frontal lobe lesions, were addressed by multiple psychiatric evaluations for optimal therapy titration. Rheumatologists were consulted, suspecting vasculitis. Indirect immunofluorescence was preformed which showed high titer of perinuclear antineutrophil cytoplasmic antibody (pANCA) and negative cytoplasmic ANCA (cANCA). Positive pANCA autoantibodies brought us closer to the diagnosis of CIMDL. Further examinations, including heart ultrasound, speech therapy for dysphagia and dysarthria, and daily physical therapy contributed to the patient's overall improvement. While weakness in the left side of the body and the right leg persisted, collaborative efforts from various specialists resulted in significant progress in the patient's medical state, with the prospect of further rehabilitation.

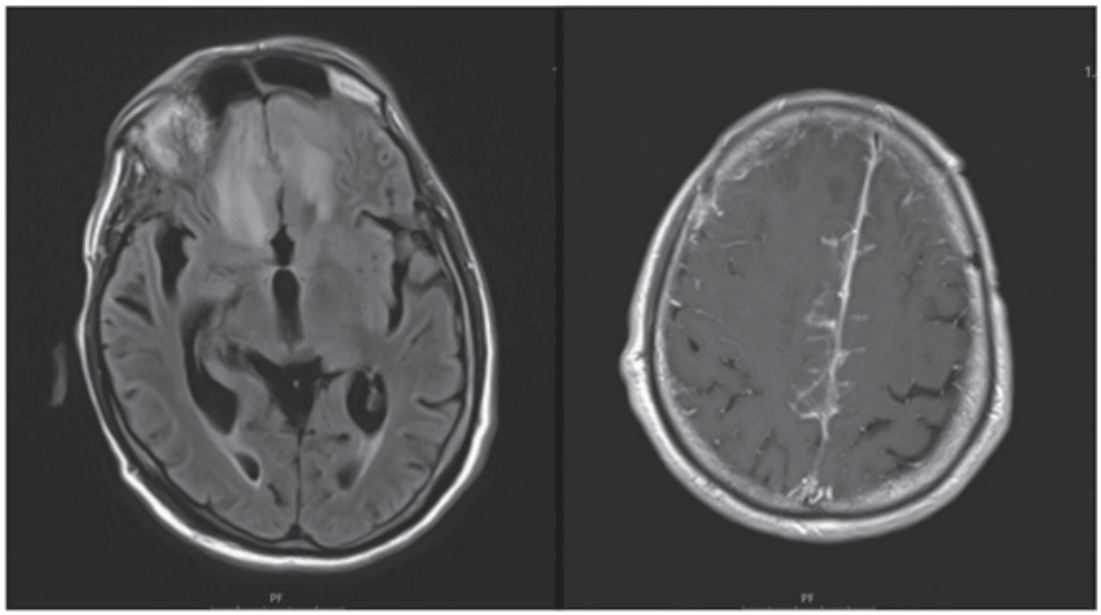

Fig 1. (a) Axial FLAIR images showing brain parenchyma edema bilaterally in frontal regions; (b) axial T1W postcontrast images showing leptomeningeal contrast enhancement. Intraparenchymal changes show no contrast enhancement.

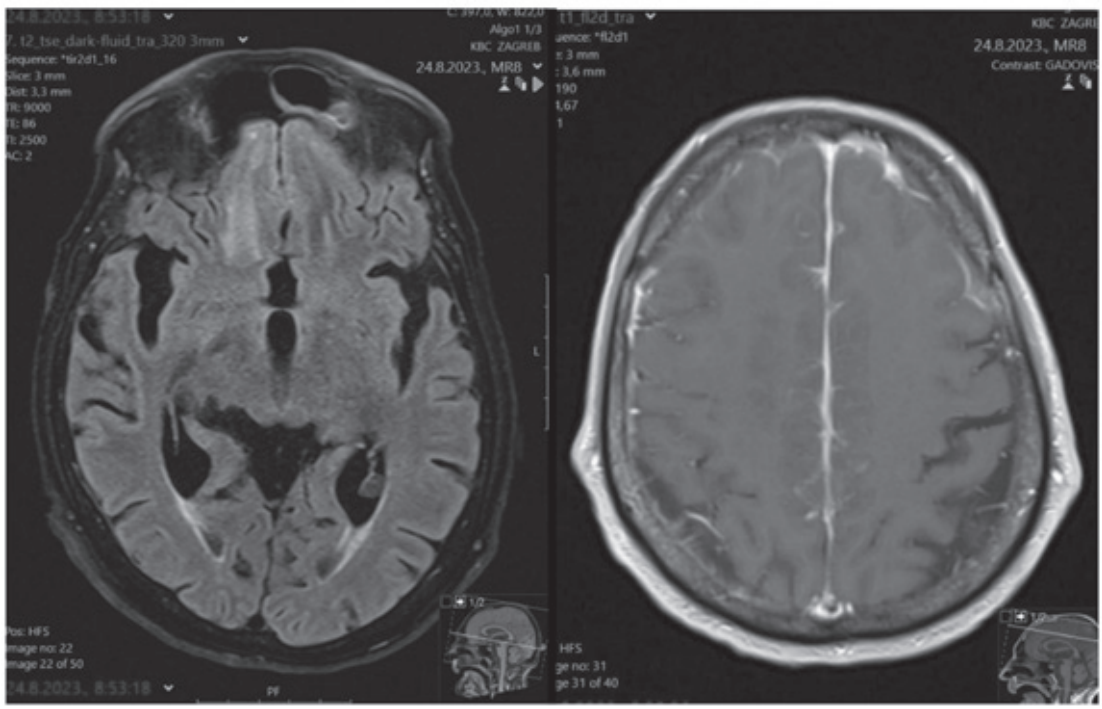

Fig 2a Fig 2b

Fig 2. (a) Follow-up MRI, axial FLAIR images showing partial regression of parenchymal edema in frontal regions; (b) follow-up MRI, axial T1W postcontrast images showing partial regression of leptomeningeal contrast enhancement. Intraparenchymal changes remained without contrast enhancement.

Discussion

Cocaine is known to cause various systemic clinical manifestations, including serious neurological complications[1,6]. On a systemic level, it can cause acute myocardial infarction and cardiac arrhythmias[1]. The most common neurological manifestations include cerebral infarction, intracerebral and subarachnoid hemorrhage, transient ischemic attacks, migraines, and seizures[6]. Given that the most frequently used route of cocaine administration is intranasal inhalation, localized adverse effects are commonly observed in the nasal tract, such as erosion of the septum, palate, and ethmoid sinuses[1,3,4]. Nasal insufflations cause mucosal lesions, and chronic cocaine abuse can lead to progressive damage, resulting in ischemic necrosis of the septal cartilage and perforation of the nasal septum, known as CIMDL[6]. While localized destruction is common, destruction of the neighboring skull base and extension of the lesions to the brain are rare but have been documented in the literature[6]. Our case aligns with similar radiological findings, revealing extensive edema affecting bilateral cortex and white matter of frontal lobes, with a diffuse post-contrast enhancement of the leptomeninges. Despite commonalities, our patient exhibited dysarthria, severe left-side hemiparesis, and frontal lobe syndrome with behavioral changes.

The pathogenesis of CIMDL is not fully understood, with various factors contributing to its destructive nature, including inflammatory, infectious, pro-apoptotic, and autoimmune mechanisms. ANCA formation, recurrent secondary bacterial infection in the damaged nasal mucosa, chemical irritation from the substance itself, mechanical trauma from high velocity inhalation, acquired immunosuppression in long-time abusers, osteoblast inhibition, as well as ischemic changes and necrosis of the mucosa and perichondrium caused by vasoconstrictor effects of cocaine all appear to play prominent roles in inducing destruction[1,2,6].

It is well known that one of the characteristics of CIMDL is the presence of ANCA in the affected tissue[1,4], which were also found to be present in our patient. CIMDL is therefore known to mimic the clinical manifestations of other systemic necrotizing inflammatory diseases with positive ANCA, such as small-vessel vasculitis, mainly granulomatosis with polyangiitis (GPA), also known as Wegener's granulomatosis (WG) or atrophic rhinitis, systemic lupus erythematosus, tuberculosis, etc.[1-3]. As mentioned, one of the most interesting side effects of cocaine abuse is its ability to induce several types of vasculitis, especially those that mimic ANCA-associated vasculitis, such as GPA[4,6].

Granulomatosis with polyangiitis is a systemic autoimmune disease characterized by granulomatous inflammation and necrosis of the upper and lower respiratory tract. It is a vasculitis mainly affecting small- and medium-size vessels, with focal proliferative granuloma formation[2]. GPA has the highest level of sinonasal involvement among systemic vasculitides and therefore it is the main differential diagnosis for CIMDL[2]. Nasal manifestations are the presenting signs in 50%-90% of GPA cases[2]. Lesions from CIMDL and GPA limited to the upper respiratory tract may be clinically indistinguishable, but the degrees of local destruction are usually much more significant in CIMDL than in the nasal form of GPA[6].

Antineutrophil cytoplasmic antibodies are detectable in most patients with GPA, as well as in those with CIMDL. ANCAs are present in up to 83% of cases of limited GPA, and similarly, in one study, 84% of the CIMDL patients were found to be positive on ANCA test[2,4]. One thing that can be beneficial in differentiating CIMDL from other ANCA-positive vasculitides is the presence of pANCA staining pattern, which is typical in CIMDL, while cANCA staining pattern predominates in GPA[2,4,6]. ANCAs, specifically for neutrophil elastase (NE), are therefore a valuable diagnostic marker for CIMDL because they are almost never detectable in patients with GPA[2,6]. Our patient had positive pANCA pattern.

While positive pANCA findings are suggestive of CIMDL, they are not exclusive, as levamisole-associated vasculitis, linked to cocaine, can also exhibit similar profiles[4,6]. ANCAs play a crucial role in the inflammatory response, with CIMDL responding well to aggressive immunosuppressive therapy, particularly high-dose pulse corticosteroid therapy[2]. Our patient exhibited significant clinical and radiological improvement following this treatment. CIMDL poses a challenge for timely diagnosis due to its broad spectrum of differential diagnoses, necessitating further research to fully understand its pathophysiology.

Cocaine-induced midline destructive lesions is a rare entity resulting from necrotizing inflammatory tissue response triggered by cocaine abuse in predisposed individuals, often presenting with significant neurological involvement. Timely recognition and treatment are crucial to avoid fatal consequences. The complexity of CIMDL necessitates a multidisciplinary approach, with ANCAs playing a pivotal role in diagnosis. Further research is essential to comprehensively understand the pathophysiology of this condition.

References

1. Di Cosola M, Ambrosino M, Limongelli L, Favia G, Santarelli A, Cortelazzi R, Lo Muzio L. Cocaine-induced midline destructive lesions (CIMDL): a real challenge in diagnosis. Int J Environ Res Public Health. 2021 Jul 23;18(15):7831. doi: 10.3390/ijerph18157831
2. Mirzaei A, Zabihiyeganeh M, Haqiqi A. Differentiation of cocaine-induced midline destructive lesions from ANCA-associated vasculitis. Iran J Otorhinolaryngol. 2018;30(100):309-13.
3. Nitro L, Pipolo C, Fadda GL, *et al*. Distribution of cocaine-induced midline destructive lesions: systematic review and classification. Eur Arch Otorhinolaryngol. 2022;279(7):3257-67. doi: 10.1007/s00405-022-07290-1
4. Pendolino AL, Benshetrit G, Navaratnam AV, *et al*. The role of ANCA in the management of cocaine-induced midline destructive lesions or ENT pseudo-granulomatosis with polyangiitis: a London multicentre case series. Laryngoscope. 2024;134(6):2609-16. doi: 10.1002/lary.31219
5. Di Cosola M, Sembronio S, Dioguardi M, Robiony M, Diaz-Flores Garcia V, Pucci R, *et al*. The clinical manifestations of cocaine-induced midline destructive lesion: a real challenge for maxillo-facial surgeons, mapping evidence review. Chirurgia. 2022;35:317-28. doi: 10.23736/S0394-9508.22.05502-4
6. García-Pérez D, Ruiz-Ortiz M, Panero I, Eiriz C, Moreno LM, García-Reyne A, García A, Martín-Medina P, Salvador-Álvarez E, Hernández-Lain A, Serrano A, Gil-Etayo FJ, Castaño-León AM, Paredes I, Pérez-Núñez Á. Snorting the brain away: cerebral damage as an extension of cocaine-induced midline destructive lesions. J Neuropathol Exp Neurol. 2020 Dec 4;79(12):1365-9. doi: 10.1093/jnen/nlaa097

Sažetak

KOKAINOM IZAZVANE DESTRUKTIVNE LEZIJE SREDIŠNJE LINIJE

H. Pašić, B. Vidrih, I. Šarac, N. Rotim, A. Hrkać Pustahija, B. Malojčić, I. K. Franić, I. Radmanović, M. Živković, S. Jurić, J. Šarić-Jurić i *M. Bošnjak Pašić*

Dugotrajna konzumacija kokaina nazalnim putem može uzrokovati destrukciju nosne sluznice, etmoidnih sinusa i perforaciju nepca, što dovodi do kokainom izazvanih destruktivnih lezija središnje linije (CIMDL) koje pogađaju samo ograničen broj predisponiranih bolesnika. CIMDL su autoimuni nekrotizirajući upalni fenomen povezan s prisutnošću atipičnih antineutrofilnih citoplazmatskih antitijela (ANCA). Bolesnici se žale na epistaksu, nazalnu opstrukciju, hiposmiju, sinusne infekcije i bol u licu. Protokol za dijagnozu CIMDL uključuje anamnezu, klinički pregled, magnetsku rezonancu, laboratorijske testove, imunološke i serološke pretrage te rendgensku snimku prsnog koša. Kod 68-godišnjeg muškarca zabilježene su lezije na mozgu nalik ishemijskim lezijama s okolnim edemom. Dijagnoza CIMDL postavljena je na temelju anamneze, slikovnih pretraga i laboratorijskih testova uključujući pozitivne pANCA koji se čini važnim za fenotip bolesti.

Ključne riječi: *Kokain; Antineutrofilna citoplazmatska antitijela; Kokainom izazvane destruktivne lezije središnje linije*