

# Introducing the transcaval transcatheter aortic valve implantation to Croatia: pioneering experience from Split

**Andrija Matetić<sup>1,2\*</sup>**  
**Frane Runjić<sup>1</sup>**,  
**Nikola Crnčević<sup>1</sup>**,  
**Ivica Kristić<sup>1</sup>**,  
**Darija Baković Kramarić<sup>1,2</sup>**

<sup>1</sup>University Hospital of Split, Split, Croatia  
<sup>2</sup>University of Split School of Medicine, Split, Croatia

**KEYWORDS:** transcaval approach, transcatheter aortic valve implantation, pioneering.

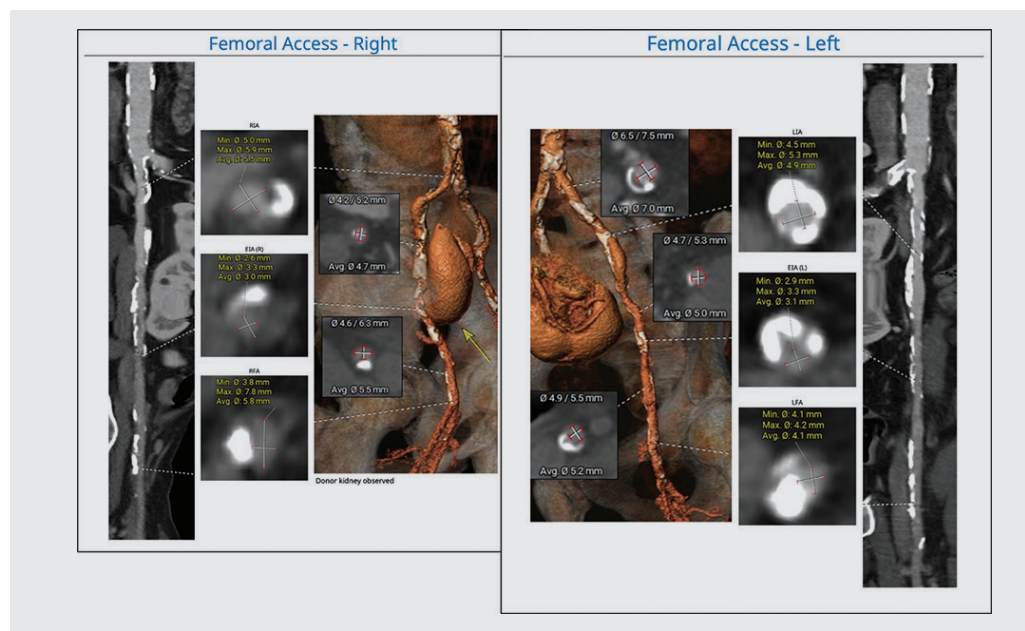
**CITATION:** *Cardiol Croat.* 2025;20(1-2):28-9. | <https://doi.org/10.15836/ccar2025.28>

**\*ADDRESS FOR CORRESPONDENCE:** Andrija Matetić, Klinički bolnički centar Split, Spinčiceva 1, HR-21000 Split, Croatia. / Phone: +385-98-9546-455 / E-mail: [andrija.matetic@gmail.com](mailto:andrija.matetic@gmail.com)

**ORCID:** Andrija Matetić, <https://orcid.org/0000-0001-9272-6906> • Frane Runjić, <https://orcid.org/0000-0001-6639-5971>  
Nikola Crnčević, <https://orcid.org/0000-0002-1399-3406> • Ivica Kristić, <https://orcid.org/0000-0002-9882-9145>  
Darija Baković Kramarić, <https://orcid.org/0000-0001-6751-5242>

**Introduction:** Transcatheter aortic valve implantation (TAVI) is a life-saving procedure for patients with severe symptomatic aortic stenosis at high surgical risk. The transfemoral approach is preferred, but some patients have unsuitable iliofemoral arteries, necessitating alternative access<sup>1</sup>. While no consensus exists on the best alternative, the transcaval approach offers advantages when performed in experienced centers<sup>2,3</sup>. Compared to transaxillary or transcarotid access, transcaval TAVI lowers stroke risk, allows easier valve deployment, accommodates any sheath size, is fully percutaneous, and maintains a transfemoral-like setup<sup>2,3</sup>. This study presents the first transcaval TAVI cases in Croatia and Central-Southeast Europe, successfully performed at the University Hospital of Split. Six cases were completed, with one exemplary case detailed here.

**Case report:** 78-year-old male with severe symptomatic aortic stenosis and high surgical risk was referred for TAVI. His history included chronic heart failure, chronic kidney disease with a functional kidney transplant, severe peripheral artery disease, prior carotid surgery, stroke, and cancer treatment. Due to extensive iliofemoral calcification and prior kidney transplant attachment, the transfemoral approach was unfeasible (**Figure 1**). Transaxillary access was also ruled out due to significant stenoses. The Structural Heart Team opted for the transcaval approach after detailed preprocedural planning (**Figure 2**). The fully percutaneous procedure was performed under operator-led sedation. The tract between the inferior vena cava and abdominal aorta was created using an electrified wire and snare, followed by eSheath (16F) placement. An Edwards Sapien S3 Ultra 29 mm valve was deployed success-

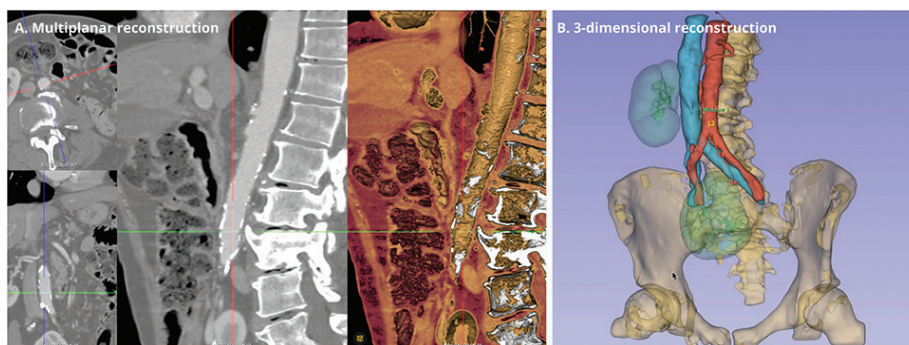


**FIGURE 1.** Computed tomography reconstructions of iliofemoral arteries: Severe bilateral atherosclerosis and calcifications with a functional kidney donor on the right side.

**RECEIVED:**  
February 5, 2025  
**ACCEPTED:**  
February 14, 2025



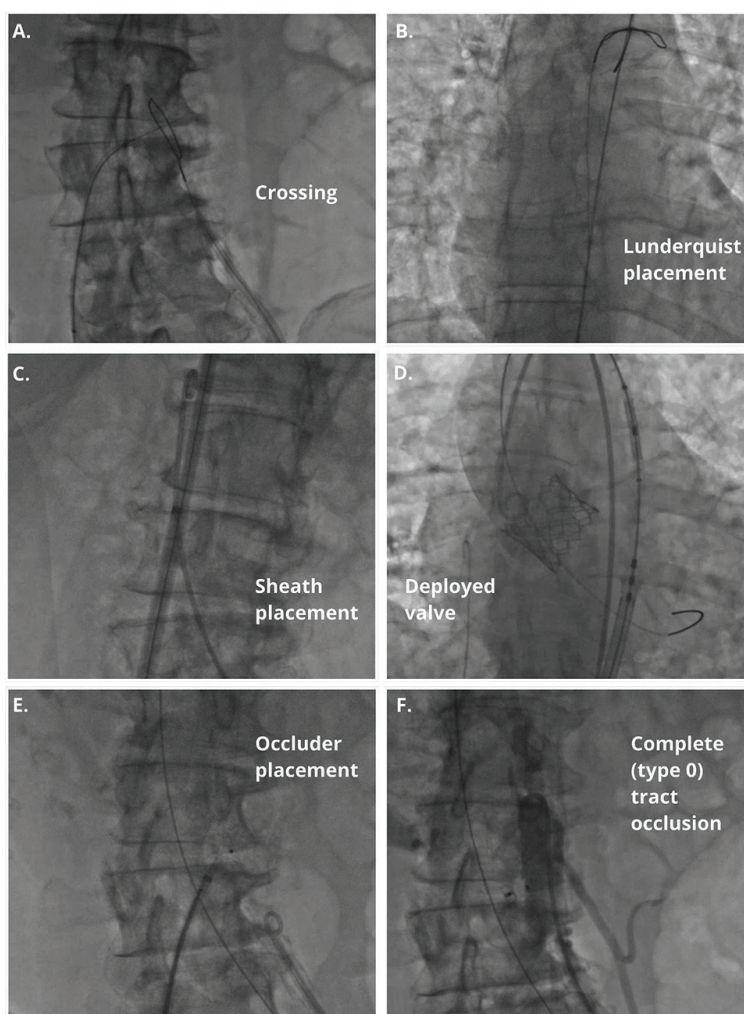
**Introducing the transcaval transcatheter aortic valve implantation to Croatia:  
pioneering experience from Split**



**FIGURE 2. Procedural planning using the multiplanar and 3-dimensional reconstructions: Complete planning was done internally by the operators within the University Hospital of Split.**

fully, achieving optimal positioning and no regurgitation. The tract was sealed using an Amplatzer Duct Occluder, and vascular access was closed with suture devices (**Figure 3**). The patient recovered uneventfully and was discharged on postoperative day 3.

**Conclusion:** Transcaval TAVI is a viable alternative for patients with unsuitable iliofemoral anatomy. It can be achieved with favourable procedural outcomes, if preceded by meticulous preprocedural planning and performed by experienced operators.



**FIGURE 3. Procedural execution and steps (A-F): All procedures were done without the proctors, after advanced international education.**

**LITERATURE**

1. Vahanian A, Beyersdorf F, Praz F, Milojevic M, Baldus S, Bauersachs J, et al; ESC/EACTS Scientific Document Group. 2021 ESC/EACTS Guidelines for the management of valvular heart disease. *Eur Heart J*. 2022 Feb 12;43(7):561-632. <https://doi.org/10.1093/eurheartj/ehab395>
2. Salihi A, Ferlay C, Kirsch M, Shah PB, Skali H, Fournier S, et al. Outcomes and Safety of Transcaval Transcatheter Aortic Valve Replacement: A Systematic Review and Meta-analysis. *Can J Cardiol*. 2024 Nov;40(11):2054-2062. <https://doi.org/10.1016/j.cjca.2024.05.016>
3. Lederman RJ, Babaliaros VC, Lisko JC, Rogers T, Mahoney P, Foerst JR, et al. Transcaval Versus Transaxillary TAVR in Contemporary Practice: A Propensity-Weighted Analysis. *JACC Cardiovasc Interv*. 2022 May 9;15(9):965-975. <https://doi.org/10.1016/j.jcin.2022.03.014>