

## RADIOLOGICAL WORKUP OF SPINE TRAUMA

Katarina Maljić<sup>1,2</sup>, Darko Tomić<sup>1,3</sup> , Tanja Pavlović<sup>1</sup>, Ivana Stojak<sup>1</sup>, Ana-Marija Kapetanović

<sup>1</sup> Faculty of Health Studies, University of Mostar, 88 000 Mostar, Bosnia and Herzegovina

<sup>2</sup> Faculty of Economics, University of Mostar, 88 000 Mostar, Bosnia and Herzegovina

<sup>3</sup> Croatian Hospital "Dr. Fr. Mato Nikolić" Nova Bila, 72 276 Nova Bila, Bosnia and Herzegovina

Received on 18. 3. 2025.

Reviewed on 20. 4. 2025.

Accepted on 2. 5. 2025.



### ABSTRACT

**Introduction:** imaging plays an important role in the treatment of patients with spinal trauma. Until a final diagnosis is made, the first imaging method is X-ray diagnostics, then CT and finally MRI diagnostics for spinal cord injuries. The aim of this paper is to investigate how radiological methods can help in the precise diagnosis and monitoring of patients with spinal injury, and which radiological diagnostic method is the most effective.

**Research methodology:** data collection time: from 1.1. 2023 to 1.1. 2024 at the University Clinical Hospital Mostar, Department of Radiology. The subjects are patients with spinal trauma who were referred for radiological treatment at the University Clinical Hospital Mostar during the mentioned time period.

**Results:** The youngest subject was 7 years old, and the oldest was 83 years old. The mean age of the subjects was 49.4 years. The majority of subjects were in the age groups 60-69 and older than 70 years, both groups 23%. The most common injury was a rib fracture, in 27% of subjects, acetabular fracture in 23% of subjects, and cervical spine fracture in 21%. Of the total number of subjects, 49% had a lumbar spine injury, 30% a thoracic injury and 21% a cervical spine injury. The most common type of imaging was CT, 38% 33% of subjects had X-ray imaging and 29% MRI imaging.

**Conclusion:** CT is the first imaging modality due to its fast and easy acquisition and high sensitivity for detecting bone fractures. New technologies in the field of CT, especially DECT and photon-counting CT, have managed to increase the sensitivity for detecting spinal trauma. MRI provides detailed information about ligaments, soft tissues, disc and spinal cord.

**Keywords:** spine trauma, radiological diagnostics

Corresponding author: Darko Tomić, M.Sc.; [darkotomic@hotmail.com](mailto:darkotomic@hotmail.com)

## INTRODUCTION

The spine plays a crucial role in maintaining the body's upright posture in relation to the action of gravity and receives, attenuates and distributes sudden compressive and tensile loads caused by the constant kinetics of the body. Its role is also important in protecting the spinal cord and the associated nerve roots located in the spinal canal (1). The paravertebral musculature, which consists of the deep muscles of the back, is also important for the stability of the spine (2). After completing the clinical examination, radiological examinations of the spine are ordered, if necessary.

Routinely and for orientation, the spine is imaged in two directions: anteroposterior (AP) and laterolateral (LL).

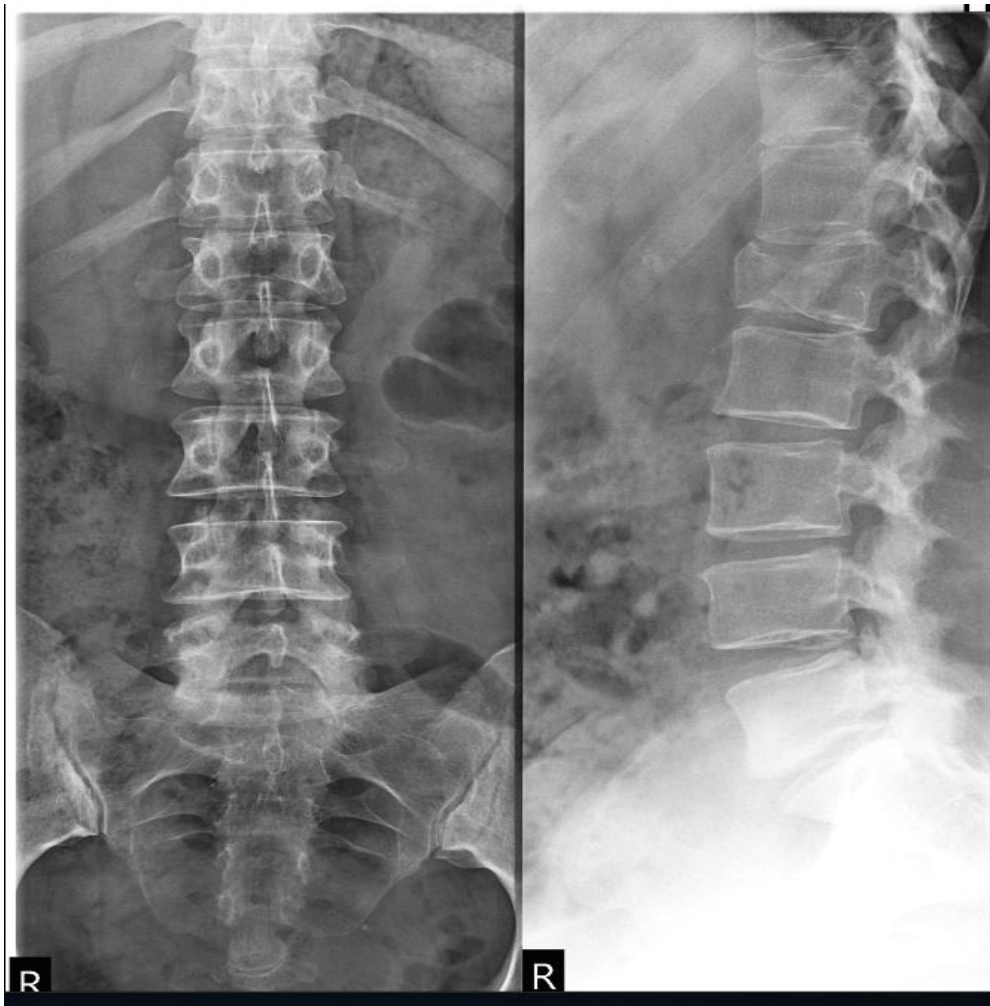
If there is a spinal deformity, the degree of its deformation is determined by AP and LL images. It is also a good idea to take a vertebrogram of the entire spine, from which the balance of the spine is analyzed, i.e. the intersegmental impact of the pathological process on the spine is analyzed.

Electromyoneurography and nerve conduction velocity measurement are often used in the treatment of cervicocephalic

syndrome. Transcranial magnetic resonance imaging is often used to assess the vascularity of the vertebrobasilar artery. Doppler ultrasound of the vertebral artery (Transcranial Cervical Doppler - TCD), then MR angiography of the neck and sometimes selective spinal angiography to determine the blood supply to the spinal cord, bone elements and paravertebral structures (3).

In emergency cases, the appropriate choice of imaging for spinal trauma depends on several factors such as the availability of modalities, the clinical and neurological status of the patient, the type of trauma (blunt, single or multiple trauma), and other associated comorbidities.

In the rare circumstances when CT is not available, the initial imaging modality is radiography. A minimum of lateral and anteroposterior views for the spinal axis should be obtained with the addition of an open-mouth odontoid view for the cervical spine. Additional views such as oblique views and/or swimmer's view are often performed in an attempt to clear the cervicothoracic junction. With the exception of pediatric trauma, radiography has been replaced by CT in most settings (4).

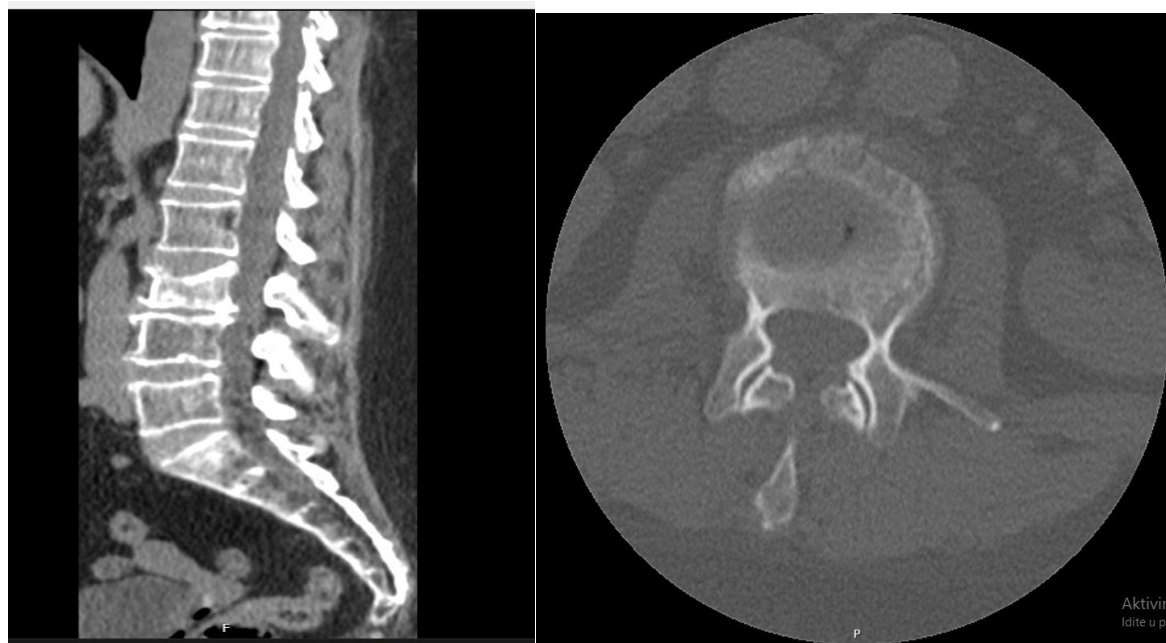


**Figure 1.** *X-ray of the lumbar spine*

*(Source: Croatian Hospital "Dr. Fr. Mato Nikolić" Nova Bila; Radiology Department)*

Computed tomography (CT) is the preferred method for evaluating the cervical spine for bony injuries following blunt trauma. The entire spinal axis can be reliably and expeditiously assessed with automatic reshaping of the axial data set into multiple planes, allowing for better and more accurate diagnosis of bony and

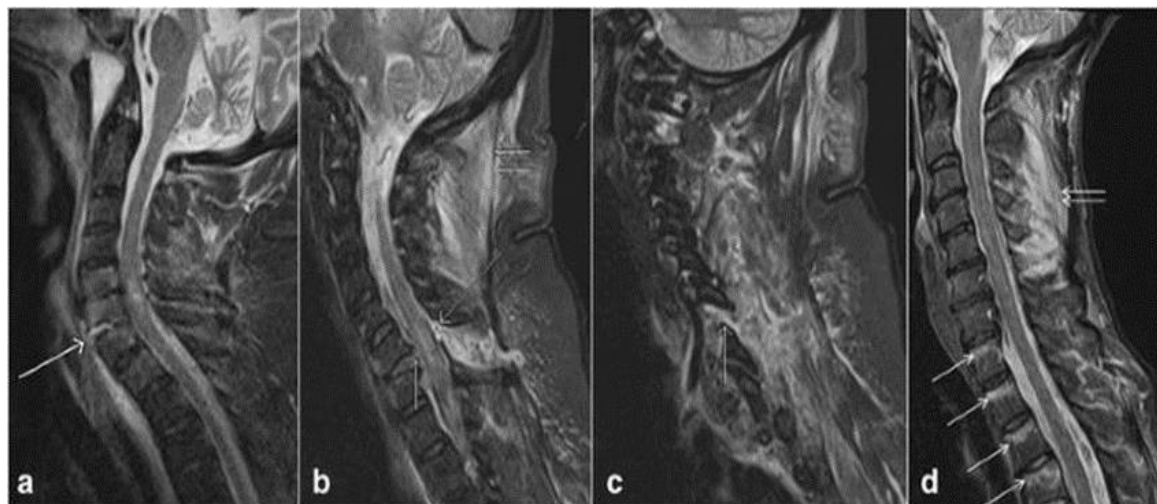
soft tissue abnormalities. Moreover, in the case of polytrauma, images of the spine can be reconstructed directly from the chest, abdomen, and pelvis data sets with sensitivity equivalent to that of a dedicated spine CT scan. This has the added advantage of minimizing radiation dose (5).



**Figure 2.** (a) Sagittal and (b) axial CT views showing a burst fracture of L3 with significant retropulsion of the vertebral body into the spinal canal and loss of body height. (Source: Croatian Hospital "Dr. Fr Mato Nikolić" Nova Bila; Radiology Department)

MRI is now considered the method of choice for evaluating the spectrum of soft tissue injuries associated with spinal trauma. This includes damage to the intervertebral discs, ligaments, vascular structures, and spinal cord. No other imaging modality has been able to faithfully reproduce the internal architecture of the spinal cord, and this is a special feature that is unique to MRI. Any patient who has persistent neurological deficits after spinal trauma should undergo MRI in the acute period to exclude direct damage/compression of the spinal cord. MRI provides indisputable evidence not only of spinal cord injury, but will also reliably show disc

injuries/herniations, paraspinal soft tissue edema (ligamentous sprain /rupture), epidural hematomas, and vascular injuries. In addition, MRI provides the most reliable assessment of chronic spinal cord injury and imaging analogues of posttraumatic progressive myelopathy, which often presents with imaging findings such as syrinx formation, myelomalacia, and cord atrophy. The extent to which MRI can detect spinal instability is overestimated because MRI cannot provide a reliable assessment of ligamentous integrity in most cases. In fact, MRI falsely overestimates the soft tissue component of the injury (6).



**Figure 3.** Picture of tau inversion recovery (STIR) images show complete rupture of the anterior longitudinal ligament (arrow, a), complete rupture of the posterior longitudinal ligament (short single arrow, b) and ligamentum ruptum flavum (long arrow, b), rupture of the nuchal ligament (short double arrow) arrows, b), injury to the facet capsule (arrow, c) and injury to the interspinous ligament (short double arrows, d).  
(Source: <https://bmcmusculoskeletaldisord.biomedcentral.com/articles/10.1186/s12891-0161169-6>)

The MRI protocol for the cervical spine in acute spinal trauma includes sagittal T1 (T1-weighted) and T2-weighted (T2W) and short tau inversion recovery (STIR) sequences of 3 mm thickness and axial T2-weighted gradient echo (GRE) images without contrast. In the thoracic and lumbar spine, sagittal T1-weighted, T2-weighted and STIR sequences of 4 mm thickness and axial T1-weighted, T2-weighted and T2 GRE images of 4 mm thickness without contrast are recommended. 3D volumetric axial GRE or T2-weighted slices of 1–2 mm thickness are useful in the cervical region. Fat-saturated T2-weighted images are valuable for the evaluation of ligamentous and soft tissue injuries, and T2 GRE for the evaluation of small hemorrhages or blood products in the spinal cord (6).

### Injuries to the vertebral column and spinal cord

Classically, spinal injuries are categorized by mechanism of injury and/or by

instability. Instability is defined as an abnormal transfer between adjacent vertebral segments with normal physiologic motion. Unrecognized instability after trauma is a potential cause of delayed spinal cord injury. Therefore, early stabilization of the initial injury is imperative for appropriate clinical management. The simplest method of testing for instability in a controlled environment is to perform lateral flexion and extension radiographs to produce a visible subluxation at the suspected level, but this is rarely performed in practice. The mechanism of injury will result in several different types of traumatic injuries to the cervical, thoracic, and lumbar vertebrae and spinal cord, which can result in stable or unstable spinal injuries (7). Due to the distinct anatomical differences and resulting injury patterns, cervical spine injuries are divided into subaxial injuries (base of skull to axis) and lower cervical injuries (C3–C7). The mechanism of cervical spine injury can be divided into

four major groups: hyperflexion, hyperextension, rotation, and vertical compression with frequent variations involving components of the major groups (e.g., flexion and rotation).

The most common fracture, at the thoracolumbar junction, is a simple compression or wedge fracture (50% of all fractures) which is considered stable. The remaining types of fractures among them are the so-called seat belt injuries, which can be divided into three subtypes: type I (Chance fracture) involves the posterior bony elements, type II (Smith fracture) involves the posterior ligaments and, in type III, the annulus fibrosus ruptured, allowing subluxation and are considered unstable fractures (8).

Whiplash-associated disorders (WAD) is a clinical diagnosis and describes a variety of clinical manifestations, such as neck pain immediately or 24 hours after trauma, neck stiffness, headache, dizziness, vertigo, hearing and vision disturbances, concentration and psychological problems. Imaging findings include bony injuries such as bone contusions and occult fractures, ligament injuries (the most common finding) and tears. Disc lesions and post-traumatic herniation may also occur. MRI signal changes in the alar and transverse ligaments may be observed.

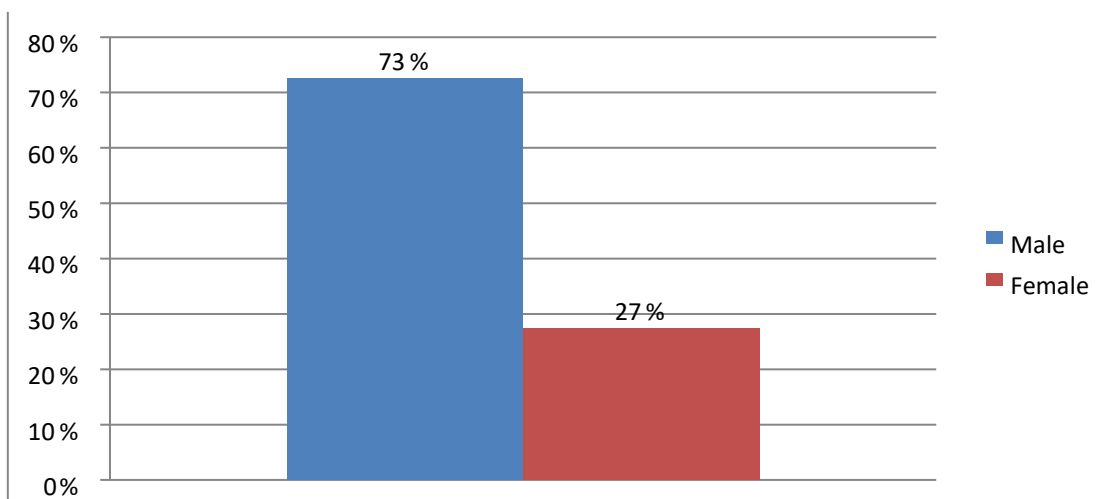
Whether these signal abnormalities are responsible for the complaints of patients with WAD remains controversial, as these signal abnormalities have also been observed in asymptomatic individuals and have not been significantly associated with clinical testing and prognosis of acute whiplash injury. A recent meta-analysis could not demonstrate any association between MRI signal changes in the alar and transverse ligaments and WAD (9).

## RESEARCH METHODOLOGY

The research is prospective qualitative. Purposive sampling. The data collection time was in the period from January 1, 2023 to January 1, 2024 at the University Clinical Hospital Mostar, Department of Radiology. The respondents were patients with spinal trauma who were radiologically and diagnostically processed in the aforementioned Department. For statistical data processing, the following programs were used: SPSS, Excel.

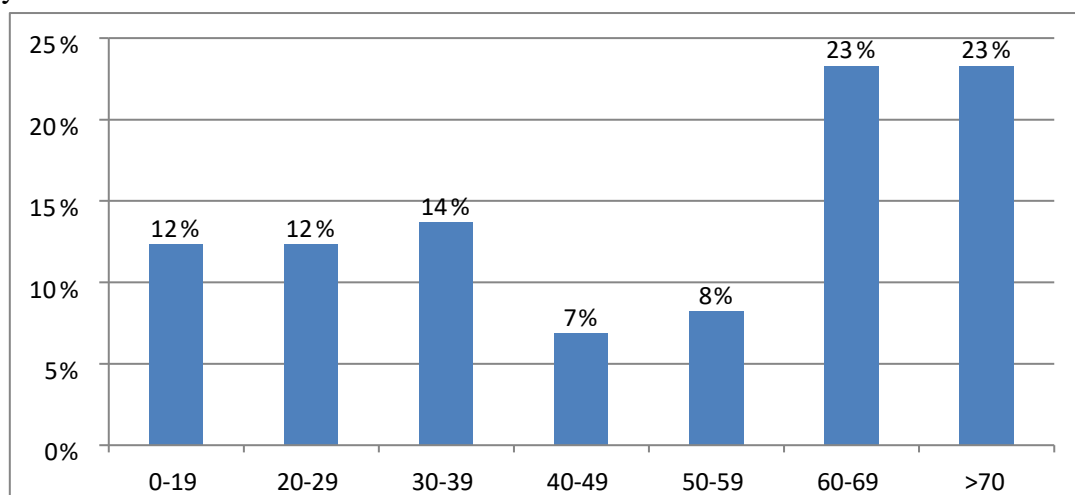
## RESULTS

A total of 73 subjects who had spinal trauma participated in the study for the period from January 1, 2023 to January 1, 2024.



**Chart 1.** Gender distribution of respondents

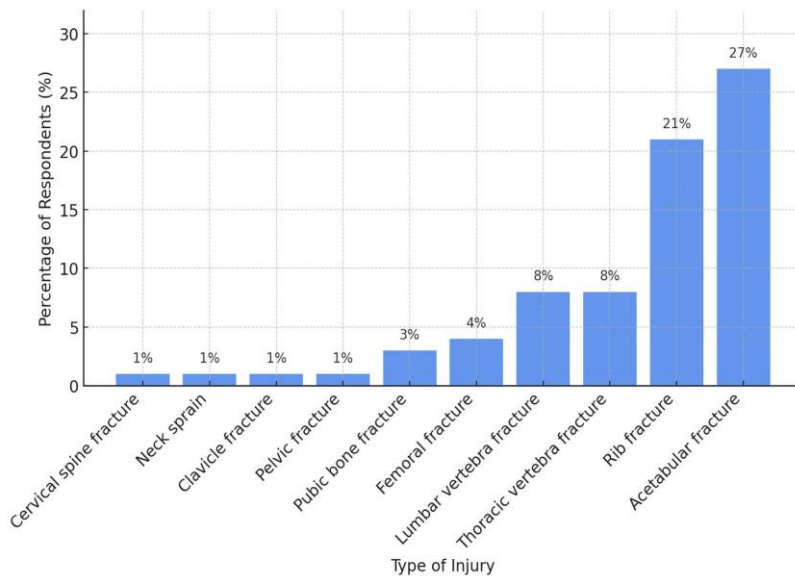
73% of male respondents and 27% of female respondents participated in the study.



**Chart 2.** Age distribution of respondents

The youngest respondent was 7 years old, and the oldest was 83. The median age of respondents was 49.4 years old. The largest number of respondents were in the age groups 60-69 and over 70, both groups 23%. There were 14% of respondents in

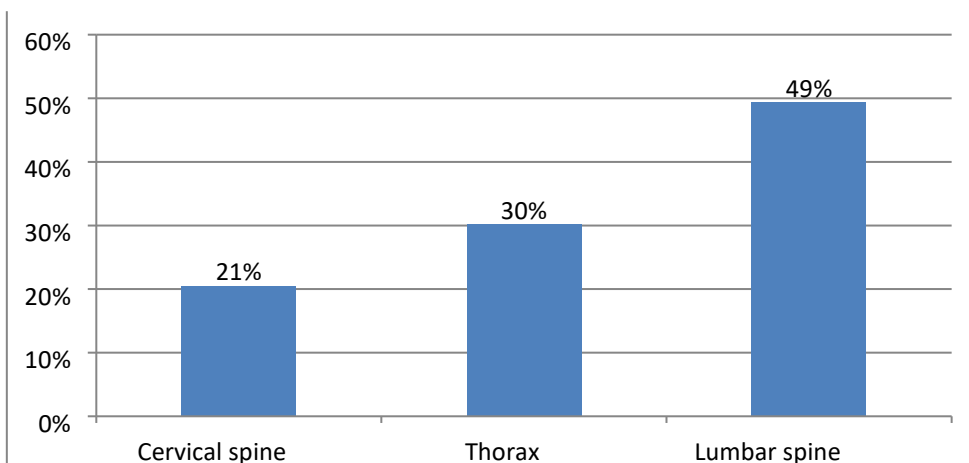
the age group 30-39, 12% each in the age groups 0-19 and 20-29. The age group 50-59 had 8% of the total number of respondents, and the smallest number was in the age group 40-49, 7%.



**Chart 3.** *Distribution of respondents by type of trauma*

The most common injury was a rib fracture, in 27% of the subjects, an

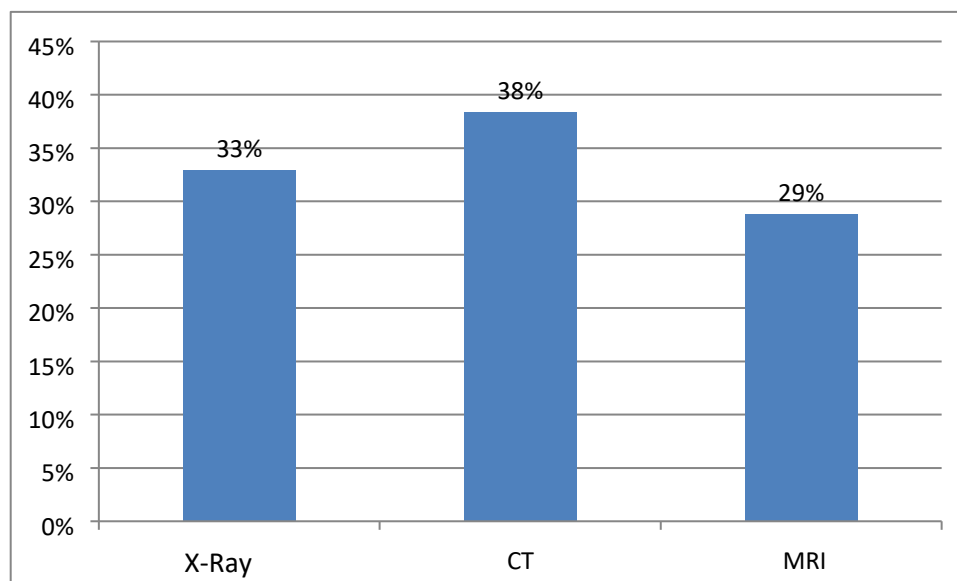
acetabular fracture in 23% of the subjects, and a cervical spine fracture in 21%.



**Chart 4.** *Distribution of respondents according to spinal injury*

Of the total number of respondents, 49% had a lumbar spine injury, 30% a thoracic

spine injury and 21% a cervical spine injury.



**Chart 5.** *Distribution of respondents by type of recording*

The most common type of imaging was CT, 38% 33% of respondents had X-ray imaging and 29% MRI imaging.

## DISCUSSION

Plain radiography is appropriate to obtain adequate radiographs in cases where the patient is at low risk of injury, CT will be skipped unless there is a risk of more serious injury, or in children. However, plain radiographs miss a significant proportion of injuries due to poor image quality, inadequacy as demonstrated by the lack of craniocervical and/or cervicothoracic junctions in the field of view, or inaccurate interpretation of the image by the clinician (10,11).

A study of 1577 trauma patients, where all patients underwent plain radiography in five views (anteroposterior, lateral, odontoid, and right and left oblique views) and helical CT scanning, showed that plain radiographs failed to identify 299/416 fractures (72%) detected on CT (12).

The growing evidence against plain radiography suggests that this option

should only be used in areas where CT is not available or in children where exposure to medium to high levels of ionizing radiation is contraindicated.

Where CT is not available, a high-quality five-view plain radiograph with visualization of all seven vertebrae, preferably reviewed by a radiologist, is recommended.

In a study of patients with minor injuries with normal neurologic status and CT findings, 21% of patients with persistent central cervical tenderness had a cervical disc/ligament injury detected on MRI that warranted clinical treatment with a cervical collar (18%) or operative stabilization (3%). Advanced cervical spondylosis was strongly associated with the severity of injury in these patients (13).

In addition to providing details of bony anatomy, CT scanning can detect significant soft tissue abnormalities such as traumatic disc herniations and significant epidural or subdural hematomas in the spinal canal. The trend toward the use of CT as the primary imaging modality is illustrated in a study by Shabaniya et al.

They conducted a study in six regions worldwide, and found that in neurologically intact patients with spinal trauma, CT was the predominant imaging modality for all regions (14).

CT imaging is not without its problems, and in addition, image acquisition artifacts such as metal artifacts, beam hardening, scattering, and ring artifacts can occur. A combination of advances in mathematics and technology has made it possible to reduce these artifacts. For example, photon-counting CT has been shown to reduce beam hardening artifacts while increasing spatial resolution. In addition, CT does not determine the severity of spinal cord injury, nor does it help to assess the prognosis of the injury (15).

MRI is currently considered the gold standard imaging modality for the evaluation of patients with spinal cord injury and spinal trauma (16).

MRI has multiplanar capabilities with high contrast resolution and can therefore provide information on spinal cord compression, ligamentous instability, disc herniation, contusions and hemorrhage as well as injuries to the vertebral bodies and paraspinal tissues (17).

In a review by Sliker et al. (2005) in patients with blunt trauma, the authors reported a 22.7% detection rate of ligamentous injury by MRI, of which 80.8% required treatment (18).

Despite the time required to perform MRI, it is still recommended in the pre- and postoperative phases when feasible. Not only is MRI considered safe, when protocols are followed, it also directly influences the clinical decisions of the surgeon (19).

The main disadvantage of MRI imaging is the time it takes to obtain the scan.

## CONCLUSION

The youngest respondent was 7 years old, and the oldest was 83 years old. The average age of respondents was 49.4 years old. The largest number of respondents was in the age groups 60-69 and over 70 years old, both groups 23%. There were 14% of respondents in the age group 30-39 years, 12% each in the age groups 0-19 and 20-29 years. The age group 50-59 years had 8% of the total number of respondents, and the smallest number was in the age group 40-49 years, 7%.


The most common injury was a rib fracture, in 27% of the subjects, an acetabular fracture in 23% of the subjects, and a cervical spine fracture in 21%. Of the total number of subjects, 49% had a lumbar spine injury, 30% a thoracic injury and 21% a cervical spine injury. The most common type of imaging was CT, 38% 33% of the subjects had an X-ray and 29% an MRI.

## REFERENCES

1. Keros P, Pećina M. *Funkcijska anatomija lokomotornog sustava*. Naklada Ljevak. Zagreb. 2006.
2. Krmpotić-Nemanić J. *Anatomija čovjeka*. Medicinska naklada. Zagreb. 2007.
3. Riascos R, Bonfante E, Cotes C, Guirguis M, Hakimelahi R, West C. Imaging of atlanto-occipital and atlantoaxial traumatic injuries: what the radiologist needs to know. *Radiographics*. 2015;35(7):2121–34.
4. Van Goethem JW, Maes M, Özsarlak Ö et al. Imaging in spinal trauma. *Eur Radiol*. 2005;15(3):582–90.
5. Hogan GJ, Mirvis SE, Shanmuganathan K, Scalea TM.

- Exclusion of unstable cervical spine injury in obtunded patients with blunt trauma: is MR imaging needed when multi-detector row CT findings are normal? *Radiology*. 2005;237:106–13.
6. Lee JY, Vaccaro AR, Lim MR, et al. Thoracolumbar injury classification and severity score: a new paradigm for the treatment of thoracolumbar spine trauma. *J Orthop Sci*. 2005;10(6):671–5.
  7. Sarrami P, Armstrong E, Naylor JM, Harris IA. Factors predicting outcome in whiplash injury: a systematic meta-review of prognostic factors. *J Orthop Traumatol*. 2017;18:9–16.
  8. Boban J, Thurnher MM, Van Goethem JW. Spine and spinal cord trauma. In: Barkhof F, et al., editors. *Clinical neuroradiology*. Cham: Springer; 2018.
  9. Stabler A, Eck J, Penning R, et al. Cervical spine: postmortem assessment of accident injuries – comparison of radiographic, MR imaging, anatomic, and pathologic findings. *Radiology* 2001;221:340–6.
  10. Diaz JJ Jr., Gillman C, Morris JA Jr., May AK, Carrillo YM, Guy J. Are fiveview plain films of the cervical spine unreliable? A prospective evaluation in blunt trauma patients with altered mental status. *J Trauma* 2003;55:658–63.
  11. Diaz JJ Jr., Aulino JM, Collier B, et al. The early work-up for isolated ligamentous injury of the cervical spine: does computed tomography scan have a role? *J Trauma* 2005;59:897–903.
  12. Ackland HM, Cameron PA, Varma DK, et al. Cervical spine magnetic resonance imaging in alert, neurologically intact trauma patients with persistent midline tenderness and negative computed tomography results. *Ann Emerg Med* 2011;58:521–30.
  13. Shabani S, Kaushal M, Soliman HM, Nguyen HS, Aarabi B, Fehlings MG, Kotter M, Kwon BK, Harrop JS, Kurpad SN. AOSpine Global Survey: International Trends in Utilization of Magnetic Resonance Imaging / Computed Tomography for Spinal Trauma and Spinal Cord Injury across AO Regions. *J. Neurotrauma*. 2019;36:3323–3331.
  14. Edward Boas DF. CT artifacts: Cases and reduction techniques. *Imaging Med*. 2012;4:229–240.
  15. Magu S, Singh D, Yadav RK, Bala M. Evaluation of Traumatic Spine by Magnetic Resonance Imaging and Correlation with Neurological Recovery. *Asian Spine J*. 2015;9:748–756.
  16. Bondurant FJ, Cotler HB, Kulkarni MV, McArdle CB, Harris JH. Acute spinal cord injury. A study using physical examination and magnetic resonance imaging. *Spine*. 1990;15:161–168.
  17. Sliker CW, Mirvis SE, Shanmuganathan K. Assessing Cervical Spine Stability in Obtunded Blunt Trauma Patients: Review of Medical Literature. *Radiology*. 2005;234:733–739.
  18. Ghaffari-Rafi A, Peterson C, Leon-Rojas JE, Tadokoro N, Lange SF, Kaushal M, Tetreault L, Fehlings MG, Martin AR. The Role of Magnetic Resonance Imaging to Inform Clinical Decision-Making in Acute Spinal Cord Injury: A Systematic Review and Meta-Analysis. *J. Clin. Med*. 2021;10:4948.

## RADIOLOŠKA OBRADA TRAUME KRALJEŽNICE

Katarina Maljić<sup>1,2</sup>, Darko Tomić<sup>1,3</sup> , Tanja Pavlović<sup>1</sup>, Ivana Stojak<sup>1</sup>, Ana-Marija Kapetanović

<sup>1</sup> Fakultet zdravstvenih studija, Sveučilišta u Mostaru, 88 000 Mostar, Bosna i Hercegovina

<sup>2</sup> Ekonomski fakultet Sveučilišta u Mostaru, 88 000 Mostar, Bosna i Hercegovina

<sup>3</sup> Hrvatska bolnica "Dr. fra Mato Nikolić" Nova Bila, 72 276 Nova Bila, Bosna i Hercegovina

### SAŽETAK

Uvod: u liječenju bolesnika s traumom kralježnice slikovna snimanja imaju važnu ulogu. Do postavljanja konačne dijagnoze, prva metoda oslikavanja je rendgenska dijagnostika, zatim CT i u konačnici MRI dijagnostika za ozljede leđne moždine. Cilj ovog rada je istražiti kako radiološke metode mogu pomoći u preciznoj dijagnozi i praćenju pacijenata s ozljedom kralježnice, te koja je radiološko-dijagnostička metoda najučinkovitija.

Metodologija istraživanja: vrijeme prikupljanja podataka: od 1.1. 2023. do 1.1. 2024. godine na Sveučilišna klinička bolnica Mostar, Zavod za radiologiju. Ispitanici su pacijenti s traumom kralježnice koji su upućeni na radiološku obradu SKB Mostar u spomenutom vremenskom periodu.

Rezultati: najmlađi ispitanik imao je 7 godina, a najstariji 83 godine. Srednja dob ispitanika je 49,4 godine. Najviše ispitanika nalazilo se u dobnim skupinama 60-69 i starijih od 70 godina, obje skupine po 23%. Najčešća ozljeda bila je prijelom rebara, kod 27% ispitanika, prijelom acetabula imalo je 23% ispitanika, te prijelom vratne kralježnice njih 21%. Od ukupnog broja ispitanika, 49% imalo je ozljedu lumbalne kralježnice, 30% ozljedu grudnog koša i 21% ozljedu vratne kralježnice. Najčešća vrsta snimanja bio je CT, 38% 33% ispitanika imalo je RTG snimanje i 29% MR snimanje.

Zaključak: CT je prvi modalitet snimanja zbog svoje brze i jednostavne akvizicije i visoke osjetljivosti za otkrivanje prijeloma kostiju. Nove tehnologije u području CT-a, posebice DECT i CT s brojanjem fotona, uspjele su povećati osjetljivost za otkrivanje traume kralježnice. MRI pruža detaljne informacije o ligamentima, mekim tkivima, disku i leđnoj moždini.

**Ključne riječi:** trauma kralježnice, radiološka dijagnostika

Autor za korespondenciju: mr. sc. Darko Tomić; [darkotomic@hotmail.com](mailto:darkotomic@hotmail.com)