



ENDOSCOPIC RECTAL ULTRASOUND IN RECTAL ADENOCARCINOMA STAGING: CAN A SURGEON RELY ON ENDOSCOPIC FINDINGS BEFORE THE SURGERY? – COMPARISON WITH POSTOPERATIVE PATHOLOGICAL DIAGNOSIS

Melanija Ražov Radas¹ and Nataša Lisica Šikić²

¹Division of Gastroenterology, Department of Internal Medicine, Zadar General Hospital, Zadar, Croatia;

²Department of Pathology, General Hospital Zadar, Croatia

SUMMARY – Our aim in this study was to demonstrate the usefulness of endoscopic rectal ultrasound scan (ERUS) in providing information that can help surgeons decide on therapeutic approach and type of surgical procedure in patients with rectal cancer. We compared ERUS findings with postoperative pathological data in 41 patients with endoscopic and pathological (PH) diagnosis of rectal cancer. These patients underwent ERUS examination to determine the extent of the disease and the findings were subsequently compared with postoperative pathological diagnosis. After ERUS examination, there were three patients in group T0, five in group T1, 12 in group T2, 17 in group T3, two in group T4, and two patients had a mucinous metastatic type of cancer. After excluding 15 patients who met the exclusion criteria, we compared ERUS findings of 26 patients with their pathological diagnosis to determine the sensitivity and accuracy of ERUS. The total sensitivity of the ERUS in preoperative staging of the tumor stage T0-T4 was 96%. Accuracy was 89%. This study showed that a surgeon can rely on the findings of ERUS performed by an experienced endoscopist before deciding of type of surgical procedure for T0-T2, and even T3 degree of rectal cancer. T3 rectal cancers are in the “gray zone”, so both procedures, ERUS and nuclear magnetic resonance imaging (NMR), are needed to decide on the final therapeutic approach. NMR remains the gold standard for staging T4 rectal cancer.

Keywords: *ERUS; NMR; PH diagnosis; Colorectal adenocarcinoma; Sensitivity; Surgical procedure*

Introduction

The incidence of colorectal cancer is around 40-44/100,000 (55.5/100,000 in the Republic of Croatia) per year in both sexes. In the period of 2017-2019, approximately 23,720 new cases of rectal cancer were diagnosed in men (23%) and 16,190 in women (16%) in the United States (1). Mortality from rectal cancer is around 14.8 per 100,000 inhabitants, whereas the 5-year survival is 64.9% (2).

In Croatia in 2015, the incidence of rectal, rectosigmoid, and anal cancers was 7% in men and 5% in women (3). The total number of newly diagnosed patients with invasive cancers (all sites, excluding skin

Correspondence to: *Melanija Ražov Radas*
Division of Gastroenterology, Department of Internal Medicine
Zadar General Hospital, Bože Peričića 5, 23000 Zadar, Croatia
E-mail: melanijarr@gmail.com;
melanija.razov.radas@bolnica-zadar.hr

Received December 10, 2020, accepted October 11, 2021

cancer) was 22,503 (11,969 in men and 10,534 in women). The incidence rate was 535,3/100,000 in men and 484,3/100,000 in women, with the men-to-women ratio of 53:47. The colon, rectum, and anus have a common incidence of 16% in men and 13% in women. In Croatia, 14,012 people (8030 men and 5982 women) died of cancer in 2015 despite the national early cancer detection program. Mortality rates were 333,3/100,000 (men) and 278,0/100,000 (women), with the men-to-women ratio of 57:43 (3).

The incidence of colorectal cancer is higher in affluent, western countries due to the lifestyle and influence of environmental factors, which can be prevented (4). Anal cancer is closely related to the sexually transmitted infection of human papillomavirus type 16 and 18 (HPV). Most cases of anal cancer develop in people aged over 55, and one-third develops in younger people. Pelizzer T *et al.* (5) performed a systematic review with meta-analysis to assess the association between HPV infection and rectal cancer and confirmed that the two were connected, with no difference between the sexes and with similar values for HPV 16 and HPV 18. Preoperative workup in rectal cancer includes nuclear magnetic resonance (NMR) imaging of the pelvic region, especially in T3 and T4 stages of the disease, and endorectal ultrasound (ERUS) scan proved equally accurate in T1 and T2 stages (6). The presence of a stenotic tumor was the only parameter significantly related to a poorer performance of ERUS in N staging.

Endoscopic ultrasound (EUS) is now well established as an important tool in clinical practice. From purely diagnostic imaging, it has progressed to include tissue acquisition which provided the basis for therapeutic procedures. Even as interventional EUS developed, there has been ongoing progress in EUS diagnostic capabilities due to improved imaging systems, better needles for tissue acquisition and development of enhanced imaging functions such as contrast-enhanced harmonic EUS (CH-EUS) and EUS elastography. EUS can be performed using either radial or linear echo-endoscopes. The former provides imaging with a 360° view like computed tomography (CT), while the latter provides a narrower sector longitudinal imaging, which is important for real-time tracking of a puncture needle crucial for EUS-guided interventions (7).

Stephen Hasak *et al.* (8) concluded that ERUS continues to be an important modality for evaluation of benign and malignant disorders of the lower gastrointestinal tract, although its use as a cancer staging modality has declined due to improvements in MRI technology. Various technologies to enhance ultrasound imaging and for therapeutics have been developed that have or may contribute to expanded indications for rectal EUS.

Patients and methods

In Croatia, endoscopic ultrasound (EUS) is performed in five University Hospital Centers and our hospital, General Hospital Zadar. About 170,000 people gravitate to General Hospital Zadar.

In the period from June 2013 to March 2018, around 1000 EUS examinations were performed at our hospital, including 41 ERUS examinations in patients with rectal carcinoma.

In our study, we included patients who met the inclusion criteria as follows: aged 18 years and older, have proven rectal adenocarcinoma (colonoscopy and pathological findings), have not undergone previous surgery and/or preoperative radiation and chemotherapy, and were planned to undergo surgery at our hospital. We excluded patients who met the exclusion criteria, i.e., who were under the age of 18, who underwent radiation and/or chemotherapy prior to surgery, who were undergoing surgery at an external institution, and who had a tumor other than adenocarcinoma.

Of 41 eligible patients with rectal cancer confirmed by colonoscopy and pathology. After ERUS examination, three of 41 patients were in group T0, five in group T1, 12 in group T2, 17 in group T3, two in group T4, and two patients had mucinous metastatic type of cancer. We excluded 8 patients who were operated on in other institutions because we could not obtain the pathologist's findings after surgery, 5 patients who underwent preoperative radiation and chemotherapy because the PH finding is different than PH before radiation and chemotherapy so comparison between the second PH and first ERUS is not adequate, and 2 patients with metastatic mucinous cancer. Thus, only 26 patients were analyzed.

The median age of these 26 patients was 63.5 years (range: 40-83 years). There were 16 men and 10 women.

These patients underwent preoperative ERUS staging using PENTAX linear probe. After the therapy protocol (surgery, chemotherapy, irradiation), their ERUS findings were compared with their pathological diagnosis to determine the ERUS sensitivity and accuracy.

Statistical analysis

To analyze the data, we used Wilcoxon signed-rank test, contingency test, Kendall's tau correlation coefficient, and negative predictive value.

Results

The ERUS sensitivity was defined as the ability of the test to identify correctly patients with the disease. ERUS and PH findings matched in 96% of all cases that we examined. ERUS sensitivity was thus 96%.

Table 1. Sensitivity of endoscopic rectal ultrasound (ERUS)

		Test 2 (PH)		
		Ill (T=1,2,3,4)	Healthy (T=0)	total
Test 1 (ERUS)	Positive	23	3	26
	Negative	1	2	3
	total	24	5	

Positive = tumor stages T1-T4; Negative = tumor in situ;
 PH = pathological diagnosis
 Sensitivity = $23/(23+1) = 23/24 = 0.958$.

Accuracy of the test was defined as the number of correctly diagnosed patients among the total number of patients. Thus, the ERUS accuracy was = $23/26 = 0.884$.

Table 2. Contingency test for spread of the tumor to the lymph nodes

		Test 2 (PH)		
		Positive	Negative	total
Test 1 (ERUS)	Positive	3	6	9
	Negative	0	14	14
	total	3	20	

ERUS = endoscopic rectal ultrasound; PH = pathological diagnosis; Sensitivity = $3/(3+0)=3/3 = 1$.

Using Wilcoxon signed-rank test (two-tailed), we found that tumor size measured during ERUS and on pathological examination were not significantly different ($z = 0.707$).

The correlation between ERUS findings and pathological examination results was examined with Kendall's tau correlation coefficient (used when there is a large number of bound ranks). The result was 0.82 ($p < 0.01$).

Discussion

We demonstrated, albeit on a small sample of patients, that ERUS in the hands of an experienced endoscopist can be used to determine the size of tumor and degree of its penetration through the bowel wall with great certainty regarding the accuracy of the finding. This provides strong confidence when discussing local disease spread with surgeons and helps them determine the appropriate type of surgery. The final result is extremely important for therapeutic approach (Fig. 1).

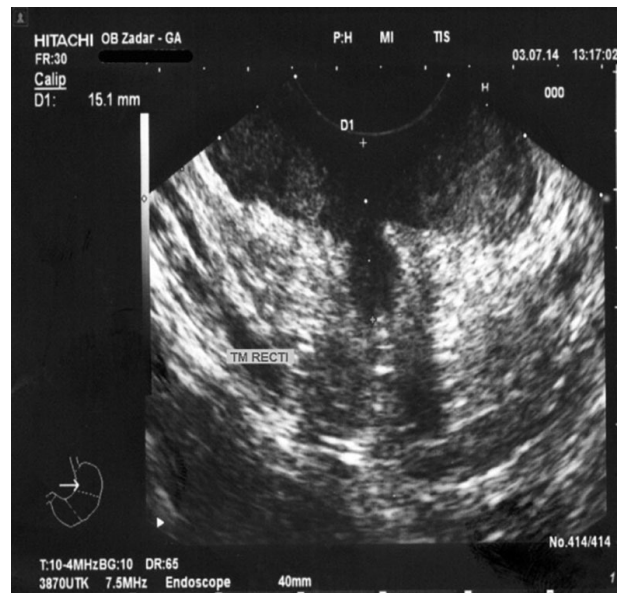

Fig. 1. Endoscopic rectal ultrasound (ERUS) findings in 64-year-old woman: tumor penetrates through all rectal wall layers and into the perirectal fatty tissue (T3N0). Postoperative pathological diagnosis confirmed the penetration into all layers and subserosa (pT3N0M0).

Accurate staging of rectal cancer is essential for selecting patients who can undergo sphincter-preserving surgery, and ERUS provides many advantages in that respect. In addition, it is non-invasive and reproducible, the procedure itself does not last long, and the patient preparation is not demanding. Therefore, ERUS has become an important part of the diagnostic algorithm for rectal cancer and the standard of care as it allows for identification of patients who require preoperative neoadjuvant therapy (9).

ERUS has limitations, which need to be considered. It cannot estimate vascular invasion (mucinous tumors) (Fig. 2), differentiate benign lesion from malignant one without using elastography or CETRUS (contrast-enhanced transrectal ultrasound), distinguish hypoechoic inflammatory response of the surrounding tissue from the extension of the primary process, and estimate tumor microinvasion into the next layer.

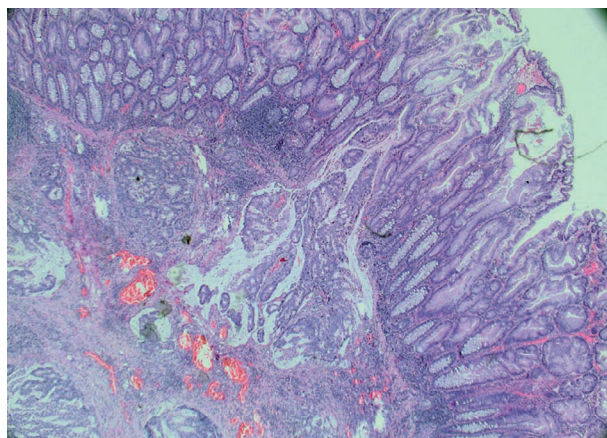


Fig. 2. Mucinous carcinoma recti (staining: hemalaun-eosin, 10').

However, ERUS is the best method for local T1-T2 staging of rectal cancer. It seems to improve disease-free survival because ERUS facilitates the appropriate selection of patients for neoadjuvant therapy. The use of ERUS has also increased the number of sphincter-preserving surgeries performed in patients

with rectal cancer. In comparison with MRI, Haddad *et al* (10) find NMR better for locally advanced tumors (T3/T4). Rectal cancer staging with ERUS or NMR is not accurate in patients who have received neoadjuvant therapy. NMR is the most useful staging tool for determining the status of the circumferential resection margin, which is important in the assessment of the risk of local recurrence. Cost-benefit analysis shows significant savings in performing ERUS compared to NMR, which is extremely expensive, time-consuming, unsuitable for patients with metal implants, and often has long waiting times.

This study showed that ERUS of the rectal region may be considered equally valuable as NMR in the interpretation of the disease propagation.

Conclusion

In our study, we demonstrated that ERUS has high sensitivity in estimating the tumor penetration through the rectal wall and perirectal tissues. It is ideal for preoperative T1 and T2 staging but may also be useful in T3 staging if performed by an experienced endoscopist. It is essential for the assessment of the need for neoadjuvant radiotherapy or endoscopic therapy, such as endoscopic submucosal dissection (ESD), and may be considered equally valuable as NMR in the interpretation of the disease propagation. It is also ideal for postoperative monitoring and follow-up after radiotherapy. Our study also showed that an experienced endoscopist can determine, with certainty, the tumor size and degree of tumor penetration through the bowel wall, so the surgeon can rely on these endoscopic findings when deciding on the type of surgical procedure for T0-T2, and even T3 rectal cancer. This does not minimize the importance of NMR imaging, but simplifies the procedure for the patient. Any patient can undergo preoperative ERUS. Still, NMR remains the gold standard for T4 staging of rectal cancer.

Conflict of Interest: The author declares that she has no conflict of interest.

References

1. American Cancer Society (2017) Colorectal cancer facts & figures 2017-2019. Available from: <https://www.cancer.org/content/dam/cancer-org/research/cancer-facts-and-statistics/colorectal-cancer-facts-and-figures/colorectal-cancer-facts-and-figures-2017-2019.pdf>. Accessed: 2 March 2018.
2. CA: A Cancer Journal for Clinicians. Colorectal cancer statistics, 2014. National Cancer Institute, Surveillance, Epidemiology, and End Results program. Available from: seer.cancer.gov
3. Šekerija M. Cancer incidence in Croatia, Bulletin No. 40. 2015.
4. Jonson IT, Lund EK. Review article: nutrition, obesity and colorectal cancer. *Aliment Pharmacol Ther.* 2007;26(2):161-81.
5. Pelizzer T, Pieta Dias C, Poeta J, Torriani T, Roncada C. Colorectal cancer prevalence linked to human papillomavirus: a systematic review with meta-analysis. *Rev Bras Epidemiol.* 2016;19(4):791-802.
6. Fernanadez-Esparrach G, Ayuso-Colella JR, Sendino O, Pages M, Coatrecases M, Maurel J, et al. EUS and magnetic resonance imaging in the staging of rectal cancer: a prospective and comparative study. *Gastrointes Endosc.* 2011;74(2):347-54. doi:10.1016/j.gie.2011.03.1257.
7. Ang TL, Kwek ABE, Wang LM. Diagnostic endoscopic ultrasound: technique, current status and future directions. *Gut Liver* 2018;12(5):483-96.
8. Hasak S, Kushnir V. Rectal endoscopic ultrasound in clinical practice. *Curr Gastroenterol Rep* 2019 Apr 12;21(4):18.
9. Harewood GC, Wiersema MJ. Cost-effectiveness of endoscopic ultrasonography in the evaluation of proximal rectal cancer. *Am J Gastroenterol.* 2002;97:874-82. doi:10.1111/j.1572-0241.2002.05603.x
10. Haddad GN. Staging of rectal cancer: MRI versus endoscopic ultrasound [slide presentation] Alpharetta, GA: Imedex, LLC; 2009. Available from: http://www.imedex.com/appresources/pdf/presentations/a108slides/Haddad_1355_for_website.pdf. Accessed: 2 March 2018.

Sažetak

ULOGA ENDOSKOPSKOG ULTRAZVUKA REKTALNE REGIJE U ODREĐIVANJU STADIJA REKTALNOG ADENOKARCINOMA: MOŽE LI SE KIRURG PREOPERATIVNO OSLONITI NA ENDOSKOPSKI NALAZ? – USPOREDBA S POSTOPERATIVNOM PATOLOŠKOM DIJAGNOZOM

M. Ražov Radas i N. Lisica Šikić

Ovim se ispitivanjem pokušala dokazati korist endoskopskog ultrazvuka rektalne regije (ERUZ) kod oboljelih od karcinoma rektuma na odluku o terapijskom pristupu i vrsti kirurškog postupka. Uspoređeni su nalazi ERUZ-a s postoperativnom patološkom dijagnozom, gdje je jasno prikazan prodor tumora kroz slojeve rektuma. ERUZ-om je pregledan 41 bolesnik kako bi se odredio prodor tumora kroz stijenu. Naknadno je učinjena usporedba ERUZ-a s postoperativnim patološkim nalazima. Na temelju nalaza ERUZ-a, tri su bolesnika bila u skupini T0, pet u skupini T1, 121 u skupini T2, 17 u skupini T3, dva u skupini T4, a dva su imala mucinozni metastatski tip karcinoma. Dio bolesnika je operiran izvan naše ustanove i stoga nije uključen u ispitivanje. Bolesnici koji su primili kemoterapiju i prošli protokol zračenja prije operacije također su bili isključeni. Konačno je uspoređeno 26 nalaza ERUZ-a s patološkom dijagnozom kako bi se utvrdila osjetljivost i točnost ERUZ-a. Ukupna osjetljivost ERUZ-a za sve tumore (stadij T0-T4) iznosila je 96%. Točnost je bila 89%. Ovim istraživanjem dokazano je da se kirurg može osloniti na nalaz iskusnog endoskopičara prije nego što odluči o vrsti kirurškog zahvata posebno za tumore stadija T0-T2, pa čak i tumore rektuma stadija T3. Međutim, tumori T3 stadija se nalaze u "sivoj zoni", tako da nam je za konačni terapijski pristup osim ERUZ-a potrebna nuklearna magnetska rezonancija (NMR). NMR ostaje zlatni standard za T4 stadij karcinoma rektuma..

Ključne riječi: ERUZ; NMR; PH dijagnoza; Rektalni adenokarcinom; Osjetljivost; Kirurški postupak