



# EVALUATION OF ULTRASOUND AS AN IMAGING MODALITY IN THE ASSESSMENT OF CAROTID ARTERY INVASION IN PATIENTS WITH HEAD AND NECK CANCER

Tijana Pandurović<sup>1</sup>, Damir Štimac<sup>1,2</sup>, Tajana Turk<sup>2,3</sup>, Siniša Pešić<sup>3</sup>, Vedran Zubčić<sup>4,5</sup>,  
Matea Bogović<sup>1</sup>, Nenad Čekić<sup>6,7,8</sup> and Luka Šimić<sup>9</sup>

<sup>1</sup>Department of Radiology, Vukovar National Memorial Hospital, Vukovar, Croatia;

<sup>2</sup>Department of Radiology, Faculty of Medicine, Josip Juraj Strossmayer University of Osijek, Osijek, Croatia;

<sup>3</sup>Department of Interventional and Diagnostic Radiology, Osijek University Hospital Center, Osijek, Croatia;

<sup>4</sup>Department of Otorhinolaryngology and Maxillofacial Surgery, Faculty of Medicine, Josip Juraj Strossmayer University of Osijek, Osijek, Croatia;

<sup>5</sup>Department of Maxillofacial and Oral Surgery, Osijek University Hospital Center, Osijek, Croatia;

<sup>6</sup>Department of Anatomy and Neuroscience, Faculty of Medicine, Josip Juraj Strossmayer University of Osijek, Osijek Croatia;

<sup>7</sup>Department of Anatomy, Histology, Embryology, Pathologic Anatomy and Pathologic Histology, Faculty of Dental Medicine and Health, Josip Juraj Strossmayer University of Osijek, Osijek, Croatia;

<sup>8</sup>Department of Surgery, Vukovar National Memorial Hospital, Vukovar, Croatia;

<sup>9</sup>Faculty of Electrical Engineering, Computer Science and Information Technology of Osijek, Osijek, Croatia

**SUMMARY** – Tumor invasion of carotid arteries (CA) is found in 2%-7% of patients with head and neck cancer (HNC). There are no standardized criteria to evaluate the invasion. Tumor invasion of CA is assessed by using computerized tomography (CT) and magnetic resonance imaging. Ultrasound was also used but the method has not become daily routine. The aim of this study was to examine the effect of tumor invasion on CA dynamics and to evaluate the role of ultrasonography in the diagnosis of invasion. The study was conducted on two groups of 22 patients each. The first group consisted of patients with confirmed HNC and CA infiltration, while the second group consisted of patients without any data of HNC. Motion of the CA wall was assessed using ultrasound from which a CA was segmented and then the amount of motion was assessed by optical flow calculation. All patients with a CT-verified CA infiltration had an altered CA motion. The research showed that tumor-infiltrated CA had an altered dynamic when viewed on ultrasound.

**Keywords:** *Head and neck cancer; Carotid artery invasion; Optical flow; Segmentation; Ultrasound*

---

Correspondence to: *Tijana Pandurović, MD*, Department of Radiology, Vukovar National Memorial Hospital, Županijska ulica 35, HR-32000 Vukovar, Croatia  
E-mail: [tijana.pandurovic@gmail.com](mailto:tijana.pandurovic@gmail.com)

Received July 10, 2023, accepted July 21, 2023

## Introduction

Head and neck cancers (HNCs) are a heterogeneous tumor group that accounts for 3% of malignancies<sup>1</sup>. According to the EURO CARE-5 population-based study, approximately 250 000 cases of HNC and 63 500 deaths occur annually in Europe<sup>2</sup>. HNCs are associated with a significant reduction in the quality of life because they spread to parts of the body used for breathing, speaking, and swallowing. At the time of diagnosis, most patients are in an advanced stage of the disease, so the mortality rate is high<sup>3,4</sup>. The 5-year survival rate is around 50%<sup>3,5</sup>.

The status of carotid arteries (CA) is of great importance in determining the stage of the disease and deciding upon the choice of treatment<sup>6</sup>. Tumor invasion of the CA is a significant prognostic factor and correlates with a poor prognosis<sup>7,8</sup>. Diagnosing carotid wall invasion is especially challenging because the rate of inaccuracy of the invasion prediction by clinical examination is up to 63%<sup>6</sup>. Deep neck fascia surrounding the CA and CA pulsatility delay the infiltration<sup>9</sup>. The infiltration is related to poor prognosis because of the possibility of occlusion and bleeding when the cancer erodes through the wall, as well as the rapid disease progression characterized by such an advanced cancer<sup>10</sup>.

To date, no standardized criteria exist for CA wall invasion assessment, and studies have produced conflicting results<sup>10-17</sup>. Various parameters have been observed such as CA compression, tumor surrounding more than 180° of the wall circumference, length of contact between the tumor and CA, ill-defined wall, fat obliteration between the CA and the tumor, and CA displacement<sup>7,12</sup>. Observing only one parameter is not predictive of the invasion<sup>7,12,14,18,19</sup>. In contrast, some authors have reported that combining parameters with computerized tomography (CT) and magnetic resonance imaging (MRI) suggest an invasion<sup>7,9,16</sup>.

In studies that applied ultrasound as a method of assessing carotid artery invasion, morphological characteristics of the CA wall or the relationship with the surrounding structures were observed<sup>20,21</sup>. Several studies have reported that tumor invasion creates focal hypoechogenicity of the wall<sup>22-25</sup>. The application of

ultrasound in assessing CA invasion as a standalone method has not become common practice despite its availability, simplicity, low price, and absence of harmful effects on patients.

To our best knowledge, the CA wall dynamics using ultrasound has not been observed in the assessment of tumor invasion. The aim of this study was to evaluate the role of ultrasonography in the diagnosis of HNCs. We hypothesized that weakened movement or lack of CA movement could suggest its invasion. Because no standardized and validated criteria exist, assessment of CA invasion is still challenging and not reliable enough.

## Material and Methods

### Study design

We performed a case-control study that included 44 patients who were treated at the Osijek University Hospital Center from July 2020 to May 2022. The patients were divided into 2 groups. The first group consisted of 22 patients with confirmed malignant disease of the head and neck. The second group was a control group with 22 patients without clinically and diagnostically evident malignant head and neck disease. All patients were informed about the research and signed informed consent forms. Patient data were deidentified before analysis. The research was approved by the Ethics Committee of the Osijek University Hospital Center and Faculty of Medicine, Josip Juraj Strossmayer University of Osijek.

The inclusion criteria for patients in the first group were as follows: primary, nonrecurrent HNC without previous radiation therapy or chemotherapy; metastases in cervical lymph nodes confirmed by fine needle aspiration; and preoperative non-contrast and contrast-enhanced CT of the neck where an HNC, metastatically altered lymph node of the neck, and CA infiltration was described. The inclusion criteria for patients in the second group required they had no clinically and diagnostically obvious malignant tumor of the head and neck; and referral to neck CT scan for any reason other than HNC. Measurements were performed by two independent investigators.

### **Baseline demographic data**

Basic demographic data such as age and gender, as well as medical history and radiologic and cytologic findings, were collected. All patients underwent an ultrasound examination of the neck, focusing on their carotid arteries and metastatic lymph nodes.

### **Ultrasound protocol**

A linear probe with a frequency of 9 MHz (a Logiq E9 device) was used for ultrasound imaging of the CA and metastatic lymph node with a short video recording. Patients were in supine position during the examination, with their neck extended and head laterally rotated opposite to the side of the neck being examined. Axial slices in B mode were made. Both sides of the neck were examined to identify malignantly altered lymph nodes that had been defined based on predictive ultrasonic criteria, as follows: a round shape, irregular edges, hypoechoic or heterogeneous interior, absence of the central hilus, and peripheral nodal vascularity<sup>26-31</sup>. Then, the CA wall motion next to the metastatic lymph node was monitored, and a video recording was made. Whether the motion of the CA wall had altered (i.e., reduced or absent wall movement) was assessed. In the case of altered wall movement, the percentage of the wall with reduced or absent motion was estimated.

### **Image analysis**

Digital Imaging and Communications in Medicine data obtained with an ultrasound procedure must first be preprocessed. Each video has a defined size of 250 images. The data preprocess includes trimming the input data. The input images obtained by ultrasound devices often contain other information embedded in images (e.g., date, device information, and image scale) that must be removed because it might skew the optical flow calculation. Following this step, manual segmentation was done using the open-source 3D Slicer (version 4.11) segmentation software. The segmentation was done manually by a radiologist, segmenting the regions of interest, in this case, the CA.

A blurring step was performed on the given input image series because they contained high-frequency noise that negatively affects the optical flow calculation. Blurring was also performed on the segmentations

to provide smoother transitions between individual frames and to remove the outliers in the data because the segmentations are done manually. The input image series was blurred using a gaussian filter, with the kernel size being 2% of the input image diagonal, whereas the segmentations were blurred using a median filter with the same size.

Image stabilization was done in such a way that the area around the vessel segmentation remained mostly static as the movement of the vessel area through the surrounding tissue was observed. Image stabilization was performed by extracting the features in 2 consecutive frames<sup>32</sup> from the region of the image not containing the vessel. The mask was generated by dilating the vessel segmentation by 5% of the image diagonal.

The motion was estimated by tracking the extracted features using the Lucas-Kanade optical flow<sup>33</sup>. The affine transformation between the 2 consecutive frames was determined by finding the optimal transformation using a least median method. Finally, the transformations for each frame were computed as a cumulative sum of transformations for all previous frames and smoothed using a rolling average filter.

From the vessel segmentation, we extracted the region of interest using dilation and erosion filters with the size corresponding to 1% of the image diagonal. Therefore, this region of interest corresponded to the area around the outline of the vessel, spanning both inwards and outwards. Another reference mask was computed from the segmentation by dilating it for 10% of the image diagonal. The metric used to determine whether a pixel was under the influence of tumor infiltration was the length of the optical flow vector for each pixel in the image series. The optical flow vectors were computed *per* frame, using the Gunnar-Farneback algorithm<sup>34</sup>. Because optical flow can be sensitive to noise, a rolling average was used as a metric and was computed using the next and previous 10% of available frames. Once the optical flow values were computed, a reference value was calculated as the average value of the pixels within the reference mask. Then, the value of optical flow for each pixel within the vessel surface mask was compared against the reference mask. If the value was smaller than the reference, then the pixel in question experienced less movement than the reference and was considered to

have been infiltrated by the tumor. In the same way, if the value at a specific pixel was higher than the reference, then it was not considered to have been infiltrated.

In addition, the regions of the artery wall that were or were not infiltrated were graphically indicated within the data. The analysis was done *via* programming languages and programming libraries for image processing, Python (version 3.9.13) and Open CV (Open Source Computer Vision Library)<sup>35,36</sup>.

#### Statistical analysis

Categorical data were expressed as absolute and relative frequencies. Difference in category variables was tested by the Fisher exact test. The normality of numerical variable distribution was tested with the Shapiro-Wilk test, and due to non-normal distribution, data were described by median and interquartile range. The Mann-Whitney U test was used to test differences in continuous variables between the control group and the malignant head and neck tumor group (Hodges-Lehman difference of the median, with a 95% confidence interval (CI)). The Wilcoxon test (Hodges-Lehman difference between medians, with a 95% CI) was used to test differences in continuous variables according to groups (ultrasound combined

with optical flow *vs.* ultrasound infiltration). All p values were 2-sided. The level of significance was set to  $\alpha=0.05$ . MedCalc Statistical Software (version 20.218) and SPSS (version 23) were used on data analysis.

#### Results

The research was conducted on 44 patients, of which 22 (50%) were in the control group. Of the 44 patients, 35 (79%) were male and 9 (21%) were female, with no significant difference between the groups. All 22 patients with HNC had an infiltrated CA on CT (Fig. 1). Control group patients were statistically significantly younger than those with HNC (63 *vs.* 70 years; Mann-Whitney U test,  $p=0.03$ ). The percentage of infiltration estimated by the calculation of optical flow on ultrasound images was significantly higher among HNC patients compared to the control group (Mann-Whitney U test,  $p<0.001$  (Table 1, Fig. 2). There were no significant differences between the ultrasound infiltration findings assessed by the radiologist and the infiltration assessed by the calculation of optical flow (%) on ultrasound images (Wilcoxon test,  $p<0.001$  (Table 2).

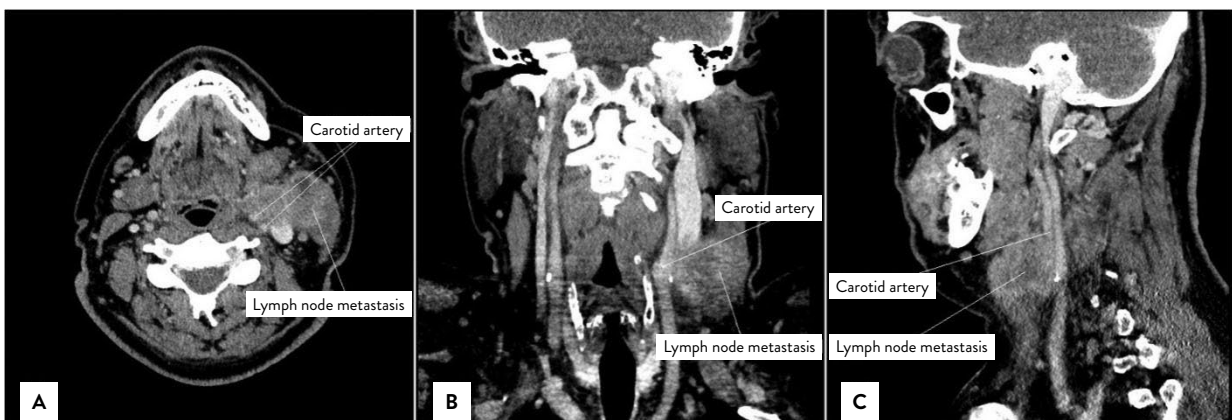


Fig. 1. Contrast enhanced computed tomography scans of neck cancers showing extensive lymphadenopathy and carotid artery invasion: (a) axial view; (b) coronal view; (c) sagittal view.

Table 1. Differences in age and infiltration according to groups

	Median (interquartile range)		Difference (95% CI)	P*
	Control group	HNC patients		
Age (years)	63 (57-71)	70 (64-78)	7 (1-12)	<b>0.02</b>
Ultrasound infiltration/ optical flow				
No infiltration (px)	217361 (174607-319274)	605352.5 (410017-954244)	346108 (203753-542062)	<b>&lt;0.001</b>
Infiltrated (px)	8844.5 (1306-16600)	209685 (71726-336766)	200732 (71726-319892)	<b>&lt;0.001</b>
No infiltration (%)	95.67 (93.87-99.34)	76.14 (61.67-91.47)	-20.52 (-28.86 to -8.53)	<b>&lt;0.001</b>
Infiltrated (%)	4.03 (0.66-6.13)	23.86 (8.53-38.33)	20.5 (8.53-28.86)	<b>&lt;0.001</b>
Ultrasound infiltration/ radiologist (%)	0 (0-0)	20 (20-30)	20 (20-25)	<b>&lt;0.001</b>

\*Mann Whitney U test; HNC = head and neck cancer; CI = confidence interval; px = pixel

Table 2. Differences in infiltration assessed by optical flow calculation on ultrasound images and ultrasound infiltration assessed by the radiologist in overall sample, control and HNC patients

	Median (interquartile range)	Difference	95% CI	p*
<b>Overall sample</b>				
Ultrasound/optical flow (%)	7.73 (4.18-23.58)	-3.1	-5.91 to -0.005	0.06
Ultrasound/radiologist (%)	0 (0-20)			
<b>Control patients</b>				
Ultrasound/optical flow (%)	4.33 (0.71-6.61)	-4.0	-5.58 to -2.31	<b>&lt;0.001</b>
Ultrasound/radiologist (%)	0 (0-0)			
<b>HNC patients</b>				
Ultrasound/optical flow (%)	23.86 (8.53-38.33)	-1.36	-9.46-5.78	0.52
Ultrasound/radiologist (%)	20 (20-30)			

\*Wilcoxon test; HNC = head and neck cancer; CI = confidence interval

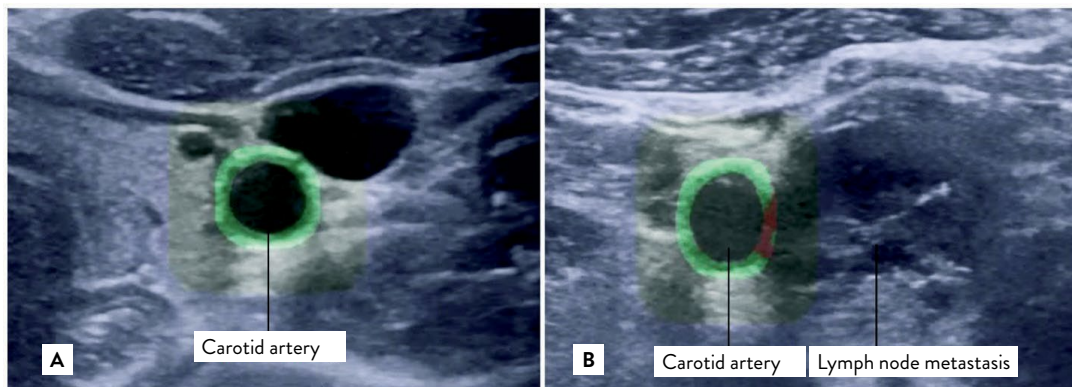


Fig. 2. Optical flow estimation on ultrasound images. The artery wall regions that are or are not infiltrated are graphically indicated: (a) patient without malignant disease of the head and neck; (b) patient with head and neck cancer and cervical lymph node metastasis. Green wall = no infiltration; red wall = infiltrated

## Discussion

Our study showed that CAs described as infiltrated on CT had variable dynamics (i.e., reduced or absent wall motion). Information about the existence of tumor invasion of CA in HNC patients is very important for deciding on the choice of treatment and prognosis. Studies have examined morphological characteristics of the CA wall and the relationship between the CA wall and the surrounding structures<sup>22-25</sup>. Disruption of the echostructure (i.e., the appearance of focal hypoechogenicity of the wall, the loss of fascial plane between the CA and the tumor, and more than half the circumference of the CA being surrounded by a tumor) indicates tumor invasion<sup>24,28-30</sup>. Some studies have suggested that ultrasound and MRI are better predictors of CA invasion<sup>24,29</sup>. Mann *et al.*<sup>37</sup> report that reduced CA mobility and CA compression combined with a slowed flow in the CA indicate invasion.

All CAs described as infiltrated on CT were also marked as dynamically altered on ultrasound. Some arteries moved less than the non-infiltrated arteries. Our study showed that reduced or absent movement of a CA wall next to the metastatically altered lymph node detected by ultrasound indicated tumor invasion. Our study showed that ultrasound could be useful for assessing CA wall invasion in HNC patients.

Considering the subjectivity of ultrasound examination, additional quantification was made. No significant differences were observed even when, for quantification purposes, an optical flow calculation was made on ultrasonic images. The amount of CA movement, assessed by optical flow, also indicated that a segment described as infiltrated on CT and ultrasound images had less movement than the non-infiltrated segment. No significant difference was seen between the assessment of the percentage of infiltrated CA wall by optical flow calculation and the radiologist's assessment. Considering our results, ultrasound can be considered a reliable method for the assessment of CA invasion, complementary to CT. A positive correlation exists between 3 or more image criteria for artery wall infiltration on a CT and an ultrasonically detected weakened or absent wall movement when assessing CA tumor invasion.

The radiologist described appropriate movement of the CA on ultrasound in all control group patients. There were no segments with altered dynamics. Assessment of the amount of movement by calculating optical flow on ultrasound images showed a reduced amount of CA movement in 17 of 22 patients. The percentage of reduced movement was 1%-9%. The reason could be that most of the control group patients were referred to the ultrasound imaging because of arteriosclerotic alterations of CA that contributed to an increased wall rigidity (i.e., contributed to a reduced movement of the CA wall)<sup>38</sup>. Further studies should include patients without signs of arteriosclerotic alterations in their control groups.

This study had several limitations. It was a retrospective study conducted at a single center. All HNC patients underwent postoperative histopathologic tumor analysis but CA in terms of tumor invasion had not been analyzed. Therefore, we used the most available reference method of visualization, i.e., CT. The next limitation was the small number of patients because of a relatively low incidence of CA infiltration from a metastatic lymph node. The possibility of bias existed, considering there is no standardized criterium for evaluating CA infiltration. We used optical flow on ultrasound images to overcome the subjectivity of ultrasound.

## Conclusion

Improving radiological methods in assessing a disease enables better choice of therapy and better prognosis for the patient. Our study provides new insights into the CA dynamics and the possibility of ultrasound application in the assessment of CA wall tumor invasion. The research showed the tumor-infiltrated CAs to have an altered dynamics. The movement of CA wall was either weakened or absent. Ultrasound is a method by which we can analyze the dynamics of arteries in real time and reach an accurate diagnosis in a faster and simpler way. Considering the rarity of this disease, a multicenter study on a larger sample is needed to verify ultrasound as a complementary method for assessing CA invasion.

## References

1. World Health Organization. Global Cancer Observatory. International Agency for Research on Cancer. Geneva: WHO, 2023.
2. Gatta G, Botta L, Sánchez MJ, Anderson LA, Pierannunzio D, Licitra L, *et al.* Prognoses and improvement for head and neck cancers diagnosed in Europe in early 2000s: the EURO CARE-5 population-based study. *Eur J Cancer*. 2015;51(15):2130-43. DOI: 10.1016/j.ejca.2015.07.043.
3. Johnson DE, Burtneß B, Leemans CR, Lui VWY, Bauman JE, Grandis JR. Head and neck squamous cell carcinoma. *Nat Rev Dis Prim*. 2020;6(1):92. DOI: 10.1038/s41572-020-00224
4. Du M, Nair R, Jamieson L, Liu Z, Bi P. Incidence trends of lip, oral cavity, and pharyngeal cancers: global burden of disease 1990-2017. *J Dent Res* 2020;99(2):143-51. DOI: 10.1177/0022034519894963.
5. Sung H, Ferlay J, Siegel RL, Laversanne M, Soerjomataram I, Jemal A, *et al.* Global Cancer Statistics 2020: GLOBOCAN estimates of incidence and mortality worldwide for 36 cancers in 185 countries. *CA: C J Clin*. 2021;71(3):209-49. DOI: 10.3322/caac.21660.
6. Yoo GH, Hocwald E, Korkmaz H, Du W, Logani S, Kelly JK, Sakr W, Jacobs JR. Assessment of carotid artery invasion in patients with head and neck cancer. *Laryngoscope*. 2000;110(3):386-90. DOI: 10.1097/00005537-200003000-00010.
7. Lodder WL, Lange CAH, Teertstra HJ, Pameijer FA, van den Brekel MWM, Balm AJM. Value of MR and CT imaging for assessment of internal carotid artery encasement in head and neck squamous cell carcinoma. *Int J Surg Oncol*. 2013;(2013):968758. DOI: 10.1155/2013/968758.
8. Zanoni DK, Patel SG, Shah JP. Changes in the 8th edition of the American Joint Committee on Cancer (AJCC) Staging of Head and Neck Cancer: Rationale and Implications. *Curr Oncol Rep*. 2019;21(6):52. DOI: 10.1007/s11912-019-0799-x.
9. Teymoortash A, Rassow S, Bohne F, Wilhelm T, Hoch S. Clinical impact of radiographic carotid artery involvement in neck metastases from head and neck cancer. *Int J Oral Maxillofac Surg*. 2016;45(4):422-6. DOI: 10.1016/j.ijom.2015.11.017.
10. Yousem DM, Hatabu H, Hurst RW, Seigerman HM, Montone KT, Weinstein GS, *et al.* Carotid artery invasion by head and neck masses: prediction with MR imaging. *radiology* 1995;195(3):715-20. DOI: 10.1148/radiology.195.3.7754000.
11. Yu Q, Wang P, Shi H, Luo J. Carotid artery and jugular vein invasion of oral-maxillofacial and neck malignant tumors: diagnostic value of computed tomography. *Oral Surg Oral Med Oral Pathol Oral Radiol Endod*. 2003;96(3):368-72. DOI: 10.1016/S1079-2104(03)00366-4.
12. Pons Y, Ukkola-Pons E, Clément P, Gauthier J, Conessa C. Relevance of 5 different imaging signs in the evaluation of carotid artery invasion by cervical lymphadenopathy in head and neck squamous cell carcinoma. *Oral Surg Oral Med Oral Pathol Oral Radiol Endod*. 2010;109(5):775-8. DOI: 10.1016/j.tripleo.2009.12.053.
13. Kim Y, Philouze P, Malard O, Dufour X, Nokovitch L, Céruse P, *et al.* Resection and reconstruction of the carotid artery for head and neck squamous cell carcinoma. *Eur Arch Otorhinolaryngol*. 2022;279(9):4515-23. DOI: 10.1007/s00405-022-07342-6.
14. Zhao Y, Bao D, Wang X, Lin M, Li L, Zhu Z, *et al.* Prediction model based on preoperative CT findings for carotid artery invasion in patients with head and neck masses. *Front Oncol*. 2022;12:987031. DOI: 10.3389/fonc.2022.987031.
15. Chitose S-I, Ono T, Shin B, Sato K, Umeno H. Use of dynamic MRI during swallowing to assess carotid artery invasion by neck metastasis. *Head Neck*. 2018;40(2):330-7. DOI: 10.1002/hed.24960.
16. Orlandi E, Ferrari M, Lafe E, Preda L, Benazzo M, Vischioni B, *et al.* When everything revolves around internal carotid artery: analysis of different management strategies in patients with very advanced cancer involving the skull base. *Front Oncol*. 2021;11:781205. DOI: 10.3389/fonc.2021.781205.
17. Sarvanan K, Bapuraj JR, Sharma SC, Radotra BD, Khandelwal N, Suri S. Computed tomography and ultrasonographic evaluation of metastatic cervical lymph nodes with surgicoclinicopathologic correlation. *J Laryngol Otol*. 2002;116(3):194-9. DOI: 10.1258/0022215021910519.
18. Bennett SH, Futrell JW, Roth JA, Hoye RC, Ketcham AS. Prognostic significance of histologic host response in cancer of the larynx or hypopharynx. *Cancer*. 1971;28(5):1255-65. DOI: 10.1002/1097-0142.
19. Norling R, Grau C, Nielsen MB, Homøe P, Sørensen JA, Lambertsen K, *et al.* Radiological imaging of the neck for initial decision-making in oral squamous cell carcinomas – a questionnaire survey in the Nordic countries. *Acta Oncol*. 2012;51(3):355-61. DOI: 10.3109/0284186X.2011.640346.
20. Welkoborsky HJ. Sonography of the large neck vessels and of tumors with suspected infiltration of the large neck vessels. In: Welkoborsky HJ, Jecker P, editors. *Ultrasonography of the*

- Head and Neck – An Imaging Atlas. Springer, 2019; p. 205-33. DOI: 10.1007/987-3-030-12641-4\_10.
21. Rocha MA, Noschang J, Pinto CAV, Baroni RH, Tachibana A. Diagnostic Imaging Assessment of Tumor Vascular Involvement. In: Zerati AE, Nishinari K, Wolosker N, editors. *Vascular Surgery in Oncology*. Springer, 2022; p. 551-75. DOI: 10.1007/978-3-030-97687-3\_18.
  22. Rothstein SG, Persky MS, Horii S. Evaluation of malignant invasion of the carotid artery by CT scan and ultrasound. *Laryngoscope*. 1988;98(3):321-4. DOI: 10.1288/00005537-198803000-00017.
  23. Hajek PC, Salomonowitz E, Turk R, Tscholakoff D, Kumpan W, Czembirek H. Lymph nodes of the neck: evaluation with US. *Radiology*. 1986;158(3):739-42. DOI: 10.1148/radiology.158.3.3511503.
  24. Langman AW, Kaplan MJ, Dillon WP and Gooding GA. Radiologic assessment of tumor and the carotid artery: correlation of magnetic resonance imaging, ultrasound, and computed tomography with surgical findings. *Head Neck*. 1989;11(5):443-9. DOI: 10.1002/hed.2880110511.
  25. Gritzmann N, Grasl MC, Helmer M, Steiner E. Invasion of the carotid artery and jugular vein by lymph node metastases: detection with sonography. *AJR Am J Roentgenol*. 1990;154(2):411-4. DOI: 10.2214/ajr.154.2.2105036.
  26. Caudell JJ, Gillison ML, Maghami E, Spencer S, Pfister DG, *et al.* NCCN Guidelines® Insights: Head and Neck Cancers, Version 1.2022. *J Natl Compr Cancer Netw*. 2022;20(3):224-34. DOI: 10.6004/jnccn.2022.0016.
  27. Ahuja AT, Ying M, Ho SY, Antonio G, Lee YP, King AD, Wong KT. Ultrasound of malignant cervical lymph nodes. *Cancer Imaging*. 2008;8(1):48-56. DOI: 10.1102/1470-7330.2008.0006.
  28. Wu CH, Chang YL, Hsu WC, Ko JY, Sheen TS, Hsieh FJ. Usefulness of doppler spectral analysis and power doppler sonography in the differentiation of cervical lymphadenopathies. *AJR Am J Roentgenol*. 1998;171(2):503-9. DOI: 10.2214/ajr.171.2.9694484.
  29. Van den Brekel MW, Stel H V, Castelijns JA, Nauta JJ, van der Waal I, Valk J, *et al.* Cervical lymph node metastasis: assessment of radiologic criteria. *Radiology*. 1990;177(2):379-84. DOI: 10.1148/177.2.2217772.
  30. Rotim T, Kristek B, Turk T, Kretić D, Perić M, Pušeljčić I, *et al.* Measurable and unmeasurable features of ultrasound lymph node images in detection of malignant infiltration. *Acta Clin Croat*. 2017;56(3):415-24. DOI: 10.20471/acc.2017.56.03.08.
  31. Vasilj A, Kojić Katović S. Fine-needle aspiration cytology of head and neck lymph nodes in a ten year period – single center experience. *Acta Clin Croat*. 2015;54(3):315-8. <https://hrcak.srce.hr/148894>.
  32. Kumar G, Bhatia PK. A detailed review of feature extraction in image processing systems. *Fourth International Conference on Advanced Computing & Communication Technologies*. 2014; p. 5-12. DOI: 10.1109/ACCT.2014.74.
  33. Bouguet J-Y. Pyramidal Implementation of the Affine Lucas Kanade Feature Tracker Description of the Algorithm. 2001;5(1-10):4.
  34. Farnebäck G. Two-Frame Motion Estimation Based on Polynomial Expansion. In: Bigun J, Gustavsson T, editors. *Image Analysis*. 13th Scandinavian Conference (SCIA). 2003 June 29-July 2; Berlin, Heidelberg: Springer, 2003; p. 363-70.
  35. Bradski G. The Open CV Library. *Dr. Dobb's Journal: Software Tools for the Professional Programmer*. 2000;25(11):120-3.
  36. Widodo CE, Adi K, Gernowo R. Medical image processing using Python and Open CV. *J Phys Conf Ser*. 2020;1524(1):12003. DOI:10.1088/1742-6596/1524/1/012003.
  37. Mann WJ, Beck A, Schreiber J, Maurer J, Amedee RG, Gluckmann JL. Ultrasonography for evaluation of the carotid artery in head and neck cancer. *Laryngoscope*. 1994;104(7):885-8. DOI: 10.1288/00005537-199407000-00020.
  38. Ben-Shlomo Y, Spears M, Boustred C, May M, Anderson SG, Benjamin EJ, *et al.* Aortic pulse wave velocity improves cardiovascular event prediction: an individual participant meta-analysis of prospective observational data from 17,635 subjects. *J Am Coll Cardiol*. 2014 Feb;63(7):636-46.

## Sažetak

## PROCJENA ULTRAZVUKA KAO SLIKOVNO-DIJAGNOSTIČKE METODE U ODREĐIVANJU INVAZIJE KAROTIDNE ARTERIJE U BOLESNIKA OBOLJELIH OD KARCINOMA GLAVE I VRATA

*T. Pandurović, D. Štimac, T. Turk, S. Pešić, V. Zubčić, M. Bogović, N. Čekić i L. Šimić*

Tumorska invazija karotidne arterije (CA) nalazi se u 2%-7% bolesnika sa zloćudnim tumorom glave i vrata (HNC). Ne postoje standardizirani kriteriji za procjenu invazije. Procjenjuje se prvenstveno kompjutoriziranom tomografijom (CT) i magnetskom rezonancijom (MR). Primjenjivao se i ultrazvuk, no metoda nije u svakodnevnoj uporabi. Cilj ovog istraživanja bio je ispitati utjecaj tumorske invazije na dinamiku CA te ulogu ultrazvuka u dijagnostici invazije. Istraživanje je provedeno na dvjema skupinama od po 22 ispitanika. Prvu skupinu činili su ispitanici s poznatim HNC i infiltracijom CA, dok su drugu činili ispitanici bez podataka o HNC. Svim ispitanicima ultrazvučno je procijenjeno gibanje stijenke CA, a potom je CA segmentirana i procijenjena količina gibanja izračunom optičkog toka. Kod svih ispitanika s CT verificiranom infiltracijom CA ultrazvučno i izračunom optičkog toka utvrđeno je smanjeno gibanje stijenke. Rezultati ovog istraživanja pokazuju da oslabljeno ili odsutno kretanje CA može ukaiavati na njezinu infiltraciju.

*Ključne riječi: Karcinom glave i vrata; Invazija karotidne arterije; Optički tok; Segmentacija; Ultrazvuk*