

IRIDOGONIODYSGENESIS SYNDROME: A CASE REPORT

Tamara Knežević, Katja Novak-Lauš, Jelena Škunca and Zdravko Mandić

University Department of Ophthalmology, Sestre milosrdnice University Hospital, Zagreb, Croatia

SUMMARY – A rare case is presented of iridogoniodysgenesis syndrome, an autosomal dominant inheritance disorder that includes abnormalities in the differentiation of the anterior segment structures and increased values of intraocular pressure, which at long run increases the risk of glaucomatous optic neuropathy. The syndrome is diagnosed when ocular changes are accompanied by extraocular structure anomalies such as maxillary hypoplasia, micro- and anodontia, redundant periumbilical skin, inguinal hernia and hypospadias (males). A 44-year-old male patient presented for treatment of retinal detachment on his left eye. Cataract surgery and pars plana vitrectomy with endolaser were done. Due to his vision loss, high intraocular pressure values bilaterally and positive family history of glaucoma, he was rehospitalized for complete glaucomatous diagnostic evaluation. The rare iridogoniodysgenesis syndrome and associated juvenile glaucoma were verified in the patient by positive family history of glaucoma, slit lamp iris hypoplasia and mild pupillary deformities, gonioscopic results of open angle with iridotrabecular synechiae and neovascularizations at the iris root and ciliary body, fundus examination showing optic disk changes with a cup to disk ratio of 0.9 and 0.8 for the right and left eye, respectively, visual field dG2 program abnormalities such as absolute scotomata within 30 degrees on both eyes, and finally optical coherent tomography results of the cup to disk area ratio of 0.9 and 0.8 for the right and left eye, respectively, with average thickness of the retinal nerve fiber layer of 51 mm and 72 mm for the right and left eye, respectively. Disease control was achieved with medicamentous therapy; however, continuous follow up of the patient is a priority to prevent the potential glaucomatous damage.

Key words: *Iris diseases – genetics; Iris – abnormalities; Glaucoma – etiology; Glaucoma – therapy; Case report*

Introduction

The iridogoniodysgenesis syndrome is a spectrum of diseases characterized by abnormalities in the differentiation of the iridocorneal angle tissue (goniodysgenesis) and maldevelopment of the anterior stromal layer of the iris such as hypoplasia and its color¹. It is clinically related to Axenfeld-Rieger syndrome that manifests with iris hypoplasia, prominent Schwalbe's line, and adhesions between iris stroma and iridocorneal angle¹. These genetic abnormalities can stop aqueous humor flow and raise intraocular pressure (IOP), which may result in glaucoma in up to 75% of cases²⁻⁷. The syn-

drome is also manifested with extraocular anomalies such as maxillary hypoplasia, micro- and anodontia, redundant periumbilical skin and hypospadias (in males), and is genetically linked with chromosome 4q25⁸. A gene from 4q25 was mutated in patients with iridogoniodysgenesis and Axenfeld-Rieger syndrome. Several missense mutations of the RIEG-1 gene, encoding various transcription factors important for the anterior segment phenotype, are demonstrated by mutation analysis. Likewise, a mutation which indicates that these syndromes and their phenotypic variability are only allelic variants of the same disorder with different level of the gene expression has also been recognized.

Correspondence to: *Tamara Knežević, MD*, University Department of Ophthalmology, Sestre milosrdnice University Hospital, Vinogradska c. 29, HR-10000 Zagreb, Croatia
E-mail: tamara.knezevic3@zg-tcom.hr

Received May 8, 2008, accepted August 29, 2008

Case Report

A 44-year-old male patient was rehospitalized for complete glaucoma diagnostic evaluation. A month be-

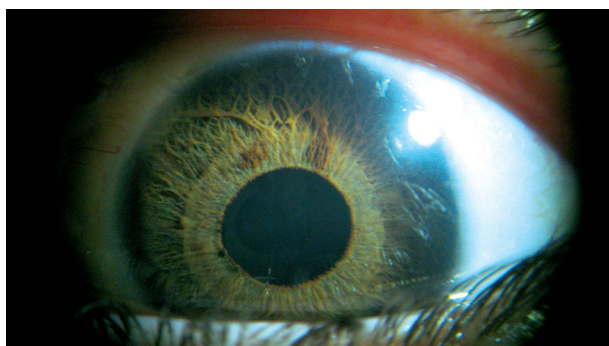
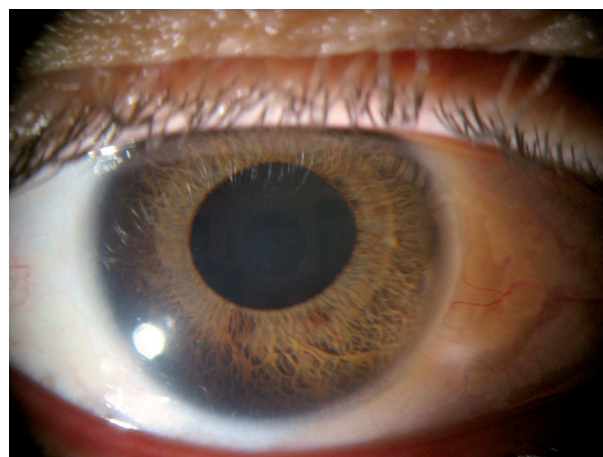


Fig. 1. Anterior segment photodocumentation showing stromal cryptal hypoplasia with pupil deformities.



fore he had initially presented for retinal detachment on the left eye, when phacoemulsification with implantation of the acrylic intraocular lens and pars plana vitrectomy with instillation of silicone oil and endolaser were performed. Then high IOP values were recorded bilaterally, along with positive family history for glaucoma (his mother) and surgical removal of redundant periumbilical skin at age 21. During his second hospital stay, high IOP values bilaterally were recorded again (up to 26 and 42 mm Hg on the right and left eye, respectively). Ophthalmologic examination showed visual acuity of 1.0 on the right eye and 0.15 on the left eye; slit lamp examination of the right eye discovered a central corneal scar, iris stromal hypoplasia and discrete pupil deformities with normal light reactions. The left eye showed iris stromal hypoplasia and discrete pupil deformities with normal light reactions. Therefore, the same developmental changes of the anterior segment

were present in both eyes. Intraocular acrylic lens was implanted in the capsular bag with posterior capsule opacification. Fundus examination showed optical disk changes with a cup to disk area ratio (c/d ratio) of 0.9 and 0.8 for the right and left eye, respectively.

During hospitalization, iris photodocumentation (Fig. 1), clinical examination and photodocumentation of the fundus (Fig. 2), diurnal IOP curve, gonioscopy (Fig. 3), visual field Octopus dG2 program and optical coherent tomography (OCT) were explored to search for and prove glaucomatous damages. Bilateral gonioscopy showed open angle with iridotrabecular synechiae and neovascularizations at the iris root and ciliary body. On day 3 of his hospital stay, we introduced timolol maleate as a therapeutic alternative due to elevated IOP. Afterwards, diurnal IOP curve values under the treatment were 12-17 mm Hg for the right eye and 14-20 mm Hg for the left eye. Visual field testing of the right eye showed abso-

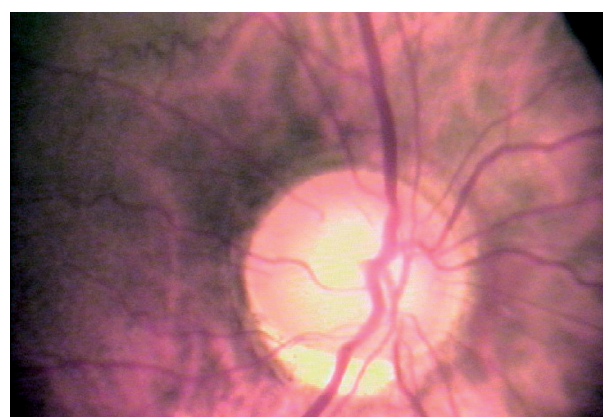
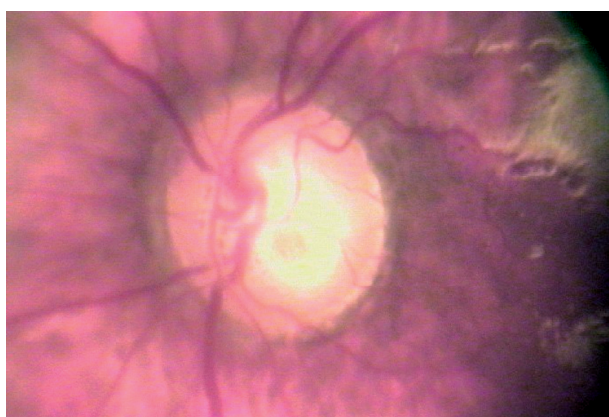

Fig. 2. Fundus photodocumentation showing significant glaucomatous damage (c/d ratio 0.9 and 0.8 for the right and left eye, respectively).




Fig. 3. Gonioscopy findings showing dysgenesis of the angle chamber layers with neovascularizations at the iris root and ciliary body and iridotrabecular synechiae.

lute scotoma in the superior nasal quadrant within 30 degrees and a central absolute scotoma of the left eye. OCT of both eyes proved significant glaucomatous optic nerve damage (c/d area ratio 0.9 with mean retinal nerve fiber layer (RNFL) thickness of 51 μm on the right eye; and c/d area ratio 0.8 with mean RNFL thickness of 72 μm on the left eye). YAG laser capsulotomy was performed. The patient was administered medicamentous monotherapy (timolol eye drops), which proved adequate to achieve normal IOP values, and was discharged from the hospital with recommendation for frequent follow up visits.

Discussion and Conclusion

When having a patient with abnormalities of the iridocorneal angle, positive family history, abnormal IOP values, anterior segment developmental changes with nonocular structure anomalies, it is necessary to consider that such clinical features are underlain by some of the autosomal dominant disorders known as iridogoniodysgenesis syndrome¹. This disorder is characterized by malformations of the anterior segment structures and nonocular structures, and is genetically linked to chromosome 4q25 which contains RIEG-1 gene responsible for the phenotype in these patients⁸. Recently, several mutations of this gene have been discovered, indicating that diseases such as iridogoniodysgenesis and Axenfeld-Rieger syndrome are allelic variants of the same disorder⁸. The phenotypic variability is determined by different levels of the gene expression, and if changes of the anterior segment are mild and especially if glaucomatous damage has not yet occurred, it is quite easy to misdiagnose such abnormalities. There are some literature data confirming the iridogoniodysgenesis syn-

drome to be etiologically related to abnormality of the neural cell migration, leading to the formation of an abnormal segment structure of the eye⁹. Such developmental malformations can obstruct the aqueous humor outflow, which can lead to IOP elevation and consequently to a significant glaucomatous damage in up to 75% of these cases⁷. Considering the high probability of developing glaucoma in these patients, careful follow up is needed to avoid such devastating complications. Therefore, we have presented a case with advanced glaucomatous changes due to structural malformations to underline the need of early diagnosis and strict follow up. In this case, the eye had already been surgically treated for retinal detachment and now medicamentous therapy proved sufficient to normalize high IOP, with close follow up required. Some authors suggest that therapeutic approach should be primarily surgical to facilitate the aqueous humor outflow towards Schlemm's canal and subconjunctival space¹⁰⁻¹⁴. In the present case, such therapeutic option should be considered in case that new glaucomatous changes are observed.

In conclusion, the purpose of this report is to emphasize that iridogoniodysgenesis syndrome as a rare genetic disorder requires early recognition and efficacious therapeutic approach to prevent vision loss due to glaucomatous damage.

References

1. WALTER MA, MIRZAYANS F, MEARS AJ, HICKEY, K, PEARCE WG. Autosomal dominant iridogoniodysgenesis and Axenfeld-Rieger syndrome are genetically distinct. *Ophthalmology* 1996;103:1907-15.
2. KULAKSC *et al.* Mutation in the RIEG1 gene in patients with iridogoniodysgenesis syndrome. *Hum Mol Genet* 1998;7:1113-7.

3. WEATHERILL JR, HART CT. Familial hypoplasia of the iris stroma associated with glaucoma. *Br J Ophthalmol* 1969;53:433-8.
4. MEARS AJ, MIRZAYANS F, GOULD DB, PEARCE WG, WALTER MA. Autosomal dominant iridogoniodysgenesis anomaly maps to 6p25. *Am J Hum Genet* 1996;59:1321-7.
5. JORDAN T, EBENEZER N, MANNERS R, MCGILL J, BATTACHARYA S. Familial glaucoma iridogoniodysgenesis maps to a 6p25 region implicated in primary congenital glaucoma and iridogoniodysgenesis anomaly. *Am J Hum Genet* 1997;61:882-8.
6. PEARCE WG, WYATT HT, BOYD TAS, OMBRES R, SALTER AB. Autosomal dominant iridogoniodysgenesis: genetic features. *Can J Ophthalmol* 1983;18:7-10.
7. JERNDAL T. Congenital glaucoma due to dominant goniodysgenesis. A new concept of hereditary glaucoma. *Am J Hum Genet* 1983;35:645-51.
8. KAISER-KUPFER MI. Neural crest origin of trabecular meshwork and other structures of the anterior chamber. *Am J Ophthalmol* 1989;107:671-2.
9. STRINGERN HM, DINN I, WALTER MA. Genotype-phenotype correlations in Axenfeld-Rieger malformations and glaucoma patients with FOXC1 and PITX2 mutations. *Invest Ophthalmol Vis Sci* 2007;48:228-37.
10. BARKAN O. Surgery of congenital glaucoma. Review of 196 eyes operated by goniotomy. *Am J Ophthalmol* 1953;36:1523-34.
11. BROUGHTON WL, PARKS MM. An analysis of treatment of congenital glaucoma by goniotomy. *Am J Ophthalmol* 1981;91:566-72.
12. SHAFFER RN. Prognosis of goniotomy in primary infantile glaucoma (trabeculodysgenesis). *Trans Am Ophthalmol Soc* 1982;80:321-5.
13. MEYER G, SCHWENN O, PFEIFFER N, GREHN F. Trabeculotomy in congenital glaucoma. *Arch Clin Exp Ophthalmol* 2000;238:207-13.
14. AKIMOTO M, TANIHARA H, NEGI A, NAGATA M. Surgical results of trabeculotomy *ab externo* for developmental glaucoma. *Arch Ophthalmol* 1994;112:1540-4.

Sažetak

SINDROM IRIDOGONIODISGENEZE: PRIKAZ SLUČAJA

T. Knežević, K. Novak-Lauš, J. Škunca i Z. Mandić

Cilj ovoga rada je prikazati bolesnika s rijetkim sindromom iridogoniodisgeneze, autosomno dominantnim poremećajem koji uključuje razvojne poremećaje struktura prednjega segmenta i povišene vrijednosti očnog tlaka, što dugoročno povećava rizik od nastanka glaukomskih oštećenja. Da bi se dijagnosticirao ovaj sindrom, očne promjene moraju biti praćene ekstraokularnim razvojnim poremećajima kao što su zubne nenormalnosti, zaostala periumbilikalna koža, ingvinalna hernija, hipospadija (u muškaraca). Muškarac u dobi od 44 godine hospitaliziran je prvi put zbog ablacije retine lijevoga oka. Izvedena je ekstrakcija katarakte s implantacijom akrilne leće te pars plana vitrektomija s instilacijom silikonskog ulja i endolaserom. Zbog gubitka vida, visokih vrijednosti očnoga tlaka i pozitivne obiteljske glaukomske anamneze (majka) bolesnik je hospitaliziran drugi put radi potpune glaukomske obrade. Osobna anamneza, biomikroskopski pregled, fotodokumentacija šarenica, fundusa, dnevna krivulja tlaka, Octopus dG2 program za vidno polje i rezultati optičke koherentne tomografije dokazali su da se radi o sindromu iridogoniodisgeneze s pratećim juvenilnim glaukomom. Uredne vrijednosti tlaka postignute su medikamentnom terapijom, no daljnje praćenje bolesnika je nužno radi prevencije daljnjih glaukomskih oštećenja.

Ključne riječi: *Bolesti šarenice – genetika; Šarenica – nenormalnosti; Glaukom – etiologija; Glaukom – terapija; Prikaz slučaja*