



Bulletin of the International Association for Paleodontology

Volume 19, Issue 2, 2025

Established: 2007

CONTENT

Maria Istiqomah Marini et al. / Tooth wear among the indigenous Dayak Kenyah of Sungai Bawang village, East Kalimantan, Indonesia: a forensic anthropological perspective	86
Anahit Yurevna Khudaverdyan et al. / Analysis of the craniodental pathology of skulls from the 1st century BC – 3rd century from the monuments Shirakavan, Karmrakar (Armenia) and Bokany (Moldova)	95
Marlin Tolla et al. / Fluorosis and caries in prehistoric populations of Papua Indonesia	109
Sivakumar Pradap et al. / Sex determination using odontometric and anthropometric dimensions of 5-6-year-old children ...	121
Arofi Kurniawan et al. / Radiomorphometric analysis of mandibular symphysis and ramus heights on panoramic radiographs for sex determination in Surabaya, Indonesia	130
Almasyifa Herlingga Rahmasari Amin et al. / Torus palatinus and torus mandibularis as supplementary indicators in forensic human identification: a systematic review	137
Resham Pakhmode et al. / Tooth regeneration using USAG-1 gene: A review	148
Indhra Cahyanita et al. / The use of ear morphoscopy and morphometry in sex determination: a case report	152

Reviewers of this issue:

Nor Atika Ashar, Anita Adamić, Simon Botond, Melike Cangoz, Hasan Hüseyin Erbeden, Almudena Estalrrich, Katie Faillace, Ali Ghanbari, Shalini Gupta, Nur Intaniah binti Ishak, Krishna Kant Gupta, Mohammadreza Karimi, Darko Kero, Zama Moosvi, Efthymia Nikita, Nicole Niklisch, Zuzana Obertová, Swapnil N Patil, Svend Richter, Vineeta Saini, Ayşegül Sarbak, Kara Schotanus, Parul Sinha, Anastasiia V. Sleptsova and Pradhuman Verma.

We thank all the reviewers for their effort and time invested to improve the papers published in this journal.

The use of ear morphoscopy and morphometry in sex determination: a case report *

• Indhra Cahyanita (1), Ade Firmansyah Sugiharto (2), Putu Melati Suci Kusuma (2), Andi Nur Sakina Tri Meilana (1), Ken Sekar Langit (1), Elza Ibrahim Auerkari (1) •

1 - Division of Forensic Odontology, Department of Oral Biology, Faculty of Dentistry, University of Indonesia, Jakarta, Indonesia

2 - Department of Forensic Medicine and Medicolegal Studies, Faculty of Medicine, University of Indonesia, Jakarta, Indonesia

Address for correspondence:

Elza Ibrahim Auerkari

Division of Forensic Odontology, Department of Oral Biology, Faculty of Dentistry, University of Indonesia, Jl. Salemba Raya No.4, Jakarta, Indonesia

Email: eiauerkari@yahoo.com

Bull Int Assoc Paleodont. 2025;19(2):152-156.

Abstract

Sex determination is an important aspect in forensic investigations. Human ears are considered unique, as they have distinctive morphological and morphometric features that allow sex determination and may be used as adjunct evidence. This case report highlights the sex identification of two deceased Indonesian males aged 33 and 76 years by evaluating their ear morphoscopy and morphoscopic measurements. Photographs were taken of the ears of both deceased individuals. Morphoscopic evaluations included evaluations of the Darwin's tubercle, helix form, earlobe form, and earlobe attachment. The morphometric measurements included measurements of the left ear height, left ear width, left lobule height, and left lobule width. The results were compared to those of previous studies. From morphoscopy evaluations and morphometric measurements, both victims were identified as male. In conclusion, ear morphoscopy and ear morphometry can be used as tools for sex determination with accurate data from the respective population to elevate the accuracy of the measurements.

Keywords: ear morphoscopy; ear morphometry; sex determination; forensic

** Bulletin of the International Association for Paleontology is a journal powered by enthusiasm of individuals. We do not charge readers, we do not charge authors for publications, and there are no fees of any kind. We support the idea of free science for everyone. Support the journal by submitting your papers. Authors are responsible for language correctness and content.*



Introduction

The human body has many morphological and morphometric features that have been used in forensic examinations for personal identification, including those of the human ear, which is unique to an individual (1,2). These measurements can be applied for living or deceased individuals and can be used to determine sex and age and for individual identification (1–3).

The human ear has been studied and found to vary both morphologically and morphometrically between people and populations (4–6). Morphometric studies of growth patterns, phenotypic inheritance, and ear morphology have greatly exceeded morphoscopic studies in their clinical and forensic applications (4). Alphonse Bertillon was the first person since the late 19th century to use ears as tools to identify individuals via anthropometric measurements (3,4,7,8).

Data gathering is one of the goals of anthropometry, which involves the measurement of living human body dimensions to comprehend human physical variance (9). Several studies have metrically examined the structure of the ear, including linear distances, ratios, growth variations, and bilateral asymmetry (1–7). Herein, we report two cases where we used ear morphoscopic analysis and morphometric measurements as adjunct evidence for sex determination.

Case report

Photographs and measurements were taken of the ears of two deceased males who were of Indonesian descent, aged 33 and 79 years. For the first individual, who died from a traffic accident, only the left ear was photographed and measured as his right ear was damaged due to injuries suffered during the accident. Photographs and measurements were taken of both ears for the second individual, who died due to an illness. Both deceased individuals were examined within 1–8 hours after their death. The anatomical structures of the ear that were evaluated included Darwin's tubercle, the helix form, the earlobe form, and the earlobe attachment. Morphoscopic evaluations showed that the first deceased individual's Darwin's tubercle was a nodosity type, the helix form was normally rolled, the earlobe form was tongue-shaped, and the earlobe was partially attached. In the second deceased individual, Darwin's tubercle was detected and was a projection type, the helix form was normally rolled, the earlobe form was tongue-shaped, and the earlobe

attachment was free for both ears. Manual vernier callipers were used to measure the ear anthropometry point based on parameters set in previous studies (Figure 1.) (7,8,10,11). Measurements included the left ear height (LEH), left ear width (LEW), left lobule height (LLH), and left lobule width (LLW) (Figure 2.). The measurement results were 63 mm, 37 mm, 21 mm, and 21 mm, respectively, for the first deceased individual and 64 mm, 38 mm, 23 mm, and 25 mm, respectively, for the left ear and 65 mm, 37 mm, 23 mm, and 25 mm, respectively, for the right ear of the second deceased individual. Measurements were performed by one person to avoid interobserver errors.

Discussion

The human ear is made of external, middle, and internal parts, with the external ear includes the pinna and external acoustic meatus (3). The external characteristics of the human ear are unique to each person just like fingerprints (3,7,8,12). Information about the morphological features and normal human ear dimensions of various populations can aid anthropological and forensic efforts to provide data for identification (7).

Previous studies conducted in the UK, India, Nigeria, and Indonesia have shown that males and females have different ear sizes (2,7,8,12,13). Data from all populations show that males have overall longer and wider ears than females (2,7,8,12,13). From our case report, the second deceased individual, who was 79 years old, had longer and wider left ear measurement results compared to the first deceased individual, who was 33 years old. According to Boesoirie et al., for the Sundanese ethnic group from Indonesia, the average measurements for EH, EW, LH, and LW tend to increase with age, but further investigations are needed with more uniform sample sizes for all age groups, as these measurements have not been shown to correlate with age (12).

Previous studies have shown that the left and right ears have different sizes (2,3,7). For example, a study by Jan et al. found that the EH, EW, LH, and LW for the left ear are 60.3 ± 3.3 mm, 30.5 ± 2.4 mm, 16.7 ± 2.0 mm, and 19.8 ± 2.2 mm, respectively, while those for the right ear are 60.3 ± 3.4 mm, 30.1 ± 2.0 mm, 16.5 ± 0.18 mm, and 19.8 ± 0.19 mm, respectively (3). For our case report, the first deceased individual only had the left ear available to evaluate and measure, while the second deceased individual had both ears available. Having measurements

from both ears would have strengthened the conclusions.

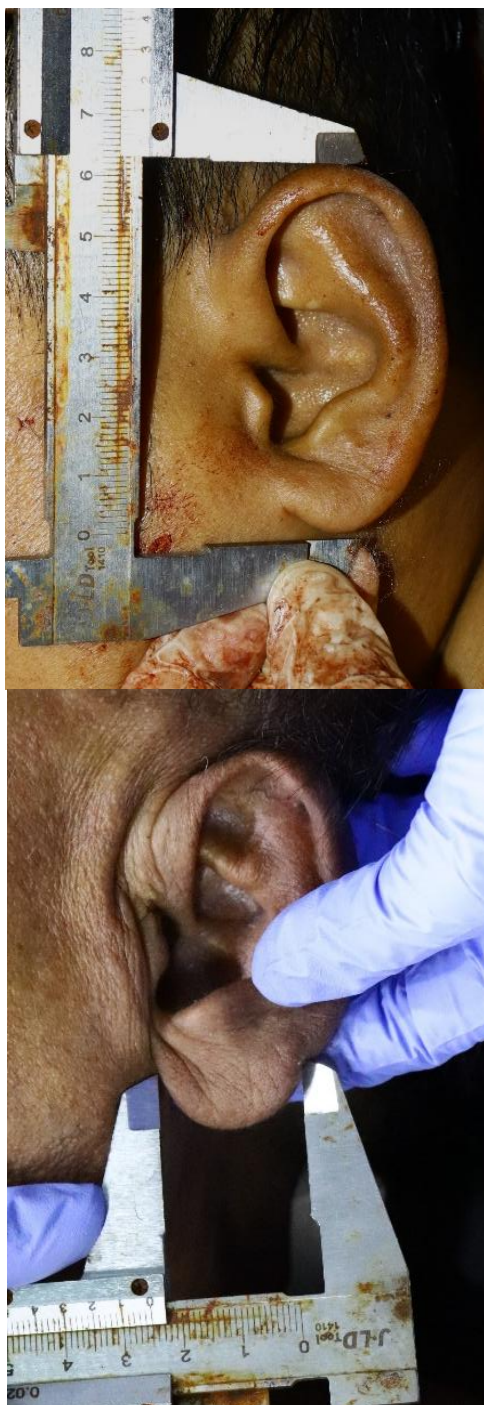

Figure 1. Measure of the ear taken with a vernier caliper.

Our measurements result for the first individual were similar to the average values for the Sundanese Indonesian population aged 26–35 years, which are reported as 61.3 ± 2.3 mm (EH),

28.8 ± 1.8 mm (EW), 17.7 ± 1.5 mm (LH), and 18.4 ± 2.3 mm (LW) (12). The measurements for the second deceased individual, who was 79 years old, fell within the 56–65 year age range measurements of 6.46 ± 0.46 mm (EH), 2.99 ± 0.21 mm (EW), 18.9 ± 0.21 mm (LH), 27.6 ± 1.9 mm (12). Results outside of the aforementioned ranges still fell within the minimum and maximum measurements reported by Boesoerie et al. (12). The morphological features that were assessed have shown different results between two previous studies. Krishan et al. would have identified both individuals as males, as the nodosity, tongue-shape, free lobe, normally rolled morphology, and projection are traits that are found more commonly in males (1). However, Sezgin et al. found that traits such as a free earlobe and normally rolled morphology are found more commonly in females than in males, and a partially attached lobe is found more commonly in males than in females (14). Thus, the first case showed three male characteristics and one female characteristic, while the second case showed two male characteristics and two female characteristics. These discrepancies may be a result the studies being conducted in different populations, namely India and Turkey. There are no such data for Indonesian populations.

In this case report, both deceased individuals were examined within 1–8 hours after their death, at which time, the condition of their soft tissues was still good and there was no deformation because of decomposition. Decomposition or putrefaction is the destruction of the soft tissues of the body as the result of the actions of bacteria and enzymes (15). Most previous studies have been conducted on living humans not deceased individuals, and thus, this needs further investigation.

Conclusion

Both morphoscopy and morphometric methods, using the ear as a tool, can be used for sex determination for deceased individuals, as shown in both cases presented herein. The condition of the ear is important as damage may make them unevaluatable. Using the appropriate data for the population being investigated is also important.

Discussion of limitations

This case report only presents two cases and both deceased were males. Furthermore, both individuals were examined within 1–8 hours after their death, which was not representative of a deceased person's condition at later stages of

decomposition and thus, it is not known whether the ear can be used for identification at later stages. A limited amount of data is available for the Indonesian population and Indonesia has diverse ethnicity, resulting in different morphological traits. Therefore, further studies are needed to gather more data that are representative of the Indonesian population and to investigate changes in the ear caused by decomposition to determine at what stage this method is still relevant. The data obtained can be useful for anthropology and forensics analyses.

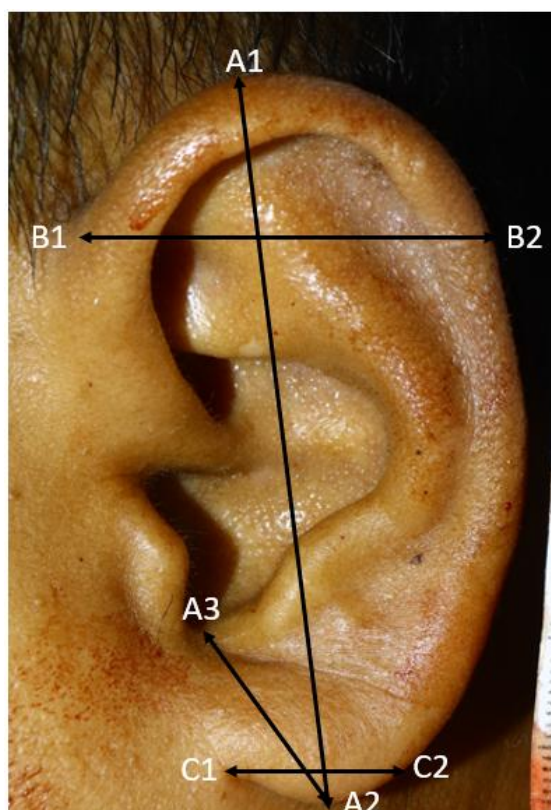


Figure 2. Morphometric measurements used on the human ear (A1-A2 Ear Height; A2-A3 Lobular length; B1-B2- Ear Width; C1-C2- lobular width).

Ethical approval statement

This study was approved by the Ethics Committee of Faculty of Dentistry, University of Indonesia, Jakarta, Indonesia (Number:43/KEPKG/FGUI/XI/2025). The study was conducted in accordance with ethical standards respecting the dignity and confidentiality of the deceased and complied with relevant institutional and national regulations.

Declaration of Interest

None

Author Contributions

IC, AFS, PMSK, ANST, KSL, and EIA contributed to the study's conceptualization. IC, ANST and KSL contributed to data collection, including measurements and documentation. AFS, PMSK, and EIA provided supervision and guidance throughout the studies.

Statement on the use of artificial intelligence in manuscript preparation

Artificial intelligence was not used in the preparation of this manuscript.

References

1. Krishan K, Kanchan T, Thakur S. A study of morphological variations of the human ear for its applications in personal identification. *Egypt J Forensic Sci.* 2019 Dec 1;9(1):1–11.
2. Fakorede ST, Adekoya KO, Fasakin TP, Odufisan JO, Oboh B. Ear morphology and morphometry as potential forensic tools for identification of the Hausa, Igbo and Yoruba populations of Nigeria. *Bull Natl Res Cent.* 2021 Dec;45(1):205.
3. Jan SS, Saleem SM. Ear morphology and anthropometry: gender and age differences in Indian college students. *Indian J Clin Anat Physiol.* 2023 Apr 28;10(1):27–31.
4. Rubio O, Galera V, Alonso MC. Dependency relationships among ear characters in a Spanish sample, its forensic interest. *Leg Med.* 2019 May 1;38:14–24.
5. Purkait R. External ear: An analysis of its uniqueness. *Egypt J Forensic Sci.* 2016;6(2):99–107.
6. Loh TY, Cohen PR. Darwin's Tubercle: Review of a Unique Congenital Anomaly. Vol. 6, *Dermatology and Therapy.* Springer Healthcare; 2016. p. 143–9.
7. Verma P, Sandhu HK, Verma KG, Goyal S, Sudan M, Ladgotra A. Morphological variations and biometrics of ear: An aid to personal identification. *Journal of Clinical and Diagnostic Research.* 2016 May 1;10(5):ZC138–42.
8. Rani D, Krishan K, Baryah N, Kanchan T. Variability in human external ear anthropometry- Anthropological and forensic applications. *Clinica Terapeutica.* 2021 Nov 25;172(6):531–41.
9. Prasetyo AT, Putri IL. Anthropometric Study of Human Ear: A Baseline Data for Ear Reconstruction. *Journal of Craniofacial Surgery.* 2022 Jun 1;33(4):1245–9.
10. Farkas LG, Katic MJ, Forrest CR, Alt KW, Bagič I, Baltadjiev G, et al. International anthropometric study of facial morphology in various ethnic groups/races. *Journal of Craniofacial Surgery.* 2005 Sep 1;16(4):615–46.

11. Sforza C, Grandi G, Binelli M, Tommasi DG, Rosati R, Ferrario VF. Age- and sex-related changes in the normal human ear. *Forensic Sci Int.* 2009 May 30;187(1-3):110.e1-110.e7.
12. Boesoirie SF, Handayani R, Gatera VA, Boesoirie TS, Aroeman NA. Determination of the Difference Between Men and Women Anthropometry Auricles Using Photogrammetric Method in Sundanese Ethnic Group. *Clin Cosmet Investig Dermatol.* 2022;15:2133-41.
13. Alexander KS, Stott DJ, Sivakumar B, Kang N. A morphometric study of the human ear. *Journal of Plastic, Reconstructive and Aesthetic Surgery.* 2011 Jan;64(1):41-7.
14. Sezgin N. Morphological and Metric Identification of Earprint between Sexes. *International Journal of Forensic Sciences.* 2023;8(4):1-10.
15. Mathur A, Agrawal YK. An overview of methods used for estimation of time since death. Vol. 43, *Australian Journal of Forensic Sciences.* 2011. p. 275-85.